

Hepato-protective Effects of *Ocimum Canum Sims* Hydro-alcoholic Leaf Extract in I/R Induced Hepatic Injury in Rats

Saiprasanna Behera, S Manohar Babu, Y Roja Ramani, Prasanta Kumar Choudhury

Saiprasanna Behera, Department of Pharmacology, Royal College of Pharmacy and Health Sciences, Berhampur, Odisha- 760002
Prasanta Kumar Choudhury, Department of Pharmaceutics, Royal College of Pharmacy and Health Sciences, Berhampur, Odisha- 760002, India

S Manohar Babu, Y Roja Ramani, Department of Pharmacology, SIMS College of Pharmacy, Mangaldas Nagar, Guntur- 522001, India

Correspondence to: Saiprasanna Behera, Department of Pharmacology, Royal College of Pharmacy and Health Sciences, Berhampur, Odisha- 760002, India. behera.saiprasanna82@gmail.com
Telephone: +09861252518

Received: June 17, 2012

Revised: July 31, 2012

Accepted: August 6, 2012

Published online: November 21, 2012

ABSTRACT

AIM: The plant *Ocimum canum Sims* (Family: Lamiaceae) is rich in antioxidants, particularly in flavonoids. It has been highly useful in treating various types of diseases and in lowering blood glucose, especially in managing diabetes mellitus. The aim of our work is to evaluate the effect of *Ocimum canum* on a model of hepatic ischemia-reperfusion in Rat.

METHOD: Wistar albino rats were subjected to 45 min of hepatic ischemia, followed by a 60 min reperfusion period. *Ocimum canum* (OC) hydro-alcoholic leaf extract were administered in doses of 100, 200 and 400 mg/kg/day, orally for 15 days before I/R injury respectively and repeated before the reperfusion period. Liver samples were taken for histological examination or determination of hepatic malondialdehyde (MDA), super oxide dismutase (SOD), catalase and glutathione (GSH) activity. Serum aspartate aminotransferase (AST), alanine aminotransferase (ALT), alkaline phosphatase (ALP) and total bilirubin levels were determined to assess liver functions. Lactate dehydrogenase (LDH) was assayed in serum samples for the evaluation of generalized tissue damage.

RESULTS: Ischemia/reperfusion caused a significant decrease in hepatic SOD, catalase and GSH, and significant increase in MDA levels. Serum AST, ALT, ALP and bilirubin levels, as well as LDH activity levels were also elevated in the I/R group. Treatment with OC hydro-alcoholic leaf extract reversed all these biochemical

parameters as well as histological alterations induced by I/R. In all the testing, a significant correlation existed between concentrations of the extract and alteration in the biochemical and histological parameters.

CONCLUSION: OC hydro-alcoholic leaf extract at the dose of 400 mg/kg/day reduced I/R-induced organ injury through its ability to balance the oxidant-antioxidant status.

© 2012 Thomson research. All rights reserved.

Key words: Ischemia/reperfusion; *Ocimum canum* (OC) hydro-alcoholic leaf extract; Antioxidant

Behera S, Babu SM, Ramani YR, Choudhury PK. Hepato-Protective Effects Of *Ocimum Canum* Hydro-alcoholic Leaf Extract, In I/R Induced Hepatic Injury In Rats. *Journal of Gastroenterology and Hepatology Research* 2012; 1(10): 266-273 Available from: URL: <http://www.ghrnet.org/index./joghr/>

INTRODUCTION

Most surgical procedures involve a period of ischemia followed by reperfusion, as do many disease states such as shock, sepsis and pancreatitis. In the liver, ischemia/reperfusion (I/R) injury can occur in several clinical settings such as hepatic trauma, resection of large intrahepatic tumors and liver transplantation^[1] (Serracino-Ingloft *et al*, 2001). Ischemia is a state of tissue oxygen deprivation accompanied by a reduced washout of the resulting metabolites^[2]. Reperfusion is the restoration of blood flow to the ischemic tissue. Despite the unequivocal benefit of reperfusion of blood to an ischemic tissue, reperfusion itself can elicit a cascade of adverse reactions that paradoxically injure tissue^[3]. Deprivation of oxygen to the liver during ischemia induces severe damage; however, much more damaging reactive oxygen species (ROS) are generated during the reperfusion period^[4]. The organ dysfunction that accompanies this condition is generally associated with increased microvascular permeability, interstitial edema, impaired vasoregulation, inflammatory cell infiltration and parenchymal cell dysfunction and necrosis^[5,6].

Free radical ablation for the treatment of reperfusion injury found its first clinical application in the prevention of posts ischemic tissue

injury after organ transplantation^[7,8]. Thus, free radical scavengers and antioxidant agents are thought to be useful in the clinical setting of hepatic I/R damage^[9].

Flavonoids exert their antioxidant effects (countering inflammatory, bacterial, viral, microbial, hormonal, carcinogenic, neoplastic and allergic disorders) by neutralizing all types of oxidizing radicals including the super oxide and hydroxyl radicals and by chelation. Chemically flavonoids are polyphenolic compounds possessing fifteen carbon atoms, two benzene rings joined by a linear three carbon chain. The six subgroups of flavonoids are Chalcones, Flavone, Flavonol, Flavonone, Anthocyanins, Isoflavonoid. Flavonoids also act as powerful chain breaking antioxidants due to the electron donating capacity of their phenolic groups^[10]. Two types of flavonoids are present in *Ocimum* species. Lipophilic flavonoid aglycones (external flavonoids), often highly methylated, are found in glandular hairs on the surface of the leaves, stems and inflorescences. These have been the subject of two recent studies^[11,12]. The second type of flavonoids is polar flavonoid glycosides, which are stored in the vacuoles of aerial plant parts. Nevadensin and salvigenin are found in *O. canum* Sims^[13] (Figure 1).

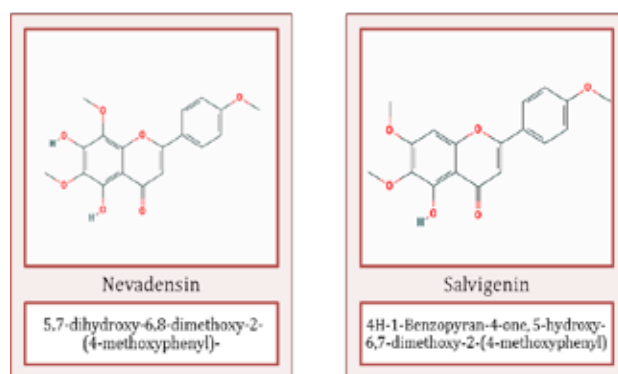


Figure 1 Flavonoid glycosides of *Ocimum canum*.

Ocimum canum Sims. (Hairy Basil) synonymously known as *O. americanum* Linn. is a traditional medicinal plant distributes throughout Odisha and it is commonly known as Kala Tulasi in Odiya has an unusual mint-like flavor. The plant branches out from its base, with angle stems and open foliage. It is not often used as a culinary herb, unlike the related basil species *O. basilicum*, but more often as a medicinal plant. The essential oils found in this species have strong fungicidal activity against certain plant pathogens^[14-16]. In Africa, leaves of *O. americanum* have been used as an insecticide for the protection against postharvest insect damage especially that by bruchid beetles^[17]. Medicinal properties may be associated with the external flavonoids, as some specimens produce very high levels of these compounds, especially nevadensin^[12], which has antioxidant activity^[18].

O. canum is used specially for treating various types of diseases and lowering blood glucose and also treats cold, fever, parasitic infestations on the body and inflammation of joints and headaches^[19]. Essential oil from the leaves of *O. canum* possesses antibacterial and insecticidal properties^[20]. The present study, therefore, investigated the protective effect of *Ocimum canum* hydro-alcoholic leaf extract against oxidative stress during I/R injury of the liver, by measuring biochemical values and conducting histological examinations.

MATERIALS AND METHODS

The experimental protocols were conducted with the approval of the Animal Research Committee at Royal College of Pharmacy and

Health Sciences, Berhampur. Odisha. All animals were maintained in accordance with the recommendations of the CPCSEA.

Animals

Male Wistar albino rats (200-250 g) were obtained from the animal house of R.C.P.H.S. and were housed in an air-conditioned room with 12 h light and dark cycles, with constant temperature (22±2 °C) and relative humidity (65-70%) levels. All experimental protocols were approved by the Institutional Animal Ethical Committee (Approval No-07/IAEC/2011) of Royal College of Pharmacy and Health Sciences, Berhampur. Odisha. India. The rats were anesthetized by intraperitoneal injection of sodium pentobarbital (30 mg/kg). All surgical procedures were conducted with clean but not sterile instruments.

Plant collection

Leaves of *Ocimum canum* were collected in the month of December 2011 from its natural habitat from nearby Mohuda village, Berhampur, Ganjam district of Odisha. India. The plant was authenticated from Department of Botany, Khalikote College, Berhampur, Odisha. India. The leaves were cleaned and dried under the shade to avoid degradation of volatile oil. The leaves were dried in hot air woven at 55°C for 3 d and at 40°C for the next 4 d (Figure 2).



Figure 2 *Ocimum canum*- Western Orissa Medicinal plant Gallery (photo by Surendra Hota Bargarh. Odisha. India.)

Preparation of Plant Extracts

The dried leaves were coarsely powdered and extracted with a mixture of methanol: water (7:3, v/v) by a Soxhlet apparatus at 50°C. The solvent was completely removed and obtained dried crude extract which was used for investigation. Further the extracts were subjected for the antioxidant study as well as pharmacological screening.

Experimental protocol

Under anesthesia, a midline laparotomy was made using minimal dissection. The abdomen was shaved and a transverse incision was performed. The bowel loops were covered with saline-soaked gauze. Total hepatic ischemia was induced for 45 min by clamping the hepatic artery, the portal vein and the bile duct using a vascular clamp and the rats were then allowed to reperfuse for 60 min. Abdominal

incision was closed in layers with 4-0 dexion and 2-0 nylon during reperfusion stage in order to prevent the loss of body fluid and quantity of heat.

Animals were divided into seven groups consisting of six rats each. *Ocimum canum* (OC) hydro-alcoholic leaf extract was dissolved in water and administered to the animals. *Ocimum canum* (OC) hydro-alcoholic leaf extract used in this study contains external flavonoids, especially nevadensin.

Group-I: -NAIVE-Normal control-rats in this group did not undergo ischemia or reperfusion and served as the control group.

Group-II: -SHAM-Sham-operated (animals subjected to the identical procedure of surgery without ischemia-reperfusion injury) plus physiological saline treatment.

Group-III: -I/R-Animals subjected 45 min of total hepatic ischemia, followed by reperfusion for 60 mins and served as untreated experimental control.

Group-IV: -OC control- Sham operated plus *Ocimum canum* control (400 mg/kg body wt. treatment up to 15 d).

Group-V: -OC 100 mg/kg+I/R-Hepatic I/R plus *Ocimum canum* hydro-alcoholic leaf extract 100 mg/kg body wt. treatment up to 15 d.

Group-VI: -OC 200 mg/k +I/R-Hepatic I/R plus *Ocimum canum* hydro-alcoholic leaf extract 200 mg/kg body wt. up to 15 d.

Group-VII: -OC 400 mg/kg+I/R-Hepatic I/R plus *Ocimum canum* hydro-alcoholic leaf extract 400 mg/kg body wt. up to 15 d.

None of the animals died during these procedures. At the end of the reperfusion period, animals were decapitated and trunk blood samples were collected to determine serum alanine aminotransferase (ALT), aspartate aminotransferase (AST), alkaline phosphatase (ALP), bilirubin and lactate dehydrogenase (LDH) activity, the indicators of liver functions and generalized tissue damage, respectively. The hepatic tissue samples were stored at -20°C. Afterwards, tissue malondialdehyde (MDA) levels, an end product of lipid peroxidation, superoxide dismutase (SOD), Catalase and glutathione (GSH), key endogenous antioxidants, were measured in these samples. The hepatic tissue samples were also placed in formaldehyde (10%) for histological evaluation.

Measurement of serum index of hepatotoxicity

Serum alanine aminotransferase (ALT), aspartate aminotransferase (AST), alkaline phosphatase (ALP), bilirubin and lactate dehydrogenase (LDH) activity was measured using commercial kits (Crest Biosystems, Bambolim Complex, Goa, India) and the results are expressed in international units per liter^[21].

Measurement of hepatic oxidative stress markers

(1) Lipid peroxidation was used as an indirect measure of oxidative damage induced by ROS (free radicalinduced injury). Lipid peroxidation was assayed as the malondialdehyde (MDA) level in liver homogenate by the thiobarbituric acid method using tetraethoxypropane as the standard^[22]. A mixture of 8.1% sodium dodecylsulphate (0.2 mL, Merck), 20% acetic acid (1.5 mL), and 0.9% thiobarbituric acid (1.5 mL, Merck) was added to 0.2 mL of 10% tissue homogenate. Distilled water was added to the mixture to bring the total volume to 4 mL. This mixture was incubated (95°C, 1 h). After incubation, the tubes were placed in cold water and 1 mL of distilled water plus 5 mL of n-butanol/ pyridine (15:1, v/v) was added, followed by mixing. The samples were centrifuged (4000 rpm, 10 min). The organic phase (supernatant) was removed, and absorbances were measured with respect to a blank at 532 nm. 1, 1, 3, 3-Tetraethoxypropane was used as the standard. Lipid peroxide levels were expressed as nmol MDA/g of wet tissue; (2)The hepatic antioxidant activity, superoxide dismutase (SOD), was assessed

in the homogenized liver by the method of Sun *et al*^[23]. [0.3 mM xanthine, 0.6 mM Na₂EDTA, 0.15 mM nitroblue tetrazolium (NBT), 0.4 M Na₂CO₃, and 1 g/L bovine serum albumin (BSA)] was added 100 µL of the tissue supernatant. Xanthine oxidase (50 µL, 167 U/L) was added to initiate the reaction and the reduction of NBT by superoxide anion radicals, which are produced by the xanthine-xanthine oxidase system, was determined by measuring the absorbance at 560 nm. Cu, Zn-SOD activity was expressed as units of SOD/mg of tissue protein, where 1 U is defined as that amount of enzyme causing half-maximal inhibition of NBT reduction To 2.45 mL of assay reagent in addition, the total protein content in the liver tissues was determined according to the Lowry's method^[24]; (3) CAT activity was measured by the method by Aebi^[25]. Supernatant (10 µL) was placed in a quartz cuvette and the reaction initiated by adding 2.99 mL of freshly prepared 30 mM H₂O₂ n phosphate buffer (50 mM, pH 7.0). After rapid mixing, the rate of H₂O₂ decomposition was determined from absorbance changes at 15 and 30 s at 240 nm. CAT activity was expressed as k/mg of tissue protein, where k is the first order rate constant; And (4) GSH in liver tissue was assayed by the method of Tietze and Anderson^[26,27]. Briefly, 100 µL of tissue supernatant was placed in a 3 mL cuvette; 750 µL of 10 mM 5-5'-dithio-bis-2-nitrobenzoic acid (DTNB) solution (100 mM KH₂PO₄:KH plus 5 mM Na₂EDTA, pH 7.5 and GSHRD, 625 U/L) was added and the mixture was incubated (3 min, room temperature). Then 150 µL of 1.47 mM β-NADPH was added, mixed rapidly by inversion, and the rate of 5-thio-2-nitrobenzoic acid formation (proportional to the sum of reduced and oxidized glutathione) was measured spectrophotometrically for 2 min at 412 nm. The reference cuvette contained equal concentrations of DTNB and NADPH, but no sample; results were expressed as nmoL/mg of wet tissue

Histological procedures

Liver specimens from all groups were rapidly taken and fixed in Bouin's solution and processed for light microscopic study using hematoxylin and eosin stain^[28]. For light microscopic investigations, hepatic tissue specimens were fixed in 10% formaldehyde, dehydrated in alcohol series, clearing in toluene and embedding in paraffin. Paraffin sections (5 µm) were stained with hematoxylin and eosin (H&E) and examined under a photomicroscope. All tissue sections were examined microscopically for the characterization of histopathological changes by an experienced histologist in blind fashion (Procedures were carried out in NIDAN diagnostics, Berhampur, Odisha, India).

Statistical Analysis

Results are presented as the mean±SEM. All statistical analyses were performed using Graph Pad Prism Software program (version 5)^[29]. Data were analyzed using analysis of variance followed by Bonferroni's post-test. The Kruskal-Wallis 1-way analysis of variance by ranks was used to simultaneously test the pathologic score for the I/R and I/R±*Ocimum canum* groups. A P value of <0.05 was considered statistically significant.

Table 1 Level of alanine aminotransferase (ALT), aspartate aminotransferase (AST) and alkaline phosphatase (ALP) in Serum.

GROUP	TREATMENT	ALT (IU/L) (Mean±SEM)	AST (IU/L) (Mean±SEM)	ALP (IU/L) (Mean±SEM)
GROUP I	Naive	90.40±11.45	196.23±13.32	236.41±21.33
GROUP II	Sham	97.52±10.79	198.71±14.95	230.56±23.08
GROUP III	I/R	212.12±26.06*	324.21±23.32*	337.23±22.12*
GROUP IV	OC control	87.53±16.62	195.38±10.53	224.50±42.08
GROUP V	OC 100 mg/kg+I/R	186.31±17.45**	287.64±17.73**	298.64±31.09**
GROUP VI	OC 200 mg/kg+I/R	152.42±18.19	224.35±13.04	256.21±27.11
GROUP VII	OC 400 mg/kg+I/R	94.62±12.15	197.38±11.02	228.34±20.12

*P < 0.01 vs. naive, sham and OC groups; **P < 0.05 vs. I/R+OC.

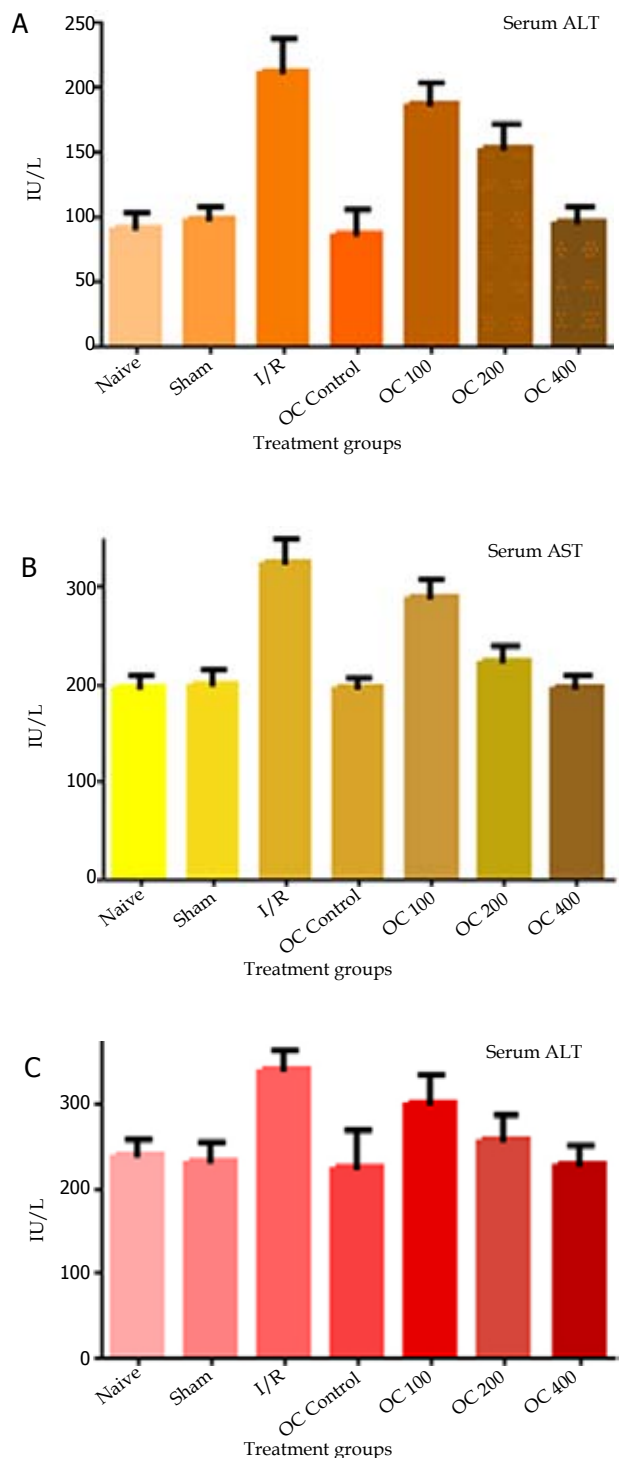


Figure 3 ALT: Level of alanine aminotransferase; AST: aspartate aminotransferase; ALP: alkaline phosphatase.

RESULTS

This study showed no significant difference between the biochemical measurements of group 1 and group 2. Hepatic I/R rats (group 3) showed a significant elevation of serum index of hepatotoxicity (ALT). ALT, AST and ALP levels were significantly higher in the I/R group when compared with those of the control group ($p < 0.001$). OC treatment reversed these values significantly

Similarly, in the I/R group, increased lactate dehydrogenase activity, as an index of generalized tissue damage, was reversed

Table 2 Level of bilirubin and lactate dehydrogenase (LDH) in Serum.

GROUP	TREATMENT	Total Bilirubin (mg/dl)(Mean±SEM)	LDH (U/L) (Mean±SEM)
GROUP I	Naive	0.87±0.09	1197.74±134.58
GROUP II	Sham	0.92±0.07	1395.47±125.60
GROUP III	I/R	2.04±0.23*	2010.96±140.19*
GROUP IV	OC control	0.81±0.09	1145.53±113.53
GROUP V	OC 100 mg/kg+I/R	1.57±0.17**	1740.31±131.76**
GROUP VI	OC 200 mg/kg+I/R	1.04±0.11	1478.47±125.60
GROUP VII	OC 400 mg/kg+I/R	0.84±0.08	1206.56±126.78

* $P < 0.01$ vs. naive, sham and OC groups; ** $P < 0.05$ vs. I/R+OC.

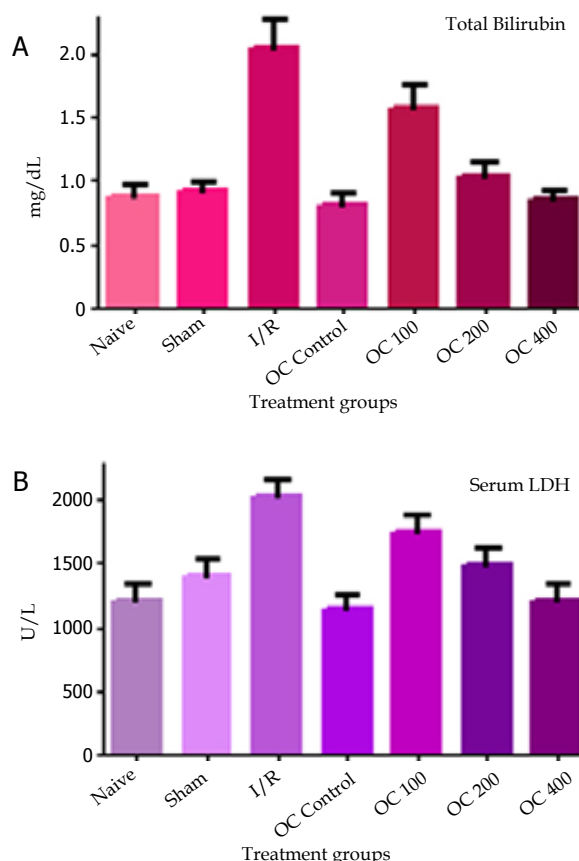


Figure 4 Level of bilirubin and lactate dehydrogenase (LDH) in Serum.

significantly by OC treatment ($p < 0.01$) (Figure 4).

The liver MDA, which is an index of tissue lipid peroxidation, was found to be significantly higher in the I/R group (27.70±2.51 nmol/g), however treatment with OC decreased the elevated MDA level significantly back to the control level (17.28±2.87nmol/g protein) (Figure 5A). The levels of liver SOD lowered significantly after hepatic I/R compared with the sham group (SOD: 30.45±3.19 U/g protein vs 20.43±2.44 U/g protein, $P=0.000$), after administration of *Ocimum canum* hydro-alcoholic leaf extract 100, 200 and 400 mg/kg, SOD activity in liver was elevated (20.43±2.44 U/g protein vs 25.37±2.48 U/g protein, 27.68±2.86 U/g protein, 31.75±2.37 U/g protein, $P=0.706$, $P=0.014$, $P=0.014$) (Figure 5B). Figure 5C shows the plasma Catalase levels of the hepatic injured rat treated with *Ocimum canum* hydro-alcoholic leaf extract 100, 200 and 400 mg/kg. Administration of OC 100, OC 200 and OC 400, showed excellent effects in suppressing the hepatic injury. Among them, OC 400 showed the greatest inhibitory effect against hepatic reperfusion injury. The endogenous antioxidant, GSH, level in the hepatic tissue was decreased significantly after I/R (20.43±2.44 U/g protein). On the other hand OC treatment significantly reversed this I/R-induced

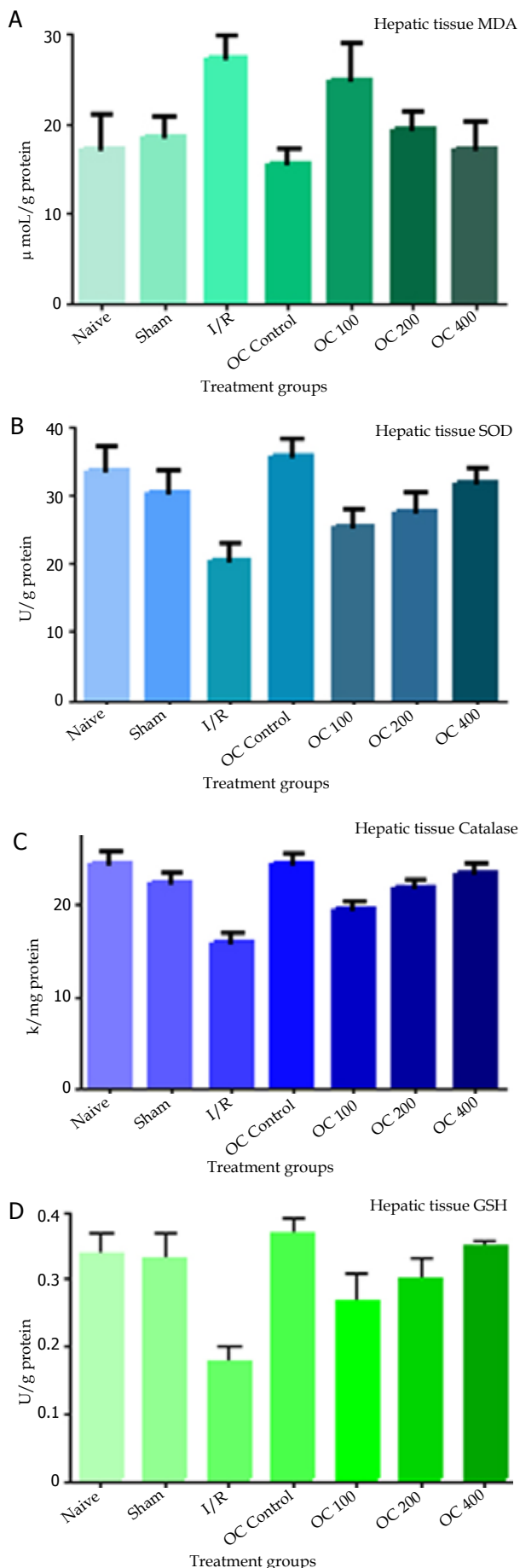


Figure 3 The renal tissue oxidant and antioxidant enzyme levels of the groups.

Table 3 The renal tissue oxidant and antioxidant enzyme levels of the groups.

GROUP	TREATMENT	MDA (nmol/g protein) (Mean±SEM)	SOD (U/g protein) (Mean ± SEM)	CATALASE (k/ protein) (Mean±SEM)	GSH (U/g protein) (Mean ± SEM)
GROUP I	Naive	17.20±3.93	33.65±3.76	24.64±1.24	0.34±0.03
GROUP II	Sham-operated control	18.69±2.08	30.45±3.19	22.45±1.16	0.33±0.04
GROUP III	I/ R	27.70±2.51*	20.43±2.44*	16.05±0.85*	0.18±0.02*
GROUP IV	OC control	15.60±1.44	35.70±2.56	24.53±1.12	0.37±0.02
GROUP V	OC 100 mg/kg+I/R	24.87±4.17**	25.37±2.48**	19.51±0.78**	0.27±0.04**
GROUP VI	OC 200 mg/kg+I/R	19.45±1.83	27.68±2.86	21.87±0.95	0.30±0.03
GROUP VII	OC 400 mg/kg+I/R	17.28±2.87	31.75±2.37	23.43±1.13	0.35±0.01

*P < 0.01 vs. naive, sham and OC groups; **P < 0.05 vs. I/R + OC.

Liver histological examination

Table 4 Histological injury scores of liver tissue.

GROUP	Portal inflammation	Necrosis	Vacuolar degeneration	Sinusoidal dilatation	Vascular congestion
Naive	1	0	0	0	0
Sham	0	0	0	0	1
IR	2	3	2	1	2
IR + OC 100 mg/kg	1	2	1	1	1
IR + OC 200 mg/kg	1	1	0	1	1
IR + OC 400 mg/kg	0	0	0	0	1

Injury Scores: None [0], Mild [1], Moderate [2] and Severe [3]

GSH reduction (0.35±0.01 U/g protein) (Figure 5D).

After 60 minutes of continuous ischemia, large confluent areas of tissue lysis with blood congestion in the sinusoids and leukocyte infiltrates were observed (Figure 6C). In the liver treated with OC 100, limited and focal areas of hepatocyte necrosis were also observed (Figure 6D), whereas the parenchyma was almost normal after OC 200 and OC 400 treatment respectively (Figure 6E and 6F).

Light microscopic investigation of the control group (either given saline or OC) revealed a regular morphology of liver parenchyma with intact hepatocytes and sinusoids (Figure 6A). In the I/R group, severe sinusoidal congestion and hemorrhage, dilation of central vein, subendothelial edema and degenerated hepatocytes with perinuclear vacuolization were observed (Figure 6C). In the OC treated I/R groups, histological analysis demonstrated a well-preserved liver parenchyma. Despite the mild sinusoidal dilatation and hemorrhage, which were in localized areas, the usual appearance of the central vein and hepatocytes was observed in most areas (Figure 6D, 6E and 6F).

DISCUSSION

The current data demonstrate that temporary blockade of hepatic blood supply yielded structural and functional alterations in the liver. The antioxidant, OC, on the other hand, reduced the severity of injury.

I/R injury is a complex process involving numerous intracellular signaling pathways, mediators, cells and pathophysiological disturbances; and its prevention during surgery is of the utmost importance^[30]. Considerable evidence suggests that oxygen derived free radicals are involved in the hepatic injury caused by ischemia and reperfusion^[31-34]. Thus, therapeutic strategies are designed to reduce free radical induced damage, either by intervening in the process by which free radicals are formed or by scavenging the free radicals that have already been formed. Different degrees of protection were obtained with numerous compounds; however, the structure-activity relationship, bioavailability and therapeutic efficacy of these compounds differ extensively. Thus clinical application of these agents is limited in respect of their side effects, toxicity, solubility, membrane penetration etc.

The biological, pharmacological and medicinal properties of

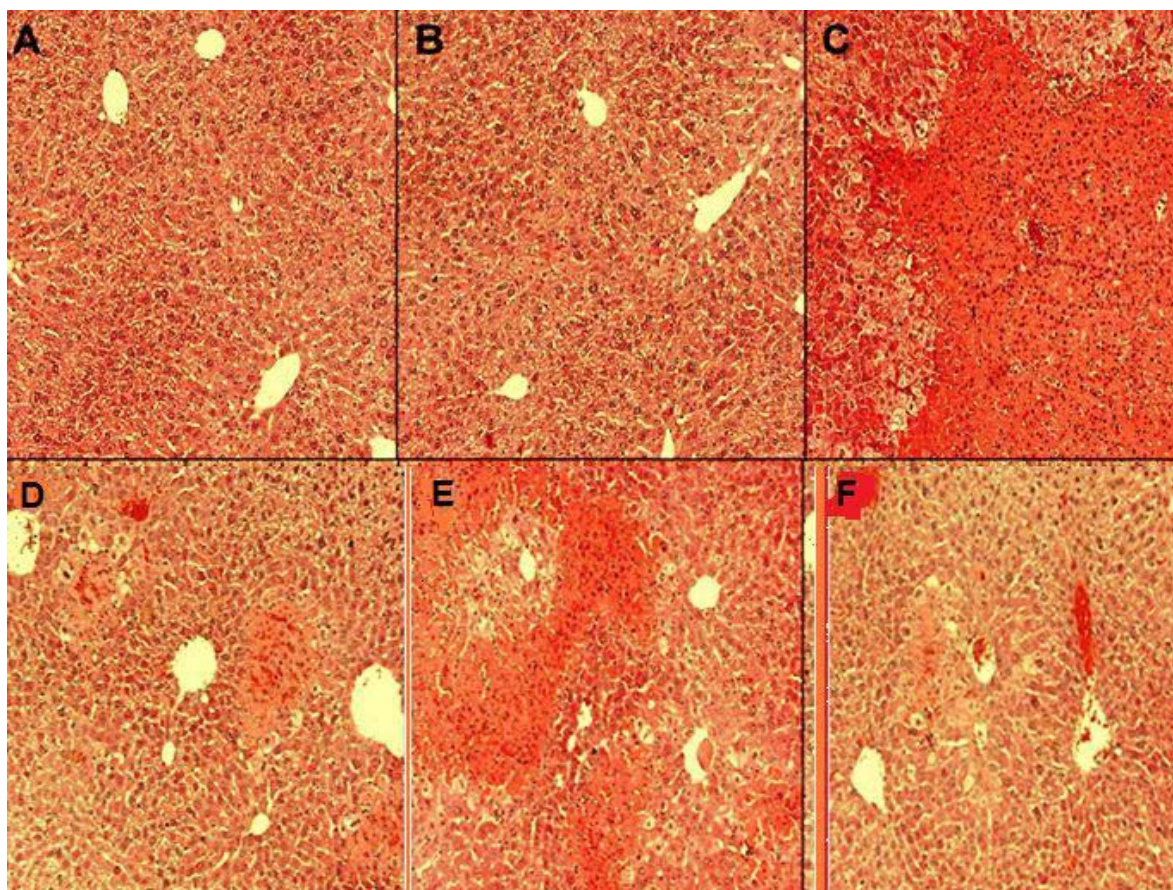


Figure 6 OC pre-treatment prevent histological lesions of the liver following reperfusion injury. Hematoxylin-eosin-stained sections were used for histopathological evaluation of hepatic injuries. The sections were examined at 400-fold magnification. Representative livers as follows: **A:** Normal wistar albino rats; **B:** Sham-operated rats; **C:** Sixty minutes ischemia control group; **D:** OC 100 treated group; **E:** OC 200 treated group; **F:** OC 400 treated group.

bioflavonoids and proanthocyanidins have been extensively reviewed^[35,36]. The structure of flavonoid consists of two hydroxy substituted aromatic rings joined by a three carbon link (a C6-C3-C configuration) which renders them hydrogen and electron donors. Thus, they are effective scavengers of free radicals, which are intermediate products of lipid peroxidation, and they slow down oxidation reactions. The antioxidant activity of flavonoids has been studied in lipid substrates, as well as in relation to human health, in particular with regards to retarding the aging of cells and protecting against certain illnesses such as cardiovascular or coronary disease and cancer^[37]. The main phenolics reported in basil are phenolic acids and flavonol-glycosides^[38,39]. Nevadensin and salvigenin are the two flavonol-glycosides found in *O. canum* Sims

Oxygen radical-initiated lipid peroxidation may contribute to the impaired cellular function and necrosis associated with reperfusion of ischemic tissues^[40]. In the present study, I/R caused significant increases in the hepatic malondialdehyde levels, end products of lipid peroxidation. This observation is in agreement with the previous studies, where elevated levels of lipid peroxidation products were increased from 40% to 80% above basal values^[31,33-34]. Furthermore, our results demonstrated that OC treatment abolishes the increase in malondialdehyde, probably in part by scavenging the very reactive hydroxyl and peroxy radicals. Previous studies have justified that flavonoid glycosides of *Ocimum basilicum* (Labiatae) decreased ulcer index, and inhibited gastric acid and pepsin secretions in aspirin-induced ulcers in rats^[41]. P Caturvedi *et al* in 2008^[42] demonstrated the antioxidant properties *O. canum* exhibiting its hepatoprotective abilities against alcohol-induced oxidative stress.

Oxidative stress-induced tissue damage can be prevented or ameliorated by favoring the balance towards a lower oxidative status. Glutathione is an important constituent of intracellular protective mechanisms against various noxious stimuli, including oxidative stress^[43]. The results of the present study support the notion that depletion of tissue GSH, as observed in the I/R-induced hepatic injury, is one of the major factors that permit lipid peroxidation and subsequent tissue damage. On the other hand, the decrease in hepatic GSH effect was reversed by the administration of *Ocimum canum* hydro-alcoholic leaf extract. A possible explanation for this effect is that *Ocimum canum* functioned as free radical scavenger and therefore increased the available free GSH which detoxifies the reactive intermediary oxygen products of lipid peroxidation induced by I/R.

Superoxide dismutase scavenges the superoxide ions produced as cellular by-products of ethanol metabolism. The reduced SOD activity in the I/R group resulted in the accumulation of superoxide radicals and the production of oxidative stress. The *Ocimum canum* hydro-alcoholic leaf extracts (i.e. OC 100, OC 200 and OC 400) were found to have good scavenging activity, mainly via superoxide anions, at all concentrations tested. The results show significant differences between the normal control and I/R groups ($P \leq 0.001$), but no significant difference from the OC -treated groups

Catalase acts as a preventive antioxidant and plays an important role in protection against the effects of lipid peroxidation. The inhibition of CAT activity suggests that there is increased synthesis of superoxide ions during ischemic reperfusion because superoxide can be a powerful inhibitor of catalase. In all the experiments conducted in the present study, significant differences were seen between the

I/R groups and the normal controls ($P \leq 0.05$), but no significant differences in the experimental groups (i.e. OC 100, OC 200 and OC 400).

Liver transaminases (AST/ALT) are not liver function tests, but are biomarkers of liver injury in a patient with some degree of intact liver function. Alkaline phosphatase (ALP) is an enzyme in the cells lining the biliary ducts of the liver. ALP levels in plasma will rise with large bile duct obstruction, intrahepatic cholestasis or infiltrative diseases of the liver. Lactate dehydrogenase is an enzyme found in many body tissues, including the liver. Elevated levels of LDH may indicate liver damage. Bilirubin is a breakdown product of heme (a part of hemoglobin in red blood cells). Increased total bilirubin causes jaundice, and can signal a number of clinical problems. A significant increase in the levels of liver markers (ALT, AST, ALP and Total bilirubin) was observed in I/R groups, and this may be due to changes in membrane phospholipid composition caused by the peroxidation process, which in turn increases membrane permeability. Treatment with *Ocimum canum* hydro-alcoholic leaf extract helped to prevent this significant increase and appeared to restore the normal condition to some extent.

The results of this study clearly demonstrated that temporary blockade of hepatic blood supply yielded structural and functional alterations in the liver. On the other hand OC treatment improved I/R-induced impairment in the liver functions. It significantly decreased I/R-induced elevations in hepatic lipid peroxidation, lactate dehydrogenase activity and serum ALT, AST, ALP and total bilirubin, while decreased GSH, Catalase and SOD levels were replenished by OC treatment. These protective effects of *Ocimum canum* hydro-alcoholic leaf extract on reperfusion-induced injury can be attributed, at least in part, to its ability to balance oxidant-antioxidant status suggesting a future role in the treatment of organ failures due to ischemia reperfusion.

CONCLUSION

In conclusion, it was found that the plant based antioxidant *Ocimum canum* hydro-alcoholic leaf extract decreased oxygen free radicals during hepatic IR injury in rats. Also, evaluation of liver enzymes and histopathological findings of liver tissue indicated that *Ocimum canum* had beneficial effects on the liver, so *Ocimum canum* can be considered a preventive treatment agent in hepatic IR injury. As this study does not contain information about the long-term results of OC treatment of hepatic IR injury, further experimental and clinical studies are needed.

REFERENCES

- Serracino-Inglott F, Habib NA, Mathie RT. Hepatic ischemia-reperfusion injury. *Am J Surg* 2001; **181**: 160-166
- Star RA. Treatment of acute renal failure. *Kidney Int* 1998; **54**: 1817-1831
- Bonventre JV. Mechanisms of ischemic acute renal failure. *Kidney Int* 1993; **43**: 1160-1178
- Parks DA, Granger DN. Ischemia-reperfusion injury: a radical view. *Hepatology* 1988; **8**: 680-682
- Werns SW, Lucchesi BR. Free radical and ischemic tissue injury. *Trends Pharmacol Sci* 1990; **11**: 161-166
- Granger DN, Korhuis RJ. Physiological mechanisms of postischemic tissue injury. *Ann Rev Physiol* 1995; **57**: 311-332
- Amersi F, Nelson SK, Shen XD, Kato H, Melinek J, Kupiec-Weglinski JW, Horwitz LD, Busuttill RW, Horwitz MA. Bucillamine, a thiol antioxidant, prevents transplantation-associated reperfusion injury. *Proc Natl Acad Sci USA* 2002; **99**: 8915-8920
- Seo MY, Lee SM. Protective effect of low dose of ascorbic acid on hepatobiliary function in hepatic ischemia/reperfusion in rats. *J Hepatol* 2002; **36**: 72-77
- Kupiec-Weglinski JW, Busuttill RW. Ischemia and reperfusion injury in liver transplantation. *Transplant Proc* 2005; **37**: 1653-6
- Naveen Kumar V, Raju R. Flavonoids as antioxidants. Available from: URL: <http://farmacists.blogspot.in/2009/05/flavonoids-as-antioxidants.html>
- Grayer RJ, Bryan SE, Veitch NC, Goldstone FJ, Paton A, Wollenweber E. External flavones in sweet basil, *Ocimum basilicum*, and related taxa. *Phytochemistry* 1996; **43**: 1041-1047
- Grayer RJ, Veitch NC, Kite GC, Price AM, Kokubun T. Distribution of 8-oxygenated leaf surface flavones in the genus *Ocimum*. *Phytochemistry* 2001; **56**: 559-567
- Xaasan CC, Ciilmi CX, Faarax MX, Passannanti S, Piozzi F, Paternostro M. Unusual flavones from *Ocimum canum*. *Phytochemistry* 1980; **19**: 2229-2230
- Singh RK, Dwivedi RS. Effect of oils on *Sclerotium rolfsii* causing foot rot of barley. *Indian Phytopathology* 1987; **40**: 531-533
- Shukla RP, Singh RK, Dwivedi RS. Toxicity of essential oils against *Rhizoctonia solani* Kuhn fungus causing sheath blight (ShB) in rice. *International Rice Research Newsletter* 1990; **15**: 27
- Dubey RC. Fungicidal effect of essential oils of three higher plants on sclerotia of *Macrophomia phaseolina*. *Indian Phytopathology* 1991; **44**: 241-244
- Weaver DK, Dunkel FV, Ntezurubanza L, Jackson LL, Stock DT. The efficiency of linalool, a major component of freshly milled *Ocimum canum* Sims (Lamiaceae), for protection against post-harvest damage by certain stored product Coleoptera. *Journal of Stored Products Research* 1991; **27**: 213-220
- Grayer Renee J, Geoffrey C, Kite, Nigel C, Veitch, Maria R, Eckert, Petar D, Marin, Priyanganie Senanayake, Alan J, Paton. Leaf flavonoid glycosides as chemosystematic characters in *Ocimum*. *Biochemical Systematics and Ecology* 2002; **30**: 327-342
- Ngassoum MB, Ousmaila H, Ngamo LT, Maponmetsem PM, Jirovetz L, Buchbauer G. Aroma compounds of essential oils of two varieties of the spice plant *Ocimum canum* Sims. from northern. *Cameroon J Food Comp Anal* 2004; **17**: 197-204
- Bassole IHN, Guelbeogo WM, Nebie R, Costantini C, Sagnon NF, Kabore ZI, Traore SA. Ovicidal and larvicidal activity against *Aedes aegypti* and *Anopheles gambiae* complex mosquitoes of essential oils extracted from three spontaneous plants of Burkina Faso. *Parasitology* 2003; **45**: 23-26
- Reitman S, Frankel S. A colorimetric method for determining serum glutamic oxaloacetic and glutamic pyruvic transaminases. *Am J Clin Pathol* 1957; **28**: 56-63
- Ohkawa H, Ohishi N, Yagi K. Assay for lipid peroxides in animal tissues by thiobarbituric acid reaction. *Anal Biochem* 1979; **95**: 351-358
- Sun Y, Oberley LW, Li Y. A simple method for clinical assay of superoxide dismutase. *Clin Chem* 1988; **34**: 497-500
- Lowry OH, Rosebrough NJ, Farr AL, Randall RJ. Protein measurement with the Folin phenol reagent. *J Biol Chem* 1951; **193**: 265-275
- Aebi H. Catalase in vitro. *Methods Enzymol* 1984; **105**: 121-126
- Tietze F. Enzymic method for quantitative determination of nanogram amounts of total and oxidized glutathione: applications to mammalian blood and other tissues. *Anal Biochem* 1969; **27**: 502-522
- Anderson ME. Determination of glutathione and glutathione disulfide in biological samples. *Meth Enzymol* 1985; **113**: 548-555

- 28 Bancroft JD, Gamble M. Theory and practice of histological techniques. 6th ed. China: Churchill Livingstone; 2008
- 29 Harvey J, Paige SM. The InStat Guide to choosing and interpreting statistical tests: A manual for Graph pad InStat, Version 3. San Diego, CA USA. 1998
- 30 Marubayashi S, Dohi K. Therapeutic modulation of free radical-mediated reperfusion injury of the liver and its surgical implications. *Surg Today* 1996; **26**: 573-580
- 31 Sener G, Tosun O, Sehirli AO, Kaçmaz A, Arbak S, Ersoy Y, Ayanoglu-Dülger G. Melatonin and N-acetylcysteine have beneficial effects during hepatic ischemia and reperfusion. *Life Sci* 2003; **72**: 2707-2718
- 32 Sener G, Sehirli O, Ipçi Y, Ercan F, Sirvanci S, Gedik N, Yeğen BC. Aqueous garlic extract alleviates ischemia-reperfusion-induced oxidative hepatic injury in rats. *J Pharm Pharmacol* 2005; **57**: 145-150
- 33 Oflluoglu E, Kerem M, Pasaoglu H, Turkozkan N, Seven I, Bedirli A, Utku Yilmaz T. Delayed energy protection of ischemic preconditioning on hepatic ischemia/ reperfusion injury in rats. *Eur Surg Res* 2006; **38**: 114-121
- 34 Zhu WH, Leng XS, Zhu JY. Effect of Shenfu injection on ischemia-reperfusion injury of rat liver graft. *Hepatobiliary Pancreat Dis Int* 2006; **5**: 205-209
- 35 Shahidi F, Wanasundara PK. Phenolic antioxidants. *Crit Rev Food Sci Nutr* 1992; **32**: 67-103
- 36 Rice-Evans CA, Miller NJ, Paganga G. Structure-antioxidant activity relationships of flavonoids and phenolic acids. *Free Radic Biol Med* 1996; **20**: 933-956
- 37 Shahidi F. Flavonoids as Antioxidants; Natural Antioxidants. Chemistry, Health Effects and Practical Applications. AOCS Press: Champaign Illinois, 1997; pp. 174-194
- 38 Javanmardi J, Khalighi A, Kashi A, Bais HP, Vivanco JM. Chemical characterization of basil (*Ocimum basilicum* L.) found in local accessions and used in traditional medicines in Iran. *Journal of Agricultural and Food Chemistry* 2002; **50**: 5878-5883
- 39 Kividompolo, M. and T. Hyotylainen. Comprehensive two-dimensional liquid chromatography in analysis of Lamiaceae herbs: Characterization and quantification of antioxidant phenolic acids. *Journal of Chromatography* 2007; **1145**: 155-164
- 40 Stark G. Functional consequences of oxidative membrane damage. *J Membr Biol* 2005; **205**: 1-16
- 41 Alarcon DL, Martin MJ, Locasa C, Motilva V. Antiulcerogenic activity of flavonoids and gastric protection. *Ethnopharmacol* 1994; **42**: 161-170
- 42 Chaturvedi P and George S. Protective role of *Ocimum canum* plant extract in alcohol-induced oxidative stress in albino rats. *Br J Biomed Sci* 2008; **65**: 80-85
- 43 Ross D. Glutathione, free radicals and chemotherapeutic agents. *Pharmacol Ther* 1988; **37**: 231-249

Peer reviewers: Dhruba Sankar Goswami, M.Pharm (Pharmaceutics)(PhD), Lecturer, S.D.College of Pharmacy, Barnala, Punjab 148101, India; Pooja Maity, Kalinga Institute Of Medical Sciences, Bhubaneswar, India.