

The Impact of MSI Phenotype by MLH1 Expression in Gastric Adenocarcinomas: Critical Analysis of the Brazilian Experience

Kleber Simões, MD, PhD, Carlos Eduardo Jacob, MD, PhD, Rui Manuel Reis, PhD, Bruno Zilberstein, MD, PhD, Suely Nonogaki, BSc, Rodrigo Albergaria Réssio, BSc, Alda Wakamatsu, MSc, Cláudio Bresciani, MD, PhD, Joaquim Jose Gama-Rodrigues, MD, PhD, Ivan Ceconello, MD, PhD, Adhemar Longatto-Filho, MSc, PhD, P.M.I.A.C., Venâncio Avancini Ferreira Alves, MD, PhD

Kleber Simões, Rodrigo Albergaria Réssio, Alda Wakamatsu, Adhemar Longatto-Filho, Venâncio Avancini Ferreira Alves, Laboratory of Medical Investigation (LIM) 14, Faculty of Medicine, University of São Paulo, São Paulo, Brazil

Rui Manuel Reis, Adhemar Longatto-Filho, Molecular Oncology Research Center, Barretos Cancer Hospital, Pio XII Foundation, Barretos, Brazil

Rui Manuel Reis, Adhemar Longatto-Filho, Life and Health Sciences Research Institute (ICVS), School of Health Sciences, University of Minho, Braga, Portugal; ICVS/3B's - PT Government Associate Laboratory, Braga/Guimarães, Portugal

Suely Nonogaki, Division of Pathology, Adolfo Lutz Institute, São Paulo, Brazil

Carlos Eduardo Jacob, Bruno Zilberstein, Cláudio Bresciani, Joaquim Jose Gama-Rodrigues, Ivan Ceconello, Department of Gastroenterology, University of Sao Paulo School of Medicine, Brazil.

Conflict-of-interest statement: The authors declare that there is no conflict of interest regarding the publication of this paper.

Open-Access: This article is an open-access article which was selected by an in-house editor and fully peer-reviewed by external reviewers. It is distributed in accordance with the Creative Commons Attribution Non Commercial (CC BY-NC 4.0) license, which permits others to distribute, remix, adapt, build upon this work non-commercially, and license their derivative works on different terms, provided the original work is properly cited and the use is non-commercial. See: <http://creativecommons.org/licenses/by-nc/4.0/>

Correspondence to: Prof. Venâncio Avancini Ferreira Alves, M.D., PhD, Department of Pathology, University of São Paulo School of Medicine, Brazil.

Email: venancio@uol.com.br

Received: October 23, 2017

Revised: November 28, 2018

Accepted: December 2, 2018

Published online: December 21, 2018

ABSTRACT

BACKGROUND: Gastric cancer remains a clinical concern due to its high prevalence and mortality; consequently, efforts for comprehensive molecular subtyping, as related to morphology and prognosis, are mandatory.

MATERIALS AND METHODS: We correlated the immunohistochemical expression profile of a panel with two major mismatch-repair (MMR) enzymes MLH1 and MSH2 with clinicopathological features and prognosis in a series of 133 gastric cancers and compared with worldwide experience.

RESULTS: MMR negativity was found associated to clinicopathological features as proximal location, predominantly polypoid and fungating macroscopic types (Bormann's type I and II), intestinal and tubular morphology according to Lauren's and WHO systems respectively, expansible type according to Ming classification, heavy lymphoplasmacytic infiltrate and absent perineural infiltration. Loss of MLH1 immunorexpression was related to a beneficial impact on disease-specific survival; an independent prognostic impact at multivariate models was observed in cases with the loss of MLH1.

CONCLUSIONS: Taken together, these results validate the biological significance of immunohistochemical detection of MMR enzymes as a method to identify specific pathological features and to assess prognosis in gastric cancer.

Key words: Microsatellite instability; Mismatch repair enzymes; Gastric cancer; Pathology; Prognosis

© 2018 The Author(s). Published by ACT Publishing Group Ltd. All rights reserved.

Simões K, Jacob CE, Reis RM, Zilberstein B, Nonogaki S, Réssio RA, Wakamatsu A, Bresciani C, Gama-Rodrigues JJ, Ceconello I, Longatto-Filho A, Alves VAF. The Impact of MSI Phenotype by MLH1 Expression in Gastric Adenocarcinomas: Critical Analysis of the Brazilian Experience. *Journal of Gastroenterology and Hepatology Research* 2018; **7(6)**: 2759-2767 Available from: URL: <http://www.ghrnet.org/index.php/joghr/article/view/2180>

INTRODUCTION

Gastric cancer still carries high mortality rates and remains among the most important causes of cancer-related death worldwide, mainly in high incidence areas^[1]. Data from USA pointed out 21,600 new cases and 10,990 deaths, annually^[2]. Despite the progressive reduction in incidence in the last five decades and improvement on surgical and oncologic treatment, the worldwide incidence clearly demonstrate that Asia still remains as the main focus of gastric cancer burden, with circa 70% of the cases diagnosed globally; conversely, Central and South America have 7% of all gastric cancer reported^[1]. However, mortality is Latin America, including Brazil, is proportionally high in comparison with other continents^[1-3], which seriously indicate the necessity to improve gastric cancer management. Currently, several efforts are addressed to a better comprehension of molecular characteristics of gastric cancer subtyping, as related to morphology, in order to improve the histopathological classification of these tumors^[4]. Moreover, the precise histopathological and molecular classification of the tumours represents critical variables for the efficiency of targeted therapies options^[5]. Gastric carcinogenesis is related to a plethora of molecular alterations that involves, epigenetics alteration, genetic mutations and copy number aberrations of oncogenes, suppressor tumor genes, dietary related risk factors where and nitrates and high salt intakes, and infection agents, such as *Helicobacter pylori* (*H. pylori*)^[6-11]. Among all these variables, the microsatellite instability (MSI) represented a genetic pathway, that is characterized by inactivation of DNA mismatch repair (MMR) genes, and consequently originates frameshift mutation in microsatellite regions leading to new alleles that are not found in the normal subjects^[6,10]. The reports that explored the presence of MSI in gastric cancer are limited reports and showed opposing results concerning the associating MSI phenotype and patient survival^[8]. This scenario, however, contrast with colorectal cancer (CRC), in which at least two apparently exclusive oncogenic phenotypes have already been well documented and their pathological characteristics and prognostic significance well characterized: chromosomal instability versus microsatellite instability (MSI) pathways, the latter related to methylation phenotype^[9]. Chromosomal instability is characterized by significant structural genetic aberrations, such as loss of chromosomal arms, large deletions, insertions, translocations and rearrangements, commonly associated to the classical *APC*, *kRAS* and *TP53* mutations, usually leading to a worse prognosis. The alternate molecular phenotype, MSI was initially identified as a phenotype of hereditary non-polyposis colorectal cancer syndrome-related tumors (HNPCC or Lynch syndrome); yet, MSI has also been detected in 15% to 20% of sporadic CRC. Although this subdivision is not yet well acknowledged in gastric cancer, rates from 5% to 50% of MSI have been reported in gastric carcinomas. For tumors of different organs, immunohistochemical assessment of MMR enzymes expression (MLH1, MSH2, MSH6 and PMS2) has been validated as a good predictive tool for MSI phenotype detection, and an alternative to more expensive molecular studies as the initial approach in research or diagnostic settings, including screening of tumors of patients fulfilling Amsterdam and/or Bethesda criteria for Lynch syndrome^[11, 12]. Currently, validated and well-accepted technical recommendations about MMR status determination employing well-controlled and standardized immunohistochemical assays are available^[13-15]. However, herein we opted to analyze the expression of MLH1 enzyme that currently is accepted as one of the critical constituents of the MMR apparatus. The h-MLH1/PMS2 heterodimer was associated to the human MMR system and cancer.

Genetic and epigenetic alterations occurring in MLH1 is one of the most important mechanisms that drive MMR alterations occurrence in MSI gastrointestinal carcinomas^[16].

MATERIAL AND METHODS

Patients and specimens

Paraffin blocks from 133 gastrectomy specimens treated between February 1993 to December 2002 at the Department of Gastroenterology, were retrieved from the files of Department of Pathology, Hospital das Clinicas, University of Sao Paulo, School of Medicine. Inclusion criteria for this study encompassed localized tumors, not showing distant metastatic disease at diagnosis, infiltrating at least *muscularis propria* (pT2a and higher according to TNM 2002/AJCC staging system), irrespective of lymph node status. All patients were treated according to a well-established surgical protocol (gastrectomy and D2 lymph node dissection) at the Department of Gastroenterology, Hospital das Clinicas, University of Sao Paulo, a national reference center^[17]. Patients with familial history of gastric cancer were not included in this study. Clinical status and outpatient follow-up data of patients last updated was in July 2008.

Assessment of pathological variables

Four-micrometer histological sections obtained from original paraffin blocks and, after Haematoxylin-eosin staining, were submitted to histological review. Primary tumors were histologically classified according to World Health Organization^[18] in tubular, tubule/papillary, signet-ring cell and mucinous categories. Lauren^[19] and Ming's^[20] systems were also applied to primary tumors classification, stratifying lesions into diffuse or intestinal and infiltrating or expansile types respectively, the latter derived from evaluation of deepest tumoral edge. The maximum level of tumoral infiltration in gastric wall was determined as *muscularis propria*, subserosa, penetrating subserosa or direct invasion of adjacent structures. Lymphatic vascular and perineural invasion was assessed as non-detected or present. Pathological nodal status (pN) was determined by counting of histologically affected lymph nodes and classified as pN0, pN1, pN2 or pN3 according to AJCC/UICC TNM Staging system I. Information about largest dimension of primary tumor was obtained from original surgical pathology reports, as well as its main location, classified as proximal (*cardia, fundus* and *proximal corpus*) or distal tumors (*distal corpus, antrum* and *prepyloric region*). Borrmann classification^[21] was also achieved from the original macroscopic reports and the cases were grouped in polypoid/fungating (types I and II) or ulcerated/infiltrative/mixed categories (types III, IV and V). Peri/intratumoral inflammatory infiltrate was semi-quantified as absent, mild/moderate and intense whereas desmoplastic stromal response as absent, mild, moderate or intense. Final pathological TNM stage was also assessed.

Tissue Micro-Arrays

All haematoxylin-eosin stained slides were re-evaluated, allowing selection of primary tumor areas for Tissue Microarray (TMA) spotting as previously described^[22]. The respective paraffin blocks were marked and TMA constructed using a 1.0 mm gauge for tissue cylinder extraction of donor and placement on receptor block, using a Manual Tissue Microarrayer from Beecher Instruments (model MTA1). Each individual case was sampled twice on receptor block as a strategy for overcoming representativity losses inherent to TMA method, as stated in papers describing validation of this

technology^[23-28]. TMA paraffin blocks were sectioned on a Leica microtome in three µm sections.

Immunohistochemistry

In situ detection of MMR enzymes was achieved through immunohistochemistry (IHC) employing primary monoclonal antibodies to MLH1 (clone G168-15, dilution 1: 100), MSH2 (clone G219-1129, dilution 1: 800), MSH6 (clone 44-MSH6, dilution 1: 100) and PMS2 (clone A16-4, dilution 1: 1.000), all purchased from BD Biosciences Pharmingen. For IHC assays, sectioned slides from TMA paraffin blocks were dewaxed, rehydrated and submitted to heat induced antigen retrieval in pH = 6.0 citrate buffer using a steamer for 30 minutes. Endogenous peroxidase was blocked using 6% H₂O₂ and sections from primary tumors overnightly incubated with primary antibodies at 4°C. Avidin-biotin free polymer-based amplification system (Novolink, Novocastra, UK) and diaminobenzidine as chromogen were used for development of reaction products. Positive controls represented by two cases of colorectal adenocarcinoma known to express all four MMR enzymes were used, as well as negative controls established by omitting the primary antibody incubation step, were used in every reaction. Lymphocytes, endothelial cells and, whenever present, non-neoplastic gastric foveolar cells served as internal positive controls. Representative spots of primary tumors placed on TMA were evaluated and scored as Lost (when no positive reaction was observed) or Preserved (when at least 10% of positive reaction was found), considering that at least some degree of well-defined nuclear immunostaining must be seen for a case to be regarded as positive. Positive internal controls (lymphocytes, endothelial cells or non-neoplastic mucosa) were found in a particular sample to validate the absence of neoplastic nuclear staining as a true negative result. Each MMR enzyme was individually analyzed, as well as all possible combination sets of negativities, with respective frequencies of each enzyme and combination set reported.

Validation of TMA findings in large sections All cases with TMA samples resulting negative were confirmed by validation of reaction in conventional large sections, with the same stringent criteria used for positive or negative assignment. Cases with negative result in TMA and positive in large section were scored as positive.

Statistical analysis

Clinicopathological variables were compared between MMR enzymes positive and negative groups, stratified according to MLH1 and MSH2 status in primary tumors (lost or preserved) using Pearson's chi square test and considered significant at $p < 0.05$. To demonstrate influence of different clinicopathological variables, as well as primary tumor MMR enzymes status, on gastric cancer related mortality, univariate comparisons were made by Log-rank test (considered significant at $p < 0.05$ level). Cox multivariate proportion of hazards models were constructed to assess differential contributions of clinicopathological variables and MMR status of primary tumors on disease related mortality, with variables selected for inclusion in these models based on their significance at univariate analysis ($p < 0.05$), as well as their independence in relation to each other.

RESULTS

Clinicopathological features

From 133 cases, 93 were male (69.9%) and 40 (30.1%) were female. Mean age was 60.1 + 12.8 years old (mean + SD) with a median of 61 years old. Mean primary tumor size was 5.9 + 3.0

cm, with a median of 5.5 cm. Proximal tumors comprising those aroused in *cardia*, *fundus* and proximal *corpus* represented 12.8% of lesions, with the remaining 87.2% aroused in distal corpus, antral and prepyloric regions. Macroscopic types according to Borrmann classification were distributed as follows, type I: 12 (9.0%), type II: 27 (20.3%), type III: 69 (51.9%), type IV: 18 (13.5%) and type V: seven (5.3%). Mean size of primary tumors was 5.9 + 2.1 cm (mean + SD), with a median of 5.5 cm. According to the Lauren histological classification, 83 cases (62.4%) were intestinal-type and 49 (36.8%) were diffuse-type. At World Health Organization (WHO) classification, tubular/tubule-papillary carcinoma comprised 77 cases (57.9%), mucinous type occurred in eight cases (6.0%) and signet-ring cell carcinoma type was assigned to 44 cases (33.1%).

According to Ming classification, 103 cases (77.4%) showed an infiltrating pattern, whereas 30 (22.6%) were found expansive. Histological evaluation of infiltrating level of primary tumor showed that in 58 cases (43.6%) carcinoma compromised *muscularis propria*, 74 cases (55.6%) invaded to subserosa connective tissue and in 1 case (0.8%) adjacent structures were compromised. Intratumoral lymphoplasmacytic infiltrate was absent in 8 cases (6.0%), mild to moderate in 93 (69.9%) and intense in 32 cases (24.1%). Desmoplastic stromal response was evaluated as absent to mild in 62 cases (46.6%), moderate in 49 (36.8%) and intense in 22 cases (16.6%). Lymphatic invasion was detected in 67 cases (50.4%) and blood vessel invasion in 23 cases (17.3%). Perineural infiltration was detected in 70 cases (52.6%). Lymph node status determined by pathological TNM stratified cases as follows: pN0 in 42 cases (31.6%), pN1 in 63 (47.4%), pN2 in 26 (19.5%) and pN3 in 2 (1.5%). Pathological staging according to TNM showed the following frequencies: Stage IB: 41 cases (30.8%), Stage II: 59 (44.4%), Stage IIIA: 29 (21.8%), Stage IIIB: 2 (1.5%) and Stage IV: 2 (1.5%). Kaplan-Meier plots for the most significant clinico-pathological features at univariate analysis are demonstrated at Figure 1.

MMR status

Despite inherent TMA methodological issues (spot physical or representatives losses), 116 cases were found adequate for MLH1 evaluation (87.2%). Thirty-one gastric adenocarcinoma cases showed loss of MLH1 expression (26.7%).

The MLH1 expression

MLH1 negative tumors showed a larger size (6.9 + 3.3 cm vs 5.6 + 2.7, $p = 0.031$) than the other groups, were more commonly located at proximal stomach (35.5% vs 7.1%, $p < 0.001$) and featured a predominantly polypoid and/or fungating Borrmann's macroscopic types I and II (67.7% vs 18.8%, $p < 0.001$). Only four MLH1 negative tumors were classified as having diffuse/"signet-ring" cell morphology according to Lauren (12.9% vs 40.5%, $p = 0.005$) or WHO classification ($p = 0.009$). Ming's expansive type was more commonly seen among MLH1 negative tumors when compared to positive ones (38.7% vs 18.8%, $p = 0.027$). Most MLH1 negative tumors invaded only *muscularis propria* (67.7%), whereas most MLH1 positive tumors invaded subserosa (62.4%, $p = 0.011$). Inflammatory infiltrate showed a trend to be more commonly qualified as intense in MLH1 negative tumors (41.9% vs 21.2%, $p = 0.064$). Table 1 resumes all clinicopathological findings and MLH1 expression.

Survival analyses

Univariate survival analysis showed that increased gastric cancer related mortality was significantly related to male gender (LogRank:

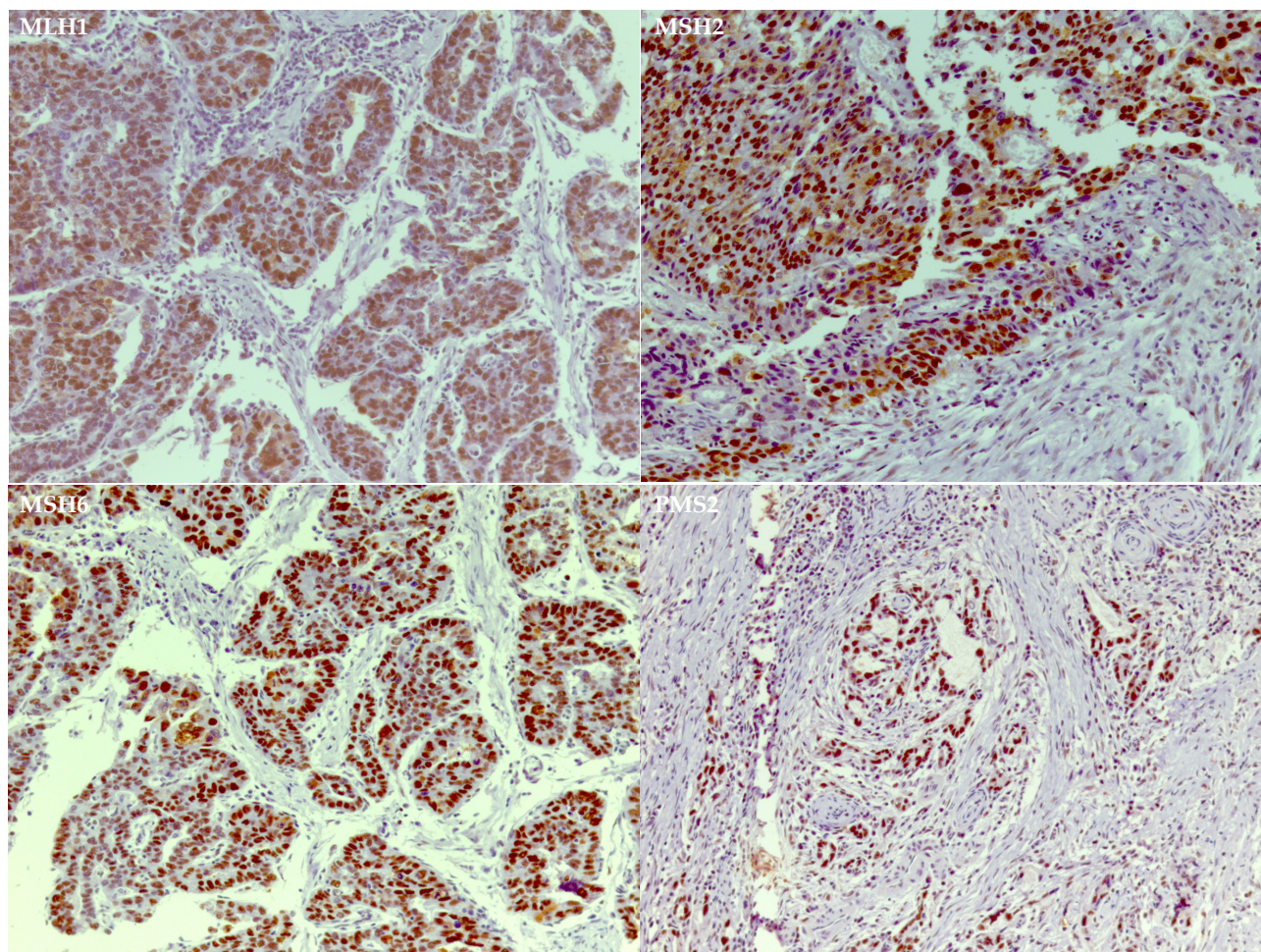


Figure 1 Kaplan-Meier plots for the most significant clinico-pathological features at univariate analysis (LogRank and p value in the inset).

5.11, $p = 0.024$), tumors greater than 5.5 cm (LogRank: 3.98, $p = 0.046$) and distally located (LogRank: 4.49, $p = 0.034$), tumors showing a macroscopic Borrmann types III, IV or V (LogRank: 4.75, $p = 0.029$). Patients harboring tumors with a “signet-ring” or mucinous morphology according to WHO classification (LogRank: 8.61, $p = 0.003$), diffuse morphology according to Lauren’s classification (LogRank: 11.62, $p = 0.003$) and perineural infiltration (LogRank: 12.62, $p < 0.001$) followed a worse prognosis. Presence of lymph node metastases (LogRank: 10.08, $p < 0.001$) and TNM stages II and IIIA/IV in relation to stage IB (LogRank: 21.92, $p < 0.001$) were also significantly related to poorer survival. Age, Ming’s histological type, deepest level of neoplastic infiltration on gastric wall, inflammatory infiltrate and lymphovascular or venous invasion was not statistically related to survival in univariate analyses. The most significant values were seen for patients having MLH1 positive tumors (LogRank: 5.46, $p = 0.019$).

Cox hazard model analyses

The most significant prognostic variables observed in univariate analyses (gender, Lauren histological classification, perineural infiltration and TNM stage) were included in multivariate Cox hazard proportions models. When MLH1 was included in the Cox model with the variables mentioned, positive tumors had only a marginal association with survival (HR = 2.58, $p = 0.053$), with Lauren diffuse histological type and pathological TNM stages IIIA and IV showing independent values on survival (HR = 2.18, $p = 0.032$; HR = 3.68, $p = 0.021$ and HR = 56.88, $p = 0.002$ respectively).

DISCUSSION

Our data highlighted the prominent role of MMR immunohistochemistry evaluation in the clinical scenario of gastric cancer outcome. At least one MSI enzyme was tested negative in the casuistic of gastric carcinoma. An important survival benefit was observed when simultaneous loss of MLH1 and PMS2 (data not shown) expression was observed. Most of the genetic aberrations in gastric cancer have been classified as due to MSI or to loss of heterozygosity (LOH) phenotypes, which are almost mutually exclusive pathways of carcinogenesis^[26-31]. Analysis of the length of PCR derived fragments of mono and/or dinucleotide markers has been used as the gold standard for genetic determination of MSI phenotype in gastric cancer as well as in neoplasms from other primary sites, mainly colorectal tumors, as a research or screening tool for patients with suspected familial cancer syndromes^[10,32,33]. Molecular classification of MSI phenotype, low frequency MSI and high frequency MSI was proved to stratify sporadic cases of gastric cancer into subsets with preferential clinicopathological features such as tumor location, age, histological type and grade, pathological staging and prognosis^[7,34-39]. More recently, immunohistochemistry has been successfully used to demonstrate defective mismatch repair enzyme (MMR) expression in cases with known MSI status, and is currently accepted as another gold standard methodology for MSI screening, mainly in colorectal and endometrial cancer^[11,34,40,41,42-49]. Nevertheless, data characterizing MMR enzymes expression in sporadic gastric cancer are still lacking in literature, and its

Table 1 Correlation between clinico-pathological variables and MLH1 status of primary tumors.

		MHL1		
		Negative (n, %)	Positive% (n, %)	P
Gender	Male	22 (71%)	59(70.2%)	G3G8:G35
	Female	9 (29%)	25 (29.8%)	0.939
Age	Mean +/- S.D.	62.1+15.1	60,06+11.9	0.446
Primary tumor location	Proximal (Cardia and Fundus)	11 (35.5%)	6 (7.1%)	< 0.001
	Distal (Corpus and Antrum)	20 (64.5%)	68 (92.9%)	
Borrmann type	I and II	21 (67.7%)	16 (19%)	< 0.001
	III, IV and V	10 (32.3%)	68 (81%)	
WHO histological type	Tubular/Tubulo-papillary adenocarcinoma	26 (83.9%)	44 (52.4%)	0.008
	Mucinous adenocarcinoma	2 (6.5%)	4 (4.8%)	
	"Signet-ring" cell carcinoma	2 (6.5%)	32 (38.1%)	
	Other	0	2 (2.4%)	
	Undifferentiated	0	2 (2.4%)	
Lauren histological type	Intestinal	27 (87.1%)	49 (59%)	0.007
	Difuse	4 (12.9%)	34 (41%)	
Ming histological type	Infiltrative	19 (61.3%)	69 (82.1%)	0.019
	Expansile	12 (38.7%)	15 (17.9%)	
Deepest infiltrative level	muscularis propria	21 (67.7%)	30 (36.1%)	0.01
	subserosa	10 (32.3%)	52 (62.6%)	
	adjacent structures	0	1 (1.2%)	
Inflammatory infiltrate	absent	2 (6.5%)	3 (3.6%)	0.043
	mild to moderate	16 (51.6%)	63 (75.9%)	
	accentuated	13 (41.9%)	17 (20.5%)	
Lymphatic invasion	not detected	16 (53.3%)	36 (43.9%)	0.4
	present	14 (46.7%)	46 (56.1%)	
Vascular invasion	not detected	24 (85.7%)	65 (78.3%)	0.396
	present	4 (14.3%)	18 (21.7%)	
Perineural infiltration	not detected	17 (56.7%)	34 (41.5%)	0.199
	present	13 (43.3%)	48 (58.5%)	
Lymph node status	no lymph node metastasis	10 (33.3%)	25 (29.8%)	0.187
	metastases in 1 to 6 (pN1)	18 (60%)	38 (45.2%)	
	metastases in 7 to 15 (pN2)	2 (6.7%)	20 (23.8%)	
	metastases in more than 15 (pN3)	0	1 (1.2%)	
Pathological TNM	Stage IB	10 (32.3%)	25 (29.8%)	0.285
	Stage II	18 (58.1%)	35 (41.7%)	
	Stage IIIA	3 (9.7%)	21 (25%)	
	Stage IIIB	0	1 (1.2%)	
	Stage IV	0	2 (2.4%)	

usefulness for the assessment of clinicopathological features, including prognosis, are yet infrequently explored^[16,21,34,50,51]. In this context, our data fully characterized the expression of a panel of MMR enzymes in a series of sporadic gastric cancer cases employing a well-controlled immunohistochemistry protocol according to recent recommendations in literature, including antigen retrieval techniques and avidin-biotin free visualization systems^[13,52]. In addition, correlations between the statuses of different MMRs related to clinicopathological features and prognosis were also explored.

Defective expression of at least one MMR enzyme was observed in 45 of 133 gastric cancer cases (33.6%), which is quite similar to the range of frequencies of microsatellite instability as determined by genetic approaches reported in literature^[52,53]. However, the present study is original on assessing the expression profiles of MMR in gastric cancer and on showing that negativity of MMR enzymes occurs more commonly in association; with only 15 out of 45 cases with some defective MMR enzymes showed only one lost marker

(33.3%). Moreover, 14 out of 45 (31.1%) and 7 out of 45 cases (15.5%) had three or all the four MMR enzymes tested negative, respectively.

Association between negative results for MMRs might rise a questioning whether technical issues, such as tissue preservation, problems with antigen retrieval or visualization system, could influence the false-negative results. Thus for, reviewing all cases with stringent criteria for interpretation of negativity^[13], validation of TMA negative results in large sections from each case and the already mentioned employment of a well-controlled and literature validated immunohistochemistry procedures^[49-52] fully corroborate our *in situ* findings.

Regarding association of immunohistochemical profile of MMR enzymes with clinical and pathological features, this study demonstrated that tumors located at cardia and fundus, predominantly polypoid and fungating macroscopic types (Borrmann's types I and II) and intestinal histological type according to Lauren classification

are associated with defective expression of MLH1 enzyme). Tubular and/or tubule-papillary histological phenotypes, the counterparts of intestinal type of Lauren's classification, were significantly associated to loss of expression of MLH1.

Other important clinicopathological features related to MMR negativity were the expansile Ming's histological type (MLH1, MSH2 and MSH6), tumoral infiltration restricted to *muscularis propria* (MLH1 and MSH2), absent perineural infiltration (MSH2, MSH6 and PMS2) and older patients at the time of diagnosis (PMS2). Heavy lymphocytic infiltration showed a trend to be associated with MLH1 and MSH6 loss of expression, as well as the absent pattern to mild desmoplastic stromal reaction (MSH6). These data not only represent a more comprehensive approach in relation to previously reported associations between MSI/MMR status and pathological features in gastric cancer, but also partially reproduce what is credited for colorectal cancer, strongly relating microsatellite phenotypes with more favorable pathological features affecting clinical outcome^[29,55-59]. Moreover, prognostic impact of MMR immunohistochemistry was demonstrated with univariate disease-specific survival analyses of primary tumor status for MLH1, MSH6 and PMS2. Our data are in accordance with those reported for tumors of other sites, which immunohistochemical determination of MMR protein statuses was demonstrated to be a sensible and specific alternative for molecular analysis for microsatellite status determination, providing meaningful biological information to stratify patients in groups portending tumors with different pathological features as well as clinical outcomes as in colorectal, ovarian, urothelial, biliary and germinative malignant neoplasms^[49,60-62]. Considering that mismatch-repair activity is functionally obtained through heterodimerization involving specific MMR enzymes in the so called MutS α (MLH1/PMS2) and MutL α (MSH2/MSH6) complexes^[63,64], we have also explored associations between MMR protein profile and clinicopathological features with survival, as well as. The concurrent loss of expression of MLH1 and PMS2 resumed all associations reported with clinicopathological features when the analysis was undertaken for each isolated MMR enzyme. Moreover, Cox multivariate survival analyzes showed that concurrent loss of MLH1 and PMS2 was a significant and independent prognostic factor of improved survival, a fact revealed only when the two enzymes were analyzed in combination. The concurrent loss of expression of the pair MSH2/MSH6 was also related to clinicopathological features of better prognosis, but this pair was not found an independent prognostic factor in Cox multivariate models. Although MSI frequency in gastric cancer varies widely depending on studied group, from 7.1% in American patients of European descent up to 76% of intestinal phenotype gastric cancer in selected oriental populations^[54,64,65], it is well known that microsatellite unstable phenotype is characterized by scattered genomic frame shift mutations at mono and/or dinucleotide repeats. Additionally, it is well characterized that increasing frequencies of microsatellite instability occur along progression through gastritis, metaplasia, dysplasia and neoplasia sequence^[11,67,68] firstly stated by Correa^[69], and is mechanistically explained by progressive loss of MLH1 and/or MSH2 protein expression mainly due to epigenetic silencing of gene expression secondary to CpG island methylation in the sporadic setting^[32,70-72]. The better prognosis determinate by microsatellite analysis, unstable phenotype in gastric carcinomas has been reported^[7,16,50] and reproduced at the immunohistochemical level in the present study, thus supporting the notion of an independent carcinogenic pathway^[73], the resulting alterations in selected molecular pathways responsible for these are just recently being characterized^[74]. However, as anticipated, the prognostic value of

MSI still remains controversial; although, the pathologic TNM stage and MSI status have been continuously recognized as an independent prognostic factor for overall survival after curative surgery^[75]. Frame shift mutations in repeating mono and/or dinucleotide sequences occurring in MSI phenotype were described in genes involved in different homeostatic molecular pathways, mainly those involved in cell proliferation and apoptosis, as well as inactivation of growth control imposed by TGF β /TGF β RII pathway^[34], and can explain the distinctive clinicopathological features and the better prognosis of our series of immunohistochemically detected MSI gastric cancers.

Recently, it was demonstrate an inverse association between the expression of the mismatch repair gene MLH1 and that of the base excision repair (BER) gene DNA polymerase β , which provided evidences that exist a crosstalk between MLH1 and Pol β that modulates the response to alkylation damage. This is important because Pol β /MLH1 can be considered for planning chemotherapeutic approaches for gastric cancer treatment.

In conclusion, in the present study, we characterized the expression profile of a panel of the four main MMR enzymes in a series of gastric carcinomas, employing properly standardized immunohistochemical detection of these antigens as a tool to detect cases presenting certain clinicopathological features. In addition, a survival benefit from MMR loss of expression was demonstrated, mainly when analysis was undertaken considering simultaneous loss of MLH1 and PMS2. These results taken together validate the biological significance of in situ immunohistochemical detection of MMR enzymes as a low cost and widespread available method to identify certain features and to assess prognosis in gastric cancer.

REFERENCES

1. de Martel C, Forman D, Plummer M. Gastric cancer: epidemiology and risk factors. *Gastroenterol Clin North Am.* 2013 Jun; **42**(2): 219-40. [PMID: 23639638]; [DOI: 10.1016/j.gtc.2013.01.003]
2. Goss PE, Lee BL, Badovinac-Crnjevic T, Strasser-Weippl K, Chavarri-Guerra Y, St Louis J, Villarreal-Garza C, Unger-Saldaña K, Ferreyra M, Debiasi M, Liedke PE, Touya D, Werutsky G, Higgins M, Fan L, Vasconcelos C, Cazap E, Vallejos C, Mohar A, Knaul F, Arreola H, Batura R, Luciani S, Sullivan R, Finkelstein D, Simon S, Barrios C, Kightlinger R, Gelrud A, Bychkovsky V, Lopes G, Stefani S, Blaya M, Souza FH, Santos FS, Kaemmerer A, de Azambuja E, Zorilla AF, Murillo R, Jeronimo J, Tsu V, Carvalho A, Gil CF, Sternberg C, Dueñas-Gonzalez A, Sgroi D, Cuello M, Fresco R, Reis RM, Maserá G, Gabús R, Ribeiro R, Knust R, Ismael G, Rosenblatt E, Roth B, Villa L, Solares AL, Leon MX, Torres-Vigil I, Covarrubias-Gomez A, Hernández A, Bertolino M, Schwartzmann G, Santillana S, Esteva F, Fein L, Mano M, Gomez H, Hurlbert M, Durstine A, Azenha G. Planning cancer control in Latin America and the Caribbean. *Lancet Oncol.* 2013; **14**: 391-436. [PMID: 23628188]; [DOI: 10.1016/S1470-2045(13)70048-2]
3. Siegel RL, Miller KD, Jemal A. Cancer statistics, 2016. *CA Cancer J Clin.* 2016; **66**: 7-30. [PMID: 26742998]; [DOI: 10.3322/caac.21332]
4. Lei Z, Tan IB, Das K, Deng N, Zouridis H, Pattison S, Chua C, Feng Z, Guan YK, Ooi CH, Ivanova T, Zhang S, Lee M, Wu J, Ngo A, Manesh S, Tan E, Teh BT, So JB, Goh LK, Boussioutas A, Lim TK, Flotow H, Tan P, Rozen SG. Identification of molecular subtypes of gastric cancer with different responses to PI3-kinase inhibitors and 5-fluorouracil. *Gastroenterology.* 2013; **145**: 554-65. [PMID: 23684942]; [DOI: 10.1053/j.gastro.2013.05.010]
5. Wong H, Yau T. Molecular targeted therapies in advanced gastric cancer: does tumor histology matter? *Therap Adv Gastroenterol.*

- 2013; **6**: 15-31.
6. Nagini S. Carcinoma of the stomach: A review of epidemiology, pathogenesis, molecular genetics and chemoprevention. *World J Gastrointest Oncol.* 2012; **4**: 156-69. [PMID: 22844547]; [PMCID: PMC3406280]; [DOI: 10.4251/wjgo.v4.i7.156]
 7. Velho S, Fernandes MS, Leite M, Figueiredo C, Seruca R. Causes and consequences of microsatellite instability in gastric carcinogenesis. *World J Gastroenterol* 2014; **20**: 16433-16442. [PMID: 25469011]; [PMCID: PMC4248186]; [DOI: 10.3748/wjg.v20.i44.16433]
 8. Beghelli S, de Manzoni G, Barbi S, Tomezzoli A, Roviello F, Di Gregorio C, Vindigni C, Bortesi L, Parisi A, Saragoni L, Scarpa A, Moore PS. Microsatellite instability in gastric cancer is associated with better prognosis in only stage II cancers. *Surgery* 2006; **139**: 347-356. [PMID: 16546499]; [DOI: 10.1016/j.surg.2005.08.021]
 9. Williams AS, Huang WY. The analysis of microsatellite instability in extracolonic gastrointestinal malignancy. *Pathology.* 2013; **45**: 540-52. [PMID: 24018804]; [DOI: 10.1097/PAT.0b013e3283653307]
 10. Vilar E, Gruber SB. Microsatellite instability in colorectal cancer—the stable evidence. *Nat Rev Clin Oncol* 2010; **7**: 153-162. [PMID: 20142816]; [PMCID: PMC3427139]; [DOI: 10.1038/nrclinonc.2009.237]
 11. Cancer Genome Atlas Research Network. Comprehensive molecular characterization of gastric adenocarcinoma. *Nature.* 2014; **513**: 202-9. [PMID: 25079317]; [PMCID: PMC4170219]; [DOI: 10.1038/nature13480]
 12. Stoffel EM, Mangu PB, Gruber SB, Hamilton SR, Kalady MF, Lau MW, Lu KH, Roach N, Limburg PJ; American Society of Clinical Oncology; European Society of Clinical Oncology. Hereditary colorectal cancer syndromes: American Society of Clinical Oncology Clinical Practice Guideline endorsement of the familial risk-colorectal cancer: European Society for Medical Oncology Clinical Practice Guidelines. *J Clin Oncol.* 2015; **33**: 209-17. [PMID: 25452455]; [PMCID: PMC5321096]; [DOI: 10.1200/JCO.2014.58.1322]
 13. Gerykova-Bujalkova M, Krivulcik T, Bartosova Z. Novel approaches in evaluation of pathogenicity of single-base exonic germline changes involving the mismatch repair genes MLH1 and MSH2 in diagnostics of Lynch syndrome. *Neoplasma.* 2008; **55**: 463-71. [PMID: 18999873]
 14. Moghbeli M, Moaven O, Memar B, Raziei HR, Aarabi A, Dadkhah E, Forghanifard MM, Manzari F, Abbaszadegan MR. Role of hMLH1 and E-cadherin promoter methylation in gastric cancer progression. *J Gastrointest Cancer.* 2014; **45**: 40-7. [PMID: 24022108]; [DOI: 10.1007/s12029-013-9548-9]
 15. Hansen TP, Nielsen O, Fenger C. Optimization of antibodies for detection of the mismatch repair proteins MLH1, MSH2, MSH6, and PMS2 using a biotin-free visualization system. *Appl Immunohistochem Mol Morphol* 2006; **14**: 115-121. [PMID: 16540742]; [DOI: 10.1097/01.pai.0000145183.75706.a2]
 16. Velho S, Fernandes MS, Leite M, Figueiredo C, Seruca R. Causes and consequences of microsatellite instability in gastric carcinogenesis. *World J Gastroenterol.* 2014 Nov 28; **20**: 16433-42. [PMID: 25469011]; [PMCID: PMC4248186]; [DOI: 10.3748/wjg.v20.i44.16433]
 17. Jacob CE, Gama-Rodrigues J, Bresciani CJ, Zilberstein B, Proscurshim I, Iriya K, Alves VA, Ceconello I. Trends in tumor location in gastric carcinoma over a 28-year period. *Hepatogastroenterology.* 2007 Jun; **54**: 1297-301. [PMID: 17629093]
 18. Bosman, F.T., Carneiro, F., Hruban, R.H., Theise, N.D., WHO Classification of Tumours of the Digestive System, Fourth Edition, WHO Classification of Tumours, Volume 3, IARC WHO Classification of Tumours, No 3, Lyon, France, 2010.
 19. Lauren T. The two histologic main types of gastric carcinoma. *Acta Pathol Microbiol Scand* 1962; **64**: 34.
 20. Ming SC Gastric carcinoma. A pathobiological classification *Cancer* 1977; **39**: 2475-2485. [PMID: 872047]
 21. Bormann R. Geshwulste des Magens und Duodenums in Handbuch der Speziellen Pathologischen Anatomie und Histologie. Springer-Verlag, Berlin 1926.
 22. Martinho O, Simões K, Longatto-Filho A, Jacob CE, Zilberstein B, Bresciani C, Gama-Rodrigues J, Ceconello I, Alves V, Reis RM. Absence of RKIP expression is an independent prognostic biomarker for gastric cancer patients. *Oncol Rep.* 2013; **29**: 690-6. [PMID: 23232914]; [DOI: 10.3892/or.2012.2179]
 23. Ilyas MI, Grabsch H, Ellis IO, Womack C, Brown R, Berney D, Fennell D, Salto-Tellez M, Jenkins M, Landberg G, Byers R, Treanor D, Harrison D, Green AR, Ball G, Hamilton P; National Cancer Research Institute (UK) Biomarker and Imaging Clinical Studies Group. Guidelines and considerations for conducting experiments using tissue microarrays. *Histopathology.* 2013; **62**: 827-39. [PMID: 23672312]; [DOI: 10.1111/his.12118]
 24. Pinder SE, Brown JP, Gillett C, et al. Translational Subgroup of the NCR Breast Clinical Studies Group. The manufacture and assessment of tissue microarrays: suggestions and criteria for analysis, with breast cancer as an example. *J Clin Pathol.* 2013; **66**: 169-77. [PMID: 23087330]; [DOI: 10.1136/jclinpath-2012-201091]
 25. Hewitt SM. Tissue microarrays as a tool in the discovery and validation of predictive biomarkers. *Methods Mol Biol.* 2012; **823**: 201-14. [PMID: 22081347]; [DOI: 10.1007/978-1-60327-216-2_13]
 26. Dolled-Filhart MP, Gustavson MD. Tissue microarrays and quantitative tissue-based image analysis as a tool for oncology biomarker and diagnostic development. *Expert Opin Med Diagn.* 2012; **6**: 569-83. [PMID: 23480838]; [DOI: 10.1517/17530059.2012.708336]
 27. Kallioniemi OP, Kononen J, Sauter G. Introducing tissue microarrays to molecular pathology. *Clin Chem.* 2012; **58**: 1717-8.
 28. Pilla D, Bosisio FM, Marotta R. Tissue microarray design and construction for scientific, industrial and diagnostic use. *J Pathol Inform.* 2012; **3**: 42. [PMID: 23372983]; [PMCID: PMC3551499]; [DOI: 10.4103/2153-3539.104904]
 29. Yoon KI, Lee S, Han TS, Moon SY, Yun SM, Kong SH, Jho S, Choe J, Yu J, Lee HJ, Park JH, Kim HM, Lee SY, Park J, Kim WH, Bhak J, Yang HK, Kim SJ. Comprehensive genome- and transcriptome-wide analyses of mutations associated with microsatellite instability in Korean gastric cancers. *Genome Res.* 2013; **23**: 1109-17. [PMID: 23737375]; [PMCID: PMC3698504]; [DOI: 10.1101/gr.145706.112]
 30. Arai T, Sakurai U, Sawabe M. Frequent microsatellite instability in papillary and solid-type, poorly differentiated adenocarcinomas of the stomach. *Gastric Cancer.* 2013; **16**: 505-12. [PMID: 23274922]; [DOI: 10.1007/s10120-012-0226-6]
 31. Kim KJ1, Lee TH, Cho NY, Yang HK, Kim WH, Kang GH. Differential clinicopathologic features in microsatellite-unstable gastric cancers with and without MLH1 methylation. *Hum Pathol.* 2013; **44**: 1055-64. [PMID: 23266441]; [DOI: 10.1016/j.humphath.2012.09.009]
 32. Hiyaama T1, Tanaka S, Yoshihara M, Sasao S, Kose K, Shima H, Tuncel H, Ueno Y, Ito M, Kitada Y, Yasui W, Haruma K, Chayama K. Chromosomal and microsatellite instability in sporadic gastric cancer. *J Gastroenterol Hepatol* 2004; **19**: 756-760. [PMID: 15209621]; [DOI: 10.1111/j.1440-1746.2004.03369.x]
 33. Kim KM1, Kwon MS, Hong SJ, Min KO, Seo EJ, Lee KY, Choi SW, Rhyu MG. Genetic classification of intestinal-type and diffuse-type gastric cancers based on chromosomal loss and microsatellite instability. *Virchows Arch* 2003; **443**: 491-500. [PMID: 12920592]; [DOI: 10.1007/s00428-003-0840-0]
 34. Lin X, Zhao Y, Song WM, Zhang B. Molecular classification and

- prediction in gastric cancer. *Comput Struct Biotechnol J*. 2015; **13**: 448-58. [PMID: 26380657]; [PMCID: PMC4556804]; [DOI: 10.1016/j.csbj.2015.08.001]
35. Sunakawa Y, Lenz HJ. Molecular classification of gastric adenocarcinoma: translating new insights from the cancer genome atlas research network. *Curr Treat Options Oncol*. 2015; **16**: 17. [PMID: 25813036]; [DOI: 10.1007/s11864-015-0331-y]
 36. Musulén E, Moreno V, Reyes G, Sancho FJ, Peinado MA, Esteller M, Herman JG, Combalia N, Rey M, Capellá G. Standardized approach for microsatellite instability detection in gastric carcinomas. *Hum Pathol*. 2004; **35**: 335-42. [PMID: 15017590]
 37. Falchetti M, Saieva C, Lupi R, Masala G, Rizzolo P, Zanna I, Ceccarelli K, Sera F, Mariani-Costantini R, Nesi G, Palli D, Ottini L. Gastric cancer with high-level microsatellite instability: target gene mutations, clinicopathologic features, and long-term survival. *Hum Pathol*. 2008; **39**: 925-32. [PMID: 18440592]; [DOI: 10.1016/j.humpath.2007.10.024]
 38. Hasuo T, Semba S, Li D, Omori Y, Shirasaka D, Aoyama N, Yokozaki H. Assessment of microsatellite instability status for the prediction of metachronous recurrence after initial endoscopic submucosal dissection for early gastric cancer. *Br J Cancer* 2007; **96**: 89-94. [PMID: 17179982]; [PMCID: PMC2360225]; [DOI: 10.1038/sj.bjc.6603532]
 39. Simpson AJ, Caballero OL, Pena SD. Microsatellite instability as a tool for the classification of gastric cancer. *Trends Mol Med* 2001; **7**: 76-80.
 40. Wirtz HC1, Müller W, Noguchi T, Scheven M, Rüschoff J, Hommel G, Gabbert HE. Prognostic value and clinicopathological profile of microsatellite instability in gastric cancer. *Clin Cancer Res* 1998; **4**: 1749-1754. [PMID: 9676851]
 41. Ottini L, Palli D, Falchetti M, D'Amico C, Amorosi A, Saieva C, Calzolari A, Cimoli F, Tatarelli C, De Marchis L, Masala G, Mariani-Costantini R, Cama A. Microsatellite instability in gastric cancer is associated with tumor location and family history in a high-risk population from Tuscany. *Cancer Res* 1997; **57**: 4523-4529. [PMID: 9377564]
 42. Lin JT, Wu MS, Shun CT, Lee WJ, Wang JT, Wang TH, Sheu JC. Microsatellite instability in gastric carcinoma with special references to histopathology and cancer stages. *Eur J Cancer* 1995; **31A**: 1879-1882. [PMID: 8541117]
 43. Kang YH, Bae SI, Kim WH. Comprehensive analysis of promoter methylation and altered expression of hMLH1 in gastric cancer cell lines with microsatellite instability. *J Cancer Res Clin Oncol* 2002; **128**: 119-124. [PMID: 11935297]; [DOI: 10.1007/s00432-001-0296-z]
 44. Yao Y1, Tao H, Kim JJ, Burkhead B, Carloni E, Gasbarrini A, Sepulveda AR. Alterations of DNA mismatch repair proteins and microsatellite instability levels in gastric cancer cell lines. *Lab Invest* 2004; **84**: 915-922. [PMID: 15133479]; [DOI: 10.1038/labinvest.3700117]
 45. Fogt F1, Zimmerman RL, Poremba C, Noffsinger AE, Alsaigh N, Rueschoff J. Immunohistochemical screening of mismatch repair genes hMLH1, hMSH2, and hMSH6 in dysplastic lesions of the colon. *Appl Immunohistochem Mol Morphol* 2002; **10**: 57-61. [PMID: 11893037]
 46. Geisler JP1, Geisler HE, Miller GA, Wiemann MC, Zhou Z, Crabtree W. Immunohistochemical staining of the mismatch repair gene, hMSH2, and survival in patients with ovarian carcinoma. *Eur J Gynaecol Oncol* 2000; **21**: 237-240. [PMID: 10949383]
 47. Hameed F1, Goldberg PA, Hall P, Algar U, van Wijk R, Ramesar R. Immunohistochemistry detects mismatch repair gene defects in colorectal cancer. *Colorectal Dis* 2006; **8**: 411-417. [PMID: 16684085]; [DOI: 10.1111/j.1463-1318.2006.00956.x]
 48. Kassem HS, Varley JM, Hamam SM, Margison GP. Immunohistochemical analysis of expression and allelotype of mismatch repair genes (hMLH1 and hMSH2) in bladder cancer. *Br J Cancer* 2001; **84**: 321-328. [PMID: 11161395]; [PMCID: PMC2363732]; [DOI: 10.1054/bjoc.2000.1595]
 49. Stoehr C1, Burger M, Stoehr R, Bertz S, Ruemmele P, Hofstaedter F, Denzinger S, Wieland WF, Hartmann A, Walter B. Mismatch repair proteins hMLH1 and hMSH2 are differently expressed in the three main subtypes of sporadic renal cell carcinoma. *Pathobiology*. 2012; **79**: 162-8. [PMID: 22378480]; [DOI: 10.1159/000335642]
 50. González L1, Ortiz AP, Suárez EL, Umpierre S, Billoch J, Marcos MJ, Joy L, Charneco E, Lacourt MY, Bernabe-Dones RD, Cruz-Correa MR. Case-case study of factors associated to hMLH1, hMSH2, and hMSH6 protein expression among endometrial cancer patients of the University District Hospital of San Juan, Puerto Rico. *Int J Gynecol Cancer* 2012; **22**: 826-9. [PMID: 22635031]; [PMCID: PMC3482400]; [DOI: 10.1097/IGC.0b013e31825104de]
 51. Truninger K1, Menigatti M, Luz J, Russell A, Haider R, Gebbers JO, Bannwart F, Yurtsever H, Neuweiler J, Riehle HM, Cattaruzza MS, Heinimann K, Schär P, Jiricny J, Marra G. Immunohistochemical analysis reveals high frequency of PMS2 defects in colorectal cancer. *Gastroenterology* 2005; **128**: 1160-1171. [PMID: 15887099]
 52. Valentini AM, Armentano R, Pirrelli M, Gentile M, Caruso ML. Immunohistochemical mismatch repair proteins expression in colorectal cancer. *Appl Immunohistochem Mol Morphol* 2006; **14**: 42-45. [PMID: 16540729]; [DOI: 10.1097/01.pai.0000155193.92167.6a]
 53. Grogg KL, Lohse CM, Pankratz VS, Halling KC, Smyrk TC. Lymphocyte-rich gastric cancer: associations with Epstein-Barr virus, microsatellite instability, histology, and survival. *Mod Pathol* 2003; **16**: 641-651. [PMID: 12861059]; [DOI: 10.1097/01.MP.0000076980.73826.C0]
 54. Kim JY1, Shin NR, Kim A, Lee HJ, Park WY, Kim JY, Lee CH, Huh GY, Park DY. Microsatellite instability status in gastric cancer: a reappraisal of its clinical significance and relationship with mucin phenotypes. *Korean J Pathol* 2013; **47**: 28-35. [PMID: 23483099]; [PMCID: PMC3589606]; [DOI: 10.4132/KoreanJPathol.2013.47.1.28]
 55. Manavis J, Gilham P, Davies R, Ruszkiewicz A. The immunohistochemical detection of mismatch repair gene proteins (MLH1, MSH2, MSH6, and PMS2): practical aspects in antigen retrieval and biotin blocking protocols. *Appl Immunohistochem Mol Morphol* 2003; **11**: 73-77. [PMID: 12610360]
 56. Perez RO, Jacob CE, D'Ottaviano FL, et al. Microsatellite instability in solitary and sporadic gastric cancer. *Clinics* 2004; **59**: 279-285.
 57. Theuer CP1, Campbell BS, Peel DJ, Lin F, Carpenter P, Ziogas A, Butler JA. Microsatellite instability in Japanese vs European American patients with gastric cancer. *Arch Surg* 2002; **137**: 960-965. [PMID: 12146999]
 58. Benatti P1, Gafà R, Barana D, Marino M, Scarselli A, Pedroni M, Maestri I, Guerzoni L, Roncucci L, Menigatti M, Roncari B, Maffei S, Rossi G, Ponti G, Santini A, Losi L, Di Gregorio C, Oliani C, Ponz de Leon M, Lanza G. Microsatellite instability and colorectal cancer prognosis. *Clin Cancer Res* 2005; **11**: 8332-8340. [PMID: 16322293]; [DOI: 10.1158/1078-0432.CCR-05-1030]
 59. Lanza G1, Gafà R, Santini A, Maestri I, Guerzoni L, Cavazzini L. Immunohistochemical test for MLH1 and MSH2 expression predicts clinical outcome in stage II and III colorectal cancer patients. *J Clin Oncol* 2006; **24**: 2359-2367. [PMID: 16710035]; [DOI: 10.1200/JCO.2005.03.2433]
 60. Parc Y1, Gueroult S, Mourra N, Serfaty L, Fléjou JF, Tiret E, Parc R. Prognostic significance of microsatellite instability determined by immunohistochemical staining of MSH2 and MLH1 in sporadic T3N0M0 colon cancer. *Gut* 2004; **53**: 371-375. [PMID: 14960518]; [PMCID: PMC1773950]
 61. Popat S, Hubner R, Houlston RS. Systematic review of microsatellite instability and colorectal cancer prognosis. *J Clin*

- Oncol* 2005; **23**: 609-618. [PMID: 15659508]; [DOI: 10.1200/JCO.2005.01.086]
62. Smyth EF, Sharma A, Sivarajasingham N, Hartley J, Monson JR, Cawkwell L. Prognostic implications of hMLH1 and p53 immunohistochemical status in right-sided colon cancer. *Dis Colon Rectum* 2004; **47**: 2086-2091. [PMID: 15657659]; [DOI: 10.1007/s10350-004-0710-0]
 63. Liengswangwong U, Karalak A, Morishita Y, Noguchi M, Khuhaprema T, Srivatanakul P, Miwa M. Immunohistochemical expression of mismatch repair genes: a screening tool for predicting mutator phenotype in liver fluke infection-associated intrahepatic cholangiocarcinoma. *World J Gastroenterol* 2006; **12**: 3740-3745. [PMID: 16773692]; [PMCID: PMC4087468]
 64. Rosen DG, Cai KQ, Luthra R, Liu J. Immunohistochemical staining of hMLH1 and hMSH2 reflects microsatellite instability status in ovarian carcinoma. *Mod Pathol* 2006; **19**: 1414-1420. [PMID: 16941012]; [DOI: 10.1038/modpathol.3800672]
 65. Sinicrope FA1, Rego RL, Foster N, Sargent DJ, Windschitl HE, Burgart LJ, Witzig TE, Thibodeau SN. Microsatellite instability accounts for tumor site-related differences in clinicopathologic variables and prognosis in human colon cancers. *Am J Gastroenterol* 2006; **101**: 2818-2825. [PMID: 17026563]; [DOI: 10.1111/j.1572-0241.2006.00845.x]
 66. Halvarsson B, Lindblom A, Rambech E, Lagerstedt K, Nilbert M. The added value of PMS2 immunostaining in the diagnosis of hereditary nonpolyposis colorectal cancer. *Fam Cancer* 2006; **5**: 353-358. [PMID: 16817031]; [DOI: 10.1007/s10689-006-0005-9]
 67. Kolodner RD, Marsischky GT. Eukaryotic DNA mismatch repair. *Curr Opin Genet Dev* 1999; **9**: 89-96. [PMID: 10072354]
 68. Choe WH, Lee SY, Lee JH, Shim SG, Kim YH, Rhee PL, Rhee JC, Ki CS, Kim JW, Song SY, Kim JJ. High frequency of microsatellite instability in intestinal-type gastric cancer in Korean patients. *Korean J Intern Med* 2005; **20**: 116-122. [PMID: 16134765]; [PMCID: PMC3891379]
 69. Sepulveda AR, Santos AC, Yamaoka Y, Wu L, Gutierrez O, Kim JG, Graham DY. Marked differences in the frequency of microsatellite instability in gastric cancer from different countries. *Am J Gastroenterol* 1999; **94**: 3034-3038. [PMID: 10520865]; [DOI: 10.1111/j.1572-0241.1999.01453.x]
 70. Leung WK, Kim JJ, Kim JG, Graham DY, Sepulveda AR. Microsatellite instability in gastric intestinal metaplasia in patients with and without gastric cancer. *Am J Pathol* 2000; **156**: 537-543. [PMID: 10666383]; [PMCID: PMC1850057]; [DOI: 10.1016/S0002-9440(10)64758-X]
 71. Ling XL, Fang DC, Wang RQ, Yang SM, Fang L. Mitochondrial microsatellite instability in gastric cancer and its precancerous lesions. *World J Gastroenterol* 2004; **10**: 800-803. [PMID: 15040020]; [PMCID: PMC4727000]
 72. Correa P. Precursors of gastric and esophageal cancer. *Cancer* 1982; **50**: 2554-2565. [PMID: 7139550]
 73. Fleisher AS1, Esteller M, Wang S, Tamura G, Suzuki H, Yin J, Zou TT, Abraham JM, Kong D, Smolinski KN, Shi YQ, Rhyu MG, Powell SM, James SP, Wilson KT, Herman JG, Meltzer SJ. Hypermethylation of the hMLH1 gene promoter in human gastric cancers with microsatellite instability. *Cancer Res* 1999; **59**: 1090-1095. [PMID: 10070967]
 74. Leung SY, Yuen ST, Chung LP, Chu KM, Chan AS, Ho JC. hMLH1 promoter methylation and lack of hMLH1 expression in sporadic gastric carcinomas with high-frequency microsatellite instability. *Cancer Res* 1999; **59**: 159-164. [PMID: 9892201]
 75. Wu CW, Chen GD, Jiang KC, Li AF, Chi CW, Lo SS, Chen JY. A genome-wide study of microsatellite instability in advanced gastric carcinoma. *Cancer* 2001; **92**: 92-101. [PMID: 11443614]
 76. Duval A, Hamelin R. Mutations at coding repeat sequences in mismatch repair-deficient human cancers: toward a new concept of target genes for instability. *Cancer Res* 2002; **62**: 2447-2454. [PMID: 11980631]
 77. Duval A, Reperant M, Compoin A, Seruca R, Ranzani GN, Iacopetta B, Hamelin R. Target gene mutation profile differs between gastrointestinal and endometrial tumors with mismatch repair deficiency. *Cancer Res* 2002; **62**: 1609-1612. [PMID: 11912129]
 78. Fang WL1, Chang SC, Lan YT, Huang KH, Chen JH, Lo SS, Hsieh MC, Li AF, Wu CW, Chiou SH. Microsatellite instability is associated with a better prognosis for gastric cancer patients after curative surgery. *World J Surg* 2012; **36**: 2131-8. [PMID: 22669398]; [DOI: 10.1007/s00268-012-1652-7]
 79. Simonelli V, Leuzzi G, Basile G, D'Errico M, Fortini P, Franchitto A, Viti V, Brown AR, Parlanti E, Pascucci B, Palli D, Giuliani A, Palombo F, Sobol RW, Dogliotti E. Crosstalk between mismatch repair and base excision repair in human gastric cancer. *Oncotarget*. 2016 Jun 20; **8(49)**: 84827-84840. [PMID: 29156686]; [PMCID: PMC5689576]; [DOI: 10.18632/oncotarget.10185]