

## Prospective Evaluation of Mucosal Changes in the Small Bowel by Capsule Endoscopy in Patients with Crohn's Disease Treated with Infliximab and Adalimumab

Ladislav Kuzela, Marian Oltman, Jarolim Sutka, Barbora Zacharova, Peter Paulen, Beata Repakova, Miroslava Rajska

Ladislav Kuzela, Marian Oltman, Jarolim Sutka, Barbora Zacharova, Peter Paulen, Beata Repakova, Miroslava Rajska, Gastroentero-Hepatic center Thallion, Tomasikova 50/C, 831 04 Bratislava, Slovakia

Correspondence to: Ladislav Kuzela, MD, PhD, Gastroentero-Hepatic center Thallion, Tomasikova 50/C, 831 04 Bratislava, Slovakia. [kuzela@thalion.sk](mailto:kuzela@thalion.sk)

Telephone: +424-2-57108511 Fax: +421-2-57108520

Received: June 4, 2012 Revised: August 22, 2012

Accepted: August 26, 2012

Published online: November 21, 2012

**Key words:** Crohn's disease; Mucosal healing; Capsule endoscopy; Infliximab; Adalimumab

Kuzela L, Oltman M, Sutka J, Zacharova B, Paulen P, Repakova B, Rajska M. Prospective Evaluation of Mucosal Changes in the Small Bowel by Capsule Endoscopy in Patients with Crohn's Disease Treated with Infliximab and Adalimumab. *Journal of Gastroenterology and Hepatology Research* 2012; 1(10): 274-279 Available from: URL: <http://www.ghrnet.org/index./joghr/>

### ABSTRACT

**AIM:** The aim of the proposed study was to evaluate mucosal lesions in the small bowel by means of capsule endoscopy (CE) in patients with Crohn's disease (CD) before administration of infliximab (IFX) or adalimumab (ADA) and following maintenance treatment. Secondary endpoint was to assess the tolerance of CE by the patient, possible adverse events and also the diagnostic efficacy in patients with CD.

**METHODS:** The group of 50 patients with CD treated with IFX ( $n=25$ ) or ADA ( $n=25$ ), were prospectively monitored. CE using was performed in each patient before the treatment and after one year of maintenance treatment.

**RESULTS:** 42 patients concluded the study. In ADA treated patients ( $n=23$ ) after one year we observed changes in CE from conclusive to normal in 2 patients, in 1 patient impairment from inconclusive to conclusive. All the other patients remained their findings without change. In IFX treated patients ( $n=19$ ) after one year we have observed changes from conclusive to normal in 2 patients. All the other patients remained their findings without change.

**CONCLUSION:** Despite the fact that we have not observed statistical significant effect of ADA or IFX treatment on small bowel MH, we have noticed improvement by means of drop in CDAI after 1 year maintenance treatment. CE could be helpful in selecting the right patient with mucosal lesions in terms of achievement of best clinical results for the biological treatment.

### INTRODUCTION

Crohn's disease (CD) is characterized by a transmural, often granulomatous TH1 inflammatory process that can affect any part of the gastrointestinal (GI) tract, but often involves the small bowel (SB), colon or both<sup>[1]</sup>. Due to the nature of CD, the disease is characterized by the presence of extensive areas of ulceration in GI tract. These ulcerations are the origin of fistulas, of translocation of microbes and can lead to toxic megacolon, to perforation and bleeding. These complications are the main indications for resection of the diseased bowel. Surgery however, does not stop the progression of the disease. It seems, therefore, logical that effective treatment of IBD should imply thoroughly and, if possible, complete healing of bowel ulcerations in parallel with clinical remission<sup>[2]</sup>. It is known from older studies that the SB seemed to be affected by inflammatory changes in up to 30% of cases. These studies were mainly based on radiological data<sup>[3]</sup>. In 2000, Iddan *et al* first described the capsule endoscopy (CE) and the first clinical application in patients with SB bleeding<sup>[4]</sup>. CE may also reveal various lesions in the SB characteristic of CD such as erythema, aphthous or large ulcerations, or even fistulas and may be also useful in patients with established IBD to evaluate obscure GI bleeding, the extent of the disease and the response to anti-inflammatory treatment and to better classify patients with indeterminate colitis<sup>[5,6]</sup>. Voderholzer *et al* showed that SB involvement in CD occurs much more frequently than is commonly considered and based on CE data, they suggested SB involvement in approximately 60% of patients with prediagnosed CD<sup>[7]</sup>.

For decades, the goal of CD management with traditional therapy has been the induction and maintenance of remission and the

control of disease-related symptoms. The goals of management have since evolved and therefore a clinician must consider many factors when choosing a specific therapy for a patient with CD. This has become possible with the introduction of biologic agents<sup>[8]</sup>. Due to the recently published data, some authors believe that it is time to change the goals for the treatment of CD as listed below: Induction and maintenance of remission without steroids; Complete healing of the intestinal and colonic mucosa; Avoidance of complications and surgeries; Avoidance of cancer and Avoidance of mortality<sup>[2]</sup>. Emerging data also suggest that mucosal healing (MH) may be our best marker of clinical response and the prevention of complications in CD. Although we do not necessarily treat to MH as an end point in a patient who is doing well on a biologic agent, studies such as ours could probably help in underscoring the need for a clinical endoscopic evaluation in patients on a biologic therapy in order to optimize dose or guide switching to another agent<sup>[9,10]</sup>.

We have performed a study with the aim to evaluate mucosal lesions in SB by CE in patients with CD before the administration of infliximab (IFX) or adalimumab (ADA) and following one-year maintenance treatment with these agents. This clinical study is due to our knowledge one of the few (for example Eftymiou *et al* found in a prospective, multicenter, case-series study when studying forty patients with CD, that clinical response does not seem to correlate with MH in patients with SB CD /11/ and Schnitzler *et al* found that MH induced by long-term maintenance IFX treatment is associated with an improved long-term outcome of CD especially with a lower need for major abdominal surgeries /10/) to answer the question of what is the efficacy of IFX or ADA the healing rates of SB lesions (which seems to be critical for the outcome of the patient).

## METHODS

The primary end point of our study was to determine the efficacy of biological treatment on mucosal lesions in the small bowel of CD patients. Secondary aim was to determine the diagnostic significance of CE in patients with CD.

### Patients

We prospectively monitored a group of consequently included patients with CD localized in small bowel, following the approval of Ethics Committee and after the signature of Informed Consent. All the included patients were not previously treated with IFX (Remicade; Centocor, Inc., Horsham, UK) or ADA (Humira; Abbott Laboratories, North Chicago, Illinois, USA), but they were suitable for biological treatment with respect to the indication criteria below.

**Inclusion criteria were:** Male or female between 18 and 65 years of age; Advanced active CD (Crohn's Disease Activity Index /CDAI/ over 220, C-reactive protein over 15 mg/mL).

**The exclusion criteria were:** Fistulizing form of CD; patients with tuberculosis or other serious infectious disorders such as sepsis, abscesses or opportunistic infections such as herpes zoster, cytomegalovirus infection, presence of HIV antibodies; history of malignant disorder within 5 years prior to biological treatment; patients with moderate to severe heart failure (NYHA class III/IV); patients with the history of hypersensitivity to IFX, ADA or other mice proteins or to any of adjuvants; gravidity, breastfeeding; dysphagia; treatment with non-steroidal anti-inflammatory drugs (which could themselves cause mucosal lesions in the SB similar to those found during CD); implantation of a pacemaker.

Women capable of having children used an adequate contraception during the treatment with IFX or ADA (abstinence, oral contraception, intrauterine device, sterilization) to prevent pregnancy. Contraception have been continued for at least 6 months after the treatment with IFX or ADA was terminated.

For each patient, the following was recorded: gender, age, CDAI before and after IFX or ADA treatment, history of smoking, the use of corticosteroids treatment before and after IFX or ADA therapy, surgery before and after IFX or ADA treatment, adverse effects of biological treatment, presence of extraintestinal manifestation of CD before and after IFX or ADA treatment, findings of CE before and after IFX or ADA treatment, adverse events of CE.

### Study design

After the patient with CD was included in the study (when all inclusion criteria have been complied with), CE (Given Imaging Ltd., Norcross, Ga) using the M2A capsule was performed in an ambulatory outpatient setting before the first dose of IFX or ADA was administered. All patients used oral sodium phosphate preparation the night before the procedure in regard to improved visualization of the small bowel. Barium assessment to exclude small bowel strictures before recruitment was not performed. Records from CE were reviewed by the same physician following the examination. IFX treatment (2-hour intravenous infusion) was then initiated under close supervision of specialists experienced in the treatment of CD at the dose of 5 mg/kg at week 0, 2, 6 and every 8 weeks thereafter for the total period of 1 year. ADA treatment (subcutaneous injection) was initiated also under close supervision of a specialists experienced in the treatment of CD at the dose of 80 mg at baseline, followed by 40 mg every second week. During the treatment with IFX or ADA, patients continued with other medication (immunosuppressants...). CE was performed once again after the one-year treatment with IFX or ADA. Results of CE after the biological treatment were compared to the results obtained before therapy. Results were considered as conclusive (diagnostic of active CD- Figure 1) if the following signs of CD localized in the SB were observed: erythema, edema, abrasion of villi, aphthous lesions, ulcerations, scars, openings of fistula, possible strictures, bleeding; inconclusive (suspicious of active CD- Figure 2) if the findings were not typical for active CD: isolated aphthous lesions and ulcerations (less than 3) as they may no be sufficient to confirm diagnosis of CD because up to 13.8% of asymptomatic healthy volunteers can have lesions on CE; and normal (Figure 3).

Examination was regarded as complete if the capsule reached cecum.

### Statistical analysis

To compare findings of CE before and after one year of biological treatment we used the non-parametric matched Wilcoxon test. To compare the groups of patients treated with ADA or IFX in terms of followed characteristics we have used the chi square test in contingent figures and for comparing age we used 2 choices 2 sided Student *t*-test. To compare the number of extraintestinal manifestation in CD we have used the McNemar test. All tests were made on level of significance  $\alpha=0.05$ . We used statistical software SPSS 16.0.

## RESULTS

### Characteristics of patients

From 2007 to 2009 a total of 50 patients with CD were prospectively enrolled. 25 patients were treated with IFX (Table 1) and 25 patients

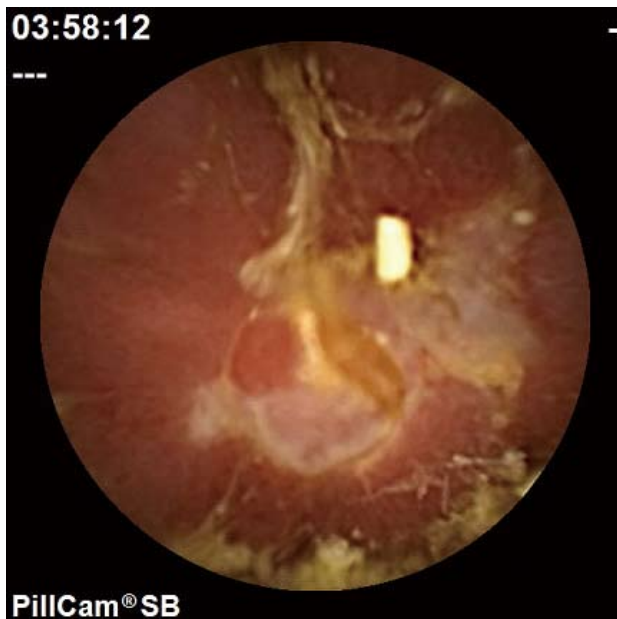


Figure 1 Conclusive finding at capsule endoscopy.

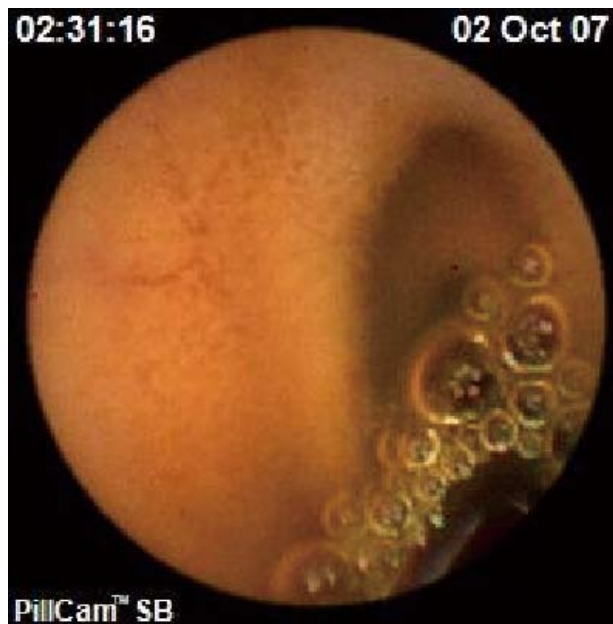

Figure 3 Normal finding at capsule endoscopy.

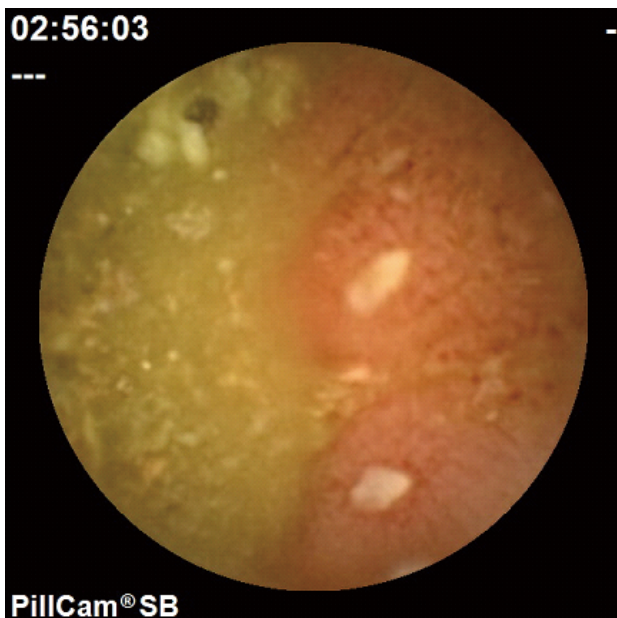


Figure 2 Inconclusive finding at capsule endoscopy.

treated with ADA (Table 2). Because of adverse events due to IFX treatment we had to withdraw 4 patients from the study (allergic reactions, which resolved after corticosteroid treatment). We did not observe adverse events in ADA treatment group. Due to CD reactivation we had to withdraw from the study 2 patients treated with IFX and 2 patients treated with ADA ( $n=4$ ). That means, one year maintenance biological treatment and two CE examinations (before and after biological therapy) concluded a total of 42 patients (from overall 50 patients enrolled).

When we compared the groups treated with IFX and ADA we found no statistical significant difference in any of the followed characteristics. The groups did not statistical significant differ in age and in men women rate. In the groups treated with ADA and IFX we enregistered statistical significant more surgical procedures before, than after therapy. Adverse events occurred only in 4 patients in

the group treated with IFX and also in this characteristic the groups did not statistical significant differ. After one year of treatment with ADA and IFX we observed statistical significant decrease in patients count with extraintestinal manifestations ( $p=0.031$ ,  $p=0.016$ ).

Findings according to CE before and after 1 year therapy did not statistical significant differ in any group. In the group treated with ADA we observed in 3 patients amelioration and in 1 patient deterioration. In the group treated with IFX we observed in 2 patients amelioration of their condition.

#### CE examination

In patients enrolled ( $n=50$ ) in the study, the first CE examination was without any complication, we did not observe any adverse event. In patients, that concluded the follow-up ( $n=42$ ) again CE was without any complication and we did not observe any adverse event. In 7 patients the examination was regarded as incomplete, as the capsule did not reached the cecum.

In the group of followed patients treated one year with ADA ( $n=23$ ), we have seen following changes when comparing CE examination before and after one year biological treatment. In the group of patients with conclusive findings, we did not observe any change on SB findings in 9 patients, in 2 the findings changed to normal. In the group of patients with inconclusive findings we have seen a change to conclusive in 1 patient, in 1 patient the finding remained inconclusive and in 1 patient we noted a change to normal. In the group of patients with normal findings we have not observed in any of 9 followed patients a change, that means findings remained normal.

In the group of patients followed and treated with IFX ( $n=19$ ) we observed following changes when we compared findings of CE examination before and after one year treatment. In the group of patients with conclusive findings we have not observed any change on SB after treatment in 6 patients, in 2 patients the findings have changed to normal. In the group of patients with inconclusive findings we did not see any change in all 3 patients. Also in the group of patients with normal findings we have not seen any change in all 8 patients, that means that the findings have remained normal.

**Table 1** Characteristics of patients treated with infliximab.

Age	Smoking	Detraction of corticosteroids	Surgery before IFX	Surgery after IFX	CE findings before IFX	CE after 1 year	Remission after 1 year IFX	Adverse events	EIM	EIM after IFX	Gender
28	yes	yes	no	no	conclusive	conclusive	yes	no	arthritis	arthritis	f
34	no	yes	yes	no	conclusive	conclusive	yes	no	no	no	m
20	no	yes	no	no	conclusive	conclusive	yes	no	PSC	PSC	m
33	no	yes	yes	no	conclusive	negative	yes	no	arthritis, episcleritis	no	f
36	no	not used	no	no	conclusive	negative	yes	no	no	no	m
58	no	not used	yes	no	conclusive	conclusive	yes	no	erythema nodosum	no	f
43	no	yes	no	no	inconclusive	inconclusive	yes	no	iritidocyclitis	no	f
44	no	yes	no	no	conclusive	conclusive	yes	no	sacroileitis	no	m
23	no	no	yes	no	inconclusive	inconclusive	yes	no	no	no	f
24	no	yes	yes	no	inconclusive	inconclusive	yes	no	no	no	m
40	no	yes	no	no	negative	negative	yes	no	pulmonary	no	m
34	no	yes	yes	no	conclusive	conclusive	yes	no	no	no	m
51	no	yes	yes	no	negative	negative	yes	no	no	no	m
21	no	yes	no	no	negative	negative	yes	no	no	no	f
26	no	yes	yes	no	negative	negative	yes	no	no	no	f
28	no	yes	no	no	negative	negative	yes	no	erythema nodosum	no	f
25	no	yes	no	no	negative	negative	yes	no	no	no	f
26	no	yes	yes	no	negative	negative	yes	no	no	no	f
28	no	yes	no	no	negative	negative	yes	no	erythema nodosum	no	f
31	no	not used	no	no	conclusive	not done	lost to follow-up	yes	no	no	f
37	no	yes	no	no	inconclusive	not done	lost to follow-up	yes	no	no	f
42	yes	yes	no	no	inconclusive	not done	lost to follow-up	yes	no	no	m
46	no	yes	no	no	negative	not done	lost to follow-up	yes	no	no	m
29	no	yes	no	no	negative	not done	relaps of disease	no	no	no	m
32	no	yes	no	no	negative	not done	relaps of disease	no	no	no	f

m: male; f: female; PSC: primary sclerosing cholangitis; EIM: extraintestinal manifestations.

**Table 2** Characteristics of patients treated with adalimumab.

Age	Smoking	Detraction of corticosteroids	Surgery before ADA	Surgery after ADA	CE findings before ADA	CE after 1 year	Remission after 1 year ADA	Adverse events	EIM	EIM after ADA	Gender
28	yes	yes	yes	no	conclusive	conclusive	yes	no	arthritis	arthritis	f
34	no	yes	yes	no	conclusive	conclusive	yes	no	no	no	m
20	no	yes	no	no	conclusive	conclusive	yes	no	PSC	PSC	m
33	no	yes	yes	no	inconclusive	conclusive	yes	no	arthritis, episcleritis	no	f
36	no	not used	no	no	conclusive	negative	yes	no	no	no	m
58	no	not used	yes	no	conclusive	conclusive	yes	no	erythema nodosum	no	f
43	no	yes	no	no	conclusive	negative	yes	no	iritidocyclitis	no	f
44	no	yes	no	no	conclusive	conclusive	yes	no	sacroileitis	no	m
23	no	no	no	no	inconclusive	inconclusive	yes	no	no	no	f
24	no	yes	no	no	inconclusive	negative	yes	no	no	no	m
40	no	yes	no	no	negative	negative	yes	no	pulmonary	no	m
34	no	yes	yes	no	conclusive	conclusive	yes	no	no	no	m
51	no	yes	yes	no	negative	negative	yes	no	no	no	m
21	no	yes	yes	no	conclusive	conclusive	yes	no	no	no	f
26	no	yes	no	no	negative	negative	yes	no	no	no	f
28	no	yes	no	no	conclusive	conclusive	yes	no	erythema nodosum	no	f
25	no	yes	no	no	conclusive	conclusive	yes	no	no	no	f
51	no	yes	no	no	negative	negative	yes	no	no	no	f
21	no	yes	no	no	negative	negative	yes	no	no	no	f
23	no	yes	no	no	negative	negative	yes	no	no	no	f
31	yes	not used	no	no	negative	negative	yes	no	no	no	m
37	yes	not used	no	no	negative	negative	yes	no	no	no	m
41	no	yes	no	no	negative	negative	yes	no	no	no	f
29	no	yes	no	no	conclusive	not done	no	no	no	no	f
35	no	yes	no	no	conclusive	not done	no	no	no	no	f

m: male; f: female; PSC: primary sclerosing cholangitis; EIM: extraintestinal manifestations.

## DISCUSSION

CD is a chronic inflammatory disease of the GI tract believed to develop as a result of the stimulation of a dysfunctional immune response in genetically susceptible individuals<sup>[12]</sup>. The great majority (if not all) of CD patients start with having pure inflammatory lesions. With continued or relapsing inflammatory activity of the disease, the rate of complications increases and eventually nearly all patients will have either stricture formation or fistulisation<sup>[5]</sup>. Therefore, the concept has grown that we should treat CD more aggressively from the onset to improve the outcome of redefined what we expect of our therapies. This became more apparent in

the era of biological therapy, where the goals of management have evolved and recent advances in treatment options for CD have made the goals of treatment more ambitious and modification of the natural course has become the ultimate endpoint. Deep and longlasting healing of the inflammatory lesions seems inevitable to achieve this goal<sup>[13,14,15]</sup>. Emerging data suggest that MH may be our best marker of clinical response<sup>[16,17]</sup> and the prevention of complications in CD. Still data on the relationship between the severity of mucosal lesions and the evolution of CD are scarce and, although MH may seem to be an important sign of efficacy in the acute stage, the role of MH in the future disease process has not been scientifically documented. Frosli *et al.*<sup>[18]</sup>, carried out a study before biologic

agents were introduced and, partly, also before antimetabolites were widely used. The limited but still observed relationship between anti-inflammatory agents and MH in their study should, however, be considered as a possible part of the effect of biologic agents because combined treatment with traditional medication is usually performed. Therefore evidence of a multifactorial influence on MH should be considered in clinical situations and in the planning of studies. Moreover, the use of MH as a predictive factor for disease course, need of steroids, and surgery, is also strengthened by the results of Froslic *et al*. Lack of MH may, on the other hand, represent an indication for intensified treatment strategies to prevent a more serious course and complications of disease. The impact of the healing effect of therapy on the outcome of CD has mainly been studied for IFX. Systematic 8 weekly treatment with IFX has been shown to induce complete MH in nearly half of the treated patients. Patients showing complete MH short term and long term had a great reduction in the number of hospitalizations, procedures and surgeries and days of ICU stay as compared with patients showing only transit or no healing<sup>[19]</sup>. Lichtenstein *et al* reported, that patients with MH showed less demands for hospitalization and surgery after treatment with IFX. This study suggested a role for MH in monitoring of treatment efficacy in patients during follow-up<sup>[20]</sup>. Rutgeerts *et al* demonstrated a numerical, but not statistical, reduction in the number of hospitalizations for CD in patients with mucosal healing. The study is likely underpowered to show a disease modifying effect<sup>[21]</sup>. Schnitzler *et al* reported in their study that MH induced by long-term maintenance IFX treatment is associated with an improved long-term outcome of the disease especially with a lower need for major abdominal surgeries<sup>[10]</sup>. Rutgeerts *et al* showed that ADA induced a greater rate of complete MH by Week 12, for pts with moderate to severe ileocolonic CD, as confirmed and these results were sustained for 1 year<sup>[9]</sup>. Baert *et al* demonstrated, that complete MH in patients with early-stage CD is associated with significantly higher steroid-free remission rates 4 years after therapy began<sup>[22]</sup>.

In our study we observed no statistical significant difference in any of the followed signs when comparing the group of patients treated with ADA and IFX. Our results indicate that in spite of clinical effect of the treatment and decline of CDAI (all of 42 patients that concluded the follow-up were in remission and the CDAI was <150) we could not demonstrate statistical significant improvement of endoscopic findings on SB at CE. Findings according to CE before and after one year of biological treatment did not statistical significant differ in any of the followed groups. In the group treated with ADA we have seen in 3 patients improvement and in 1 patients worsening of findings. In the group treated with IFX we have seen in 2 patients improvement of findings.

MH witnesses the thoroughness of the anti-inflammatory action of newer biological therapies and of immunosuppression in CD. More data are of course necessary to see whether remission associated with complete healing of the SB under IFX or ADA therapy tends to prevent progression of the disease and to avoid hospitalizations, procedures and surgeries, ICU stay. These data will also show whether complete MH may delay relapse after discontinuation of therapy. The concept that MH is of significance in CD would be therefore greatly strengthened by prospective follow-up of patients from a population-based endoscopic study. Although we do not necessarily treat to MH as an end point in a patient who is doing well on a biologic agent, studies such as ours will perhaps underscore the usefulness of a clinical endoscopic evaluation in patients who are symptomatic on a biologic therapy in order to optimize dose or guide switching to another agent.

Endoscopic assessment has been internationally used and accepted as the most important objective tool in the management of CD during the last decades. Our present results add to our knowledge to the significance of MH in CD by looking at relationships between biological treatment and MH in a prospective study, based on diagnostic criteria.

In conclusion, despite the fact that we have not observed a clear effect of ADA or IFX treatment on SB MH, in our group of CD patients we observed improvement by means of drop in CDAI during 1 year maintenance biological treatment. The CE offered in our group of patients a reliable visualization of SB mucosa, was well tolerated, without serious adverse events. Further studies exploring the association between MH and a reduction in the complications of inflammatory bowel disease will help to determine what our final therapeutic endpoint should be.

## ACKNOWLEDGMENTS

Supported by a grant from the Slovak Research and Development Agency (APVV-0239-06).

## REFERENCES

- 1 Baert F, Moortgat L, Van Assche G, Caenepeel P, Vergauwe P, De Vos M, Stokkers P, Hommes D, Rutgeerts P, Vermeire S, D'Haens G. Mucosal healing predicts sustained clinical remission in patients with early-stage Crohn's disease. *Gastroenterology* 2010; **138**: 463-48; quiz 463-48
- 2 Cosnes J, Cattan S, Blain A, Beaugerie L, Carbonnel F, Parc R, Gendre JP. Long-term evolution of disease behavior of Crohn's disease. *Inflamm Bowel Dis* 2002; **8**: 244-250
- 3 Efthymiou A, Viazis N, Mantzaris G, Papadimitriou N, Tzourmakliotis D, Raptis S, Karamanolis DG. Does clinical response correlate with mucosal healing in patients with Crohn's disease of the small bowel? A prospective, case-series study using wireless capsule endoscopy. *Inflamm Bowel Dis* 2008; **14**: 1542-1547
- 4 Fell JM, Paintin M, Arnaud-Battandier F, Beattie RM, Hollis A, Kitching P, Donnet-Hughes A, MacDonald TT, Walker-Smith JA. Mucosal healing and a fall in mucosal pro-inflammatory cytokine mRNA induced by a specific oral polymeric diet in paediatric Crohn's disease. *Aliment Pharmacol Ther* 2000; **14**: 281-289
- 5 Frøslie KF, Jahnsen J, Moum BA, Vatn MH. Mucosal healing in inflammatory bowel disease: results from a Norwegian population-based cohort. *Gastroenterology* 2007; **133**: 412-422
- 6 D'haens G, Van Deventer S, Van Hogezaand R, Chalmers D, Kothe C, Baert F, Braakman T, Schaible T, Geboes K, Rutgeerts P. Endoscopic and histological healing with infliximab anti-tumor necrosis factor antibodies in Crohn's disease: A European multicenter trial. *Gastroenterology* 1999; **116**: 1029-1034
- 7 Iddan G, Meron G, Glukhovskiy A, Swain P. Wireless capsule endoscopy. *Nature* 2000; **405**: 417
- 8 Kakkar A, Wasan SK, Farraye FA. Targeting mucosal healing in Crohn's disease. *Gastroenterol Hepatol (N Y)* 2011; **7**: 374-380
- 9 Lichtenstein GR, Yan S, Bala M, Blank M, Sands BE. Infliximab maintenance treatment reduces hospitalizations, surgeries, and procedures in fistulizing Crohn's disease. *Gastroenterology* 2005; **128**: 862-869
- 10 Lichtenstein GR, Abreu MT, Cohen R, Tremaine W. American Gastroenterological Association Institute medical position statement on corticosteroids, immunomodulators, and infliximab in inflammatory bowel disease. *Gastroenterology* 2006; **130**: 935-939
- 11 Lichtenstein GR, Hanauer SB, Sandborn WJ. Management of Crohn's disease in adults. *Am J Gastroenterol* 2009; **104**:

- 465-83; quiz 464, 484
- 12 Lo SK. Capsule endoscopy in the diagnosis and management of inflammatory bowel disease. *Gastrointest Endosc Clin N Am* 2004; **14**: 179-193
  - 13 Podolsky DK. Inflammatory bowel disease. *N Engl J Med* 2002; **347**: 417-429
  - 14 Rutgeerts P, Feagan BG, Lichtenstein GR, Mayer LF, Schreiber S, Colombel JF, Rachmilewitz D, Wolf DC, Olson A, Bao W, Hanauer SB. Comparison of scheduled and episodic treatment strategies of infliximab in Crohn's disease. *Gastroenterology* 2004; **126**: 402-413
  - 15 Rutgeerts P, Diamond RH, Bala M, Olson A, Lichtenstein GR, Bao W, Patel K, Wolf DC, Safdi M, Colombel JF, Lashner B, Hanauer SB. Scheduled maintenance treatment with infliximab is superior to episodic treatment for the healing of mucosal ulceration associated with Crohn's disease. *Gastrointest Endosc* 2006; **63**: 433-42; quiz 464
  - 16 Rutgeerts P, Vermeire S, Van Assche G. Mucosal healing in inflammatory bowel disease: impossible ideal or therapeutic target? *Gut* 2007; **56**: 453-455
  - 17 Rutgeerts P, D'Haens GR, Van Assche GA, et al. Adalimumab induces and maintains mucosal healing in patients with moderate to severe ileocolonic Crohn's disease – first results of the EXTEND Trial. *Gastroenterology* 2009; **136**(Suppl.1): A-116.
  - 18 Saruta M, Papadakis KA. Capsule endoscopy in the evaluation and management of inflammatory bowel disease: a future perspective. *Expert Rev Mol Diagn* 2009; **9**: 31-36
  - 19 Schnitzler F, Fidder H, Ferrante M, Noman M, Arijis I, Van Assche G, Hoffman I, Van Steen K, Vermeire S, Rutgeerts P. Mucosal healing predicts long-term outcome of maintenance therapy with infliximab in Crohn's disease. *Inflamm Bowel Dis* 2009; **15**: 1295-1301
  - 20 Shanahan F. Host-flora interactions in inflammatory bowel disease. *Inflamm Bowel Dis* 2004; **10** Suppl 1: S16-S24
  - 21 Steinhardt HJ, Loeschke K, Kasper H, Holtermüller KH, Schäfer H. European Cooperative Crohn's Disease Study (ECCDS): clinical features and natural history. *Digestion* 1985; **31**: 97-108
  - 22 Voderholzer WA, Beinhold J, Rogalla P, Murrer S, Schachschal G, Lochs H, Ortner MA. Small bowel involvement in Crohn's disease: a prospective comparison of wireless capsule endoscopy and computed tomography enteroclysis. *Gut* 2005; **54**: 369-373
- Peer reviewer:** Fan Xiaoming, MD, PhD, Department of Gastroenterology, Jinshan Hospital of Fudan University, No.391, East Jinyi Road, Jinshan District, Shanghai, 200540, China.