

Congenital Jejunal Membranous Stenosis in a 2-year-old Girl

Yeon Jun Jeong

Yeon Jun Jeong, Department of Surgery, Chonbuk National University Medical School, Jeonju 561-712, Korea

Correspondence to: Yeon Jun Jeong, MD, Department of Surgery, Chonbuk National University Medical School, 634-18 Geumandong, Duckjin-gu, Jeonju, 516-712, Korea. surgeon@jbnu.ac.kr

Telephone: + 82-63-250-1977 Fax: +82-63-271-6197

Received: June 8, 2012 Revised: June 28 2012

Accepted: June 30, 2012

Published online: November 21, 2012

ABSTRACT

Congenital jejunal stenosis due to a perforated membrane is an uncommon cause of intestinal obstruction, but is usually encountered during the neonatal period or during early infancy. However, in rare cases this condition can persist during childhood or adulthood when it is more likely to create diagnostic difficulties. The authors present the case of a 2-year-old girl in whom a diagnosis of jejunal membranous stenosis was suggested by computed tomography and upper gastrointestinal contrast studies.

© 2012 Thomson research. All rights reserved.

Key words: Jejunal stenosis; Membrane; Diaphragm; Child

Jeong YJ. Congenital Jejunal Membranous Stenosis in a 2-year-old Girl. *Journal of Gastroenterology and Hepatology Research* 2012; 1(10): 280-282 Available from: URL: <http://www.ghrnet.org/index./joghr/>

INTRODUCTION

Jejunioleal atresia and stenosis is a major cause of neonatal intestinal obstruction. The incidence of jejunioleal atresia has been reported to range from 1 in 330 to 1 in 1 500 live births^[1]. Stenosis is defined as a partial intraluminal occlusion, resulting in an incomplete intestinal obstruction, and accounts for 5-11% of jejunioleal obstructions^[1-3]. Furthermore, stenosis and the different types of atresia can be viewed as a continuum^[4]. Stenosis may also result from perforated diaphragmatic atresia or from a form of type I atresia with a fenestrated web^[2,3,5]. A review of the available published literature

revealed over 100 cases of congenital duodenal diaphragm or web in childhood or adulthood in single case reports or small series^[6]. However, few cases of congenital jejunal diaphragm in childhood or adulthood have been previously documented^[7,8].

CASE REPORTATION

A 2-year-old girl was admitted for evaluation and treatment of progressive abdominal distension and unremitting vomiting for 3 days. She had a history of intermittent abdominal distension and vomiting from around 6 months, when solid foods were introduced. Symptoms normal subsided after conservative treatment or without treatment. She was born after a normal pregnancy of 38 weeks duration with a birth weight of 3.03 kg. On prenatal ultrasonography 3 days before birth an intestinal obstruction was suspected, but abdominal radiography and intestinal ultrasonography findings after birth were normal. Initially she was bottled-fed and did not manifest any intestinal obstructive symptoms.

On admission, she weighed 11.7 kg (P₂₅-P₅₀) and was 88 cm high (P₅₀-P₇₅). The initial physical examination was normal, excepting the distended abdomen. However, contrast-enhanced computed tomograph (CT) of the abdomen revealed markedly dilated lumens with food materials in stomach and duodenum adjacent to normal small bowel loops (Figure 1A). An upper gastrointestinal (UGI) gastrograffin contrast study showed marked dilatation of bowels from the stomach to the 4th portion of duodenum and dye passage in the small bowel (Figure 1B). However, the exact position of the obstruction could not be ascertained, though it was presumed to be situated a few centimeters distal of Treitz's angle.

During left transverse laparotomy, the duodenum and proximal portion of jejunum appeared markedly dilated, but jejunal diameter decreased to normal at 10 cm distal of Treitz's ligament (Figure 2A). A longitudinal antimesenteric enterotomy was made over the distal portion of the dilated jejunum and an intraluminal diaphragm with a small aperture was observed (Figure 2B). A 5 cm longitudinal enterotomy was then made over the diaphragm, and this was followed by partial excision, and transverse jejunal closure. The patient made a rapid, uneventful recovery with complete obstructive symptom relief, and was discharged at 8 days postoperatively. She remained well at 4 months postoperatively and was ingesting a diet normal for age.

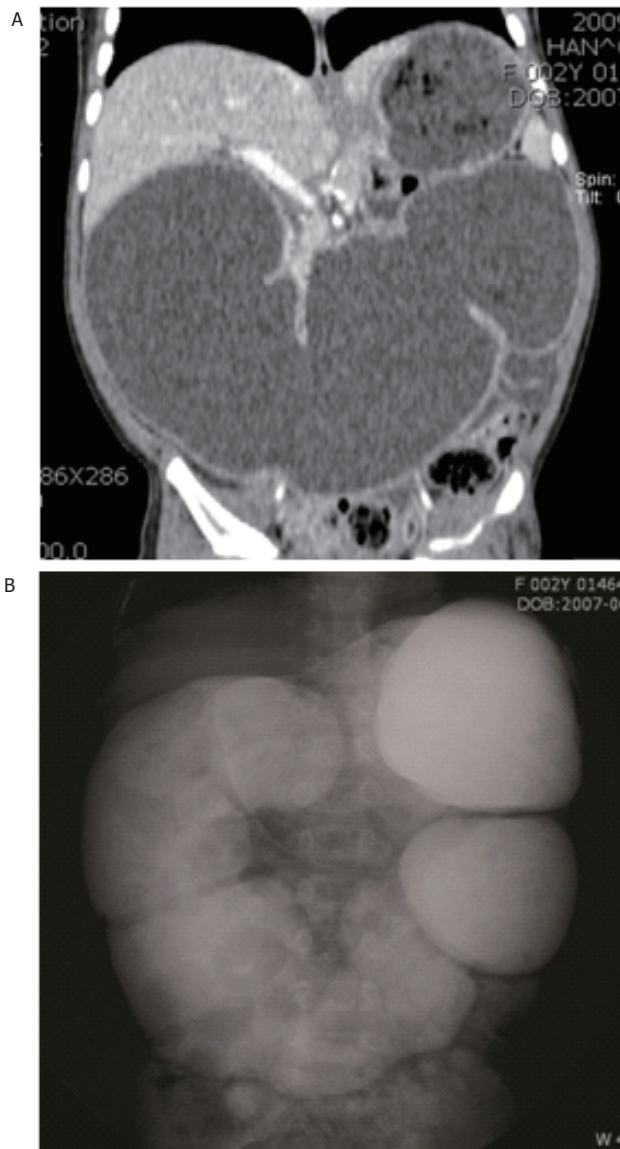


Figure 1 Radiology findings. **A:** Computed tomography (CT) of the abdomen showing markedly dilated lumens with food materials in stomach and duodenum adjacent to normal small bowel loops. **B:** Upper gastrointestinal contrast series showing marked bowel dilatation from the stomach to the 4th portion of the duodenum with dye passage in small bowels.

DISCUSSION

Intestinal stenosis is likely to create diagnostic difficulties, and initial investigations may be normal^[3], despite an abnormal variation in the caliber of the proximal obstructed intestine. Due to such diagnostic difficulties and its insidious nature, diagnosis is often delayed for months^[5]. When an incomplete small bowel obstruction is diagnosed, an upper gastrointestinal contrast study is indicated to demonstrate the site and nature of the obstruction^[5]. Alternatively, abdominal CT may aid diagnosis in cases like ours.

According to a study of congenital duodenal diaphragms in adults, the severity of symptoms varies, and they probably depend on the size of the opening in the diaphragm and the age of the individual at symptom onset^[9]. Furthermore, we suppose that a relationship exists between symptom onset and the size of the congenital upper jejunal membranous stenosis, as is the case for congenital duodenal diaphragms in adults.

Variations in the surgical management of congenital jejunoileal

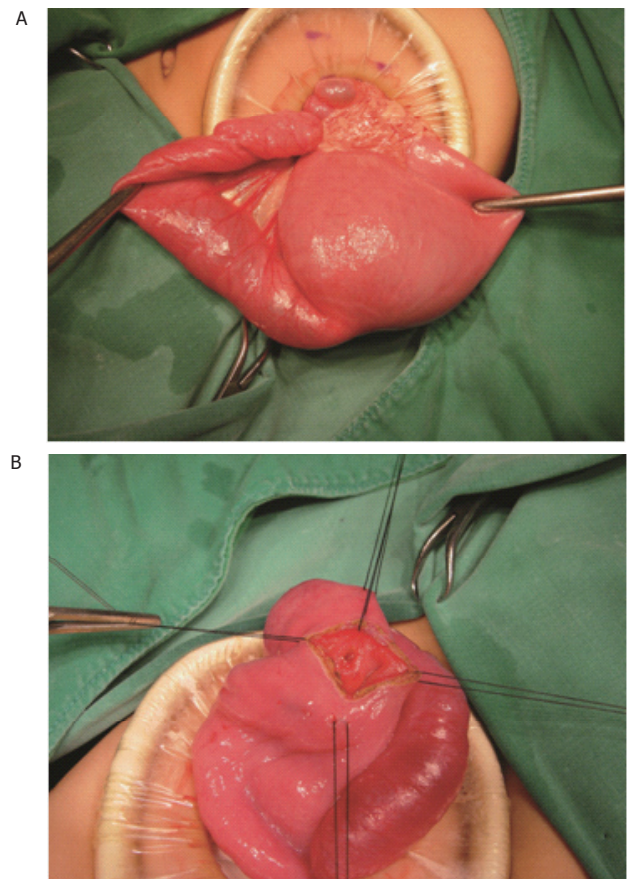


Figure 2 Intraoperative findings. **A:** The proximal portion of the jejunum appeared markedly dilated, but no dilation was evident at 10 cm distal of Treitz's ligament. **B:** A longitudinal antimesenteric enterotomy was performed over the distal portion of the dilated jejunum, and an intraluminal diaphragm with a small aperture was visualized through the enterotomy.

atresia and stenosis have been described in the surgical literature. In cases of jejunoileal stenosis, some surgeons advocate a longitudinal incision in the area of the stenosis or membrane with resection of the web and subsequent transverse closure of the intestine, whereas others favor limited intestinal resection^[1,7]. In the described case, we chose the former procedure because the stenosis was situated close to Treitz's ligament, and because an abnormal difference in caliber was present between the proximal and distal jejunum. Recently, it was reported success of endoscopic balloon dilation for an infant patient with congenital membranous stenosis in the jejunum as a treatment modality^[10].

In conclusion, the presence of congenital jejunal membranous stenosis in childhood is an uncommon condition. However, the entity of congenital jejunal membranous stenosis should be suspected in children with abdominal distension and unremitting vomiting.

REFERENCES

- 1 Grosfeld JL, O'Neill JA, Coran AG, Fonkalsrud EW. *Pediatric Surgery*. 6th ed. Philadelphia: Mosby 2006; 1269-1287
- 2 Stollman TH, de Blaauw I, Wijnen MH, van der Staak FH, Rieu PN, Draaisma JM, Wijnen RM. Decreased mortality but increased morbidity in neonates with jejunoileal atresia; a study of 114 cases over a 34-year period. *J Pediatr Surg* 2009; **44**: 217-221

- 3 Ashcraft KW, Holcomb GW 3rd, Murphy JP. Pediatric Surgery. 4th ed. Philadelphia: Elsevier Saunders 2005: 416-434
- 4 Louw JH, Barnard CN. Congenital intestinal atresia: observations on its origin. *Lancet* 1955; **269**: 1065-1071
- 5 Puri P. Newborn Surgery. 2nd ed. London: Arnold 2003: 445-456
- 6 Cooperman AM, Adachi M, Rankin GB, Sivak M. Congenital duodenal diaphragms in adults: a delayed cause of intestinal obstruction. *Ann Surg* 1975; **182**: 739-742
- 7 De Backer T, Voet V, Vandenplas Y, Deconinck P. Simultaneous laparotomy and intraoperative endoscopy for the treatment of high jejunal membranous stenosis in a 1-year-old boy. *Surg Laparosc Endosc* 1993; **3**: 333-336
- 8 Ladd AP, Madura JA. Congenital duodenal anomalies in the adult. *Arch Surg* 2001; **136**: 576-584
- 9 Moore DJ, O'Sullivan G, Hederman WP. Congenital jejunal mucosal diaphragm and phytobezoar: a cause of intermittent small bowel obstruction in an adult. *Ir J Med Sci* 1981; **150**: 160-161
- 10 Mochizuki K, Obatake M, Kosaka T, Tokunaga T, Eguchi S, Kanematsu T. Endoscopic balloon dilatation for congenital membranous stenosis in the jejunum in an infant. *Pediatric Surg Int* 2011; **27**: 91-93

Peer reviewer: Andres Cardenas, MD, MMSc, Faculty Member, Institute of Digestive Diseases and Metabolism, University of Barcelona, Hospital Clinic-Villarroel 170, Esc 3-2, 08036 Barcelona, Spain.