

## Histopathological Evaluation of Non-Alcoholic Fatty Liver Disease: Mini-Review of Literature

Raíssa Silva Bacelar de Andrade, Ayane Araújo Rodrigues, Luiz Felipe de Carvalho França, Daniel Fernando Pereira Vasconcelos

Raíssa Silva Bacelar de Andrade, Ayane Araújo Rodrigues, Luiz Felipe de Carvalho França, Daniel Fernando Pereira Vasconcelos, Postgraduate Program in Biotechnology, Federal University of Piauí, Brazil

**Conflict-of-interest statement:** The authors declare that there is no conflict of interest regarding the publication of this paper.

**Open-Access:** This article is an open-access article which was selected by an in-house editor and fully peer-reviewed by external reviewers. It is distributed in accordance with the Creative Commons Attribution Non Commercial (CC BY-NC 4.0) license, which permits others to distribute, remix, adapt, build upon this work non-commercially, and license their derivative works on different terms, provided the original work is properly cited and the use is non-commercial. See: <http://creativecommons.org/licenses/by-nc/4.0/>

**Correspondence to:** Raíssa Silva Bacelar de Andrade, Postgraduate Program in Biotechnology, Federal University of Piauí, Brazil.  
Email: [raissa\\_sba@hotmail.com](mailto:raissa_sba@hotmail.com)  
Telephone: +55-86-999509867

Received: December 12, 2017

Revised: January 6, 2018

Accepted: January 9, 2018

Published online: February 21, 2018

### ABSTRACT

Non-alcoholic fatty liver disease (NAFLD) is a liver disease, which has common characteristics, as hepatic steatosis (lipid accumulation in hepatocytes) and fibrosis of the tissue. From these characteristics, the gold standard for diagnosis of the disease is the histopathological evaluation after liver biopsy. For this evaluation, some scores are available, and the SAF score (Steatosis, Activity, Fibrosis) has recently been described for a more complete assessment of the hepatic status. The purpose of this mini-review is to report the NAFLD using this new score.

**Key words:** Fatty Liver; Histology; Steatosis; Fibrosis

© 2018 The Author(s). Published by ACT Publishing Group Ltd. All rights reserved.

de Andrade RSB, Rodrigues AA, de Carvalho França LF, Vasconcelos DFP. Histopathological Evaluation of Non-Alcoholic Fatty Liver Disease: Mini-Review of Literature. *Journal of Gastroenterology and Hepatology Research* 2018; 7(1): 2505-2508 Available from: URL: <http://www.ghrnet.org/index.php/joghr/article/view/2226>

### INTRODUCTION

Non-alcoholic fatty liver disease (NAFLD) is the most common chronic liver disease in the industrialized world and will become one of the most important challenges to public health in the coming decades due to its hepatic and extrahepatic complications<sup>[1]</sup>.

NAFLD is a result of metabolic syndrome in the liver, and its pathological processes include steatosis to steatohepatitis<sup>[2]</sup>, which can progress to fibrosis, cirrhosis and hepatic carcinoma<sup>[3,4,5]</sup>. It is characterized by accumulation of fat in hepatocytes greater than 5% in hepatic tissue, in the absence of significant consumption of alcohol, drugs and viral hepatopathy<sup>[6]</sup>. It is associated with obesity, type 2 diabetes and dyslipidemia<sup>[7]</sup>.

Insulin resistance and excessive accumulation of lipids are strongly associated with non-alcoholic fatty liver disease (NAFLD), which represents the hepatic manifestation of a systemic deficiency of the insulin network<sup>[8]</sup>. This pathogenesis is multifactorial and includes alterations in lipid metabolism, with aberrant accumulation of triglycerides, mitochondrial dysfunction, inflammation and oxidative stress<sup>[9]</sup>.

#### Hepatic Steatosis

Non-alcoholic steatosis is the most common form of chronic liver disease and is characterized by accumulation of fat in hepatocytes<sup>[10]</sup>.

The arbitrary threshold for treating steatosis as pathological is the presence of lipid droplets in at least 5% of hepatocytes. Steatosis can be classified into: macrovesicular, composed of large vacuoles that move the nucleus to the periphery of the cell; mid vesicular composed of small and large vacuoles; and microvesicular steatosis composed of innumerable small vacuoles with foamy appearance<sup>[11,12]</sup>.

## MATERIALS AND METHODS

In order to deepen the theme of the study, a review of the literature was carried out in order to answer the following question: Which scientific productions deal with the criteria of histological evaluation of the liver?

The literature search occurred in November and December 2017 in the databases PUBMED and MEDLINE.

For the selection of the sample, the criteria proposed by Moher *et al.*<sup>[13]</sup> (2009) were divided into stages: identification, screening, eligibility and inclusion. Figure 1 shows the flowchart of the whole process of identification and selection of articles.

In the identification and screening were adopted inclusion criteria: be available at the electronic address, free of charge in full and be disclosed in English, Portuguese or Spanish. Thus, dissertations, theses, reports, news, letters to the editor and scientific articles were not available in full online and those that were repeated in the databases. The following keywords or descriptors were used in the Health Sciences Descriptors of the Virtual Health Library: fatty liver, histology, fibrosis.

For the eligibility of publications, each title and abstract was read exhaustively to confirm whether they addressed the guiding question of this research and whether it would meet the inclusion and exclusion criteria established. Then, it happened to the stage of inclusion of the articles. The selection of studies is shown in Table 1.

## HISTOLOGICAL EVALUATION

Currently, liver biopsy, through histopathological evaluation, is still the gold standard for the diagnosis of NAFLD and the evaluation of its progression<sup>[14,15]</sup>.

Histologic evaluation remains the only accurate means of assessing the degree of steatosis, necroinflammatory lesions, fibrosis lesions and non-alcoholic steatohepatitis (NASH), and serves as the primary means of distinguishing NASH from a “simple” steatosis, or steatosis with inflammation<sup>[16]</sup>.

Brunt *et al.* (1999) proposed a semiquantitative evaluation system for the unique lesions recognized for NASH. The proposed system was based on the concept that the histological diagnosis of NASH is formed by a set of features rather than any individual characteristic. In this system the extent of steatosis can be classified according to the percentage of steatotic hepatocytes: mild, 0-33%; moderate, 33-66%; and severe, > 66%<sup>[17]</sup>. However, it was developed for NASH and was not developed to encompass the entire spectrum of NAFLD as defined by Matteoni *et al.*<sup>[18]</sup> (1999).

From 2002, the NASH Clinical Research Network proposed to develop and validate a histological evaluation system, characterized by NAFLD Activity Score (NAS), which would cover the spectrum of NAFLD and could be applied to pediatric NAFLD, and this would allow the evaluation of changes with therapy. The histological characteristics were grouped into five broad categories: steatosis, inflammation, hepatocellular lesion, fibrosis and various characteristics. The evaluation system was divided into 4 grades, classified as 0 > 5%, 1-5% - 33%, 2-> 33% -66% and 3-> 66%<sup>[18]</sup>. This system was based on and further perfected Brunt *et al.*'s (1999) classification proposal.

Several semiquantitative histological scoring systems were proposed to diagnose and classify NAFLD. Each one has certain advantages and some limitations. However, the recent scoring system - Steatosis, Activity, Fibrosis (SAF) algorithm proposed by Bedossa *et al.*<sup>[20]</sup> (2012) based on the findings of the American Association

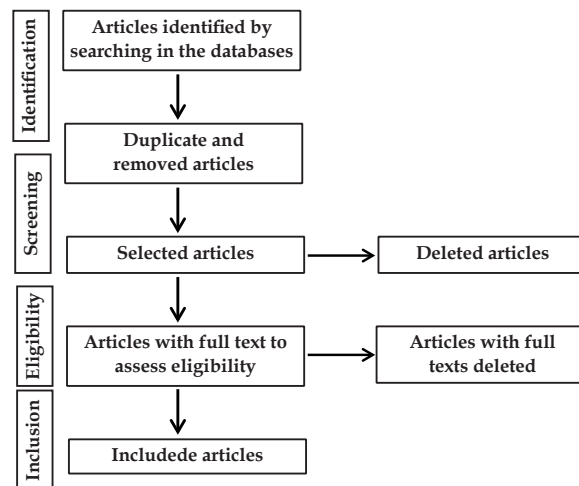


Figure 1 Flowchart of the research phases.

for the Study of Liver Disease scored the same histological characteristics but with steatosis classified separately from the activity score (ballooning and lobular inflammation).

Few literature findings emphasize the evaluation of scores and their relevance in the diagnosis of hepatic steatosis by the SAF method. With this, the objective of this study was to evaluate the new diagnostic method of SAF hepatic steatosis by means of a review in the literature.

## SAF HISTOPATHOLOGICAL SCORES

NAFLD is defined by the presence of steatosis in > 5% of hepatocytes; and NASH, by the presence, in addition, of ballooned hepatocytes of any degree and lobular inflammatory infiltrate of any amount<sup>[21]</sup>. Therefore, steatosis was used as input criteria to the algorithm weighted by hepatocellular ballooning and lobular inflammation.

The SAF score (steatosis, activity, fibrosis) is the usual method of evaluation in liver histological lesions. The steatosis score (S) was evaluated as the amount of lipid droplet, however without apparent foamy microvesicles, from 0 to 3 (S0: < 5%, S1: 5% -33%, light, S2: 34-66%, moderate; S3: > 67%). The degree of activity (A, from 0 to 4) was assessed by the presence of unweighted ballooned hepatocytes (0-2) and lobular inflammation (0-2). Cases with A0 (A = 0) had no activity, A1 (A = 1), mild activity, A2 (A = 2), moderate activity, A3 (A = 3) severe activity. The fibrosis stage (F) was evaluated using the NASH-CRN score; stage 0 (F0) (none); stage 1 (F1): 1a or 1b perisinusoidal zone 3 or 1c of portal fibrosis, stage 2 (F2): perisinusoidal and periportal fibrosis without bridge, stage 3 (F3): bridge fibrosis and stage 4 (F4): cirrhosis<sup>[22]</sup>.

## RESULTS AND DISCUSSION

Twelve articles were analyzed in this study. The articles were found in the Medline (02) and Pubmed (10) databases. Regarding the periodical and language, all were published in international magazines with English language.

As for the histopathological evaluation of the studies, one classified according to the percentage of steatotic hepatocytes (Brunt *et al.*, 1999), eight articles performed the diagnosis of NAFLD according to the NAS score (Kleiner *et al.*, 2005; Vajro *et al.*. The results are shown in Table 1 and Table 2 for the results obtained by Dowman *et al.* and the use of the SAF score (Bedossa *et al.*, 2012, Singh *et al.*,

2015, and Bedossa P, 2017).

The respective data is presented in the following table.

It was possible to observe that the NAS score is still widely used for the diagnosis of NAFLD and that the SAF score, despite classifying steatosis and fibrosis separately, is still rarely used.

From the first description of the pathological findings and the nomenclature of Ludwig *et al*<sup>[30]</sup> (1980), several important pathological classifications of NAFLD were developed to accurately diagnose NASH<sup>[12,18,19]</sup>. The histological scoring systems are based on semiquantitative scores of steatosis, ballooning, lobular infiltration and fibrosis, and are very useful in clinical trials<sup>[31]</sup>. One such widely accepted point is the NAFLD Activity Score, developed by the Pathology Committee of the NASH Clinical Research Network in 2005<sup>[31]</sup>. Although this score is easy to understand and clearly separates the three lesions, it is an unweighted sum of steatosis score, lobular inflammation and hepatocellular ballooning, but it does not include a parameter of fibrosis in NAS.

NAS without the inclusion of fibrosis may lose great reliability in the distinction of liver diseases. Based on the findings of the

**Table 1** Selection of research articles in the Pubmed and Medline databases, according to established inclusion criteria.

Articles/Source	Medline	Pubmed	Total
Found	678	432	1110
Articles not related to the theme	621	412	1033
Repeated	35	12	47
Unavailable	20	5	25
Selected	2	10	12

**Table 2** Characteristics of studies included in this study.

Autors	Title	Year of publication	Histological evaluation
Vajro <i>et al</i> [16]	Diagnosis of nonalcoholic fatty liver disease in children and adolescents: position paper of the ESPGHAN Hepatology committee	2012	The recommendation of the use for histological evaluation comes from the association of several risk factors, combined with the NAFLD activity score (NAS).
Brunt <i>et al</i> [17]	Nonalcoholic steatohepatitis: a proposal for grading and staging the histological lesions	1999	With the inclusion of an extension to steatosis, it was classified according to the percentage of steatotic hepatocytes.
Kleiner <i>et al</i> [19]	Design and validation of a histological scoring system for nonalcoholic fatty liver disease	2005	The NASH Clinical Research Network proposed to develop and validate a histological assessment system, characterized by the NAFLD Activity Score (NAS).
Bedossa <i>et al</i> [20]	Histopathological algorithm and scoring system for evaluation of liver lesions in morbidly obese patients	2012	Based on the results of the American Association for the Study of Liver Disease scored the same histological characteristics but with steatosis classified separately from the score of the activity.
Singh <i>et al</i> [22]	Fibrosis progression in nonalcoholic fatty liver vs nonalcoholic steatohepatitis: a systematic review and meta-analysis of paired-biopsy studies	2015	The SAF score (steatosis, activity, fibrosis) is the usual method of evaluation in liver histological lesions.
Kishida <i>et al</i> [23]	Development of a novel mouse model of hepatocellular carcinoma with nonalcoholic steatohepatitis using a high-fat, choline-deficient diet and intraperitoneal injection of diethylnitrosamine	2016	Variables were blindly scored by two experienced hepatopathologists using a modified scoring system adapted from the NAFLD activity score (NAS).
McPherson <i>et al</i> [24]	Evidence of NAFLD progression from steatosis to fibrosing-steatohepatitis using paired biopsies: implications for prognosis and clinical management.	2015	The NAFLD activity score (NAS).
Auberval <i>et al</i> [25]	Metabolic and oxidative stress markers in Wistar rats after 2 months on a high-fat diet	2014	In the liver, the degree of steatosis was defined on sections according to Kleiner <i>et al</i>
Mohamed <i>et al</i> [26]	Circulating adipokines in children with nonalcoholic fatty liver disease: possible noninvasive diagnostic markers	2017	The histopathological interpretation of the liver biopsy was determined according to the NAFLD activity score (NAS).
Bedossa[27]	Pathology of non-alcoholic fatty liver disease.	2017	Describing histopathological lesions in NAFLD using the SAF.
Zhang <i>et al</i> [28]	Effects of telmisartan on improving leptin resistance and inhibiting hepatic fibrosis in rats with non-alcoholic fatty liver disease	2017	The sections were then routinely analyzed for NAFLD activity score (NAS) and fibrosis score (FS) using the modified Chevallier semi-quantitative scoring system.
Dowman <i>et al</i> [29]	Development of hepatocellular carcinoma in a murine model of nonalcoholic steatohepatitis induced by use of a high-fat/fructose diet and sedentary lifestyle.	2014	Each section was allocated a NAFLD activity score (NAS) through blinded assessment according to the Kleiner scoring system.

American Association for the Study of Liver Disease, Bedossa *et al*<sup>[20]</sup> (2012) proposed the histological algorithm of NASH SAF, which classifies active and chronic lesions separately, but together as SAF scores. They increased uncertainty about the inclusion of steatosis in scores because its harmful effect is not proven, further asserting that this leads to the discrepancy between the NAS and NASH diagnosis. To date, the NAFLD score remains controversial, with the need to assess the utility and limitations of current systems. Histopathological descriptions and feature-based diagnosis are arguably the most important, but the usefulness of scoring in clinical trials, comparative studies, and ease of understanding of these outcomes, for both pathologists and clinicians, can not be underestimated.

In addition, the fibrosis stage was independently associated with general long-term mortality, liver transplantation and liver-related events<sup>[32]</sup>. The use of NAS without the inclusion of fibrosis would underestimate the presence of significant liver disease and has also been reported in other studies<sup>[33]</sup>. These results suggest the need to include fibrosis in the total score or modify the final diagnosis.

Therefore, by describing the main histopathological characteristics in a practical way, the SAF score allows an easy comparison between biopsies and becomes able to deal with more precise diagnosis in any case.

## CONCLUSION

Thus, the scoring system that uses the algorithm as the SAF score can provide practical tools for pathologists that would simplify the understanding of hepatic lesions by hepatologists.

## REFERENCES

- Della PG. Isocaloric Dietary Changes and Non-Alcoholic Fatty Liver Disease in High Cardiometabolic Risk Individuals. *Nutrients* 2017; **26**: 9(10). pii: E1065. [DOI: 10.3390/nu9101065]
- European Association for the Study of the Liver (EASL). Easleas-easo clinical practice guidelines for the management of non-alcoholic fatty liver disease. *J Hepatol* 2016; **64**: 1388–1402. [DOI: 10.1159/000443344]
- Abd El-Kader SM, El-Den Ashmawy EM. Non-alcoholic fatty liver disease: The diagnosis and management. *World J Hepatol* 2015; **7**: 846–58. [DOI: 10.4254/wjh.v7.i6.846]
- Arab JP, Candia R, Zapata R. Management of nonalcoholic fatty liver disease: An evidence-based clinical practice review. *World J Gastroenterol* 2014; **20**: 12182–201. [DOI: 10.3748/wjg.v20.i34.12182]
- Aguirre L, Portillo MP, Hijona E, Bujanda L. Effects of resveratrol and other polyphenols in hepatic steatosis. *World J Gastroenterol* 2014; **20**: 7366–80. [DOI: 10.3748/wjg.v20.i23.7366]
- Chalasan N. The diagnosis and management of non-alcoholic fatty liver disease: practice Guideline by the American Association for the Study of Liver Diseases. *Hepatology* 2012; **55**: 2005–2023. [DOI: 10.1002/hep.25762]
- Sachin SK, Audrey J, Ronald H. Clements, and Gary A. Abrams. Spectrum of NAFLD and Diagnostic Implications of the Proposed New Normal Range for Serum ALT in Obese Women. *Hepatology* 2005; **42**: 650–656. [DOI: 10.1002/hep.20964]
- Salamone F, Bugianesi E. Nonalcoholic fatty liver disease: The hepatic trigger of the metabolic syndrome. *J Hepatol* 2010; **53**: 1146–1147. [DOI: 10.1016/j.jhep.2010.06.013]
- Takaki A, Kawai D, Yamamoto K. Multiple hits, including oxidative stress, as pathogenesis and treatment target in non-alcoholic steatohepatitis (NASH). *Int J Mol Sci* 2013; **14**: 20704–28. [DOI: 10.3390/ijms141020704]
- Nagao Y, Kawahigashi Y, Sata M. Association of periodontal diseases and liver fibrosis in patients with HCV and/or HBV infection. *Hepat Mon* 2014; **14**: e23264. [DOI: 10.5812/hepatmon.23264]
- Brunt EM. Nonalcoholic steatohepatitis. *Semin Liver Dis* 2004; **24**: 3–20. [DOI: 10.1055/s-2004-823098]
- Tiniakos DG, Vos MB, Brunt EM. Nonalcoholic fatty liver disease: pathology and pathophysiology. *Annu Rev Pathol* 2010; **5**: 145–171. [DOI: 10.1146/annurev-pathol-121808-102132]
- Moher D, Liberati A, Tetzlaff J, Altman DG. Preferred reporting items for systematic reviews and meta-analyses: The PRISMA statement. *PLoS Med* 2009; **6**: e1000097. [DOI: 10.1371/journal.pmed.1000097]
- Schwimmer JB, Behling C, Newbury R. Histopathology of pediatric nonalcoholic fatty liver disease. *Hepatology* 2005; **42**: 641–649. [DOI: 10.1002/hep.20842]
- Harwood J, Bishop P, Liu H, Nowicki M. Safety of blind percutaneous liver biopsy in obese children: a retrospective analysis. *J Clin Gastroenterol* 2010; **44**: e253–e255. [DOI: 10.1097/MCG.0b013e3181cf8358]
- Vajro P, Lenta S, Socha P, Dhawan A, Mickiarnan P, Baumann U. Diagnosis of nonalcoholic fatty liver disease in children and adolescents: position paper of the ESPGHAN Hepatology committee. *J Pediatr Gastroenterol Nutr* 2012; **54**: 700–713. [DOI: 10.1097/MPG.0b013e318252a13f]
- Brunt EM, Janney CG, Di Bisceglie AM, Neuschwander-Tetri BA, Bacon BR. Nonalcoholic steatohepatitis: a proposal for grading and staging the histological lesions. *Am J Gastroenterol* 1999; **94**: 2467–2474. [DOI: 10.1111/j.1572-0241.1999.01377.x]
- Matteoni CA, Younossi ZM, Gramlich T, Boparai N, Liu YC, McCullough AJ. Nonalcoholic fatty liver disease: a spectrum of clinical and pathological severity. *Gastroenterology* 1999; **116**: 1413–1419. [PMID: 10348825]
- Kleiner DE, Brunt EM, Van Natta M, Behling C, Contos MJ, Cummings OW, Ferrell LD, Liu YC, Torbenson MS, Unalp-Arida A, Yeh M, McCullough AJ, Sanyal AJ. Design and validation of a histological scoring system for nonalcoholic fatty liver disease. *Hepatology* 2005; **41**: 1313–1321. [DOI: 10.1002/hep.20701]
- Bedossa P. Histopathological algorithm and scoring system for evaluation of liver lesions in morbidly obese patients. *Hepatology* 2012; **56**: 1751–1759. [DOI: 10.1002/hep.25889]
- Angulo P. Nonalcoholic fatty liver disease. *N Engl J Med* 2002; **346**: 1221–1231. [DOI: 10.1056/NEJMra011775]
- Singh S, Allen AM, Wang Z, Prokop LJ, Murad MH, Loomba R. Fibrosis progression in nonalcoholic fatty liver vs nonalcoholic steatohepatitis: a systematic review and meta-analysis of paired-biopsy studies. *Clin Gastroenterol H* 2015; **13**: 643–654. [DOI: 10.1016/j.cgh.2014.04.014]
- Kishida N, Matsuda S, Itano O, Shinoda M, Kitago M, Yagi H, Abe Y, Hibi T, Masugi Y, Aiura K, Sakamoto M, Kitagawa Y. Development of a novel mouse model of hepatocellular carcinoma with nonalcoholic steatohepatitis using a high-fat, choline-deficient diet and intraperitoneal injection of diethylnitrosamine. *BMC Gastroenterology* 2016; **16**: 61. [DOI: 10.1186/s12876-016-0477-5]
- McPherson S, Hardy T, Henderson E, Burt AD, Day CP, Anstee QM. Evidence of NAFLD progression from steatosis to fibrosing-steatohepatitis using paired biopsies: implications for prognosis and clinical management. *J Hepatol* 2015; **62**: 1148–55. [DOI: 10.1016/j.jhep.2014.11.034]
- Auberval N, Dal S, Bietiger W, Pinget M, Jeandidier N, Maillard-Pedracini E, Schini-Kerth V, Sigrist S. Metabolic and oxidative stress markers in Wistar rats after 2 months on a high-fat diet. *Diabetology & Metabolic Syndrome* 2014; **6**: 130. [DOI: 10.1186/1758-5996-6-130]
- Mohamed AA, Sabry S, Abdallah AM, Elazeem NAA, Refaey D, Algebaly HAF, Fath GAE, Omar H. Circulating adipokines in children with nonalcoholic fatty liver disease: possible noninvasive diagnostic markers. *Annals of Gastroenterology* 2017; **30**: 457–463. [DOI: 10.20524/aog.2017.0148]
- Bedossa P. Pathology of non-alcoholic fatty liver disease. *Liver Int* 2017; **37**: 85–89. [DOI: 10.1111/liv.13301]
- Zhang QZ, Liu YL, Wang YR, Fu LN, Zhang J, Wang XR, Wang BM. Effects of telmisartan on improving leptin resistance and inhibiting hepatic fibrosis in rats with non-alcoholic fatty liver disease. *Exp Ther Med* 2017; **14**: 2689–2694. [DOI: 10.3892/etm.2017.4809]
- Dowman JK, Hopkins LJ, Reynolds GM, Nikolauou N, Armstrong MJ, Shaw JC, Houlihan DD, Lalor PF, Tomlinson JW, Hübscher SG, Newsome PN. Development of Hepatocellular Carcinoma in a Murine Model of Nonalcoholic Steatohepatitis Induced by Use of a High-Fat/Fructose Diet and Sedentary Lifestyle. *Am J Pathol* 2014; **184**: 1550–61. [DOI: 10.1016/j.ajpath.2014.01.034]
- Ludwig J, Viggiano TR, McGill DB, Oh BJ. Nonalcoholic steatohepatitis: Mayo Clinic experiences with a hitherto unnamed disease. *Mayo Clin Proc* 1980; **55**: 434–8. [PMID: 7382552]
- Kleiner DE, Brunt EM. Nonalcoholic fatty liver disease: pathologic patterns and biopsy evaluation in clinical research. *Semin Liver Dis* 2012; **32**: 3–13. [DOI: 10.1055/s-0032-1306421]
- Angulo P. Liver fibrosis, but no other histologic features, is associated with long-term outcomes of patients with nonalcoholic fatty liver disease. *Gastroenterology* 2015; **149**: 389–393. [DOI: 10.1053/j.gastro.2015.04.043]
- Santiago-Rolón A. A Comparison of Brunt Criteria, the Non Alcoholic Fatty Liver Disease Activity Score (NAS) & a Proposed NAS-including fibrosis as Valid Diagnostic Scores for NASH. *Puerto Rico health sciences journal* 2015; **34**: 189. [PMCID: PMC4720965]

Peer Reviewer: Nermine Ehsan