

## **Pangastritis by *Strongyloides stercoralis* in An Immunocompetent Patient: Case Report and Literature Review**

Andrey Biff Sarris, Frederico Antonio Berbetz, Fernando José Leopoldino Fernandes Candido, Paula Beatriz Moreira Salles, Mário Rodrigues Montemor Netto

Andrey Biff Sarris, Frederico Antonio Berbetz, Fernando José Leopoldino Fernandes Candido, Mário Rodrigues Montemor Netto, Department of Medicine of Universidade Estadual de Ponta Grossa (UEPG), Universidade Estadual de Ponta Grossa (UEPG), Brazil

Paula Beatriz Moreira Salles, Department of Gastroenterology and Digestive Endoscopy of Instituto de Gastroenterologia de Ponta Grossa (IGAPG), Instituto de Gastroenterologia de Ponta Grossa (IGAPG), Brazil

**Conflict-of-interest statement:** The authors declare that there is no conflict of interest regarding the publication of this paper.

**Open-Access:** This article is an open-access article which was selected by an in-house editor and fully peer-reviewed by external reviewers. It is distributed in accordance with the Creative Commons Attribution Non Commercial (CC BY-NC 4.0) license, which permits others to distribute, remix, adapt, build upon this work non-commercially, and license their derivative works on different terms, provided the original work is properly cited and the use is non-commercial. See: <http://creativecommons.org/licenses/by-nc/4.0/>

**Correspondence to:** Andrey Biff Sarris, Department of Medicine of Universidade Estadual de Ponta Grossa (UEPG), Universidade Estadual de Ponta Grossa (UEPG), Brazil.

Email: [andreybiff@hotmail.com](mailto:andreybiff@hotmail.com)

Telephone: +55 42 3220-3793

Received: January 4, 2018

Revised: April 5, 2018

Accepted: April 8, 2018

Published online: April 21, 2018

### **ABSTRACT**

**INTRODUCTION:** *Strongyloides stercoralis*' infections are usually asymptomatic. The parasite colonizes the small intestine and only a few cases of gastric involvement have been described.

**CASE PRESENTATION:** A 57-year-old male patient presented a 6 kg weight loss in a time interval of three months. To exclude the

possibility of cancer, he was submitted to an upper gastrointestinal endoscopy, which suggested pangastritis. The gastric strongiloidiasis diagnosis was further confirmed in the histopatologic analysis, which revealed the presence of *S. stercoralis*' eggs and worms.

**DISCUSSION:** Even though the stomach involvement is rare, patients whose gastric mucosa is infected are more likely to evolve to the severe forms. Gastroduodenal ulcers and perforations have been reported as possible complications. Stool examination is considered the gold standard diagnostic method, but the histopatologic analysis may be valuable when stool examination fails. The treatment does not depend on the infection's site and ivermectin is the first line therapy.

**Key words:** *Strongyloides stercoralis*; Gastritis; Strongyloidiasis; Infection.

© 2018 The Author(s). Published by ACT Publishing Group Ltd. All rights reserved.

Sarris AB, Berbetz FA, Candido FJLF, Salles PBM, Netto MRM. Pangastritis by *Strongyloides stercoralis* in An Immunocompetent Patient: Case Report and Literature Review. *Journal of Gastroenterology and Hepatology Research* 2018; **7(2)**: 2574-42577 Available from: URL: <http://www.ghrnet.org/index.php/joghr/article/view/2241>

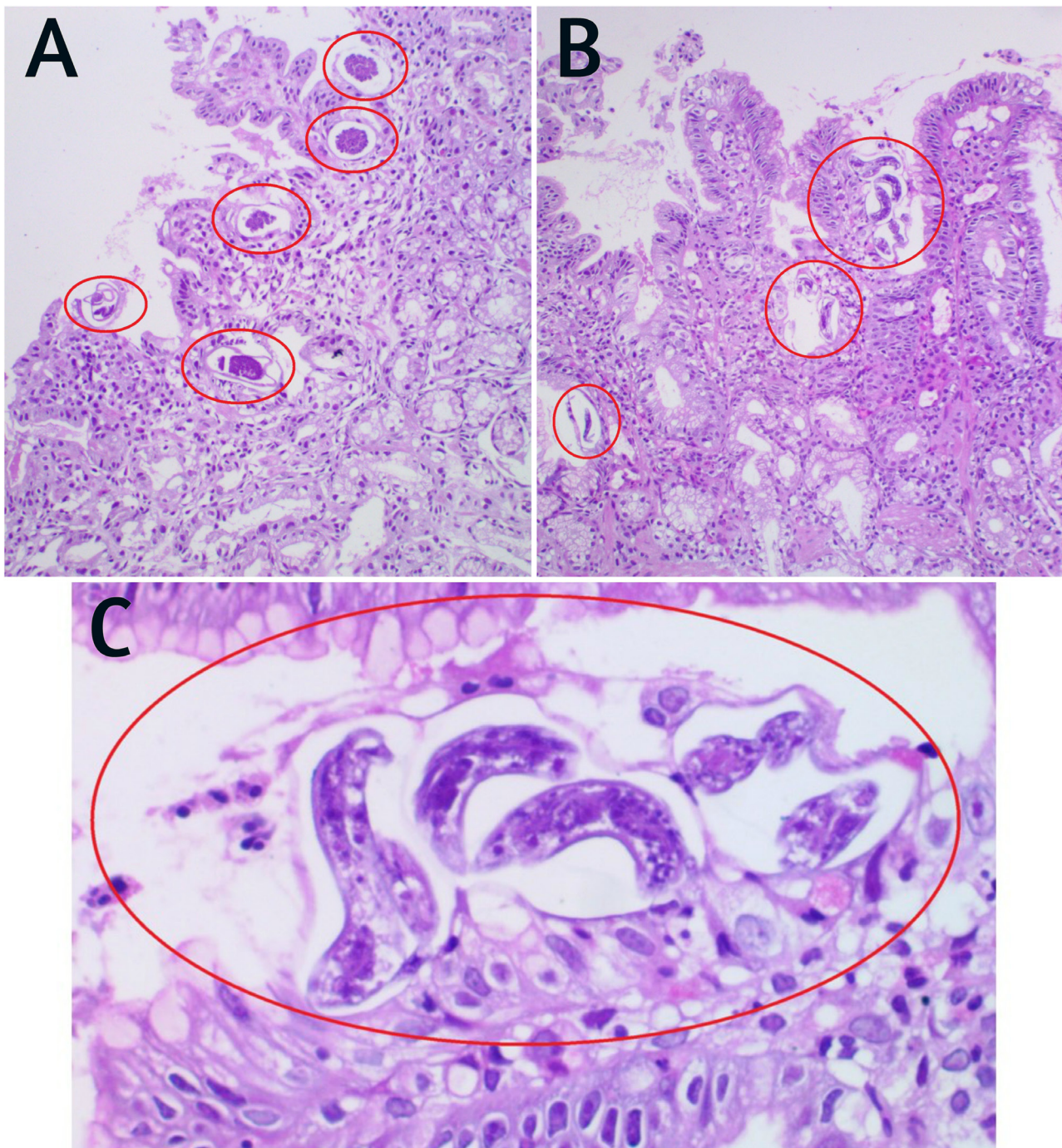
### **INTRODUCTION**

*Strongyloides stercoralis* is a common worldwide nematode, most frequently found in tropical and temperate areas, such as Brazil. The majority of infected patients are asymptomatic, what possibly contributes to the underdiagnosis of this condition<sup>[1,2]</sup>. The symptomatic, disseminated and lethal forms of the disease are more commonly observed in immunocompromised patients, especially those in use of chronic corticosteroids therapy. In Brazil, screening or empiric treatment of this condition is highly recommended in patients who will be submitted to immunosuppressive therapy for a period longer than 14 days or to those who presents others immunosuppressive conditions, such as HIV<sup>[1,2]</sup>. Estrongiloidiasis is caused by the female worm and its life cycle initiates through skin contamination. Gastric involvement is a rare phenomenon and only a few case reports have been described<sup>[1-3]</sup>.

## CASE PRESENTATION

A 57-year-old male patient presented to doctor's appointment with a 6Kg weight loss complaint in the past three months. No other symptom was reported and the physical examination did not present any abnormality. A parasitological stool test was requested, since intestinal parasitic infections are still common in Brazil. Also, an upper gastrointestinal endoscopy (UGE) was performed in order to exclude gastric cancer, which was considered due to patient's age. Analysis of the parasitological stool test revealed the presence of several *Strongyloides stercoralis*' larvae, whereas the UGE showed

moderate pangastritis. Therefore, a gastric biopsy was conducted (see Figure 1) and its histopathological analysis revealed several forms of *Strongyloides stercoralis* (eggs and larvae). Since this parasite is rarely found in the gastric mucosa of immunocompetent patients, an HIV-serological test was performed and yielded negative results. Similarly, the patient denied being previously submitted to any type of immunosuppressive therapy, such as the use of corticosteroids and immunobiological drugs. No other cause of immunosuppression could be identified through our screening; therefore, establishing the diagnosis of *Strongyloides stercoralis*' gastritis in an immunocompetent patient (see Figure 2).



**Figure 1** Gastric mucosal: A e B (HE-100x) – Eggs, larvae and adults of *Strongyloides stercoralis*; C (HE-400x) – Eggs, larvae and adults of *S. stercoralis*.

## DISCUSSION

Estrongiloidiasis, as previously mentioned, is an asymptomatic disease in most patients, including the patient described in this report. Some risk factors are associated to severe forms of infections, such as corticosteroids and immunobiologicals therapies, advanced age, HIV/AIDS and HTLV-1 infections, achlorhydria, H2 blockers use, malnutrition and cancer. The parasite usually infects the small intestine, persisting in it for years. Although it is rarely found in the stomach, patients with gastric involvement present higher risk of developing disseminated disease if they undergo any of the previously mentioned risk factors, especially immunosuppressive therapy<sup>[1-6]</sup>. The action of corticosteroid would be similar to the activating hormones of the ecdysis process (ecdysteroids), worsening autoinfection and leading to a possible fatal outcome<sup>[2]</sup>.

The infectious cycle of *S. stercoralis* can be divided in 3 parts – direct cycle, indirect cycle and autoinfection cycle<sup>[1,7,8]</sup>. The direct cycle is initiated when the rhabditiform larvae from stool matures to filariform larvae and penetrates the skin. Through blood circulation, it reaches the lungs and leads to the development of respiratory symptoms, such as coughing. Coughing, in its turn, allows the worms to reach the pharynx, where they are swallowed and achieve the gastrointestinal tract. In the small intestine, the larvae mature to female adults and produce eggs, which evolve to rhabditiform larvae. The indirect cycle is the development of living adults in the soil by maturation of eggs. Finally, autoinfection cycle occurs when filariform larvae (matured from rhabditiform) penetrates perianal skin and perpetuates the cycle. This last cycle is extremely relevant because allows the infection to perpetuate itself without any another species' participation<sup>[1,7,8]</sup>. The immune response against the parasite is mainly controlled by T-cells with a predominant TH2 response, that leads to the secretion of important cytokines, such as Interleukin-4 (IL-4), Interleukin-5 (IL-5), and Interleukin-10 (IL-10)<sup>[9]</sup>.

A few patients with gastric Estrongiloidiasis may evolve to gastroduodenal ulcers and gastric perforation<sup>[9,10]</sup>. Seo *et al*<sup>[7]</sup> described a case of gastric involvement associated to a gastric adenocarcinoma, which emphasizes the importance of more accurate diagnostic tools in high risk patients for cancer<sup>[8]</sup>. Another presentation of gastric Estrongiloidiasis was seen as multiple small gastric nodules<sup>[11]</sup>. Gastrointestinal symptoms (in the few

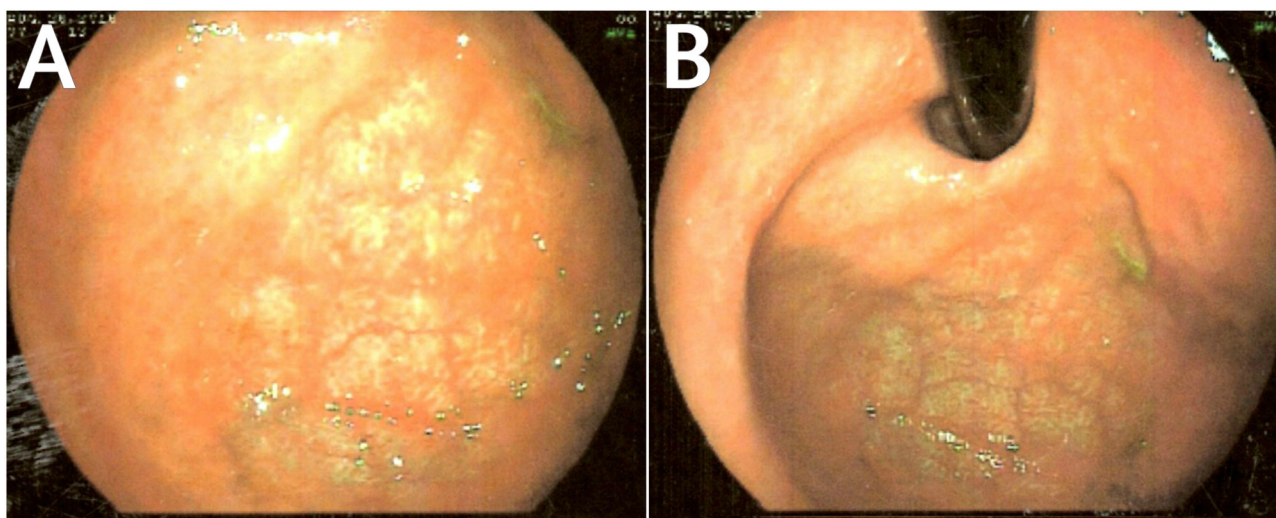
symptomatic patients) may include nausea, dyspepsia, weight loss, vomiting, constipation and abdominal pain<sup>[1,5,6,8]</sup>.

The gold standard for the diagnosis of *Strongyloides sp.* is based on organism identification on stool examination. Despite this, stool examination has a low predictive negative value – a single stool analysis fails in about 70% of the cases<sup>[1,3,6,8]</sup>. Another diagnostic tool is the histopathological analysis of the organs in which the infection is suspected, like we performed in this case. Histological findings typically includes gastritis with lymphocytic and eosinophilic infiltration in the lamina propria. Eggs, larvae and adult worms can also be found<sup>[1,4-6,8]</sup>. Serum eosinophilia can be detected in most of the cases, but may be absent, as it was observed in our case, especially in immunocompromised patients<sup>[1,4]</sup>. Many serological antibody tests (for example, the ELISA method) are currently available to be used in clinical practice. Regardless of the fact that they are quite sensitive, their specificity is less than adequate, since those antibodies may cross-react with other filarial parasites such as *Schistosoma spp.* and *Ascaris spp.* Also, they are not capable of distinguishing acute and chronic infections<sup>[1,8]</sup>. Some alternative diagnostic tools (antigens and molecular diagnosis) have been proposed, but they are not available for clinical use in many hospitals<sup>[12,13]</sup>. The endoscopic findings are usually nonspecific and may show thickened gastric folds, mucosal erosions and ulcers<sup>[1,9,10]</sup>.

Treatment is not altered based on the infection site of *Strongyloides sp.* and patients with gastric involvement should be treated the same way the ones with others forms of the disease. First line therapy is Ivermectin, 200ug/Kg, for two days<sup>[1]</sup>. Albendazole Thiabendazole and Mebendazole are considered alternative options<sup>[1,3,4,8]</sup>.

## CONCLUSIONS

Even though *S. stercoralis* usually infects the small bowel, the parasite may affect the gastric mucosa in a few patients. Since this presentation presents higher chances of evolving to severe complications, such as gastroduodenal ulcers and gastric perforation, the disease should be considered in the differential diagnosis of any patient who presents inespecific stomachal symptoms, like vomiting and abdominal pain. The diagnosis can be established by stool examination, but some cases might require more sophisticated techniques, such as histopathological analysis.



**Figure 2** Gastric mucosal: A e B – Moderate pangastritis at upper gastrointestinal endoscopy (UGE).

## REFERENCES

1. Mohamed R, Hamodat M and Al-Abadi MA. *Gastric Strongyloidiasis: Report of 2 Cases and Brief Review of the Literature*. *Lab Med*. 2017 Feb; **48(1)**: 93-96. [DOI: 10.1093/labmed/lmw041]. Epub 2016 Dec 13.
2. Benincasa CC, Azevedo FO, Canabarro MS, Valentim HM, Silva VD, Superti SV, et al. *Hiper-Infecção por Strongyloides Stercoralis: Relato de Caso*. *Rev. bras. ter. intensiva* vol.19 no.1 São Paulo Jan./Mar. 2007. [DOI: 10.1590/S0103-507X2007000100018].
3. Pereira MJ, Raposo J, Romão Z, Sofa C. Gastritis by *Strongyloides Stercoralis*. *JSM Clin Case Rep* 2014; **2(2)**: 1021
4. Yaldiz M, Hakverdi S, Aslan A, Temiz M and Culha G. Gastric infection by *Strongyloides stercoralis*: a case report. *Turk J Gastroenterol*. 2009 Mar; **20(1)**: 48-51.
5. Rivasi F, Pampiglione S, Boldorini R and Cardinale L. Histopathology of Gastric and Duodenal *Strongyloides stercoralis* Locations in Fifteen Immunocompromised Subjects. *Archives of Pathology & Laboratory Medicine*. 2006 December; **130(12)**: 1792-1798.
6. Kim J, Joo HS, Kim DH, Lim H, Kang YH and Kim MS. A case of gastric strongyloidiasis in a Korean patient. *Korean J Parasitol*. 2003 Mar; **41(1)**: 63-67. [DOI: 10.3347/kjp.2003.41.1.63].
7. Seo AN, Goo YK, Chung DI, Hong Y, Kwon O and Bae HI. Comorbid gastric adenocarcinoma and gastric and duodenal *Strongyloides stercoralis* infection: a case report. *Korean J Parasitol*. 2015 Feb; **53(1)**: 95-9. [DOI: 10.3347/kjp.2015.53.1.95]. Epub 2015 Feb 27.
8. Dhuha MAAS and Aisha AH. A Case of Gastric and Duodenal Strongyloidiasis. *Sultan Qaboos Univ Med J*. 2010 Aug; **10(2)**: 262-265.
9. Sheth S, Asslo F, Hallit R, Sison R, Afridi M, Spira R, DePasquale J, Slim J and Boghossian J. Strongyloidiasis: The Cause of Multiple Gastrointestinal Ulcers in an Immunocompetent Individual. *Case reports in Medicine*. vol.2014, Article ID 346256, 3 pages [DOI: 10.1155/2014/346256].
10. Oztürk G, Aydınlı B, Celebi F and Gürsan N. Gastric perforation caused by *Strongyloides stercoralis*: a case report. *Ulus Travma Acil Cerrahi Derg*. 2011 Jan; **17(1)**: 90-2.
11. Shafaghi A, Askari K, Hajizadeh H and Mansour-Ghanaei F. Gastric strongyloidiasis as multiple small gastric nodules. *Am J Case Rep*. 2012; **13**: 7-10. [DOI: 10.12659/AJCR.882279].
12. Corral MA, Paula FM, Gottardi M, Meisel DMCL, Castilho VLP and Gonçalves EMN. Immunodiagnosis of Human Strongyloidiasis: Use of Six Different Antigenic Fractions From *Strongyloides Venezuelensis* Parasitic Females. *Rev Inst Med Trop Sao Paulo*. 2015 Sep-Oct; **57(5)**: 427-430. [DOI: 10.1590/S0036-46652015000500010]
13. Paula FM, Sitta RB, Malta FM, Gottardi M, Corral MA, Gryscek RC, Chieffi PP. Parasitological and molecular diagnosis in experimental *Strongyloides venezuelensis* infection. *Rev Inst Med Trop Sao Paulo*. 2013 Mar-Apr; **55(2)**: 141-3.