

Laparoscopic Management of Small Peripheral Hepatic Focal Lesions

Morsi Mohamed, Wael Mansy, Mohammed Hashim, Sameh Saber, Ahmed Hamdy, Hossam E-Elshafey

Morsi Mohamed, Wael Mansy, Assistant Professor of Hepato-Biliary Surgery Zagazig University, Zagazig, Egypt

Mohammed Hashim, Specialist of General Surgery at National Hematology & Tropical Medicine Research Institute (NHTMRI), Cairo, Egypt

Sameh Saber, Lecturer of Intervention Radiology Zagazig University, Zagazig, Egypt

Ahmed Hamdy, Lecturer of General Surgery at (NHTMRI), Cairo, Egypt

Hossam E Elshafey, Lecturer of General Surgery at Helwan University, Cairo, Egypt

Conflict-of-interest statement: The authors declare that there is no conflict of interest regarding the publication of this paper.

Open-Access: This article is an open-access article which was selected by an in-house editor and fully peer-reviewed by external reviewers. It is distributed in accordance with the Creative Commons Attribution Non Commercial (CC BY-NC 4.0) license, which permits others to distribute, remix, adapt, build upon this work non-commercially, and license their derivative works on different terms, provided the original work is properly cited and the use is non-commercial. See: <http://creativecommons.org/licenses/by-nc/4.0/>

Correspondence to: Wael Mansy, Hepato-Biliary Surgery Zagazig University, Zagazig, Egypt.

Email: drwaelmansy@hotmail.com

Telephone: +01221607587

Received: October 9, 2018

Revised: October 31, 2018

Accepted: November 2, 2018

Published online: December 21, 2018

ABSTRACT

Laparoscopic resection of benign and malignant hepatic masses can now be accomplished with relatively low morbidity. This fact has changed the mindset of physicians involved in the diagnosis and management of these lesions and influenced the decision-making

process.

AIM: Evaluate the indications and efficacy of both laparoscopic liver resection and laparoscopic radiofrequency ablation for small peripheral hepatic focal lesions.

PATIENTS AND METHODS: From January 2015 to March 2018 61 patients with hepatic focal lesions managed at advanced center of Hepato-biliary disease, Zagazig University and National Hepatology & Tropical Medicine Research Institute. Where laparoscopic liver resection (LLR) done in 37 cases. While laparoscopic radiofrequency ablation (LRFA) in 20 cases 4 cases underwent laparoscopic de-roofing.

RESULTS: 33 males and 28 females with mean age 56.81 ± 10.6 years. 17 patients had postoperative complications. Recurrence occurred in 14 patients of HCC. Mortality occurred in 4 patients of HCC during the 2 years follow-up period.

CONCLUSION: Laparoscopic liver surgery is an alternative to open surgery in small and peripheral focal lesions. Providing better results and advantages in terms of survival and recurrence.

Key words: Liver; Resection; Laparoscopic; Radiofrequency

© 2018 The Author(s). Published by ACT Publishing Group Ltd. All rights reserved.

Mohamed M, Mansy W, Hashim M, Saber S, Hamdy A, E-Elshafey H. Anti-Gp210 And Anti-Sp100 Antibody Status And Ursodeoxycholic Acid Response In Primary Biliary Cholangitis. *Journal of Gastroenterology and Hepatology Research* 2018; **7(6)**: 2768-2776 Available from: URL: <http://www.ghrnet.org/index.php/joghr/article/view/2361>

INTRODUCTION

In modern surgery, minimally invasive surgical technique represents a challenging new era. For treatment of liver diseases, the laparoscopic techniques have been increasingly used. In selected patients, laparoscopic liver resection (LLR) has emerged as an alternative technique compared with open liver resection^[1].

In 1992, Gagne, reported the first laparoscopic liver resection (LLR) for benign disease. In 1994 was the first published LLR for

malignant case. These early reports make the feasibility of LLR for different indications including HCC clear^[2]. Peripheral lesion in the left lateral or peripheral antero-inferior segments have become popular to be treated by laparoscopic hepatectomy^[3].

The use of electro-surgical devices for hepatic parenchyma transection has decreased the blood loss and also improved intraoperative visualization. Accordingly Hepatobiliary surgeons for their surgical practice forced to adopt the technological advances in laparoscopy-necessary skills^[4].

Reduction of blood loss and decreased portal clamp time are the advantages of laparoscopic hepatectomy^[2]. In cirrhotic patients with liver tumors, laparoscopic resection decreases the incidence of postoperative ascites via decrease destruction of collateral blood and lymphatic flow from celiotomy and mobilization, and mesenchymal injury from compression^[5].

PATIENTS AND METHODS

This prospective study was conducted on 61 patients with hepatic focal lesions at advanced center of Hepato-biliary disease, Zagazig University and National Hepatology & Tropical Medicine Research Institute in the period from January 2015 to March 2018. All patients were revised by multi-disciplinary team including liver surgeons, intervention radiologist, medical oncology and hepatology doctors. Inclusion and exclusion criteria presented in Table 1.

Preoperatively all patients were subjected to history taking, clinical examinations, and laboratory investigations including (CBC, LFT, KFT, coagulation profile, viral markers and tumor markers “AFP, CA19-9 & CEA”). Radiology included US, Triphasic CT, Triphasic MRI in cases with uncertain diagnosis; CT chest, CT brain and bone scan for metastatic work up; Upper GIT endoscopy to detect esophageal varices; Lower GIT endoscopy and PET-CT to detect any tumor recurrence in cases of colorectal liver metastasis.

French and semi-left lateral positions were the positions for our patients. In right side lesions, 4-5 ports were placed under direct visualization. A 10-mm port is placed 2-3 cm above and to the right of umbilicus for camera. Two 12-mm ports were placed about 5cm to the left and right side of camera port and one or two 5-mm ports were placed below right and/or left costal margin for liver retraction. In left sided lesions, the same trocars were placed in the same positions but shifted 1-2 cm to the left.

The study divided in two categories, one hospital with available laparoscopic intra-operative US, used for precise assessment of hepatic focal lesions. The other hospital with no laparoscopic intra-operative US available, so for LLR we depend on Triphasic CT preoperative, plus revise CT data with expert interventional radiologist. For LRFA, we start with ordinary trans-abdominal US probe, then inflate the abdomen and assess the liver, mobilize the liver by ligaments detachment. After irrigation the abdominal cavity with fluids, we deflate the abdomen then do trans-abdominal US again, to guide the RF needle insertion. Re-inflate the abdomen again and complete the procedure under vision.

Laparoscopic Liver resection (LLR): (1) LLR done in patients with lesions located peripherally that were accessible to the laparoscopic approach and treatable by limited resection (< 3 segments) with good liver function (CHILD A); (2) Division all the ligamentous attachment of the liver by Harmonic scalpel. Mark the line of dissection by monopolar diathermy (with safety margins 1-2 cm). We used Harmonic Scalpel for hepatic parenchyma dissection; (3) Specimen extraction via small Pfannenstiel incision or widening one of the port sites, after placement of the resected part in a plastic

Table 1 Inclusion criteria.

Inclusion criteria	1. Patients with age 21-70 years.
	2. Exophytic or subcapsular HCC. Patient with peripheral (Segments 2-6).
	3. Patients with Child-Pugh (A and early B).
	4. Patients with HCC 5 cm or less in diameter.
	5. Patients with Hydatid disease proved by radiological and serological methods.
	6. Patients with American Society of Anesthesiologists (ASA) I, II, and III.
Exclusion criteria	1. Liver cirrhosis with Child-Pugh C.
	2. Patients with lesion more than 5 cm in size.
	3. Patients with advanced HCC unfit for resection.
	4. Patients with central lesion.
	5. Multifocal HCC more than 3 tumors.

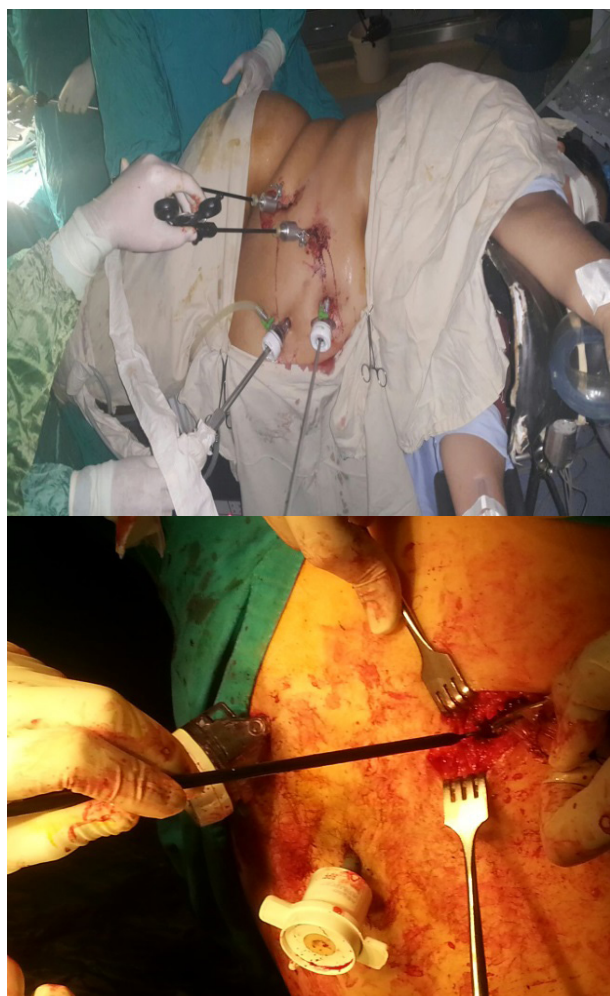

Figure 1 Port positions during LLR. B. Specimen retrieval.

bag (Endobag) or ordinary glove in small lesion and unavailable retrieval bags Figure (1, 2, 3 and 4); (4) Abdominal drain used routinely (Except in only 3 patients).

Laparoscopic Radiofrequency ablation (LRFA): (1) LRFA were chosen in patients with lesions not suitable for LLR. The laparoscopic approach is safe for subcapsular tumors due to the possibility of direct visualization and active protection of the surrounding structures (diaphragm, duodenum, stomach, colon, and gallbladder) and possibility to control the potential bleeding from these lesions. Figure (5, 6); (2) The importance of pneumoperitoneum is not only creates

a working camera which removes the surrounding structures from the liver but also reduces the respiratory movements of the liver and thus facilitates the placement of the RF needle; (3) The lesion was properly exposed either by liver retraction or elevation according to its site; (4) Treatment via RF was planned that coagulative necrosis zones overlap to ensure complete destruction of the tumor with 1cm safety margin. A small stab incision in the skin of the anterior abdominal wall used to introduce the RF needle; (5) After completion of the ablation cycle on the RF device, in order to avoid needle track seeding of malignant cells, the track mode was turned on during gradual withdrawal of the needle electrode to ablate the entry track of the needle. (6) All wounds were then closed and we did not use drains.

All operative data were recorded (operative time, blood loss, blood transfusion). All patients transferred to ICU till the general conditions improved then transferred to the ward. The urinary catheter is removed once the patient is able to ambulate and the drain is removed when it has less than 30cc/day output.

All postoperative data were recorded (postoperative complications, tumor histopathology and hospital stay). Follow-up was done after one month then every 3 months for 2 years by triphasic CT to detect the recurrence. In HCC patients the Alpha feto-protein was also measured.

Statistical analysis

Data was collected and entered to the computer using SPSS (Statistical Package for Social Science) program version 16.0, SPSS Inc., Chicago, Illinois, USA for statistical analysis. Data was entered as numerical or categorical, as appropriate. Two types of analysis were done, descriptive statistics using quantitative and qualitative data. Analytic statistics using Chi- square test and fisher exact test.

RESULTS

This prospective study was conducted on 61 patients with hepatic focal lesions. 43 patients with HCC, 5 patients with hepatic adenoma, 3 patients with colorectal liver metastases, 5 patients with hydatid cyst, 3 patients with simple hepatic cyst and 2 patients with cystadenoma. 33 (54.1%) patients were males while 28 (45.9%) cases were females. the mean of age was 56.81 ± 10.6 years with a range of 20-75 years (Table 2).

Past history of medical diseases were found in 29 patients (Hypertension in 18, diabetes in 9 patients and myocardial infarctions in 2 patients). Hepatic disease (HCV & HBV) was found in 40 patients with HCC and 1 patient with colorectal liver mets.

Single lesion was found in 56 patients. Only 5 patients had multiple lesions (one patient with HCC had 3 lesions, 3 patients with HCC had 2 lesions, while one patient with colorectal liver mets had 2 lesions). Among the 67 lesions in all patients, 30 lesions had a size less than or equal 3 cm (Table 3).

We had chosen Laparoscopic Liver Resection in 37 patients (23 for HCC, 5 for HCA, 4 for hydatid cyst and 2 for cystadenoma patients). While Laparoscopic Radio Frequency Ablation was the choice in 20 patients and only in 4 patients we did deroofting (1 patient with hydatid cyst and 3 patients with simple hepatic cysts).

We found that, CHILD score (*p* = 0.01) and lesions size (*p* = 0.036) were the most important factors that determine the choice of resection vs. radiofrequency ablation in HCC patients (Table 4).

Regarding the operative data, 34 patients underwent non-anatomical resection. While 3 patients underwent left lateral hepatectomy (2 patients with HCC and 1 patient with cystadenoma), all cases of resections were performed by Harmonic Scalpel Device.

Table 2 Demographic data among the patients.

		HCC (N=43) 70.49%	HCA (N=5) 8.2%	Liver Met. (N=3) 4.92%	Hydatid Cyst (N=5) 8.2%	Simple Cyst (N=3) 4.92%	Hepatic Cystadenoma (N=2) 3.27%
Sex	M	29 (47.54%)	0	1 (1.65%)	1 (1.65%)	1 (1.65%)	1 (1.65%)
	F	14 (22.95%)	5 (8.2%)	2 (3.27%)	4 (6.55%)	2 (3.27%)	1 (1.65%)
Age	Mean	59.44	35.6	43.2	28.24	30.4	32.3
	SD	6.69	8.96	5.48	6.47	5.45	7.45
	Range	42-75	22-46	35-60	20-35	28-52	25-49
Medical diseases	+VE.	24 (39.34%)	0	2 (3.27%)	0	2 (3.27%)	1 (1.65%)
	-VE	3 (4.92%)	5 (8.2%)	2 (3.27%)	5 (8.2%)	3 (4.92%)	2 (3.27%)
Hepatic disease	HCV	39 (36.92%)	0	1 (1.65%)	0	0	0
	HBV	1 (1.65%)	0	0	0	0	0
CHILD	A	35 (57.38%)	5 (8.2%)	3 (4.92%)	5 (8.2%)	3 (4.92%)	2 (3.27%)
	B	8 (13.11%)	0	0	0	0	0

Table 3 Evaluation of the hepatic lesions by triphasic CT.

NO. of lesions (67)		HCC (N=48) 71.64%	HCA (N=5) 7.46%	LIVER MET. (N=4) 5.98%	Hydatid cyst (N=5) 7.46%	Simple cyst (N=3) 4.47%	Hepatic Cystadenoma (N=2) 2.99%
Size of lesions	≤ 3 cm	30 (44.78%)	0	3 (4.47%)	0	0	0
	3-5cm	15 (22.39%)	2 (2.99%)	1 (1.48%)	2 (2.99%)	1 (1.48%)	2 (2.99%)
	>5cm	3 (4.47%)	3 (4.47%)	0	3 (4.47%)	2 (2.99%)	0
Site of lesions	Seg.2	11 (16.42%)	0	0	0	1 (1.48%)	0
	Seg.3	8 (11.94%)	2 (2.99%)	1 (1.48%)	2 (2.99%)	0	1 (1.48%)
	Seg.4a	3 (4.47%)	0	0	0	0	0
	Seg.4b	3 (4.47%)	0	0	0	0	0
	Seg.5	4 (5.98%)	1 (1.48%)	1 (1.48%)	0	0	0
	Seg.6	12 (17.9%)	2 (2.99%)	2 (2.99%)	2 (2.99%)	0	1 (1.48%)
	Seg.7	3 (4.47%)	0	0	0	1 (1.48%)	0
	Seg.8	4 (5.98%)	0	0	1 (1.48%)	1 (1.48%)	0

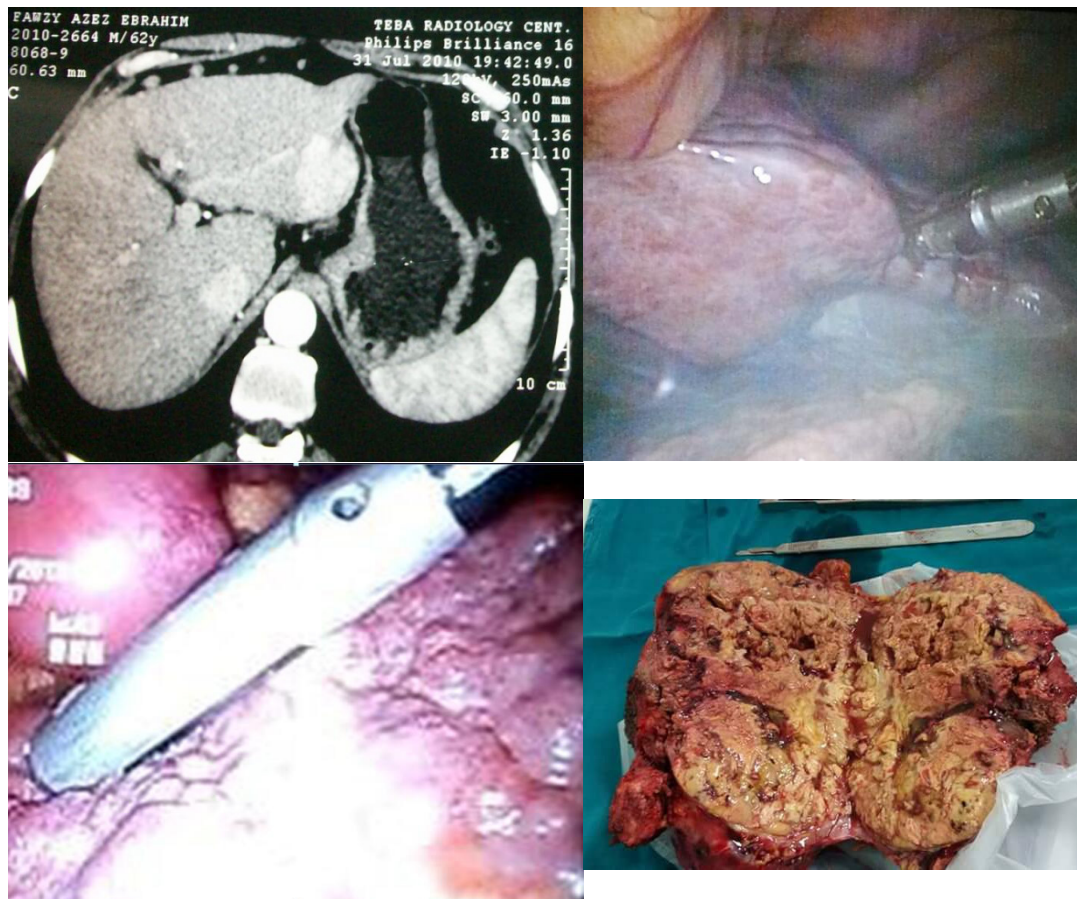


Figure 2 LLR of HCC left lobe using intra-operative US (non-anatomical resection).

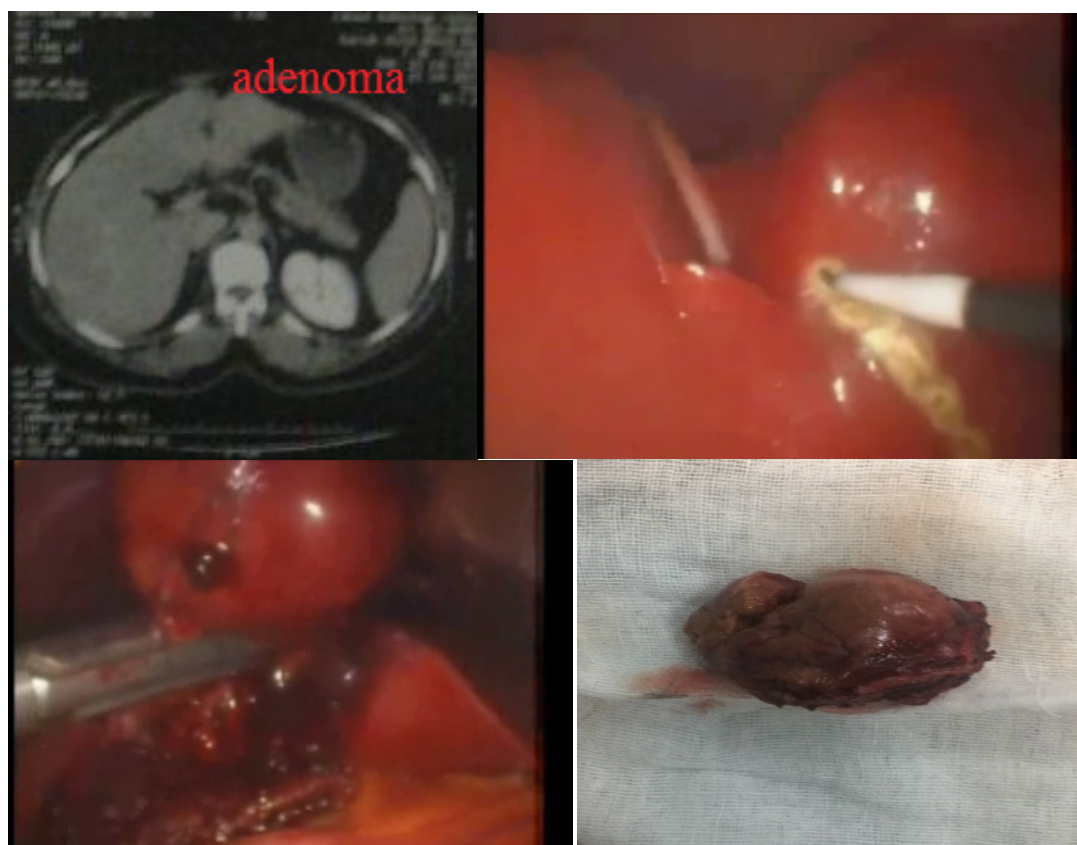

Figure 3 Laparoscopic Resection Of Hepatic Adenoma.

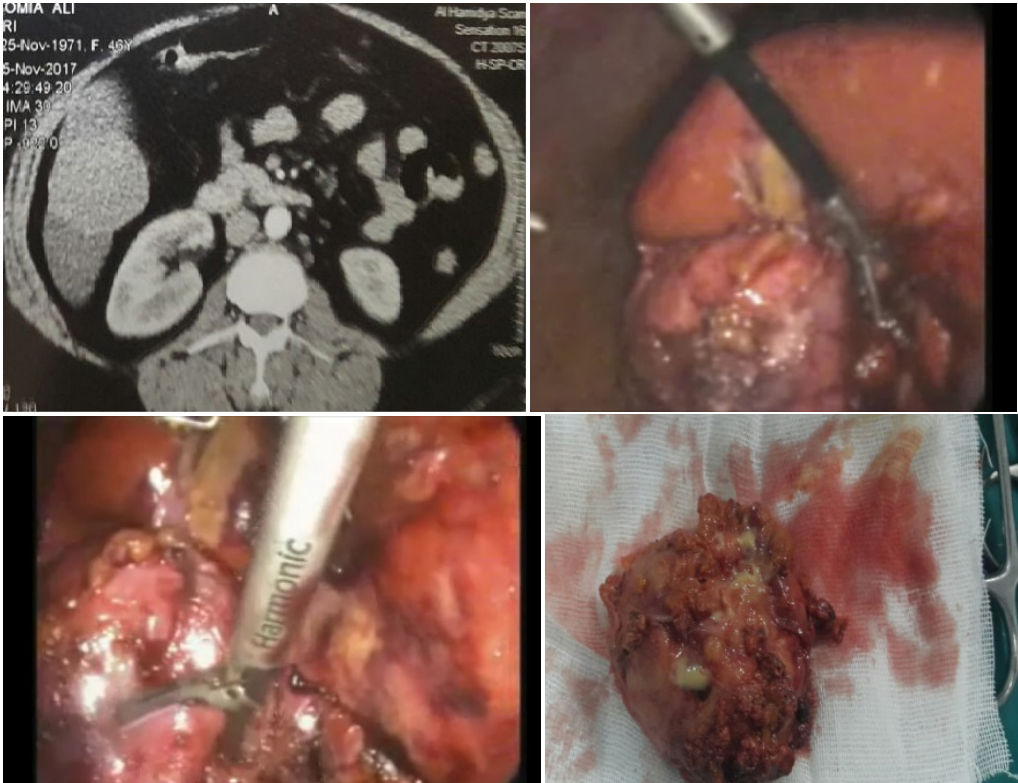


Figure 4 Hydatid cyst segment 6 (laparoscopic total pericystectomy).

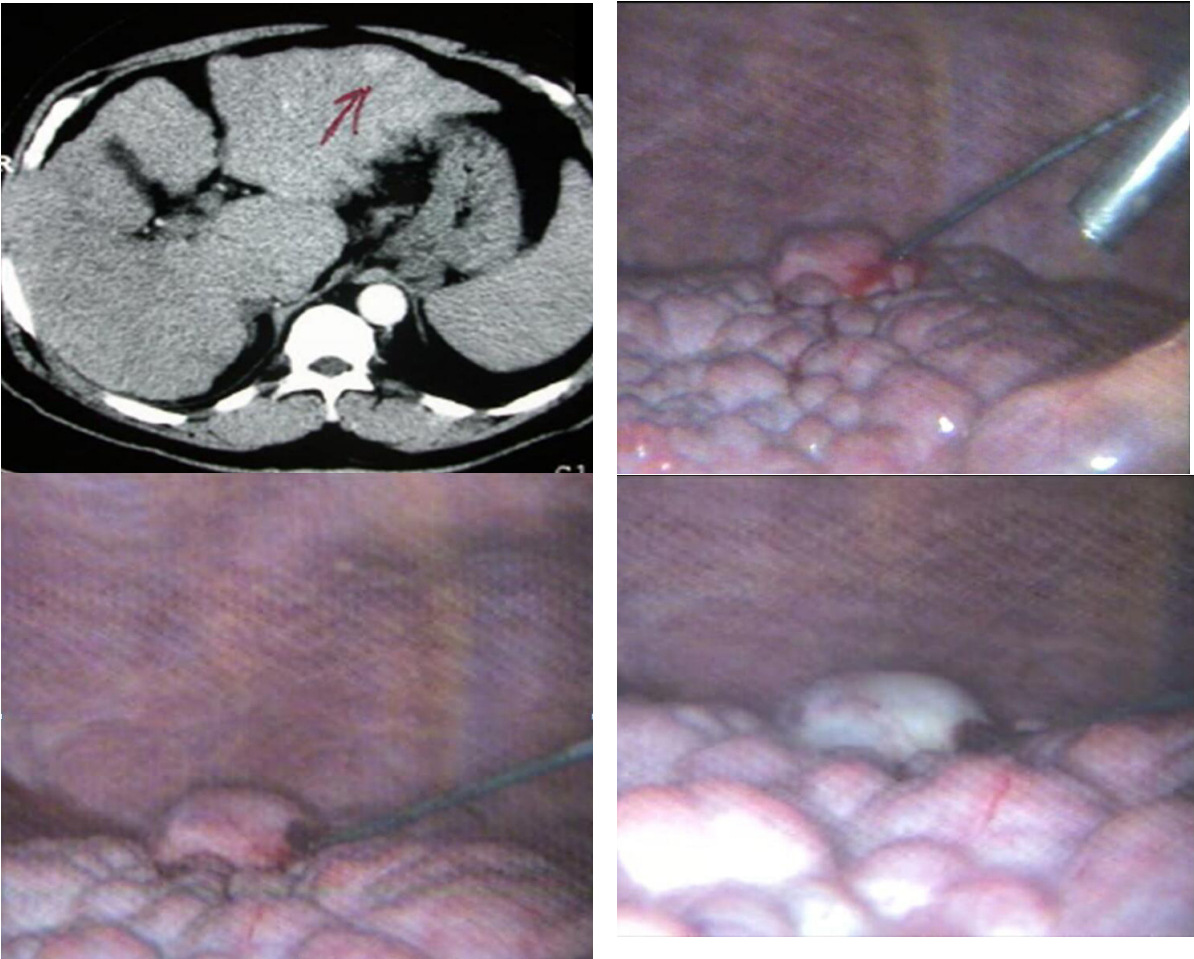


Figure 5 LRFA HCC small lesion in segment II.

Table 4 Univariate analysis of management determinants (HCC patients).

Variable	Resection (N=23)	RFA (N=20)	P value
Age			0.245
Mean	60.61	58.1	
SD	4.53	8.46	
Range	49-67	42-82	
Sex			0.101
Male	13	16	
Female	10	4	
Past History of Medical Diseases			0.606
Yes	12	12	
No	11	8	
Past History of Liver Diseases			0.635
Yes	21	19	
No	2	1	
CHILD Classification			0.01
A	22	13	
B	1	7	
Number of Lesions			0.365
One mass	21	18	
Two masses	2	1	
Three masses	0	1	
Site of Lesions			0.205
Segment 2	6	5	
Segment3	7	1	
Segment 4a	0	3	
Segment 4b	2	1	
Segment 5	2	2	
Segment 6	8	4	
Segment 7	0	3	
Segment 8	0	4	
Size Of Lesion			0.036
< 3cm	13	17	
3-5 cm	9	6	
> 5cm	3	0	

The mean operative time was significantly longer during resection (127.2 ± 36.6 min) than during deroofting (73.3 ± 15.3 min, *p* = 0.005) and RFA (105.3 ± 29.7 min, *p* = 0.032). The difference between RFA and deroofting was also significant (*p* = 0.044). 5 patients required open conversion due to massive uncontrolled bleeding encountered during the laparoscopic resection. The difference was not significant (Table 5).

All the patients with resection had a drain except three patients while no patients needed drain after RFA. All patients had drainage after deroofting. The difference was significant (*p* = 0.0001). The mean amount of blood loss was significantly higher during resection (534 ± 469.6 ml) than during RFA (120 ± 41 ml, *p* = 0.0001) and deroofting (300 ± 100 ml, *p* = 0.05). The difference between RFA and deroofting was not significant (*p* = 0.091).

The mean postoperative ICU stay was about 1.2 ± 0.4 days with maximum ICU stay of 3 days. The drains were removed after 1.8 ± 1.7 days with the maximum was 6 days. The mean hospital stay was 3.27 ± 1.57 days with the maximum hospital stay was 9 days.

Regarding complications, 17 patients (27.87%) had postoperative complications. The most frequent complication was ascites. All complications were managed conservative with no interference. No postoperative mortality was encountered in our patients (Table 6).

Over the 24 months, recurrence occurred in 14 cases of HCC.

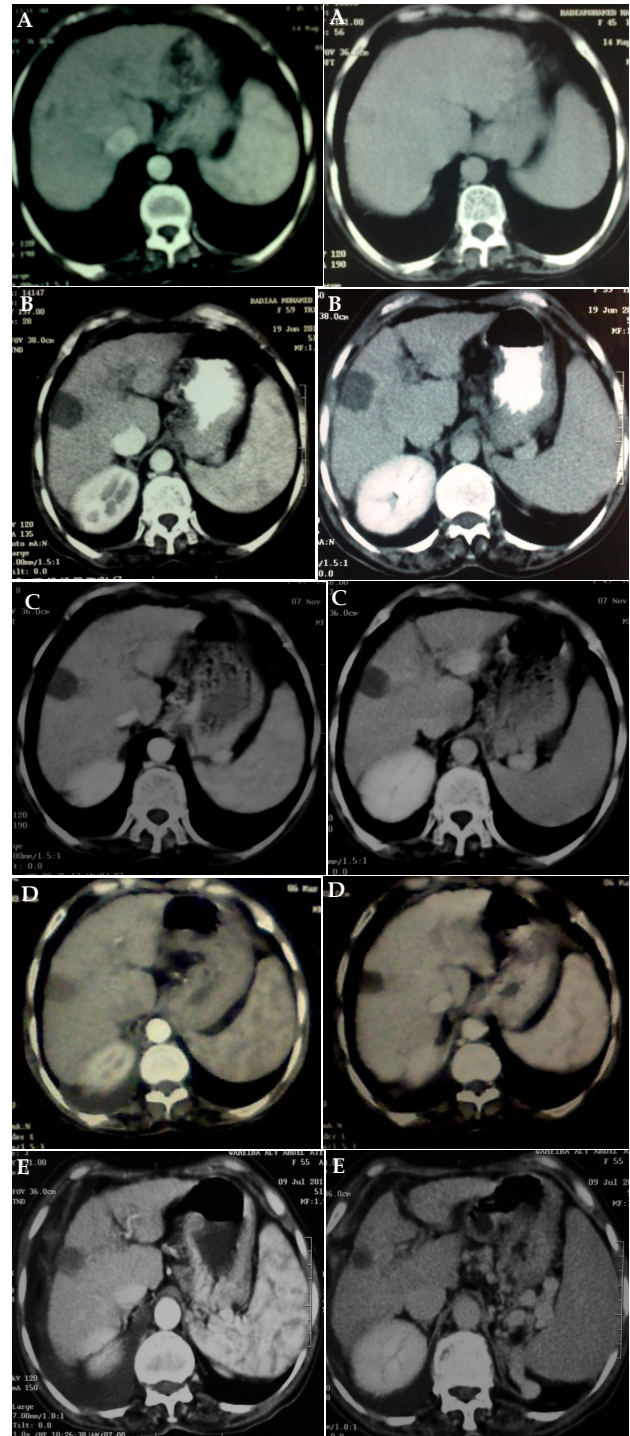


Figure 6 LRFA. A, Pre Procedure. B, 1-Month Post Ablation. C, 3-month Post Ablation. D, 6-Month Post Ablation. E, 9-Month Post Ablation.

5 patients had recurrence after resection and 9 patients after RFA. No recurrence occurred in cystic lesions patients or patients with metastatic liver nodules and patients with hepatocellular adenoma (Table 7). Mortality occurred in 4 patients due to cancer related complications. The recurrence free survival probability at 24 months was 77.05% and the survival probability at 24 months was 93.44%

DISCUSSION

The success accompanied with laparoscopic resection of benign and malignant hepatic masses with relatively low morbidity has changed

Table 5 Operative data regarding the selected procedure.

		Resection (N=37)	RFA (N=20)	Deroofing (N= 4)	χ^2	P value
Operative Time (Min)	Mean	127.2	105.3	73.33		
	SD	36.6	29.73	15.28		
	Range	70-200	60-180	60-90		
Open Conversion	Yes	5 (8.2%)	0	0	5.135	0.077
	No	32 (52.46%)	20 (32.79%)	4 (6.55%)		
Drain	Yes	34 (55.74%)	0	4 (6.55%)	44.09	0.000
	No	3 (4.92%)	20 (32.79%)	0		
Blood Loss (ML)	Mean	534	120	300		
	SD	469.6	41.04	100		
	Range	100-2000	50-200	200-400		
Blood Transfusion	Yes	23 (37.7%)	0	1	10.26	0.006
	No	14 (22.95%)	20 (32.79%)	3 (4.92%)		
No. Of Packed RBCS	Mean	0.72	0	0.333		
	SD	1.208	0	0.577		
	Range	0-5	0	0-1		
Plasma Transfusion	Yes	29 (47.54%)	8 (13.11%)	1	13.37	0.001
	No	8 (13.11%)	12 (19.68%)	3 (4.92%)		
No. Of FFP	Mean	4.12	1.2	2.67		
	SD	1.943	1.765	1.155		
	Range	0-6	0-6	2-4		

Table 6 Postoperative complications.

Post-operative complications	Patients	Percentage
No	44	-72.13%
Yes	17	-27.87%
Ascites	10	-16.39%
Liver failure	2	-3.27%
Pleural effusion	2	-3.27%
Chest infection	2	-3.27%
Biliary leak	2	-3.27%
Intra-peritoneal fluid collection	1	-1.65%
Port-site hernia	1	-1.65%
Port-site metastasis	1	-1.65%

the decision-making process for physicians involved in management of these lesions^[6].

Among the patients with HCC, 23 patients had laparoscopic liver resection while 20 patients had LRFA. There were no significant differences between those patients in terms of age, sex and the presence of associated medical conditions. This is similar to Casaccia and colleagues study where they compared the outcome of LLR and LRFA in 46 patients. The LLR and LRFA groups in their study were homogeneous with regard to age, sex and medical conditions^[7].

Several authors emphasized that increased survival of hepatic patients based on child class. According to Barcelona Clinic liver cancer (BCLC), Resection is indicated in Child A patients and RFA is indicated in Child A and B. Rao et al. suggested extending the indication for LLR to selected Child B patients. They supposed that preserving abdominal collateral venous circulation and avoid the occurrence of peritoneal adhesions via using laparoscopy in hepatic focal lesions, reduce the occurrence of ascites^[8].

In this study, resection was done in 22 patients with Child A score and one patient with Child B score while RFA was done in 13 patients with Child A and 7 patients with Child B score. The difference was significant (p 0.01) as more advanced cases are expected to have RFA rather than LLR. This is similar to Casaccia and colleagues study

Table 7 the recurrence free survival probability at different time interval.

Time (months)	Number at risk	Number failed	Survival probability
1 month	61	0	-100%
3 months	61	2	-96.72%
6 months	59	3	-91.80%
9 months	56	3	-86.88%
12 months	53	4	-80.33%
18 months	49	1	-78.69%
24 months	48	1	-77.05%

where Child was more advanced in RFA group^[9].

In our study, 39 HCC patients had one hepatic lesion; 21 had resection and 18 had RFA. This is different from Casaccia and colleagues study where number of multiple lesions was significantly higher in the LRFA group with p value < 0.001^[9].

The lesions in our patients located mostly in the peripheral lateral segments of the liver which is expected from the study design. In Yoon and colleagues study, they said that LLR could be safely performed for HCC in all segments of the liver including the postero-superior segments but with disadvantages like, longer operative time, postoperative hospital stay, a higher rate of open conversion and greater blood loss^[10].

Laparoscopic resection for benign liver disease especially hepatocellular adenoma (HA) has gained wide acceptance in recent years. In patients with < 5.0 cm adenomas, most surgeons recommend stoppage of contraceptives pills and close observation based on reports revealed tumor regression or even disappearance. However, surgical treatment is recommended in HA sized > 5.0 cm in diameter, because of malignant transformation risk, which can occur in 5-8% of patients, and also the risk for rupture and haemorrhage, observed in 21-29% of cases^[11].

In our study, HCA was found in 5 patients, all were females with past history of OCP. 2 patients had size from 3-5cm. 3 patients had size more than 5cm. non anatomical resection was done with the use

of harmonic scalpel and Endo GIA vascular stapler.

Open conversion occurred in 5 patients (10%) during resection due to massive bleeding during parenchymal transection while no conversion was needed during LRFA. This is matched with Casaccia and colleagues study where 2 LLR patients (7.69%) required open conversion due to bleeding during parenchymal transection while no conversion occurred in the LRFA group^[9]. In Lai and Tang study, 4 patients in LLR group needed open conversion due to bleeding, while 2 patients in LRFA group needed conversion to open RFA due to unfavorable position for laparoscopic RFA^[12].

There are many important advantages regarding the laparoscopic approach dealing with liver cysts. Like, early mobilization, rapid recovery, no ileus, short hospital stay, cosmetic benefits, and reduced postoperative pain. Also, there are decreased blood loss, comparable outcomes for open approach, and shorter hospital stays^[13].

Among the patients with benign cystic liver lesions in our study, Hydatid disease was found in 5 patients while the remaining 5 patients have other pathologies; 3 with simple cysts and 2 with cystadenoma. Resection was done in 4 patients with hydatid cyst and 2 patients with cystadenoma. The 3 patients with simple cysts and one patient with hydatid cyst at the dome of the liver, managed by laparoscopic deroofing.

Many surgeons prefer radical operations in cyst management, such as laparoscopic hepatectomy, resection of the cyst, or pericystectomy especially in peripheral lesions^[14]. While others prefer just cyst deroofing. Especially in central cysts or cysts close to the diaphragm and control the cyst cavity with omentoplasty^[15]. We prefer radical operations to avoid biliary leak and cyst recurrence.

Non-anatomical resection was done in 34 patients while 3 patients had bi-segmentectomy (left lateral hepatectomy) for 2 HCC and one cystadenoma. In patients with HCC, it is difficult to achieve laparoscopic anatomic resection with adequate resection margins. Liver anatomical resection for HCC, preferred for systematic removal of a segment enbloc with its portal tributaries^[16]. However, non-anatomical resection is frequently used to leave as much as parenchyma as we can. As there is impairment of liver function due to cirrhosis. SO, non-anatomical resection for HCC with safety margin was safe^[17].

In our study, 17 patients had postoperative complications in the form of ascites, liver failure, minimal pleural effusion, minimal fluid collection, biliary leak, port site metastasis and port site hernia. Ascites was found in 10 patients compared to one patient in LLR group in Casaccia study^[9]. Those patients were medically treated for ascites. In this study, liver failure was developed in 2 patients. They were all treated medically.

In this study, port site metastasis occurred in only one patient, which managed surgically. Kihara and others said that surgical resection of implanted HCC may improve survival in chosen patients with no intrahepatic disease, absent ascites, and sufficient hepatic functional reserve exists. Meticulous surgical technique can prevent tumor implantation in the abdominal wall from the start^[18].

Recurrence occurred in 14 HCC patients. 5 patients had recurrence after resection while 9 patients had recurrence after LRFA. No patient had recurrence after deroofing or resection for metastatic nodules or benign lesions.

Post resection recurrence occurred at the site of the treated tumor in 3 patients and at a different intrahepatic site in 2 patients. Those patients were treated with RFA. Post LRFA recurrence occurred at the site of the ablated tumor in 6 patients and at a different intrahepatic site in 3 patients. Those patients were treated with TACE. In Lai and Tang study, the follow-up period lasts for 29.7 ± 19.9 months in LLR

group and 35.1 ± 17.4 months in LRFA group. In LRFA group the recurrence was observed more often with no significant difference. The tumor recurred in 21 patients (27.3%) in LLR group and in 16 patients (51.6%) in LRFA group^[12].

After laparoscopic liver resection recurrence, repeat resection is difficult and even RFA can be more difficult to perform in these patients. While tumor recurrence after LRFA can be managed with surgery or various modalities of loco-regional therapy^[19].

Over the 18 months of follow-up in our study, mortality occurred in 4 patients due to cancer-related complications. The survival probability at 24 months was 93.44%. One patient died after resection while three patients died after LRFA. This is comparable to 3 patients in the LRFA group and 12 patients in the LLR group died during the follow-up in Lai and Tang study^[12].

Laparoscopic liver resection (LLR) was done in this study, as stated in Louisville statement^[20], in exophytic, subcapsular, left segment II-III-IVb or right segment V-VI HCC. Laparoscopic Radiofrequency Ablation (LRFA) is a useful way of management for the treatment of HCC regardless of its location as introduced by Jung and colleagues in 2002^[21]. In our study, we used LRFA in lesions not well indicated for LLR as lesions in the posterior and superior segments (segments IVa- VII- VIII) or near to diaphragm or gut.

CONCLUSION

Laparoscopic surgery of the liver is an alternative to open surgery providing better results and advantages in terms of survival and recurrence. Laparoscopy should be routinely considered in selected patients in centers experienced in liver surgery and in advanced laparoscopy.

CHILD score is the most important determinant of the method of laparoscopic management. LLR is adequate for CHILD A patients with low risk of recurrence and mortality. LRFA is better than LLR in CHILD B patients. It is associated with shorter operative time, less blood loss, decreased transfusion requirements, shorter hospital stay, less postoperative morbidity.

Laparoscopic deroofing is adequate for treatment of small & peripheral liver cystic disease with no risk of recurrence and shorter operative time and hospital stay. Better survival of hepatic resection on loco-regional ablation in the treatment of small HCC are confirmed also when both approaches are made laparoscopically.

REFERENCES

1. Rehman S, John SKP, French JJ, Manas DM, White SA. A Single Centre Experience of First "One Hundred Laparoscopic Liver Resections". *HPB Surg.* 2014; **2014**: 930953. [PMID: 24672143]; [PMCID: PMC3942341]; [DOI: 10.1155/2014/930953]
2. Mirnezami R, Minerzami AH, Chandrakumaran K, Hilal MA, Pearce NW, Primrose JN, Sutcliffe RP. Short- and long-term outcomes after laparoscopic and open hepatic resection: systematic review and meta-analysis. *HPB (Oxford)*. 2011 May; **13(5)**: 295-308. [PMID: 21492329]; [PMCID: PMC3093641]; [DOI: 10.1111/j.1477-2574.2011.00295.x]
3. Ogiso S, Hatano E, Nomi T, Uemoto S. Laparoscopic liver resection: Toward a truly minimally invasive approach. *World J Gastrointest Endosc.* 2015 Mar 16; **7(3)**: 159-61. [PMID: 25789085]; [PMCID: PMC4360433]; [DOI: 10.4253/wjge.v7.i3.159]
4. Koffron A, Kung R, Auffenberg G, Abecassis MM. Laparoscopic liver surgery for everyone: the hybrid method. *Surgery.* 2007 Oct; **142(4)**: 463-8; discussion 468.e1-2. [PMID: 17950337]; [DOI: 10.1016/j.surg.2007.08.006]
5. Morise Z, Kawabe N, Tomishige H, Nagata H, Kawase J, Araka-

- wa S, Yoshida R, Isetani M. Recent advances in liver resection for hepatocellular carcinoma. *Front Surg*. 2014 Jun 16; **1**: 21. [DOI: 10.3389/fsurg.2014.00021]. *eCollection* 2014. [PMID: 25593945]; [PMCID: PMC4286985]; [DOI: 10.3389/fsurg.2014.00021]
6. Koffron A, Geller D, Gamblin T, Abecassis M. Laparoscopic Liver Surgery: Shifting the Management of Liver Tumors. *Hepatology*. 2006 Dec; **44**(6): 1694-700. [PMID: 17133494]; [DOI: 10.1002/hep.21485]
 7. Casaccia M, Santori G, Bottino G, Diviaco P, Andorno E. Laparoscopic resection vs laparoscopic radiofrequency ablation for the treatment of small hepatocellular carcinomas: A single-center analysis. *World J Gastroenterol*. 2017 Jan 28; **23**(4): 653-660. [PMID: 28216972]; [PMCID: PMC5292339]; [DOI: 10.3748/wjg.v23.i4.653]
 8. Rao a, Rao G, Ahmed I. Laparoscopic or open liver resection? Let systematic review decide it. *Am J Surg*. 2012 Aug; **204**(2): 222-31. [PMID: 22245507]; [DOI: 10.1016/j.amjsurg.2011.08.013]
 9. Casaccia M, Santori G, Bottino G et al.: Laparoscopic resection vs laparoscopic radiofrequency ablation for the treatment of small hepatocellular carcinomas: A single-center analysis. *World J Gastroenterol*. 2017 Jan 28; **23**(4): 653-660. [PMID: 28216972]; [PMCID: PMC5292339]; [DOI: 10.3748/wjg.v23.i4.653]
 10. Yoon YS, Han HS, Cho JY, Ahn KS. Total laparoscopic liver resection for hepatocellular carcinoma located in all segments of the liver. *Surg Endosc*. 2010 Jul; **24**(7): 1630-7. [PMID: 20035349]; [DOI: 10.1007/s00464-009-0823-6]
 11. Herman P, Coelho F, Perini MV, Lupinacci RM, Carneiro D'Albuquerque LA, Ceconello I. Hepatocellular adenoma: An excellent indication for laparoscopic liver resection. *HPB (Oxford)*. 2012 Jun; **14**(6): 390-5. [PMID: 22568415]; [PMCID: PMC3384863]; [DOI: 10.1111/j.1477-2574.2012.00463.x]
 12. Lai E and Tang C. Radiofrequency ablation versus hepatic resection for hepatocellular carcinoma within the Milan criteria: A comparative study. *Int J Surg*. 2013; **11**(1): 77-80. [PMID: 23220487]; [DOI: 10.1016/j.ijsu.2012.11.019]
 13. Gamblin T, Holloway S, Heckman J, Geller DA. *J Am Coll Surg*. 2008 Nov; **207**(5): 731-6. [PMID: 18954786]; [DOI: 10.1016/j.jamcollsurg.2008.07.009]
 14. Chen W, Xusheng L. Laparoscopic surgical techniques in patients with hepatic hydatid cyst. *The American Journal of Surgery* 2006 **194**: 243-247.
 15. Tekin A, Kartal A, Aksoy F, Vatansev C, Kücükartallar T, Belviranli M, Sahin M, Yol S. Long-Term Results Utilizing the Unroofing Technique in Treating Hydatid Cysts of the Liver. *Surg Today*. 2008; **38**(9): 801-6. [PMID: 18751945]; [DOI: 10.1007/s00595-007-3720-4]
 16. Kim WJ, Kim KH, Shin MH, Yoon YI, Lee SG. Totally laparoscopic anatomical liver resection for centrally located tumors: A single center experience. *Medicine (Baltimore)*. 2017 Jan; **96**(4): e5560. [PMID: 28121916]; [PMCID: PMC5287940]; [DOI: 10.1097/MD.0000000000005560]
 17. Sakoda M, Ueno S, Iino S, Kiyokazu Hiwatashi K, Minami K, Kawasaki Y, Kurahara H, Mataka Y, Maemura K, Shinchi H, Natsugoe S. Survival Benefits of Small Anatomical Resection of the Liver for Patients with Hepatocellular Carcinoma and Impaired Liver Function, Based on New-Era Imaging Studies. *J Cancer*. 2016 May 25; **7**(9): 1029-36. [PMID: 27326244]; [PMCID: PMC4911868]; [DOI: 10.7150/jca.15174]
 18. Kihara K, Endo K, Suzuki K, Nakamura S, Sawata T, Shimizu T, Ikeguchi M, Tokuyasu Y, Nakamoto S. Isolated port-site metastasis of hepatocellular carcinoma after laparoscopic liver resection. *Asian J Endosc Surg*. 2017 May; **10**(2): 191-193. [PMID: 27748057]; [DOI: 10.1111/ases.12339]
 19. Pompili M, Francica G, Ponziani FR, Iezzi R, Avolio AW. Bridging and downstaging treatments for hepatocellular carcinoma in patients on the waiting list for liver transplantation. *World J Gastroenterol*. 2013 Nov 21; **19**(43): 7515-30. [PMID: 24282343]; [PMCID: PMC3837250]; [DOI: 10.3748/wjg.v19.i43.7515]
 20. Buell JF, Cherqui D, Geller DA, O'Rourke N, Iannitti D, Dagher I, Koffron AJ, Thomas M, Gayet B, Han HS, Wakabayashi G, Belli G, Kaneko H, Ker CG, Scatton O, Laurent A, Abdalla EK, Chaudhury P, Dutson E, Gamblin C, D'Angelica M, Nagorney D, Testa G, Labow D, Manas D, Poon RT, Nelson H, Martin R, Clary B, Pinson WC, Martinie J, Vauthey JN, Goldstein R, Roayaie S, Barlet D, Espot J, Abecassis M, Rees M, Fong Y, McMasters KM, Broelsch C, Busuttill R, Belghiti J, Strasberg S, Chari RS; World Consensus Conference on Laparoscopic Surgery. The international position on laparoscopic liver surgery: The Louisville Statement, 2008. *Ann Surg*. 2009 Nov; **250**(5): 825-30. [PMID: 19916210]
 21. Lee SD, Han HS, Cho JY, Yoon YS, Hwang DW, Jung K, Yoon CJ, Kwon Y, Kim JH. Safety and efficacy of laparoscopic radiofrequency ablation for hepatic malignancies. *J Korean Surg Soc*. 2012 Jul; **83**(1): 36-42. [PMID: 22792532]; [PMCID: PMC3392314]; [DOI: 10.4174/jkss.2012.83.1.36]