

Histopathological Aspects of Gastritis Patients on Gastric Mucosa: Mini-Review of Literature

Lucas Arruda Moita, Dacylla Sampaio Costa, Bruna Silva Souza, Jefferson Soares Oliveira, Daniel Fernando Pereira Vasconcelos

Lucas Arruda Moita, Dacylla Sampaio Costa, Bruna Silva Souza, Jefferson Soares Oliveira, Postgraduate Program in Biomedical Science, Federal University of Piauí, UFPI, Av. São Sebastião, 2819, Reis Veloso, Parnaíba, Piauí, Brazil

Daniel Fernando Pereira Vasconcelos, Federal University of Piauí, campus Ministro Reis Velloso, Department of Biomedicine, Av. São Sebastião, 2819, Reis Veloso, Parnaíba, PI, Brazil

Conflict-of-interest statement: The author(s) declare(s) that there is no conflict of interest regarding the publication of this paper.

Open-Access: This article is an open-access article which was selected by an in-house editor and fully peer-reviewed by external reviewers. It is distributed in accordance with the Creative Commons Attribution Non Commercial (CC BY-NC 4.0) license, which permits others to distribute, remix, adapt, build upon this work non-commercially, and license their derivative works on different terms, provided the original work is properly cited and the use is non-commercial. See: <http://creativecommons.org/licenses/by-nc/4.0/>

Correspondence to: Daniel Fernando Pereira Vasconcelos, Federal University of Piauí, campus Ministro Reis Velloso, Department of Biomedicine, Av. São Sebastião, 2819, Reis Veloso, Parnaíba, PI, Brazil.

Email: vasconcelos@ufpi.edu.br

Telephone: +55-86-994797566

Received: December 5, 2018

Revised: January 20, 2019

Accepted: January 23, 2019

Published online: February 21, 2019

ABSTRACT

Gastritis is an inflammatory condition of the gastric mucosa that has several classifications and causes. The persistence of symptoms of the acute state can lead to the atrophic development of the disease, increasing the tissue injury and consequential the development of gastric cancer. The diagnosis is made by clinical and endoscopic information as well as histopathological analysis of samples obtained from biopsy. The purpose of this review is demonstrate the

morphological aspects of gastric mucosa and gastric abnormalities found in the histopathological diagnosis of gastritis.

Key words: Gastritis; Gastric mucosa; Histology; Diagnosis

© 2019 The Author(s). Published by ACT Publishing Group Ltd. All rights reserved.

Moita LA, Costa DS, Souza BS, Oliveira JS, Vasconcelos DFP. Histopathological Aspects of Gastritis Patients on Gastric Mucosa: Mini-Review of Literature. *Journal of Gastroenterology and Hepatology Research* 2019; **8(1)**: 2785-2788 Available from: URL: <http://www.ghrnet.org/index.php/joghr/article/view/2476>

INTRODUCTION

Gastritis is considered a temporary or chronic inflammatory condition of stomach mucosa, which has several classifications, depending on its etiology and which causes high rates of morbidity in the population^[1]. In the literature, the main causes described for its development are related to stress, unhealthy diet, excessive consumption of alcoholic beverages, prolonged use of medications (anti-inflammatories and antibiotics) and mainly by *Helicobacter pylori* infection^[2,3].

The determination of the acute or chronic state of the disease occurs from the evaluation of the type of inflammatory infiltrate, the acute state is related to the presence of neutrophils in the mucosa in the other hand the chronic state is related to a predominance of macrophages, lymphocytes and plasma cells^[4].

Among the various forms that the disease may exhibit, the chronic atrophic gastritis consists of the phase of persistence of acute phase symptoms and which can be classified in several stages^[5]. The initial stage is composed of the slight involvement of the most superficial layer of the internal part of the organ that can evolve to deep lesions of mucosa with loss of glandular structures, as well as advance to the most serious stage of the disease that include in the total destruction of these structures, ulcer formation and increase the risk of gastric cancer^[5,6,7].

The diagnosis can be made based on the clinical evaluation of the patient, serological tests, endoscopic examination and the histopathological evaluation of the gastric tissue, which represents a

great relevance in the differentiation of the atrophic and non-atrophic forms of the disease^[8].

Thus, the main of this review is to report the histological aspects found in the mucosa of the stomach, as well as the possible alterations found in patients diagnosed with gastritis, in addition to assessment some diagnostic methods for this disease.

MATERIALS AND METHODS

The literature review was carried out from the analysis of scientific articles available in the SciELO, MedLine, PubMed and Science Direct databases. The following descriptors were used for the research: gastritis, gastric mucosa, morphological alterations, histopathological evaluation and diagnosis. The articles found in the research were analyzed according to the following inclusion criteria: (1) Studies that presented relevant information on the subject; (2) Publications until november 2018 with detailed description of the histopathological evaluation of gastritis; (3) Articles indexed in Portuguese, Spanish and English. At the end, as shown in Figure 1, twenty-one articles were selected to which they were read in their entirety, and information was extracted that could fill this review.

THE GASTRIC MUCOSA

The gastric mucosa is composed of a layer of superficial epithelial cells strongly connected by intercellular junctions, such as GAP type, in addition to a portion of lamina propria wich is highly vascularized and innervated^[9]. The gastric epithelium has secretory glandular cells of substances and hormones and that are fundamental in the digestion process and are necessary to the mechanism of defense of the mucosa against aggressive agents^[10].

Due to the arrangement of these cells in the epithelium, the gastric mucosa can be divided into three regions: cardiac, oxyntic and pyloric. In the cardiac region, the mucus secreting cells are concentrated. In the oxyntic region, there are parietal (hydrochloric acid) and peptic (pepsinogen secreting) cells, as well as endocrine cells such as somatostatin secretory cells and enterocromaffin (histamine secreting) cells. Finally, in the pyloric region, peptic cells, D cells and G cells (gastrin producing) can be found^[11,12].

HISTOPATHOLOGICAL ALTERATIONS FOUND IN GASTRITIS

The presence of the inflammatory infiltrate in the lamina propria, whether mononuclear or polymorphic cells, is the main finding of the non-atrophic state. Neutrophilic infiltration can indicate intense tissue damage to the mucosa. The presence of focal or dispersed

lymphocytes and granulocytes in the glandular epithelium may be indicative of chronic gastritis, which can also be found intra-glandular, forming nodules, characterizing a primary stage of gastric lymphoma^[13].

The persistence of the inflammatory infiltrate may lead to the progression of the disease to the atrophic state. At this stage, analysis of the biopsy specimen reveals extensive loss of glandular epithelium, which can progress to dysplasia, epithelial tissue metaplasia, lamina propria fibrosis or even to adenocarcinoma^[14,15].

In special gastritis, such as alcohol abuse and anti-inflammatory drugs, the formation of ulcers and edema in the mucosa can be seen soon in the endoscope examination, while in histology the loss of epithelial cells can be observed due to intense inflammatory infiltration and bleeding outbreaks due to loss of epithelium^[16] (Table 1).

DIAGNOSIS AND HISTOPATHOLOGICAL EVALUATION

The diagnosis of gastritis begins with the evaluation of the clinical data of the patient (symptoms, age and family history) and through endoscopic examination. The confirmation and classification of the gastritis is given from the histopathological evaluation of the sample of tissue removed in the examination endoscope^[4].

Although it does not have a universal classification system for gastritis, in the literature one can find some systems for evaluation, such as the Sidney system^[17] and the Operative Link for Gastritis Assessment (OLGA) system^[18]. The analyzes performed by these systems are restricted to etiological, topographic, morphological biopsy data and histological findings. Thus, according to the findings,

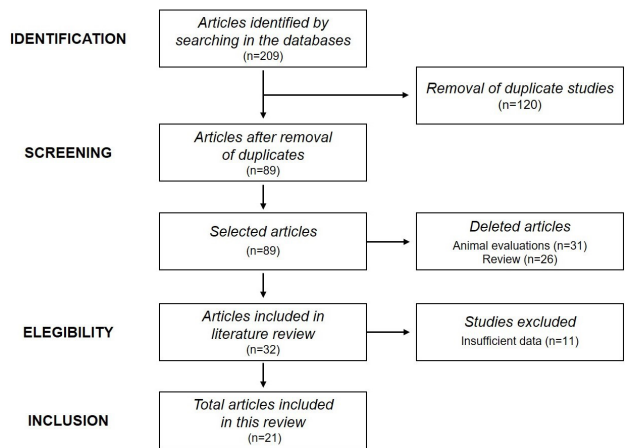


Figure 1 Flowchart used to identify, select and include studies in this review.

Table 1 Main changes reported in studies included in this review.

| Classification | Alterations found on gastric tissue | Authors | Titles |
|---|--|---|---|
| Non-atrophic gastritis | Mononuclear and polymorphic leukocytes on lamina propria | ASAKA et al[13], 1995 | Relationship between Helicobacter pylori infection, atrophic gastritis and gastric carcinoma in a Japanese population |
| Chronic / Atrophic gastritis | Focused, dispersed or intra-glandular lymphocytes and granulocytes with nodule formation | ASAKA et al[13], 1995 | Relationship between Helicobacter pylori infection, atrophic gastritis and gastric carcinoma in a Japanese population |
| | Intense inflammatory infiltrate on the mucosa with glandular loss, dysplasia and metaplasia of the epithelium, besides fibrosis of the lamina propria and formation of adenocarcinomas | DIXON et al[14], 1996 STEMMERMANN, 1994 [15] | Classification and grading of gastritis Intestinal metaplasia of the stomach |
| Special gastritis (Caused by alcohol and anti-inflammatory drugs) | Presence of ulcers and edema in the gastric mucosa with intense inflammatory infiltration, loss of epithelial cells and with haemorrhagic focus | WOLFE & SANCHS, 2000 [16] | Acid supression: optimizing therapy for gastroduodenal ulcer healing, gastroesophageal reflux disease and stress-related erosive syndrome |

the classification of the disease is directed^[19].

Created in 1990, the Sydney system standardized the language to be adopted by the pathologists in relation to the inflammatory alterations found and described from the findings of the gastric biopsies. This system consisted in the evaluation of five histological variables, the chronic inflammation, neutrophilic activity, glandular atrophy, intestinal metaplasia and presence of *H. pylori*, from biopsies made from the regions of the antrum and the body of the stomach. For each parameter to be evaluated, presence or absence was described, besides being classified in levels (mild, moderate or marked) if present in the tissue^[17,20].

The quantity and standardization of biopsy sites, as well as some nomenclatures adopted by the system, generated some challenges through the clinical pathologists, resulting in the reformulation of the system and subsequent creation of the OLGA system. In 1996, the system considered adding biopsy of the region of angular notch in the evaluation, in addition to the other regions defined in the old system of Sydney, in view of the endoscopic reports that consisted of a high degree of mucosal atrophy and intestinal metaplasia, as well as presence of neoplastic lesions. In addition, the system introduced in the analyzed variables that when establishing chronic gastritis should be correlated with its region of predominance (body or antrum), as well as whether the atrophy and metaplasia present were diffuse or multifocal^[14].

The OLGA system later appeared as a new proposal for evaluation of gastritis, where the analysis consisted of the observation of the extent of gastric atrophy, which is a result of the advanced stage of the disease, combined with the lesion sites evaluated. The atrophy is the main parameter evaluated in all biopsy regions, which is performed from the analysis of total mucosal thickness. Other secondary parameters, such as glandular atrophy (antrum and body region) and glandular shrinkage (lamina propria fibrosis and intestinal metaplasia in the region of the angular notch), are also analyzed, and for each finding a score value is assigned. In the evaluation of glandular atrophy, each sample is evaluated from the percentage of glandular loss. In both evaluations a score is determined for each analyzed region, being: (0) when there is 0% of atrophy; (1) when there is 1-30% atrophy (mild); (2) when there is 31-60% atrophy (moderate); (3) when there is > 60% atrophy (severe). From this separate evaluation of score, a general value of atrophy is obtained, which leads to a determined stage of gastritis^[18,21].

The histopathological report should contain essential information that allows the identification of the sample used in the biopsy, such as the quantity and gastric sites from which the sample was obtained, according to endoscopic identification. In addition, clinical information of the patient, such as history or current treatment, should be reported along with endoscopic findings, if any. The description of the evaluation should mention all the findings, as well as to correlate the regions analyzed and the lesions found, as well as to provide semi-quantitative values for the following findings: mononuclear infiltrate, polymorphic infiltrate, glandular atrophy and *H. pylori* foci or absent). At the end, the possible etiology of the disease, based on the manifestations, and the stage of gastritis, based on the OLGA system, should be evaluated^[21].

CONCLUSION

Knowledge about alterations found in endoscopy and histopathological analysis of biopsy samples, such as edema, ulcer, intense inflammatory infiltration and loss of epithelial cells, can be indicated as an effective strategy in the diagnosis and prognosis of

the patient, allowing the non-progression of the disease and reducing the risk of developing cancer in gastric tissue.

REFERENCES

- Borda A, Estremera F. Dyspepsia: Diagnostic-therapeutic classification and management. *Medicine* 2016; **12(2)**: 57-65. [DOI: 10.1016/j.med.2016.01.010]
- Awaad AS, El-meligy RM, Solliman GA. Natural products in treatment of ulcerative colitis and peptid ulcer. *Journal of Saudi Chemical Society* 2013; **17**: 101-124. [DOI: 10.1016/j.jscs.2012.03.002]
- Tarnawski AS. Cellular and molecular mechanisms of gastrointestinal ulcer healing: state of the art 2010. *Gastroenterologia Polska/Gastroenterology* 2010; **17(3)**: 171-179.
- Angós R. Gastritis. *Medicine - Programa de Formación Médica Continuada Acreditado* 2016; **12(2)**: 66-73. [DOI: 10.1016/j.med.2016.01.011]
- Módena JLP, Pereira LCC. *Carcinoma gástrico precoce*. In: SOBED, Endoscopia digestiva. 3ed. Rio de Janeiro: MEDSI; 2000. p 402-27.
- Mowat C, Carswell A, Wirz A, McColl KE. Omeprazole and dietary nitrate independently affect levels of vitamin C and nitrite in gastric juice. *Gastroenterology* 1999; **116**: 813-22. [PMID: 10092303]
- Vannella L, Lahner E, Annibale B. Risk for gastric neoplasias in patients with chronic atrophic gastritis: Acritical reappraisal. *World Journal of Gastroenterology* 2012; **18(12)**: 1279-1285. [DOI: 10.3748/wjg.v18.i12.1279]
- Dore MP, Graham DY. Ulcers and gastritis. *Endoscopy* 2009; **42(1)**: 38-41. [DOI: 10.1055/s-0029-1215314]
- Tulassay Z, Herszényi L. Gastric mucosal defense and cytoprotection. *Best Practice & Research: Clinical Gastroenterology* 2010; **4**: 99-108. [DOI: 10.1016/j.bpg.2010.02.006]
- Ramsay PT, Carr A. Gastric acid and digestive physiology. *Surgical Clinics of North America* 2011; **91(5)**: 977-982. [DOI: 10.1016/j.suc.2011.06.010]
- Dockray GJ. Gastrin and gastric epithelial physiology. *The Journal of Physiology* 1999; **518(2)**: 315-24. [DOI: 10.1111/j.1469-7793.1999.0315p.x]
- Jain KS, Shah AK, Bariwal J, Shelke SM, Kale AP, Jagtap JR, Bhosale AV. Recent advances in proton pump inhibitors and management of acid-peptic disorders. *Bioorganic & Medicinal Chemistry* 2007; **15**: 1181-1205. [DOI: 10.1016/j.bmc.2006.07.068]
- Asaka M, Kato M, Kudo M, Katagiri M, Nishikawa K, Yoshida J, Takeda H, Miki K. Relationship between *Helicobacter pylori* infection, atrophic gastritis and gastric carcinoma in a Japanese population. *European Journal of Gastroenterology & Hepatology* 1995; **7(1)**: 7-10. [PMID: 8574741]
- Dixon MF, Genta RM, Yardley JH, Correa P. Classification and grading of gastritis. The updated Sydney System. International Workshop on the Histopathology of Gastritis, Houston 1994. *American Journal Of Surgical Pathology* 1996; **20(10)**: 1161-81. [PMID: 8827022]
- Stemmermann GN. Intestinal metaplasia of the stomach. A status report. *Cancer* 1994; **74(2)**: 556-64. [PMID: 8033033]
- Wolfe MM, Sachs G. Acid suppression: Optimizing therapy for gastroduodenal ulcer healing, gastroesophageal reflux disease and stress-related erosive syndrome. *Gastroenterology* 2000; **118(2)**: 9-31. [DOI: 10.1016/S0016-5085(00)70004-7]
- Misiewicz JJ. The Sydney System: a new classification of gastritis. Introduction. *Journal of Gastroenterology and Hepatology* 1991; **6(3)**: 207-8. [DOI: 10.1111/j.1440-1746.1991.tb01467.x]
- Rugge M, Meggio A, Pennelli G, Pisciolli F, Giacomelli L,

- Pretis GD, Graham DY. Gastritis staging in clinical practice: the OLGA staging system. *Gut* 2007; **56**: 631-6. [DOI: 10.1136/gut.2006.106666]
19. Sipponen P, Price AB. The Sydney System for classification of gastritis 20 years ago. *Journal of Gastroenterology and Hepatology* 2011; **26**(1): 31-4. [DOI: 10.1111/j.1440-1746.2010.06536.x]
 20. Price AB. The Sydney System: histological division. *Journal of Gastroenterology and Hepatology* 1991; **6**: 209-22. [DOI: 10.1111/j.1440-1746.1991.tb01468.x]
 21. Rugge M, Pennelli G, Pilozi E, Fassan M, Ingravalle G, Russo VM, Mario FD. Gastritis: The histology report. *Digestive and Liver Disease* 2011; **43**: 373-84. [DOI: 10.1016/S1590-8658(11)60593-8]