

Journal of Gastroenterology and Hepatology Research

Online Submissions: <http://www.ghrnet.org/index./joghr/>
doi: 10.17554/j.issn.2224-3992.2019.08.823

Journal of GHR 2019 April 21; 8(2): 2864-2870
ISSN 2224-3992 (print) ISSN 2224-6509 (online)

ORIGINAL ARTICLE

Dengue Virus and Yellow Fever Virus Damage the Liver: A Systematic Review About the Histopathological Profiles

Dacylla Sampaio Costa, Lucas Arruda Moita, Even Herlany Pereira Alves, Ana Clara Silva Sales, Raiza Raianne Luz Rodrigues, Juliana Gomes Galeno, Thiago Nobre Gomes, Gustavo Portela Ferreira, Daniel Fernando Pereira Vasconcelos

Dacylla Sampaio Costa, Lucas Arruda Moita, Even Herlany Pereira Alves, Ana Clara Silva Sales, Raiza Raianne Luz Rodrigues, Juliana Gomes Galeno, Thiago Nobre Gomes, Gustavo Portela Ferreira, Daniel Fernando Pereira Vasconcelos, Postgraduate Program in Biomedical Science, Federal University of Piauí- UFPI, Av. São Sebastião, 2819, Reis Veloso, Parnaíba, Piauí, Brazil

Conflict-of-interest statement: The authors declare that there is no conflict of interest regarding the publication of this paper.

Open-Access: This article is an open-access article which was selected by an in-house editor and fully peer-reviewed by external reviewers. It is distributed in accordance with the Creative Commons Attribution Non Commercial (CC BY-NC 4.0) license, which permits others to distribute, remix, adapt, build upon this work non-commercially, and license their derivative works on different terms, provided the original work is properly cited and the use is non-commercial. See: <http://creativecommons.org/licenses/by-nc/4.0/>

Correspondence to: Dacylla Sampaio Costa, Postgraduate Program in Biomedical Science, Federal University of Piauí- UFPI, Av. São Sebastião, 2819, Reis Veloso, Parnaíba, Piauí, Brazil.
Email: dacyllasampaio@hotmail.com
Telephone: +55 86 99951-5949

Received: February 13, 2019

Revised: March 13, 2019

Accepted: March 17, 2019

Published online: April 21, 2019

ABSTRACT

Dengue virus (DENV) and Yellow Fever virus (YFV) are Flaviviruses transmitted by arthropod vectors that stand out as a major public health problem worldwide due to their high incidence rates and morbidity. They are related to the development of severe alterations, mainly associated with hemorrhagic and hepatic damages. In view of this information, the objective of this review is to describe the data

available in the literature on the main histopathological alterations in the liver after infection by DENV and YFV. For so, a literature search was conducted in the PubMed and ScienceDirect databases for the selection of articles published between 2005 and 2018 with relevance on the subject under study. The search resulted in the selection of 20 articles, of which 15 assessed the histopathological alterations in the liver after infection by DENV and 5 evaluated liver tissue damage after YFV infection. All studies demonstrated the presence of the main tissue abnormalities typical of dengue and yellow fever infection, showing a greater severity of hepatic damage related to YF infection. The main histopathological alterations in the liver after infection by these arboviruses have been demonstrated, however, the knowledge regarding some tissue damage in the liver is limited. There is, therefore, the need for further studies to clarify the pathogenesis of the arboviruses under study and the role in the progression and severity of the lesions, especially related to liver damage.

Key words: Liver damage; Histology; Flavivirus; Dengue; Yellow fever

© 2019 The Author(s). Published by ACT Publishing Group Ltd. All rights reserved.

Costa DS, Moita LA, Alves EHP, Sales ACS, Rodrigues RRL, Galeño JG, Gomes TN, Ferreira GP, Vasconcelos DFP. Dengue Virus and Yellow Fever Virus Damage the Liver: A Systematic Review About the Histopathological Profiles. *Journal of Gastroenterology and Hepatology Research* 2019; 8(2): 2864-2870 Available from: URL: <http://www.ghrnet.org/index.php/joghr/article/view/2521>

INTRODUCTION

Members of the genus Flavivirus group are the viruses responsible for causing a range of diseases transmitted by hematophagous arthropod vectors, including Yellow Fever virus (YFV) and the four antigenically distinct serotypes of Dengue virus (DENV 1-4)^[1,2]. DENV is an arbovirus responsible for generating an extensive economic and social impact, with an estimated 390 million infections a year^[3]. Yellow fever is an acute febrile infectious disease with a high mortal-

ity rate that is considered as one of the most important emerging or reemerging arboviruses in Brazil and in the world^[4,5,6,9]. Most of the infections caused by DENV and YFV are asymptomatic and, when symptomatic, can evolve to cure or to hemorrhagic clinical conditions and hepatic impairment^[2,7].

Infection by these arboviruses causes involvement of several organs, especially the liver^[8]. Severe liver involvement is one of the important risk factors in patients who deacease from infection with severe Dengue and Yellow fever^[7,9]. Evidence shows that the liver is an important organ of replication and pathogenesis of infection by DENV and YFV, although its mechanisms are not yet fully understood^[10,11]. Therefore, further studies are needed to elucidate the exact mechanisms of liver tissue damage^[12].

Damage to the liver alters the normal functioning of the organ and consequently affects other interconnected organs. This event usually occurs in severe forms of DENV, characterized as Dengue Hemorrhagic Fever (DHF) and Dengue Shock Syndrome (DSS)^[4,13]. In YFV infection, the morphological diagnosis, based on alterations characteristic of liver damage, is one of the most important methods in the identification of the disease and its degree of impairment, so that there is correct management of the patient^[14].

Based on the information presented, this review covers the current knowledge of the main histopathological alterations in the liver after viral infections of Dengue and Yellow Fever viruses from different histological methods in order to clarify the progression and pathogenesis of these Flaviviruses. Furthermore, it highlights the aspects used to assess the degree of hepatic lesions generated after viral infections by the virus under study.

MATERIALS AND METHODS

The present study is a systematic review on the main histological alterations associated with liver damage after infection by DENV and YFV. In this study, articles published and indexed in the PubMed and ScienceDirect databases with the descriptors liver damage, histology, flavivirus, dengue and yellow fever were selected.

The articles selected corresponded to the following inclusion criteria: (1) articles published in English, (2) fully available in the selected databases (3) with publication period from 2005 to 2018 and (4) articles that addressed information relevant to the theme proposed. Articles based on human and animal studies were included. In addition, exclusion criteria were established for the exclusion of review articles or with publication prior to the year established in the search and studies that did not present information relevant to the topic addressed. In detail, for the selection of articles, the criteria were divided into: identification, screening, eligibility and inclusion. In the identification process, the articles in the database were selected and those that appeared in duplicates were removed. Upon screening, the articles were selected according to the pre-established inclusion criteria.

For the eligibility of publications, each title and abstract was read in detail to confirm relevance and fit the theme under study of this research. In the end, the articles read in full and that presented information that could compose the review were selected. The selection process of the articles is shown in figure 1.

RESULTS AND DISCUSSION

From the search of data in the literature, 497 articles were found in the databases ScienceDirect (412) and Pubmed (85), of which 477 were excluded because they did not meet the pre-established criteria and because they did not have enough data to compose the review. Of

the total, 20 articles published in the 2005-2018 period were included in this study. Among the articles analyzed, 15 evaluated the liver histopathological changes in experimental and human models after infection by DENV and 5 evaluated histopathological changes after YFV infection. All articles selected used normal histological methodology, using light microscopy and tissue staining using hematoxylin-eosin stain. This methodology is described as the standard technique for analysis of histological changes. From the articles selected for the review, 3 analyzed ultrastructural changes using electron microscopy methodology and 5 quantitatively evaluated the degree of liver damage generated by DENV and YFV. Additionally, 4 articles evaluated the presence of viral antigens in the hepatic tissue by methodology described as immunohistochemistry.

HISTOPATHOLOGICAL ALTERATIONS FOUND IN THE LIVER AFTER INFECTION WITH DENGUE AND YELLOW FEVER VIRUS

According to the results of the studies, it was possible to observe a greater evidence of hepatic histopathological alterations such as steatosis, hepatocyte swelling, necrosis, areas of hemorrhage, edema and inflammatory infiltrate in experimental models infected with DENV and YFV, similar to the changes described in the infection by these viruses^[10,15-19]. The main histopathological changes are described in Table 1. Among the histological characteristics present in YFV-infected humans, hepatocellular ballooning, Councilman corpuscle and the presence of apoptotic acidophilic bodies are the most evident findings in these patients^[14,20,21]. The approach of the histological alterations of YFV and DENV is of great importance for the differential diagnosis, mainly because both diseases cause clinical manifestations of similar acute phase, but the hepatic damages in YFV infections are more serious and with a higher mortality rate when compared to DENV^[20]. Diagnosis based on the YFV morphological changes is currently the gold standard for identifying the infection, based on specific morphological characteristics of liver damage, as mentioned previously, and which are observed in almost all human cases^[14,22]. It is worth mentioning that the severity of hepatic changes is associated with circulating virus strain and host susceptibility^[23].

The presence of hepatocellular ballooning can be attributed to interference with mechanisms of control of water and ion concentrations, which may result from direct action of the YFV virus on the cell membrane or as a consequence of the immune response generated by the host^[14]. Another clear finding in the infection, called Councilman's corpuscles, is usually found in hepatocytes, secondary to the development of apoptosis, where degeneration of the nucleolus occurs and the protein resulting from the apoptotic process remains accumulated^[20].

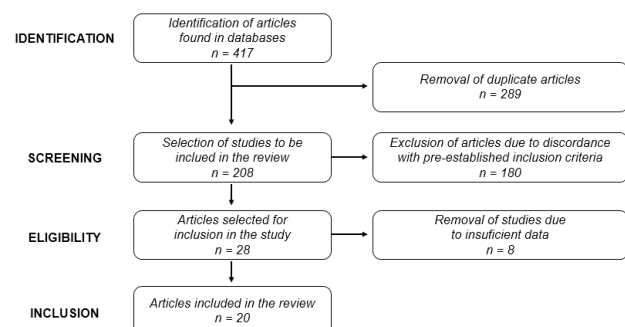


Figure 1 Flowchart showing the process of searching and selecting the reported studies.

Table 1 Main histopathological alterations caused by DENV and YFV reported in studies included in this review

Author	Title	Virus	Histological method	Main alterations histopathological
Salina [18]	Impact of dengue virus (serotype DENV-2) infection on the liver of BALB/c mice: a histopathological analysis	DENV	Light microscopy: Hematoxylin & Eosin	Presence of vacuoles, microvesicular steatosis in hepatocytes, hyperplasia of Kupffer cells (KC), hyperplasia and increase in binucleated hepatocytes and apoptotic cells. Hemorrhagic areas associated with infiltration of chronic inflammatory cells and necrosis
Paes [17]	Hepatic damage associated with dengue-2 virus replication in liver cells of BALB/c mice	DENV	Light microscopy: Hematoxylin & Eosin, Masson's trichrome or PAS	Presence of steatosis (micro and macro), hepatocyte swelling, inter and intracellular edema, hemorrhage and necrosis with inflammatory infiltrate, erythrophagocytosis that included mainly neutrophils, swollen binucleate hepatocytes and necrosis in sinusoidal capillaries
			Electron microscopy: Methylene blue solution and blue II	Hepatocytes with macrovesicular steatosis, numerous inflammatory cells (mainly lymphocytes and Kupffer cells) and hyperplastic swollen and binucleated hepatocytes. Dilated sinusoidal capillaries (edema and plasma leakage)
Milligan [25]	A lethal model of disseminated dengue virus type-1 infection in AG129 mice.	DENV	Light microscopy: Hematoxylin & Eosin	Pleomorphic nuclei, inflammation and areas of focal necrosis
Kularatne [12]	Extensive haemorrhagic necrosis of liver is an unpredictable fatal complication in dengue infection: a postmortem study	DENV	Light microscopy: Hematoxylin & Eosin	Extravasation of erythrocytes and disintegration of hepatocyte nuclei suggestive of massive necrosis of liver cells. Presence of micro and macrovesicular steatosis, infiltrates of acute inflammatory mononuclear cells
Lin [10]	Liver injury caused by antibodies against dengue virus nonstructural protein 1 in a murine model	DENV	Light microscopy: Hematoxylin & Eosin	Apoptotic cells around the vessels in the portal vein of the liver, cellular infiltration, necrotic body and formation of vesicles
Oliveira [39]	Pathologic Study of a Fatal Case of Dengue-3 Virus Infection in Rio de Janeiro, Brazil	DENV	Light microscopy: Hematoxylin & Eosin	Infiltration of mononuclear cells around the portal space, focal vacuolization in the hepatocyte cytoplasm and hemorrhagic congestion
Drumond [15]	Phylogenetic analysis of Dengue virus 1 isolated from South Minas Gerais, Brazil	DENV	Light microscopy: Hematoxylin & Eosin	Presence of steatosis, inflammatory infiltrate around the central veins and also foci of edema, hemorrhage and necrosis
Póvoa [24]	The pathology of severe dengue in multiple organs of human fatal cases: histopathology, ultrastructure and virus replication	DENV	Electron microscopy: Methylene blue solution and blue II	Numerous inclusions of large lipid droplets in hepatocytes, typical of macrosteatosis, nuclear vacuolar degeneration
			Light microscopy: Hematoxylin & Eosin	Presence of lipids in hepatocytes with small fat vacuoles around the nucleus (microsteatosis) or large vacuoles with displacement of the nucleus to the periphery of the cell (macrosteatosis), focal areas of necrosis with the presence of mononuclear infiltrates. Haemorrhage and edema, numerous hyperplastic macrophages in sinusoidal capillaries
Gonçalves [33]	Imunocompetent mice model for dengue virus infection	DENV	Light microscopy: Hematoxylin & Eosin	Microsteatosis in the liver and presence of inflammatory lymphocyte infiltrate
França [27]	A BALB/c mouse model shows that liver involvement in dengue disease is immune-mediated	DENV	Light microscopy: Hematoxylin & Eosin	Cellular infiltrate consisting mainly of lymphocytes and increased number of Kupffer cells (hyperplasia), degree of inflammation, with inflammatory foci extending to the midzonal areas

Barth [37]	Morphological studies in a model for dengue-2 virus infection in mice	DENV	Light microscopy: Hematoxylin & Eosin	Focal swollen hepatocytes, endothelial cell and hepatocyte vacuolization, dilated sinusoidal capillaries, vacuolization and swelling of groups of hepatocytes, inflammatory cells and interstitial infiltrate of inflammatory cells
			Electron microscopy: Methylene blue solution and blue II	Inflammatory cells within a sinusoidal capillary, hepatocytes with rarefied cytoplasm and swelling of the mitochondria, presence of inflammatory cells, a platelet within a sinusoidal capillary and hepatocyte steatosis
Aye [40]	Pathologic highlights of dengue hemorrhagic fever in 13 autopsy cases from Myanmar	DENV	Light microscopy: Hematoxylin & Eosin	Moderate congestion of hepatic sinusoids with different degrees of cell death. Steatosis in the hepatic lobes and swelling of hepatocytes. Presence of balloon in the cytoplasm of hepatocytes and anucleated cells and hyperplasia of Kupffer cells
Paes [23]	Liver injury and viremia in mice infected with dengue-2 virus	DENV	Light microscopy: Hematoxylin & Eosin	Slightly increased hepatocytes due to vacuolization, diffuse steatosis in hepatocytes, numerous hyperplastic Kupffer cells in capillary sinuses and edema. Diffuse necrosis of hepatocytes around portal areas with increased monocyte cell infiltration and presence of apoptotic cells
Wang [19]	Inhibitory effect of glutathione on oxidative liver injury induced by dengue virus serotype 2 infections in mice	DENV	Light microscopy: Hematoxylin & Eosin	Hepatic sections showed hemorrhage, infiltration of inflammatory cells, edema and congestion
Sreekanth [26]	Role of ERK1/2 signaling in dengue virus-induced liver injury Gopinathan	DENV	Light microscopy: Hematoxylin & Eosin	Signs of liver damage including the hepatocyte balloon, cytoplasmic vacuolization, and cell necrosis
Fernandes [20]	Outbreak of Yellow Fever among Nonhuman Primates, Espirito Santo, Brazil, 2017	YFV	Light microscopy: Hematoxylin & Eosin	Midzonal lytic necrosis, apoptotic bodies and inflammation. Hepatocellular lytic necrosis, with multiple apoptotic bodies of Councilman-Rocha Lima. Presence of massive hemorrhage, macrovacuolar steatosis and inflammatory infiltrates
Quaresma [22]	Hepatocyte lesions and cellular immune response in yellow fever infection	YFV	Light microscopy: Hematoxylin & Eosin	Lytic necrosis, steatosis and apoptosis, accompanied by mild-to-moderate inflammatory infiltrate, consisting predominantly of mononuclear cells
Leal [21]	Frequency of histopathological changes in Howler monkeys (<i>Alouatta</i> sp.) naturally infected with yellow fever virus in Brazil	YFV	Light microscopy: Hematoxylin & Eosin	Apoptosis of hepatocytes (Councilman corpuscles), midzonal necrosis, hepatocyte steatosis, hemorrhage, infiltration of inflammatory mononuclear cells
Dias Junior [14]	Fulminant hepatic failure in northern Brazil: morphological, immunohistochemical and pathogenic aspects of Lábrea hepatitis and yellow fever	YFV	Light microscopy: Hematoxylin & Eosin	Midzonal necrosis, apoptosis, midzonal acidophilic bodies. Microvesicular steatosis, inflammatory infiltrate, mainly by lymphocytes, binucleated hepatocytes and degeneration by ballooning in hepatocytes
Engelmann [16]	Pathophysiologic and Transcriptomic Analyses of Viscerotropic Yellow Fever in a Rhesus Macaque Model	YFV	Light microscopy: Hematoxylin & Eosin	Extensive necrosis of hepatocyte hemorrhagic foci, along with eosinophilic degeneration of liver cells

Kupffer cells, KC; Dengue virus (DENV) and Yellow Fever virus (YFV).

In relation to the hepatic tissue damage reported in humans infected by DENV, most studies have demonstrated some common characteristics of the livers infected with this virus, especially highlighting the presence of necrosis and microvesicular steatosis^[12,15,24]. The presence of necrosis is a common finding among studies in both humans and in models of mice infected by DENV and YFV^[2,12,15,22,25,26]. Histopathological evidence suggests that severe forms of DENV are determined by the presence of hepatocellular necrosis, usually delimited to zones I and II of hepatic acini^[27]. However, most of the histopathological aspects, not only necrosis, were evident in zone II of hepatic acini, due to the low presence of oxygen attained in this region^[17,23,27]. The same pattern of lesion in the middle zone was also observed in other arboviral diseases, as in cases of patients infected with YFV, where greater damage was observed associated to zone II, described as a median area in the hepatic tissue and presenting a higher concentration of antigen yellow fever^[14,20,21,28]. In contrast, the study by Póvoa^[24] demonstrated a greater degree of liver damage associated with only zone I, in which it presents itself as an oxygen-rich area.

In DENV and YFV infection, detection of microvesicular steatosis in most studies is conditioned by changes in lipid metabolism, most of which is in the development of hepatomegaly^[17,22]. This finding was reversible, progressively reduced and possibly associated with the development of the milder form of dengue (DF). In fact, some studies have observed a strong association between the development of lipid vacuoles and viral replication in hepatocytes, which may be explained by the aid in the formation of the capsid and non-structural proteins^[17,29]. Some studies have demonstrated the presence of macrovesicular steatosis associated with more severe conditions, especially during human infection, but less evidence^[12,24]. The presence of these lipid vacuoles may influence the spread of the virus to other regions of the liver tissue, as well as progression to other organs^[24].

The presence of hemorrhage and edema in the majority of the studies, which is characteristic of the severe forms of DENV (DHF / DSS), is possibly associated with an increase in the permeability of blood vessels. It consequently causes extravasation of plasma, leading to the development of these alterations^[24,30,31]. In fact, plasma leakage is one of the major complications of severe dengue^[32]. Approximately one-third of patients with dengue fever may have hemorrhagic manifestations, possibly related to platelet count^[27]. In the study performed by Sakinah^[18], we observed the displacement of endothelial cells that can travel with plasma leakage and bleeding in these areas with release of these cells in the blood vessels, a finding commonly present during DHF / DSS frames^[18].

Other histopathological changes such as the presence of a cellular infiltrate consisting mainly of lymphocytes and an increased number of Kupffer cells, observed in some studies by DENV and YFV, may be associated with the development of immune response against the presence of the viral agent inside the cells, leading to the release of a range of inflammatory cytokines in response to damage caused by the virus^[10,14,22,33].

In the study conducted by Paes^[17], erythrophagocytosis was observed in hepatic tissues of animal experimental models, when stained by Masson's Tricom. This is a rare finding and may possibly be related to the development of severe forms of dengue^[34]. According to previous studies, the presence of this finding was limited to bone marrow macrophages in humans^[35,36]. In fact, this study was the first to describe the presence of erythrophagocytosis in the liver of infected mice^[17].

Another prominent feature of viral infection by DENV and YFV is apoptosis. The presence of this finding in hepatocytes, Kupffer cells

and endothelial cells is mainly related to the cytopathic effect inherent to viral replication and development of immune response of the host, in order to neutralize the virus present and interfere in the replication process^[17,18,21]. In studies with animals and humans infected with YFV, apoptosis was associated with the presence of acidophilic bodies, which is characterized by being one of the most important changes in the virus infection^[14,28]. This finding may be of great importance in the identification of YFV and, as it is absent in cases of DENV, can be used as a marker for differential diagnosis^[28].

Ultrastructural analyses through electron microscopy performed in three studies were similar to most of the results found in the histopathological analyses, where the presence of swollen hepatocytes, vacuolization of hepatocytes and endothelial cells, as well as the presence of inflammatory infiltrates of lymphocytes^[17,24,37]. Electron microscopy analysis also revealed dilated sinusoidal capillaries, numerous inclusions of large lipid droplets within the hepatocytes, typical of macrovesicular steatosis^[24]. Other hepatic alterations, such as vacuolar degeneration of the nucleus and the presence of swollen mitochondria, were observed at a lower frequency, possibly suggesting the onset of apoptosis. These results are similar to those described in human studies, but the analysis of these liver changes in humans is currently limited^[24,38].

SEMI-QUANTITATIVE AND IMMUNOHISTOCHEMICAL ANALYSIS OF HEPATIC ALTERATIONS CAUSED BY DENGUE AND YELLOW FEVER VIRUSES

The immunohistochemical analysis performed in four studies showed the presence of viral antigens, such as the NS3 non-structural protein, in hepatocytes, endothelial cells and Kupffer cells, confirming the replication of the virus in these cells and emphasizing that they can be target cells for replication of DENV^[24,37]. These findings were confirmed by *in situ* hybridization, from the detection by specific probes to the negative strand of dengue RNA, which is present only within cells during replication and is a tool used to detect viral tropism. The results demonstrated hybridization in the hepatocytes, which confirms the replication of the virus in these cells^[24]. Further analyses, based on the detection of viral antigens primarily in hepatocytes, endothelial cells and Kupffer cells, were also found, correlating with studies described in fatal human cases^[30,39]. Antigen or non-structural proteins of E, NS1 and NS3 viruses were identified in the cytoplasm of hepatocytes and Kupffer cells in all study patients^[40]. Nevertheless, the NS1 non-structural protein was not visualized in capillaries, suggesting that DENV infection did not cause direct endothelial damage^[40].

In addition to the histopathological findings, five studies performed semi-quantitative analyses of liver alterations after infection by DENV and YFV. In the study by Paes^[17], the analyses were performed according to the degree of steatosis, hepatocyte swelling, necrosis, hemorrhage and intercellular edema, using a subjective scale ranging from 0 to 4 (0: no alteration, 1: mild and focally, 2: moderate and focally, 3: severe and focal, and 4: severe and diffuse), according to degree of injury. The histopathological alterations were evaluated according to the progression of the disease, being evaluated from the first day of infection to the 49th day. Among the alterations quantified, the statistically significant peak of necrosis occurred only on the seventh day of infection and regressed during the later days, which corroborates the information described in the literature, highlighting a longer period of viremia and viral replication after the seventh day

of infection^[3,41]. Peak intercellular edema was statistically significant only on the 14th day of infection. Other alterations were mild to moderate. Nevertheless, on the 49th day after infection, all hepatic lesions reduced drastically, presenting levels similar to those observed in control rats^[17].

In contrast, in the study by Póvoa^[24] and Barth^[37], the semi-quantitative analysis was based on the presence of steatosis, hemorrhage and edema present in all hepatic lobes, where it was evaluated and quantified by means of a scale from 0 to 4, according to the affected areas. Póvoa^[24] observed intense degrees of injury in all alterations analyzed when compared to controls. In addition to these alterations, Barth^[37] verified the degree of vacuolation and swelling of hepatocytes as well as endothelial cells. Light and focal alterations were observed in all areas evaluated when compared to control mice^[37].

In the semi-quantitative evaluation of patients infected by YFV, in the studies conducted by Dias Junior^[14] and Quaresma^[22], the degree of injury was quantified with scores ranging from 0 to 3 (0 = absent, + = mild, ++ = moderate and +++ = intense). In the first study, we evaluated the degree of injury caused by acidophilic bodies, balloon degeneration, steatosis, morular cells and binucleation of hepatocytes^[14]. All findings were mild to moderate in patients with YFV. However, the majority of the patients evaluated showed moderate hepatocytes with binucleate and presence of balonization. In the study by Quaresma^[22], the degree of hepatic injury was verified from the presence of apoptosis, necrosis and steatosis, where a greater prevalence of apoptosis of hepatocytes was observed when compared to the presence of necrosis and steatosis^[14].

CONCLUSION

This review demonstrated the main histopathological changes found after infection by DENV and YFV, besides evidencing the importance of the findings to uncover the main impulses of the hepatic tissue. Knowledge about the pathogenesis of viral infections with microscopic data in the clinical and laboratory evaluation of patients, such as the prognosis, prevents the disease from being agravated.

REFERENCES

- Daep CA, Muñoz-Jordán JL, Eugenin EA. Flaviviruses, an expanding threat in public health: focus on Dengue, West Nile, and Japanese encephalitis virus. *Journal of Neurovirology* 2014; **20(6)**: 539-60. [DOI: 10.1007/s13365-014-0285-z]
- Fernandez-Garcia MD, Mazzon M, Jacobs M, Amara A. Pathogenesis of Flavivirus Infections: Using and Abusing the Host Cell. *Cell Host & Microbe* 2009; **5(4)**: 318-28. [DOI: 10.1016/j.chom.2009.04.001]
- Bhatt S, Gething PW, Brady OJ, Messina JP. The global distribution and burden of dengue. *Nature* 2013; **496(7446)**: 504-7. [DOI: 10.1038/nature12060]
- Diamond MS, Pierson TC, T. C. Molecular Insight into Dengue Virus Pathogenesis and Its Implications for Disease Control. *Cell* 2015; **162(3)**: 488-92. [DOI: 10.1016/j.cell.2015.07.005]
- Monath TP, Vasconcelos PF. C. Yellow fever. *Journal of Clinical Virology* 2015; **64**: 160-73. [DOI: 10.1016/j.jcv.2014.08.030]
- Quaresma JA, Pagliari C, Medeiros DB, Duarte MI, Vasconcelos PF. Immunity and immune response, pathology and pathologic changes: progress and challenges in the immunopathology of yellow fever. *Reviews in Medical Virology*, 2013; **23(5)**: 305-18. [DOI: 10.1002/rmv.1752]
- Barrett, ADT. Yellow fever live attenuated vaccine: A very successful live attenuated vaccine but still we have problems controlling the disease. *Vaccine* 2017; **35(44)**: 5951-5955. [DOI: 10.1016/j.vaccine.2017.03.032]
- WHO -- WORLD HEALTH ORGANIZATION. Dengue: Guidelines for diagnosis, treatment, prevention and control. Geneva: World Health Organization, 2009. 160 p. [PMID: 23762963]
- Mayer SV, Tesh RB, Vasilakis N. The emergence of arthropod-borne viral diseases: A global prospective on dengue, chikungunya and zika fevers. *Acta Tropica* 2017; **166**: 155-163. [DOI: 10.1016/j.actatropica.2016.11.020]
- Lin CF, Wan SW, Chen MC, Lin SC, Cheng CC, Chiu SC, Hsiao YL, Lei HY, Liu HS, Yeh TM, Lin YS. Liver injury Downloaded from caused by antibodies against dengue virus nonstructural protein 1 in a murine model. *Laboratory Investigation* 2008; **88(10)**: 1079-89. [DOI:10.1038/labinvest.2008.70]
- Stock NK, Escadafal C, Achazi K, Cissé M, Niedrig M. Development and characterization of polyclonal peptide antibodies for the detection of Yellow fever virus proteins. *Journal of Virological Methods* 2015; **222**: 110-6. [DOI: 10.1016/j.jviromet.2015.06.006]
- Kularatne SA, Imbulpitaya IV, Abeysekera RA, Waduge RN, Rajapakse RP, Weerakoon KG. Extensive haemorrhagic necrosis of liver is an unpredictable fatal complication in dengue infection: a postmortem study. *BMC Infection Diseases* 2014; **14**: 141. [DOI: 10.1186/1471-2334-14-141]
- Guzman MG, Halstead SB, Artsob H, Buchy P, Farrar J, Gubler DJ. Dengue: a continuing global threat. *Nature Reviews -- Microbiology* 2010; **8(12)**: S7-16. [DOI: 10.1038/nrmicro2460]
- Dias Junior LB, Alves VAF, Kanamurac C, Oikawa RTC, Wakamatsu A. Fulminant hepatic failure in northern Brazil: morphological, immunohistochemical and pathogenic aspects of Lábrea hepatitis and yellow fever. *Transactions of the Royal Society of Tropical Medicine and Hygiene* 2007; **101(8)**: 831-839 [DOI: 10.1016/j.trstmh.2006.10.007]
- Drumond BP, Fagundes LG, Rocha RP, Fumagalli MJ, Araki CS, Colombo TE. Phylogenetic analysis of Dengue virus 1 isolated from South Minas Gerais, Brazil. *Brazilian Journal of Microbiology* 2016; **47(1)**: 251-8. [DOI: 10.1016/j.bjm.2015.11.016]
- Engelmann F, Josset L, Girke T, Park B, Barron A, Dewane J, Hammarlund E, Lewis A, Axthelm MK, Slifka MK, Messaoudi I. Pathophysiological and transcriptomic analyses of viscerotropic yellow fever in a rhesus macaque model. *Plos neglected tropical diseases* 2014; **8(11)**: e3295. [DOI: 10.1371/journal.pntd.0003295]
- Paes MV, Lenzi HL, Nogueira AC, Nuovo GJ, Pinhão AT, Mota EM, Basilio-de-Oliveira CA, Schatzmayr H, Barth OM, Alves AM. Hepatic damage associated with dengue-2 virus replication in liver cells of BALB/c mice. *Laboratory Investigation* 2009; **89(10)**: 1140-51. [DOI:10.1038/labinvest.2009.83]
- Sakinah S, Priya SP, Kumari S, Amira F, K P, Alsaedy H, Ling MP, Chee HY, Higuchi A, Alarfaj AA, Munusamy MA, Murugan K, Taib CN, Arulselvan P, Rajan M, Neela VK, Hamat RA, Benelli G, Kumar SS. Impact of dengue virus (serotype DENV-2) infection on liver of BALB/c mice: a histopathological analysis. *Tissue & Cell* 2017; **49(1)**: 86-94. [DOI: 10.1016/j.tice.2016.11.005]
- Wang J, Chen Y, Gao N, Wang Y, Tian Y, Wu J, Zhang J, Zhu J, Fan D, An J. Inhibitory effect of glutathione on oxidative liver injury induced by dengue virus serotype 2 infections in mice. *PLoS One* 2013; **8(1)**: e55407. [DOI: 10.1371/journal.pone.0055407]
- FERNANDES, N. C.A.; et al. Outbreak of Yellow Fever among Nonhuman Primates, Espírito Santo, Brazil. *Emerging Infectious Diseases* 2017; **23(2)**: 1080-6059. [DOI:10.3201/eid2312.170685]
- Leal SG, Romano APM, Monteiro Romano APM, Monteiro RV, Melo CB, Vanconcelos PFC. Frequency of histopathological changes in Howler monkeys (*Alouatta* sp.) naturally infected with yellow fever virus in Brazil. *Revista da Sociedade Brasileira de Medicina Tropical* 2016; **49(1)**: 29-33. [DOI: 10.1590/0037-8682-0363-2015]
- Quaresma JA, Barros VL, Pagliari C, Fernandes ER, Andrade HF Jr, Vasconcelos PF, Duarte MI. Hepatocyte lesions and cellular

- immune response in yellow fever infection. *Transactions of the Royal Society of Tropical Medicine and Hygiene* 2007; **101**(2): 161-8. [DOI: 10.1016/j.trstmh.2006.02.019]
23. Paes MV, Pinhão AT, Barreto DF, Costa SM, Oliveira MP, Nogueira AC, Takiya CM, Farias-Filho JC, Schatzmayr HG, Alves AM, Barth OM. Liver injury and viremia in mice infected with dengue-2 virus. *Virology* 2005; **338**(2): 236-46. [DOI: 10.1016/j.virol.2005.04.042]
 24. Póvoa TF, Alves AMB, Paes MV. The pathology of severe dengue in multiple organs of human fatal cases: histopathology, ultrastructure and virus replication. *PLoS one* 2014; **9**(4): e83386. [DOI: 10.1371/journal.pone.0083386]
 25. Milligan GN, Sarathy VV, White MM, Greenberg MB, Campbell GA, Pyles RB, Barrett ADT, Bourne N. A lethal model of disseminated dengue virus type 1 infection in AG129 mice. *Journal of General Virology* 2017; **98**(10): 2507-2519. [DOI: 10.1099/jgv.0.000923]
 26. Sreekanth GP, Chuncharunee A, Sirimontaporn A, Panaampon J, Srisawat C, Mochang A, Malakar S, Thuwajit P, Kooptiwut S, Suttitheptumrong A, Songprakhon P, Noisakran S, Yenchitsomanus PT, Limjindaporn T. A. Role of ERK1 / 2 signaling in dengue virus-induced liver injury. *Virus Research*, 2014; **188**: 15-26. [DOI: 10.1016/j.virusres.2014.03.025]
 27. França RF, Zucoloto S, da Fonseca BA. A BALB/c mouse model shows that liver involvement in dengue disease is immune-mediated. *Experimental and Molecular Pathology* 2010; **89**(3): 321-6. [DOI: 10.1016/j.yexmp.2010.07.00]
 28. Vieira WT, Gayotto LC, de Lima CP, de Brito T. Histopathology of the human liver in yellow fever with special emphasis on the diagnostic role of the Councilman body. *Histopathology* 1983; **7**(2): 195-208. [PMID: 6303935]
 29. Nguyen TA, Hoang L, Pham le D, Hoang KT, Okitsu S, Mizuguchi M, Ushijima. Norovirus and sapovirus infections among children with acute gastroenteritis in Ho Chi Minh City during 2005-2006. *Journal of Tropical Pediatrics* 2008; **54**(2): 102-13. [DOI: 10.1093/tropej/fmm096]
 30. Couvelard A, Marianneau P, Bedel C, Drouet MT, Vachon F, Hénin D, Deubel V. Report of a fatal case of dengue infection with hepatitis: demonstration of dengue antigens in hepatocytes and liver apoptosis. *Human Pathology* 1999; **30**(9): 1106-10. [PMID: 10492047]
 31. Srikiatkachorn A. Plasma leakage in dengue haemorrhagic fever. *Thrombosis and Haemostasis* 2009; **102**(6): 1042-9. [DOI: 10.1160/TH09-03-0208]
 32. Green S, Vaughn DW, Kalayanarooj S, Nimmannitya S, Suntayakorn S, Nisalak A, Lew R, Innis BL, Kurane I, Rothman AL, Ennis FA. Early immune activation in acute dengue illness is related to development of plasma leakage and disease severity. *Journal Infection Diseases* 1999; **179**(4): 755-62. [DOI: 10.1086/314680]
 33. Gonçalves D, de Queiroz Prado R, Almeida Xavier E, Cristina de Oliveira N, da Matta Guedes PM, da Silva JS, Moraes Figueiredo LT, Aquino VH. Immunocompetent mice model for dengue virus infection. *The Scientific World Journal* 2012; **2012**: 525947. [DOI: 10.1100/2012/525947]
 34. Jain D, Singh T. Dengue virus related hemophagocytosis: a rare case report. *Hematology* 2008; **13**(5): 286-8. [DOI: 10.1179/102453308X316095]
 35. Srichaikul T, Punyagupta S, Kanchanapoom T, Chanokovatt C, Likittanasombat K, Leelasiri A. Hemophagocytic syndrome in Dengue hemorrhagic fever with severe multiorgan complications. *Journal of the Medical Association of Thailand* 2008; **91**(1): 104-9. [PMID: 18386553]
 36. Wong KF, Chan JK, Chan JC, Lim WW, Wong WK. Dengue virus infection-associated hemophagocytic syndrome. *American Journal of Hematology* 1991; **38**(4): 339-40. [PMID: 1746547]
 37. Barth OM, Barreto DF, Paes MV, Takiya CM. Morphological studies in a model for dengue-2 virus infection in mice. *Memórias do Instituto Oswaldo Cruz* 2006; **101**(8): 905-915. [DOI: 10.1590/S0074-02762006000800014]
 38. Limonta D, Falcón V, Torres G, Capó V. Dengue virus identification by transmission electron microscopy and molecular methods in fatal dengue hemorrhagic fever. *Infection* 2012; **40**(6): 689-94. [DOI: 10.1007/s15010-012-0260-7]
 39. Basílio-de-Oliveira CA, Aguiar GR, Baldanza MS, Barth OM, Eyer-Silva WA, Paes MV. Pathologic study of a fatal case of dengue-3 virus infection in Rio de Janeiro. *Brazilian Journal of Infectious Diseases* 2005; **9**(4): 341-347. [DOI: 10.1590/S1413-86702005000400012]
 40. Aye KS, Charnkaew K, Win N, Wai KZ, Moe K, Punyadee N, Thiemmecca S, Suttitheptumrong A, Sukpanichnant S, Prida M, Halstead SB. Pathologic highlights of dengue hemorrhagic fever in 13 autopsy cases from Myanmar. *Human Pathology* 2014; **45**(6): 1221-33. [DOI: 10.1016/j.humpath.2014.01.022]
 41. Peeling RW, Artsob H, Pelegrino JL, Buchy P, Cardoso MJ, Devi S, Enria DA, Farrar J, Gubler DJ, Guzman MG, Halstead SB, Hunsperger E, Kliks S, Margolis HS, Nathanson CM, Nguyen VC, Rizzo N, Vázquez S, Yoksan S. Evaluation of diagnostic tests: dengue. *Nature Reviews Microbiology* 2010; **8**(12 Suppl): S30-8. [DOI: 10.1038/nrmicro2459]

Peer Reviewer: Ahmed Wahid