

## A Case of Gastric Variceal Bleeding: Diagnosis and Treatment of a Rare Anatomical Variant

Zarir Ahmed<sup>1</sup>, DO; Daniel Bujanda<sup>2</sup>, MD; Alex Befeler<sup>2</sup>, MD

1 Department of Internal Medicine, Saint Louis University School of Medicine, St Louis, Missouri. United States of America;

2 Department of Gastroenterology, Saint Louis University School of Medicine, St Louis, Missouri. United States of America.

**Conflict-of-interest statement:** The authors declare that there is no conflict of interest regarding the publication of this paper.

**Open-Access:** This article is an open-access article which was selected by an in-house editor and fully peer-reviewed by external reviewers. It is distributed in accordance with the Creative Commons Attribution Non Commercial (CC BY-NC 4.0) license, which permits others to distribute, remix, adapt, build upon this work non-commercially, and license their derivative works on different terms, provided the original work is properly cited and the use is non-commercial. See: <http://creativecommons.org/licenses/by-nc/4.0/>

**Correspondence to:** Zarir Ahmed, Department of Internal Medicine, Saint Louis University School of Medicine, St Louis, Missouri. United States of America.

**Email:** [zarirmed@gmail.com](mailto:zarirmed@gmail.com)

**Telephone:** +1-636-730-0066

**Received:** April 9, 2019

**Revised:** May 20, 2019

**Accepted:** May 22, 2019

**Published online:** October 21, 2019

### ABSTRACT

Assessment of the gastric variceal drainage system is important in selecting proper treatment options and interventional techniques. Our case describes a unique approach to the treatment of gastric variceal bleeding due to the anatomy of this patient.

**Key words:** Gastric varices; Cirrhosis; Gastroesophageal bleeding; Coiling

© 2019 The Author(s). Published by ACT Publishing Group Ltd. All rights reserved.

Ahmed Z, Bujanda D, Befeler A. A Case of Gastric Variceal Bleeding: Diagnosis and Treatment of a Rare Anatomical Variant. *Journal of Gastroenterology and Hepatology Research* 2019; **8(5)**: 2990-2993 Available from: URL: <http://www.ghrnet.org/index.php/joghr/article/view/2557>

### INTRODUCTION

Gastric varices are present in 40% of patients with cirrhosis<sup>[1]</sup>. Compared to esophageal variceal bleeding, they have higher mortality. The evidence behind management of gastric variceal bleeding is much less than with esophageal bleeding, with only a few trials. There are endoscopic and interventional radiologic procedures to treat acute gastric variceal bleeding. This case describes a unique anatomical variant in a patient with gastroesophageal bleeding, treated in a unique manner.

### CASE

A 77 year-old female presented to the emergency room with an episode of hematemesis and melena. Her past medical history is significant for autoimmune-related cirrhosis, hypertension, and hyperthyroidism. For the last day, she experienced weakness and dizziness and had several melanic bowel movements. Upon arrival, her blood pressure was 85/52, heart rate 105. Her abdominal exam was benign, but digital rectal exam confirmed melena. Work-up was remarkable for a hemoglobin (Hb) of 6.7 g/dL (reference 12.0-15.5 g/dL), platelets  $177 \times 10^3/\mu\text{L}$  (reference  $150-400 \times 10^3/\mu\text{L}$ ), white blood cells  $7.7 \times 10^3/\mu\text{L}$  (reference  $3.5-10.5 \times 10^3/\mu\text{L}$ ), mean corpuscular volume 79.2 fL (reference 81.0-97.0 uL), within normal liver enzymes and total bilirubin. She was given 1 unit of packed red blood cells (pRBC) and started on an octreotide and pantoprazole drip.

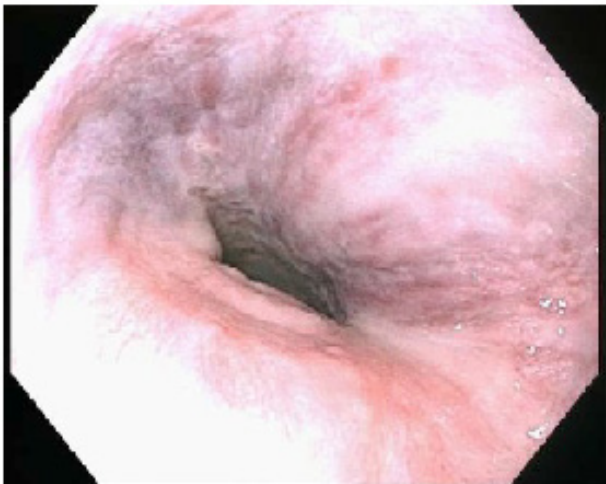Within 12 hours of admission, she underwent an esophagogastroduodenoscopy (EGD) which revealed grade 2 esophageal varices (Figure 1), type 2 gastroesophageal varices (GOV) without bleeding, non-bleeding gastric ulcer (Figure 2), and non-bleeding erosive gastropathy. It did not reveal any active bleeding sites. However, the patient's Hb did not respond to 2 units pRBCs and it stayed at 6.9 g/dL and the patient remained hypotensive. Thus 36 hours into admission, she underwent another EGD which was notable

for large non-bleeding type 2 GOV with nipple sign, suggestive of recent bleeding (Figures 3 and 4). She was stabilized after a total of 3 U pRBCs, with improvement of Hb to 9.5 g/dL and transferred to our intensive care unit for evaluation for transjugular intrahepatic portosystemic shunt (TIPS) and/or balloon-occluded transvenous obliteration (BRTO) procedure to stop the bleeding as endoscopic measures failed.

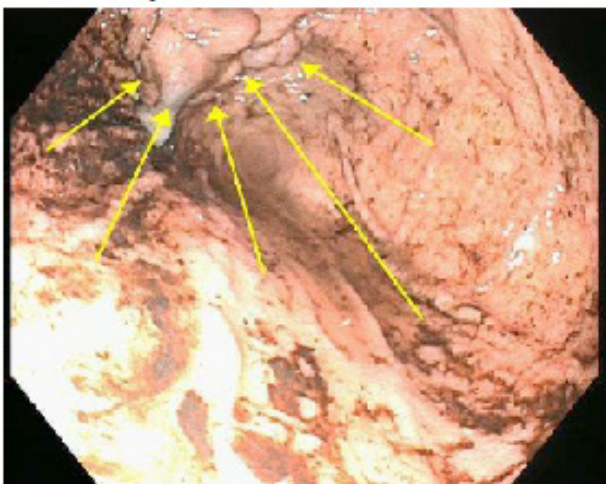
3 days into her admission, a venogram was performed which revealed collateral flow directly from the left ovarian vein into the GOV and pericardial veins (Figure 5). As there was no definite source of bleeding, embolization was not performed. Additionally, no identifiable gastrorenal shunt was seen and BRTO was not performed. Her hepatic venous pressure gradient was not significantly elevated (wedged hepatic venous pressure 17 mm Hg, hepatic arterial pressure 11 mm Hg, gradient of 6 mm Hg either to perform TIPS procedure (elevated gradient is > 10-12 mm Hg). After the procedure, she was sent to the medical ward.

However a few hours after arrival she complained of worsening light-headedness and had a few episodes of hematemesis. Her blood pressure was 70/30, heart rate 55. Her Hb was 9.3 g/dL and recheck was 9.0 g/dL. She received 1 L of fluids and transferred back to the intensive care unit on octreotide and pantoprazole drip. She was taken for another venogram emergently. In this procedure, a large ovarian and gastric varix was seen originating from the splenic vein.

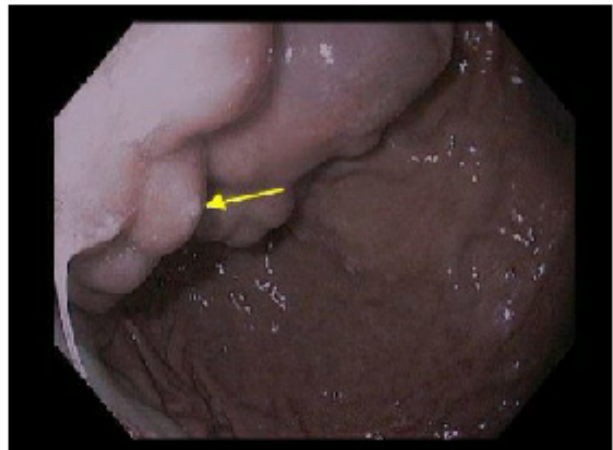
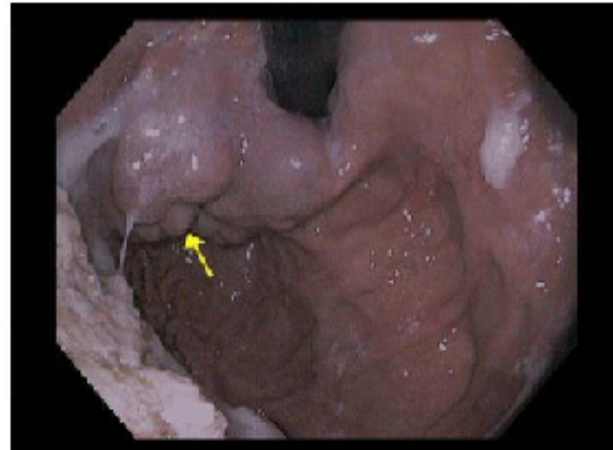
Additionally a left coronary sinus varix was seen feeding into the gastric varix. The gastric and coronary sinus varix were embolized and coiled (Figure 6). Afterwards, the patient had no further bleeding and her blood counts stabilized to Hb of 8.0 g/dL. She was discharged home after a few days with plan for coiling and embolization of the large ovarian varix as outpatient.



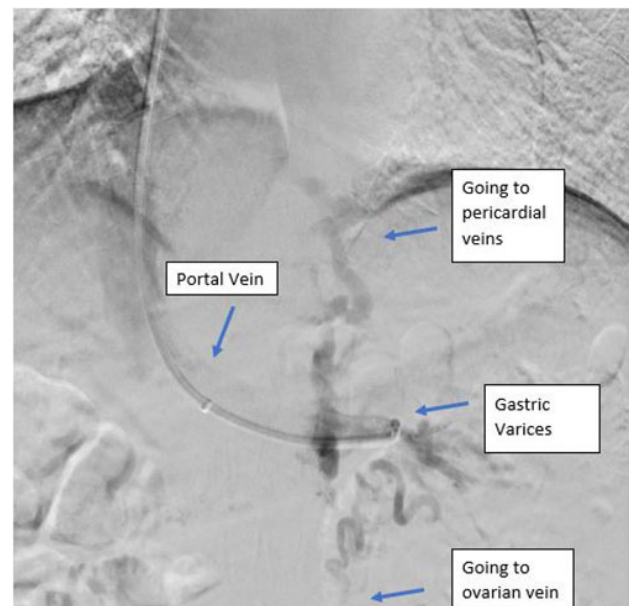
**Figure 1** Lower third of the esophagus. Columns of grade II esophageal varices without bleeding stigmata.



**Figure 2** Gastroesophageal varices extending along the fundus without any signs of active bleeding. Dark heme visualized in the stomach.



**Figure 3, 4** GOV type 2 with nipple sign. No active bleeding, but likely site of previous bleeding.



**Figure 5** Venogram demonstrating no identifiable gastrorenal shunt.

## DISCUSSION

Gastric varices (GV) are the second most common cause of upper gastrointestinal bleeding in patients with cirrhosis and portal hypertension. It is estimated that 30% of all cirrhotics develop variceal bleeding and that 10-20% originate from GV. Bleeding is more severe than esophageal varices and associated with a higher mortality although it occurs less frequently<sup>[1]</sup>.

One classification of GV is determined by the Sarin endoscopic classification. Fundal varices are divided into type 2 or type 1 gastroesophageal varices (GOV). Type 1 GOV is a continuation of esophageal varices (EV) into the lesser curvature varices. Whereas type 2 GOV is a continuation of EV into the cardia (Figure 7). Our patient had type 2 GOV.

However, the above classification system does not address the underlying anatomy. In order to achieve optimal treatment results, it is important to understand vasculature. GV drain into the systemic system either via esophageal varices called the gastroesophageal venous system, or the inferior phrenic vein (IPV) called the gastrophrenic venous system<sup>[2,3]</sup>. Our patient likely had only gastrophrenic venous drainage of her GOV type 2 as seen in her venogram.

The gastrophrenic venous circulation drains several ways. In more than 80% of cases, the left IPV terminates inferiorly into the left renal vein, forming the gastro-renal shunt. In 15% of cases it may drain instead transversely into the inferior vena cava or left hepatic vein, forming the gastro-caval shunt<sup>[4]</sup>. In less than 5% of cases IPV can drain into the pericardial vein. The IPV can also form anastomoses with the peridiaphragmatic, retroperitoneal, subcostal, adrenal, and azygous venous systems<sup>[5]</sup>. Interestingly, our patient did not have any gastro-renal nor gastro-caval shunt. Rather she had drainage with the left coronary sinus via the pericardial veins. Additionally, she had drainage anastomoses with retroperitoneal venous systems, specifically the ovarian vein, which has not been documented on any case reports.

The anatomy of portal drainage is of utmost importance as it dictates the selection of treatment options for variceal bleeding. However the evidence to support guidelines for GV bleeding management is not as clear. Initial treatment for patients with acute GV include volume resuscitation and antibiotic prophylaxis. Balloon tamponade may be a resort in cases of massive bleeding<sup>[6]</sup>. In addition, somatostatin analogs such as octreotide should be started followed by endoscopic or radiologic intervention methods to achieve hemostasis<sup>[7]</sup>.

Although variceal band ligation is the established treatment modality for EV bleeding, it is not optimal in GV bleeding due to high rebleeding rates. One effective approach to treat type 1 GOV type is endoscopic sclerotherapy with bleeding control rates up to 60-80%. Main complications include mucosal ulcers or perforation<sup>[8]</sup>. Another method is using cyanoacrylate glue, but it is not currently approved in the United States. One major complication is glue thromboses causing strokes, infarction or other sites of emboli<sup>[9]</sup>. However neither sclerotherapy or glue is appropriate for GOV type 2 due to very low rates of hemostasis, like in our patient.

Radiologic interventions for GOV2 include transjugular intrahepatic portosystemic shunt (TIPS), balloon-occluded transvenous obliteration (BRTO), embolization, or coiling. TIPS is the treatment of choice for controlling bleeding from GOV2 after a trial in Taiwan demonstrated lower rebleeding rates<sup>[10]</sup>. However, our patient did not have significant enough portal pressures to undergo this procedure (hepatic venous portal gradient should exceed 12 mm

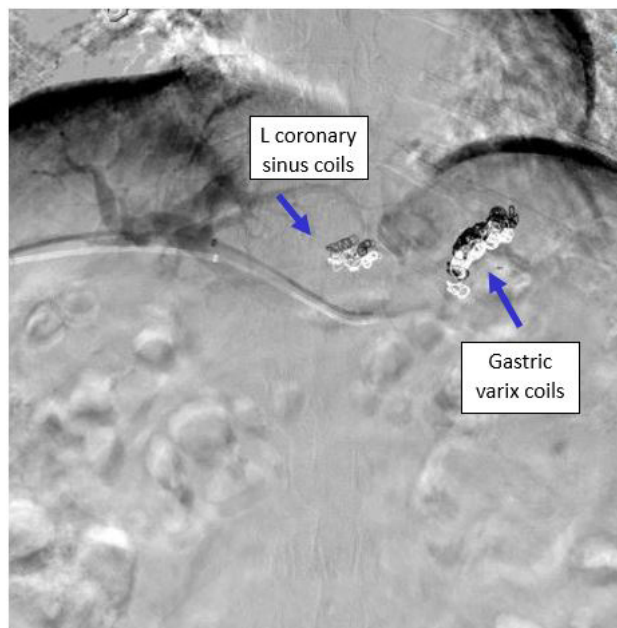


Figure 6 Gastric and left coronary sinus varix after coiling and embolization.

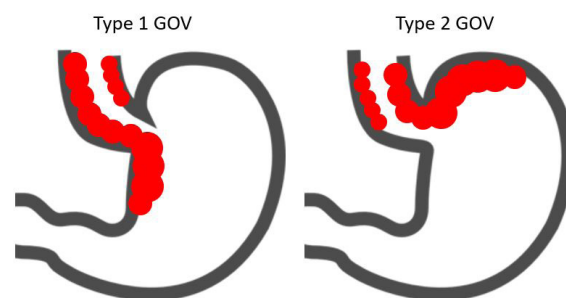


Figure 7

Hg). BRTO procedure is only viable for patients with gastro-renal shunting. This procedure involves cannulation of the left renal vein, then balloon occlusion and infusion of sclerosant or coils to obliterate the gastro-renal collaterals. Rebleeding rates for BRTO are only 1 to 15%<sup>[11]</sup>. Our patient did not have a gastro-renal shunt, thus could not benefit from BRTO. When these fail, radiologic interventions such as embolization of bleeding areas and coiling can be useful. Our patient successfully underwent coiling and embolization of her bleeding gastric and coronary varices.

There are currently no guidelines and the available literature is very few for patients that have GOV type 2 bleeding with rare anatomical variations, such as in this case. Understanding the anatomic classification of the varices and defining the flow and drainage of the venous shunts is integral in properly treating these patients. Therapeutic options for GOV bleeding include endoscopic (banding, sclerotherapy, gluing) or radiologic intervention (TIPS, BRTO, embolization/coiling). These treatments involve multi-team and system-based approach to effectively manage acute variceal bleeding. Appropriate management of GOV2 bleeding would potentially help patients with unusual anatomical variants.

Diagram 1: Type 1 gastroesophageal (GOV) is extension of esophageal varices along the lesser curvature of the stomach. Type 2 GOV is extension of the esophageal varices along the greater curvature.

## CONCLUSION

This case highlights a unique anatomical variant of gastric varices with large ovarian and pericardial varices. Typical methods to treat GOV2 bleeding such as TIPS or BRTO procedure were not amenable and as such, this patient's life-threatening bleed was treated successfully with coiling and embolization. Understanding the anatomy behind variceal bleeding is potentially life-saving in endoscopic or radiologic intervention.

## REFERENCES

1. Al-Osaimi AM, Caldwell SH. Medical and endoscopic management of gastric varices. *Semin Intervent Radiol.* 2011 Sep; **28(3)**: 273-282. [DOI: 10.1055/s-0031-1284453]
2. Arakawa M, Masuzaki T, Okuda K. Pathology of fundic varices of the stomach and rupture. *J Gastroenterol Hepatol.* 2002; **17(10)**: 1064-1069. [PMID: 12201865]
3. Wani ZA, Bhat RA, Bhadoria AS, Maiwall R, Choudhury A. Gastric varices: classification, endoscopic and ultrasonographic management. *J Res Med Sci.* 2015 Dec; **20(12)**: 1200-1207. [DOI: 10.4103/1735-1995.172990]
4. Phillips CA, Arora A, Shetty R, Kasana V. A comprehensive review of portosystemic collaterals in cirrhosis: historical aspects, anatomy, and classifications. *Int J Hepatol.* 2016; **2016**: 6170243. [DOI: 10.1155/2016/6170243]
5. Ibukuro K, Tsukiyama T, Mori K, Inoue Y. Precaval draining vein from paraesophageal varices: radiologic-anatomic correlation. *AJR Am J Roentgenol.* 1999; **172**: 651-4. [DOI: 10.2214/ajr.172.3.10063853]
6. Garcia-Tsao G, Abraldes JG, Berzigotti A, Bosch J. Portal hypertensive bleeding in cirrhosis: risk stratification, diagnosis and management: 2016 practice guidance by the American association for the study of liver disease. *Hepatology.* 2017; **65**:1. [DOI: 10.1002/hep.28906]
7. Mishra SR, Chandler SB, Kumar A, Sarin SK. Endoscopic cyanoacrylate injection versus beta-blocker for secondary prophylaxis of gastric variceal bleed: a randomised controlled trial. *Gut.* 2010 Jun; **59(6)**:729-35. [DOI: 10.1136/gut.2009.192039]
8. Lo GH, Lai KH, Cheng JS, Chen MH, Chiang HT. A prospective, randomized trial of butyl cyanoacrylate injection versus band ligation in the management of bleeding gastric varices. *Hepatology.* 2001;**33(5)**:1060. [DOI: 10.1053/jhep.2001.24116]
9. Caldwell S. Gastric varices: is there a role for endoscopic cyanoacrylates, or are we entering the BRTO era. *Am J Gastroenterol.* 2012; **107**:1784-1790. [DOI: 10.1038/ajg.2012.160]
10. Lo GH, Liang HL, Chen WC, Chen MH, Lai KH, Hsu PI, Lin CK, Chan HH, Pan HB. A prospective, randomized controlled trial of transjugular intrahepatic portosystemic shunt versus cyanoacrylate injection in the prevention of gastric variceal rebleeding. *Endoscopy.* 2007; **39**: 679-685. [DOI: 10.1055/s-2007-966591]
11. Saad WE. Balloon-occluded retrograde transvenous obliteration of gastric varices: concept, basic techniques, and outcomes. *Semin Intervent Radiol.* 2012; **29**: 118-128. [DOI: 10.1055/s-0032-1312573]