

Long-term survival in an octogenarian patient with carcinomatous pleurisy from recurrent colon cancer, responding to Bevacizumab and CPT-11

Takahisa Fujikawa¹

¹ Department of Surgery, Kokura Memorial Hospital, Kitakyushu, Fukuoka, Japan.

Conflict-of-interest statement: The author(s) declare(s) that there is no conflict of interest regarding the publication of this paper.

Open-Access: This article is an open-access article which was selected by an in-house editor and fully peer-reviewed by external reviewers. It is distributed in accordance with the Creative Commons Attribution Non Commercial (CC BY-NC 4.0) license, which permits others to distribute, remix, adapt, build upon this work non-commercially, and license their derivative works on different terms, provided the original work is properly cited and the use is non-commercial. See: <http://creativecommons.org/licenses/by-nc/4.0/>

Correspondence to: Takahisa Fujikawa, MD, PhD, FACS, Department of Surgery, 3-2-1 Asano, Kokurakita-ku, Kitakyushu, Fukuoka 802-8555, Japan.

Email: fujikawa-t@kokurakinen.or.jp

Telephone: +81-93-511-2000

Fax: +81-93-511-3240

Received: July 3, 2019

Revised: July 17, 2019

Accepted: July 18, 2019

Published online: October 21, 2019

ABSTRACT

Cancerous pleurisy of recurrent colorectal cancer is relatively rare, and standardized chemotherapy has not been established. We herein presented a case of octogenarian with recurrent colon cancer with carcinomatous pleurisy, which successfully treated by modulated bevacizumab and CPT-11 combination chemotherapy and a total of 5-year long-term survival was achieved. Significantly responsive cases of Bevacizumab-combined chemotherapy have been reported for cancer pleurisy from different carcinomas, and its usefulness for cancerous pleural effusion cases is expected. We discuss the efficacy of Bevacizumab for elderly patients with recurrent or advanced colorectal cancer and cancerous pleurisy.

Key words: Carcinomatous pleurisy; Recurrent colon cancer; Bevacizumab; CPT-11

© 2019 The Author(s). Published by ACT Publishing Group Ltd. All rights reserved.

Fujikawa T. Long-term survival in an octogenarian patient with carcinomatous pleurisy from recurrent colon cancer, responding to Bevacizumab and CPT-11. *Journal of Gastroenterology and Hepatology Research* 2019; **8(5)**: 2994-2996 Available from: URL: <http://www.ghrnet.org/index.php/joghr/article/view/2623>

LETTER TO THE EDITOR

An 84-year-old woman was presented with massive right pleural effusion. She was initially underwent ileocecal resection for Stage II ascending colon cancer at the age of 77 years, and also received partial liver resection for liver metastasis at the age of 80 years (Figure 1A, 1B). At the age of 81 years, multiple liver metastases were recognized (Figure 1C). After 7 courses of Bevacizumab + FOLFOX6 therapy were performed with the result of PR response, she underwent partial liver resection (Figure 1D). Postoperatively, adjuvant chemotherapy was not performed and no recurrence occurred for two years, but the right lung metastasis was recognized at the age of 83 years (Figure 2A). Oral UFT / USEL therapy was introduced and continued in consideration of her high age, but massive right pleural effusion was observed, and chest drainage was performed (Figure 2B, 2C). She was diagnosed as carcinomatous pleurisy by pleural examination. After small intrathoracic administration of CDDP, Bevacizumab + CPT-11 therapy (80% dose) was continued on an outpatient basis. Pleural effusion was not observed and disease control in the state of SD was achieved over a long period of 5 years (Figure 2D-2F). However, she finally passed away due to respiratory failure resulting from relapsed pleural effusion, 12 years after the initial colon resection (Figure 3).

Cancerous pleurisy from recurrent colorectal cancer is relatively rare, and standardized chemotherapy has not been established. It leads to massive pleural effusion, which impairs the normal function of the heart and lung, and thus is related to poor prognosis. The initial therapy for patients with cancerous pleurisy includes tube

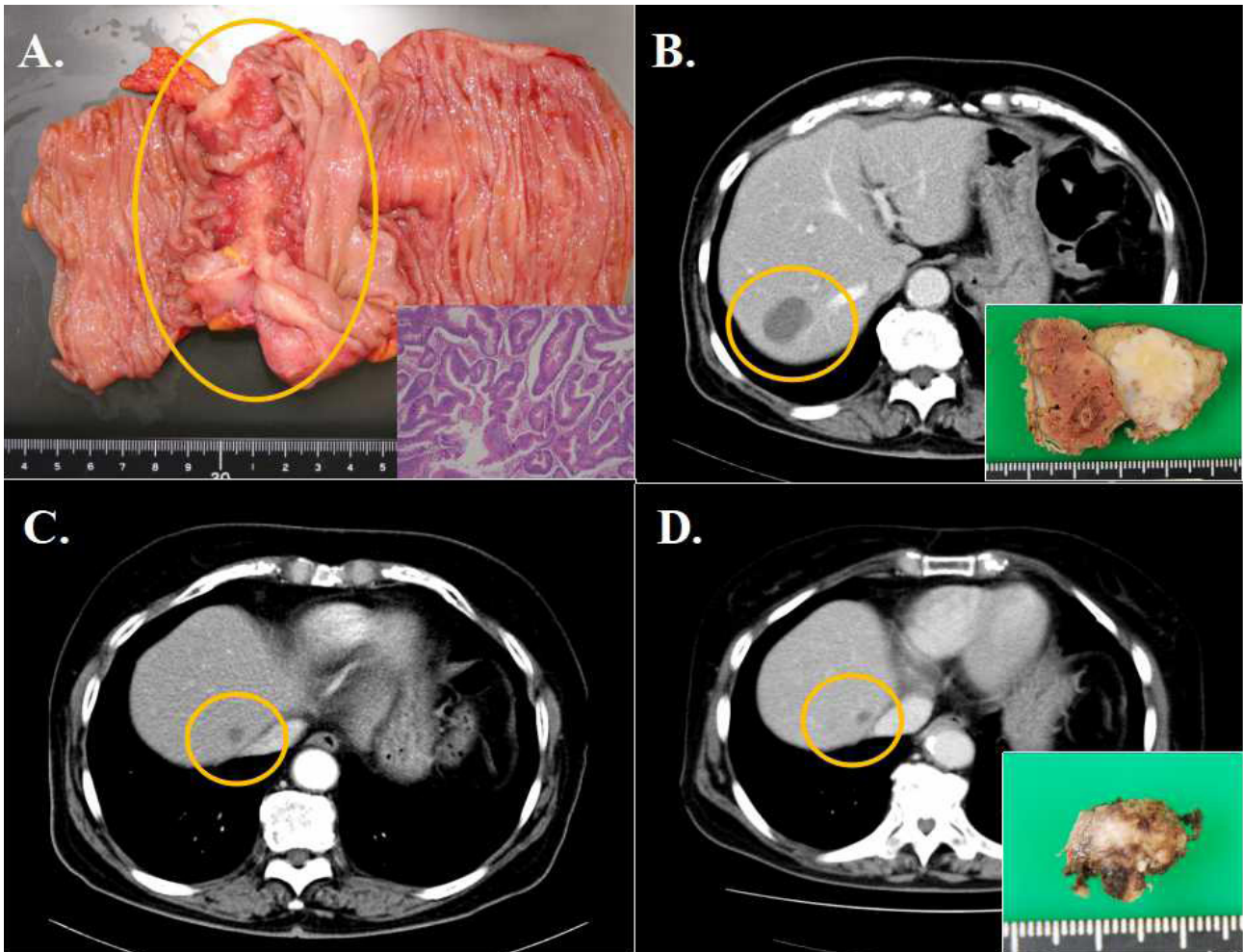


Figure 1 (A) Gross specimen of the initially resected ascending colon showed irregular wall thickness. Small image (lower right) showed microscopic findings of moderately differentiated adenocarcinoma. (B) CT scan showed liver metastasis located at S7 (small image: resected tumor). (C, D) CT scan showed secondary liver lesion in S8 (Figure 1C), and it was also resected after Bevacizumab+FOLFOX6 chemotherapy (Figure 1D).

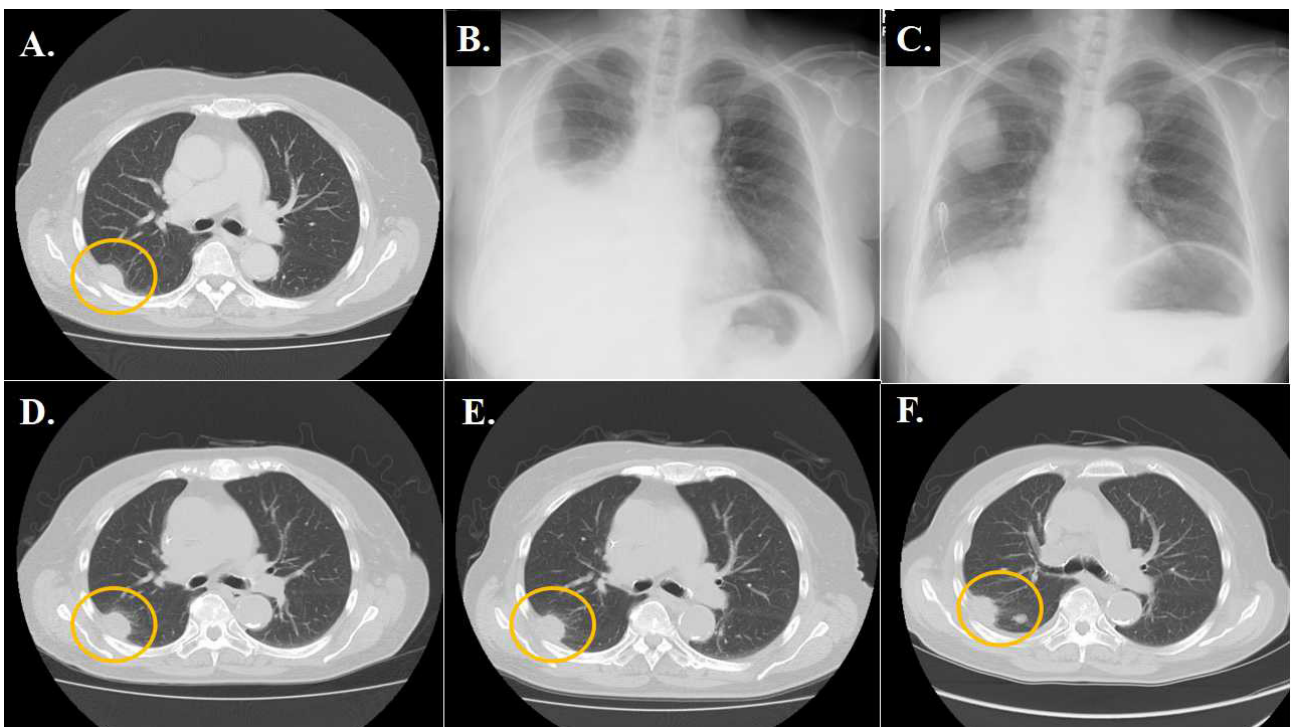


Figure 2 (A) Follow-up CT scan 24 months after surgery revealed new lung metastasis in his right lung. (B,C) Massive right pleural effusion was observed 7 months later, and the chest drainage and intrathoracic administration of CDDP were performed (2B: before drainage, 2C: after drainage). (D-F) Pleural effusion was not observed and disease control in the state of SD was achieved over a long period of 5 years (2D: at the age of 85 years, 2E: 86 years, 2F: 88 years).

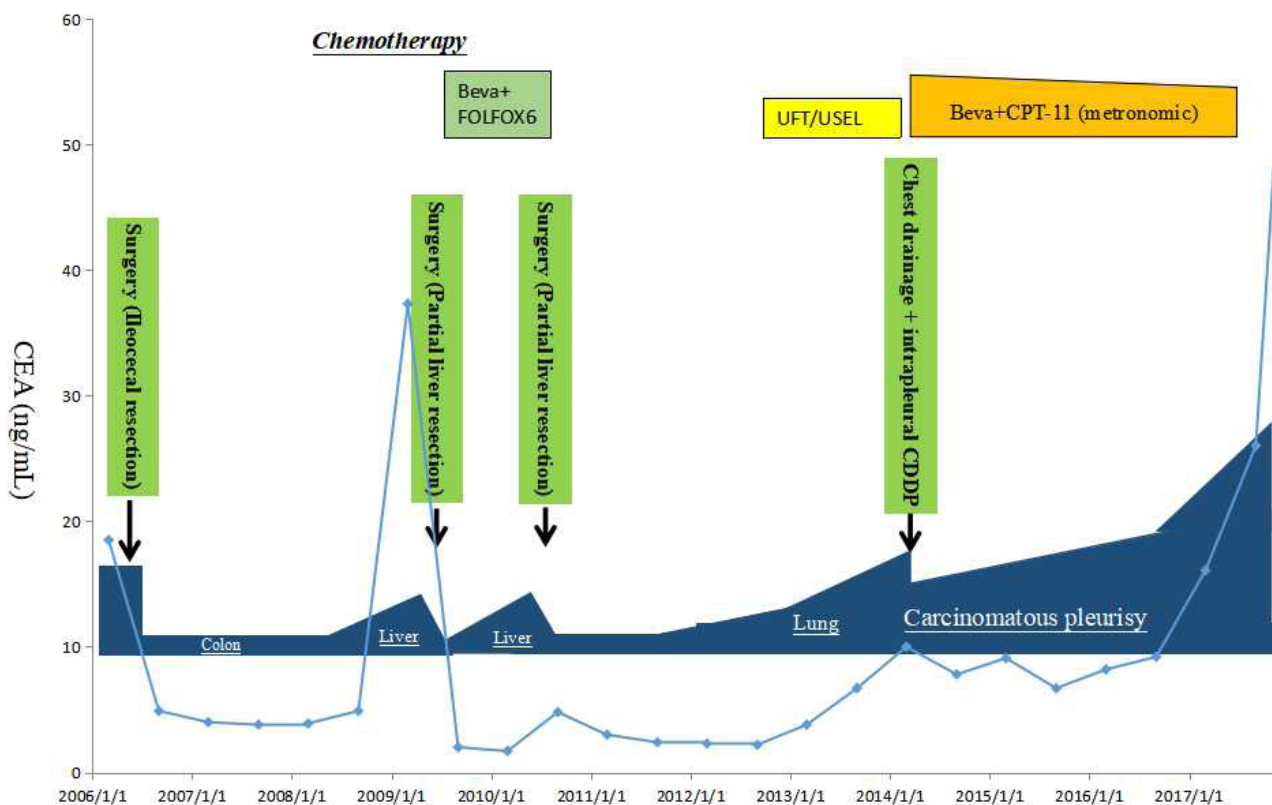


Figure 3 The whole clinical course of the current patient with serial changes in serum CEA values. Abbreviations: CEA; carcinoembryonic antigen, CDDP; cisplatin, Beva; Bevacizumab, CPT-11; irinotecan.

drainage, chemical pleurodesis, and intrapleural administration of antineoplastic agents such as cisplatin. Although the current mode of therapy can occasionally alleviate the symptoms, the relapse rate is as high as 50%^[1].

Vascular endothelial growth factor (VEGF) is an endothelial cell-specific growth factor that stimulates vasculogenesis and angiogenesis, and has been shown to be an essential intermediate in the formation of pleural effusions^[2,3]. Synthesis of VEGF by both autocrine and paracrine pathways has shown it to be present in multiple solid cancers^[4]. It is well documented that bevacizumab, a humanized monoclonal antibody against VEGF, is able to directly inhibit proliferation, migration and differentiation of vascular endothelial cells. It can also promote apoptosis of endothelial cells and suppress VEGF-induced neoangiogenesis and vascular permeability^[5], leading to synergize with chemotherapeutic agents to block the accumulation of pleural fluid^[6-8]. In the current report, we achieved the 5-year long-term survival octogenarian case of cancerous pleurisy from colorectal cancer. Thus, bevacizumab is one of the promising options for the clinical management of cancerous pleurisy from different carcinomas, even in an elderly with relatively poor performance status.

REFERENCES

1. Du N, Li X, Li F, et al. Intrapleural combination therapy with bevacizumab and cisplatin for non-small cell lung cancer-mediated malignant pleural effusion. *Oncol Rep.* 2013; **29**(6): 2332-2340. [PMID: 23525453]; [DOI: 10.3892/or.2013.2349]
2. Senger D, Galli S, Dvorak A, Perruzzi C, Harvey V, Dvorak H. Tumor cells secrete a vascular permeability factor that promotes accumulation of ascites fluid. *Science.* 1983 Feb 25; **219**(4587): 983-5. [PMID: 6823562]; [DOI: 10.1126/science.6823562]
3. Fontanini GI, Faviana P, Lucchi M, Boldrini L, Mussi A, Camacci T, Mariani MA, Angeletti CA, Basolo F, Pingitore R. A high vascular count and overexpression of vascular endothelial growth factor are associated with unfavourable prognosis in operated small cell lung carcinoma. *Br J Cancer.* 2002; **86**(4): 558-563. [PMID: 11870537 PMCID: PMC2375289]; [DOI: 10.1038/sj.bjc.6600130]
4. Kobold S, Hegewisch-Becker S, Oechsle K, Jordan K, Bokemeyer C, Atanackovic D. Intrapleural VEGF Inhibition Using Bevacizumab: A Potential Approach for the Symptomatic Treatment of Malignant Ascites? *Oncologist.* 2009; **14**(12): 1242-1251. [PMID: 20008305]; [DOI: 10.1634/theoncologist.2009-0109]
5. Ferrara N, Gerber H-P, LeCouter J. The biology of VEGF and its receptors. *Nat Med.* 2003; **9**(6): 669-676. [PMID: 12778165]; [DOI: 10.1038/nm0603-669]
6. Pichelmayr O, Zielinski C, Raderer M. Response of a Nonmalignant Pleural Effusion to Bevacizumab. *N Engl J Med.* 2005; **353**(7): 740-741. [PMID: 16107633]; [DOI: 10.1056/NEJM200508183530722]
7. Cohen MH, Gootenberg J, Keegan P, Pazdur R. FDA Drug Approval Summary: Bevacizumab (Avastin(R)) Plus Carboplatin and Paclitaxel as First-Line Treatment of Advanced/Metastatic Recurrent Nonsquamous Non-Small Cell Lung Cancer. *Oncologist.* 2007; **12**(6): 713-718; [DOI: 10.1634/theoncologist.12-6-713]
8. Teixeira LR, Vargas FS, Acencio MMP, et al. Blockage of vascular endothelial growth factor (VEGF) reduces experimental pleurodesis. *Lung Cancer.* 2011; **74**(3): 392-395. [PMID: 21616551]; [DOI: 10.1016/j.lungcan.2011.04.015]