

Diagnostic Value of Endoscopic Ultrasonography in Evaluation of Undetermined Etiology of Bile Ducts Dilation in Imaging

Samir Mrabti¹, Hassan Seddik¹, Hanae Boutallaka¹, Khaoula Loubaris¹, Tarik Adajou¹, Asmae Sair¹, Ahlame Benhamdane¹, Reda Berraida¹, Sara Sentissi¹, Ilham El Koti¹, Ahmed Benkirane¹

¹ Hepato-gastroenterology II department of the HMI Med V Rabat, FAR Avenue, Hay Riad, postal address 1018, Rabat, Morocco.

Conflict-of-interest statement: The author(s) declare(s) that there is no conflict of interest regarding the publication of this paper.

Open-Access: This article is an open-access article which was selected by an in-house editor and fully peer-reviewed by external reviewers. It is distributed in accordance with the Creative Commons Attribution Non Commercial (CC BY-NC 4.0) license, which permits others to distribute, remix, adapt, build upon this work non-commercially, and license their derivative works on different terms, provided the original work is properly cited and the use is non-commercial. See: <http://creativecommons.org/licenses/by-nc/4.0/>

Correspondence to: Samir Mrabti, Hepato-gastroenterology II department of the HMI Med V Rabat, FAR Avenue, Hay Riad, postal address 1018, Rabat, Morocco.
Email: doc.mrabti@gmail.com
Telephone: +212650804122

Received: July 24, 2019

Revised: August 29, 2019

Accepted: September 1, 2019

Published online: October 21, 2019

ABSTRACT

AIM: The aim is to determine the role of endoscopic ultrasonography in assessment of etiological diagnosis of bile ducts dilation when conventional imaging is inconclusive.

BACKGROUND: Endoscopic ultrasonography (EUS) is an effective and primordial procedure in exploration of abnormalities of biliopancreatic junction. However, its results depend of the operator expertise, and its availability is currently insufficient in our regions.

METHODS: This is a retrospective descriptive study conducted from January 2008 to May 2019, including 42 patients with intra- and/or extra-hepatic bile duct dilatation without visible obstacle on imaging. TODANI classification was considered for common bile duct (CBD) cystic dilations. Statistical analysis was performed by SPSS software version 24.0.

RESULTS: We enrolled 42 patients responding to inclusion criteria in the study, which represented 10.18% of all indications of EUS. The mean age of our patients was 59.05 ± 13.11 years, with a female predominance. Endoscopic findings showed a normal papilla in 92.9%. EUS showed a dilated CBD in 66.8% of cases, she has allowed to make the diagnosis of a cystic dilation of CBD in 52.4%, predominated by type Ia and Ib in 45.2% and 4.8% respectively, of ampulloma in 4.8% ($n = 2$), papillomatosis of the bile ducts in 2.4% ($n = 1$), one case of pancreatic head tumor (2,4%), and choledocholithiasis in 4.8% ($n = 2$). By against EUS showed no expansion in 33.3% ($n = 14$).

CONCLUSION: Our study confirms the prominent place of EUS in etiological profile of bile ducts dilatations when imaging is inconclusive.

Key words: Common bile duct diseases; Endosonography; Bile ducts

© 2019 The Author(s). Published by ACT Publishing Group Ltd. All rights reserved.

Mrabti S, Seddik H, Boutallaka H, Loubaris K, Adajou T, Sair A, Benhamdane A, Berraida R, Sentissi S, El Koti I, Benkirane A. Diagnostic Value of Endoscopic Ultrasonography in Evaluation of Undetermined Etiology of Bile Ducts Dilation in Imaging. *Journal of Gastroenterology and Hepatology Research* 2019; **8(5)**: 2975-2979 Available from: URL: <http://www.ghrnet.org/index.php/joghr/article/view/2642>

INTRODUCTION

Endoscopic ultrasonography (EUS) has revolutionized the management of bilio-pancreatic diseases over the last 20 years. Its frequent use is only a solid proof of the radical change in the management of bilio pancreatic diseases and consequently to progress therapeutically.

It is a technique which is operator dependent, and more efficient and less invasive after the first-line examination, the transabdominal ultrasound (TU), which is a quick and inexpensive method, but it depends mainly on the operator and the ultrasound image quality especially in case of significant panniculus adiposus or aerocoly

preventing exploration of the bile ducts. Its accuracy is notably superior to computed tomography (CT) and magnetic resonance cholangiopancreatography (MRCP).

Endoscopic ultrasonography is an alternative to all the usefulness of the aforementioned imaging, which allows a clear study on the biliary anatomy and to facilitate a histological study if necessary. Unfortunately few studies in the literature have clearly dealt with this subject.

METHODS

This is a retrospective descriptive study conducted from January 2008 to May 2019 in our department, including 42 patients with intra- and / or extra-hepatic bile duct dilatation without visible obstacle on imaging. The examination was performed by radial endoscopic ultrasound (Olympus GF-UE 260); patients were left lateral decubitus with sedation by propofol. EUS was supplemented, if necessary, by an endoscopic biliary sphincterotomy for biliary drainage or a biopsy for pathological anatomy study.

The inclusion criteria of our study were: Transabdominal ultrasound, computed tomography or magnetic resonance cholangiopancreatography biliary inconclusive, showing bile ducts dilation without visible obstacle.

The dilation of bile ducts was defined as a diameter of more than 2 mm for intra hepatic bile ducts beyond the first division, more than 7 mm for CBD for patients never operated, and more than 10 mm for patients whom underwent cholecystectomy.

RESULTS

Over a period of 19 years, 42 patients were collected which represents 10, 18% of all the indications of endoscopic ultrasonography. 78, 6% ($n = 33$) were women and, with a sex ratio M / F: 0.2.

The mean age of our patients was 59.05 ± 13.11 (28-80) years. 11.9% ($n = 5$) of our patients had a history of cholecystectomy. Endoscopic findings showed a normal papilla in 92.9% ($n = 39$), an increase in volume papilla in 4, 8% ($n = 2$), and one of our patient had an impenetrable bulbar stricture making impossible the transbulbar ultrasonography. EUS showed a dilated CBD in 66.8% of cases ($n = 28$), with a mean diameter of respectively $9.3 \text{ mm} \pm 3.06 \text{ mm}$ and $7.5 \text{ mm} \pm 2.5 \text{ mm}$ in its upper and retropancreatic portion.

Endoscopic ultrasonography allowed to make the diagnosis of a cystic dilation of CBD in 52.4% ($n = 22$), predominated by type Ia ($n = 19$) and Ib ($n = 2$) in 45,2 % and 4,8% respectively, of ampulloma in 4,8% ($n = 2$), one case of pancreatic head (2,4%) which were first diagnosed by the areolar honeycomb aspect of the head of the pancreas for the first and the discovery of a mass of 30 mm / 20 mm for the second. The malignant nature was confirmed histologically by biopsy. Papillomatosis of the bile ducts in 2,4% ($n = 1$) and the choledocholithiasis in 4,8% ($n = 2$). In this case, endoscopic ultrasonography was coupled with the therapeutic endoscopic retrograde cholangiopancreatography allowing stones extraction after biliary endoscopic sphincterotomy. In the other hand, EUS showed no expansion in 33,2% ($n = 14$).

DISCUSSION

The bile ducts dilatation can have several causes including choledocholithiasis, pancreatic head mass, ampulloma, papillary stenosis, and dysfunction of the Oddi sphincter^[1,2]. It can occur at any age and even in cholecystectomized patients^[2,3].

The transgastric and transbulbar EUS is an excellent method for studying the bile ducts, especially when the conventional imaging is inconclusive (transabdominal ultrasound (TU), computed tomography (CT) or magnetic resonance cholangiopancreatography (MRCP)) by dint of ultrasound emitted in real time and high resolution by the duodenoscope in place near the extrahepatic bile ducts, in addition to its ability to fully explore the duodenum wall including the papillary region^[17-18].

A study conducted in the United States, collected 90 patients with dilatation of the bile ducts without visible obstacle to the MRCP, an etiological diagnosis by EUS was conducted in 92% of cases^[4]. Biliary stones that develop in about 10% to 20% of patients, not always be identified by traditional imaging means^[5]. The sensitivity of CBD stones detection is 18% to 74% for TU, and 50% to 90% for CT^[6,7,8].

However, EUS is considered a gold standard in the detection of CBD stones, especially if they are less than 5 mm in diameter, which are sometimes not identified by MRCP^[9], with a sensitivity that can reach 90% for the detection of CBD stones^[10-12].

In the study of Fernández-Esparrach *et al*^[13] in patients with dilatation of CBD, the EUS allowed an accurate diagnosis of choledocholithiasis in 49% to 84%. In a meta-analysis published in 2008 on the performance of EUS in the detection of choledocholithiasis, the authors proposed that EUS be included in the diagnostic algorithm of patients with doubts about biliary vacuity^[14].

Lédinghen *et al*^[19] reported a negative predictive value of 100% of EUS in the diagnosis of biliary stones, excluding the need for further investigation and limiting unnecessary surgical procedures.

In the more recent study, Scheiman *et al*^[20], confirms that EUS was the most useful test for confirming a normal biliary tree, avoiding unnecessary ERCP and preventing its complications^[21].

In the other hand, there is another cause of dilation of the bile ducts, including CBD cystic dilation, which are of congenital origin, usually diagnosed in childhood, but which can be diagnosed even in adulthood in 25 % cases^[15-16]. They are characterized by communicating cystic dilations of intra hepatic or extra hepatic bile duct. The classification of TODANI plays an important role in knowing the seat, the type and the shape of the distribution of the malformation (Figure 1). It is the only cause of biliary malformation after biliary atresia^[23]. The incidence of congenital cystic dilatation of the bile ducts is very high in South Asia and Japan^[24].

Many hypotheses have explained the origin of these malformations^[24-27]. The most accepted is that which was evoked by Babbit in 1969 and which incriminated an anomaly of the biliopancreatic junction^[28].

This fusion malformation between the bile ducts and pancreatic duct is characterized by three criteria: (1) CBD at 15 mm length; (2) An extra duodenal junction of the two ducts, away from the sphincters; (3) And a connection angle greater than 30°^[29-30].

This bilio-pancreatic maljunction is one of the hypotheses explaining the CBD cystic dilations. In our series, it was seen in 52, 4% of cases without any case of malignant degeneration.

The EUS has a specificity and a high sensitivity in the detection of the pancreatic tumors, for this, our study confirms that one could have surprises in EUS, indeed, this last one can show a suspicious mass of the head of the pancreas, whose malignant nature is confirmed by biopsy using a linear echo-endoscopy. On the other hand, in the case of a papillary tumor, the biopsy can be performed at the time of duodenoscopy with a high sensitivity and specificity^[31-33].

Among the rare diagnoses that were mentioned in our study:

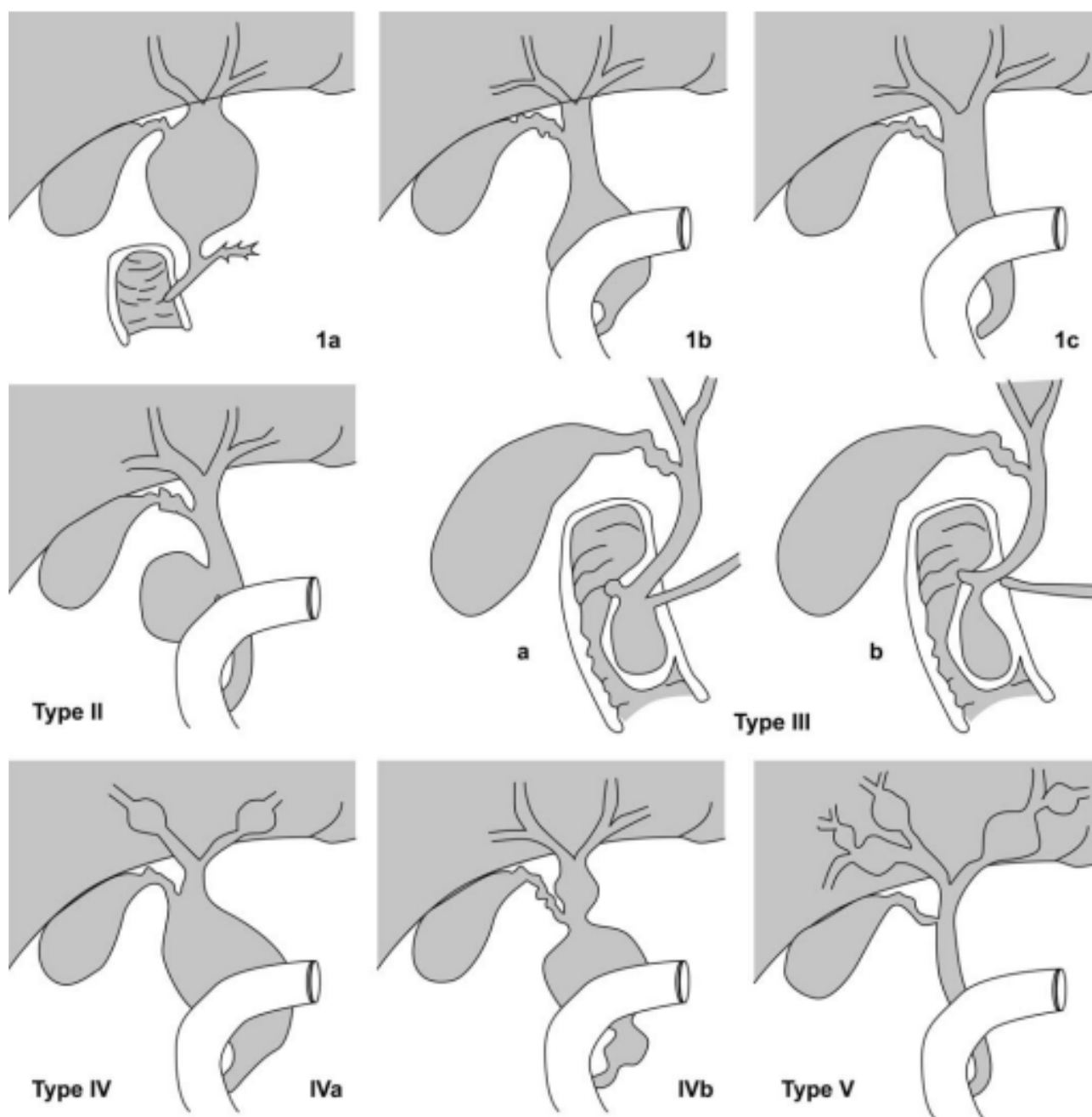


Figure 1 TODANI classification[36]. Type I (80%): extra hepatic Cystic dilatation; Type II (10%): Supra duodenal diverticulum of the CBD; Type III (4%): Choledochocoele; Type IV (11%): a: Dilatation of extra and intra hepatic bile duct, b: Multiple extra hepatic cysts; Type V (<1%): Isolated dilatation of the intrahepatic bile ducts.

Papillomatosis of the bile ducts, it is a papillary adenomatosis of the mucosa of intra and / or extrahepatic bile duct and also affecting the gallbladder, of slow evolution, of male predominance, recognized and classified by OMS among benign biliary epithelial tumors. The extensive nature of the lesions on the biliary tree, frequent tumor recurrence after resection and the high risk of malignant transformation make it difficult to manage this pathology^[34].

There are two types of papillomatosis: a type without secretion of mucin, and secreting type. The later has the ability to secrete a large amount of mucus responsible for bile duct obstruction and therefore upstream dilatation^[35]. Imaging (TU or CT) can guide the diagnosis, but endoscopic ultrasonography is a reliable test showing the dilatation of the bile ducts and the presence of mucus in them. But the diagnosis of certainty requires cytological sampling after endoscopic

retrograde cholangiography or cholangioscopy allowing a cytological study to get an idea of the degree of dysplasia and invasion of the chorion^[35]. In our series, papillomatosis was seen in only one case was treated surgically. This patient has received surgical treatment.

On other way, 33.2% of our patients showed no bile duct dilatation in EUS.

CONCLUSION

Our study confirms the efficacy and safety of endoscopic ultrasonography in the diagnosis of undetermined etiology of bile ducts dilation in imaging with high specificity and sensitivity.

All persons gave their informed consent prior to their inclusion in the study.

REFERENCES

- Holm AN, Gerke H. What should be done with a dilated bile duct? *Curr Gastroenterol Rep* 2010; **12**: 150-156. [PMID: 20424988]; [DOI: 10.1007/s11894-010-0094-3]
- Niederer C, Sonnenberg A, Mueller J. Comparison of the extrahepatic bile duct size measured by ultrasound and by different radiographic methods. *Gastroenterology* 1984; **87**: 615-621. [PMID: 6745614]
- Kaim A, Steinke K, Frank M, Enriquez R, Kirsch E, Bongartz G, Steinbrich W. Diameter of the common bile duct in the elderly patient: measurement by ultrasound. *Eur Radiol* 1998; **8**: 1413-1415. [PMID: 9853225]; [DOI: 10.1007/s003300050563]
- Songur Y, Temucin G, Sahin B. Endoscopic ultrasonography in the evaluation of dilated common bile duct. *J Clin Gastroenterol* 2001; **33**: 302-305. [PMID: 11588544]
- Ledro-Cano D. Suspected choledocholithiasis: endoscopic ultrasound or magnetic resonance cholangio-pancreatography A systematic review. *Eur J Gastroenterol Hepatol*. 2007; **19**: 1007-1011. [DOI: 10.1097/MEG.0b013e328133f30b]
- Laing FC, Jeffrey RB, Wing VW, Nyberg DA. Biliary dilatation: defining the level and cause by real-time US. *Radiology*. 1986; **160**: 39-42. [PMID: 3012631]; [DOI: 10.1148/radiology.160.1.3012631]
- Baron RL. Common bile duct stones: reassessment of criteria for CT diagnosis. *Radiology*. 1987; **162**: 419-424. [PMID: 3797655]; [DOI: 10.1148/radiology.162.2.3797655]
- Palazzo L, Girollet PP, Salmeron M, Silvain C, Roseau G, Canard JM, Chaussade S, Couturier D, Paolaggi JA. Value of endoscopic ultrasonography in the diagnosis of common bile duct stones: comparison with surgical exploration and ERCP. *Gastrointest Endosc*. 1995; **42**: 225-231. [PMID: 7498687]; [DOI: 10.1016/s0016-5107(95)70096-x]
- Kondo S, Isayama H, Akahane M, Toda N, Sasahira N, Nakai Y, *et al.* Detection of common bile duct stones: comparison between endoscopic ultrasonography, magnetic resonance cholangiography, and helical-computed-tomographic cholangiography. *Eur J Radiol*. 2005; **54**: 271-275. [DOI: 10.1016/j.ejrad.2004.07.007]
- Gan SI, Rajan E, Adler DG, Baron TH, Anderson MA, Cash BD *et al.* Role of EUS. *Gastrointest Endosc*. 2007; **66**: 425-434. [DOI: 10.1016/j.gie.2007.05.026]
- Buscarini E, Tansini P, Vallisa D, Zambelli A, Buscarini L. EUS for suspected choledocholithiasis: do benefits outweigh costs A prospective, controlled study. *Gastrointest Endosc*. 2003; **57**: 510-518. [PMID: 12665761]; [DOI: 10.1067/mge.2003.149]
- Kohut M, Nowakowska-Duława E, Marek T, Kaczor R, Nowak A. Accuracy of linear endoscopic ultrasonography in the evaluation of patients with suspected common bile duct stones. *Endoscopy*. 2002; **34**: 299-303. [PMID: 11932785]; [DOI: 10.1055/s-2002-23641]
- Fernández-Esparrach G, Ginès A, Sánchez M, Pagés M, Pellisé M, Fernández-Cruz L, López-Boado MA, Quintó L, Navarro S, Sendino O, Cárdenas A, Ayuso C, Bordas JM, Llach J, Castells A. Comparison of endoscopic ultrasonography and magnetic resonance cholangiopancreatography in the diagnosis of pancreatobiliary diseases: a prospective study. *Am J Gastroenterol*. 2007; **102**: 1632-1639. [PMID: 17521400]; [DOI: 10.1111/j.1572-0241.2007.01333.x]
- Tse F, Liu L, Barkun AN, Armstrong D, Moayyedi P. EUS: a meta-analysis of test performance in suspected choledocholithiasis. *Gastrointest Endosc*. 2008; **67**: 235-244. [PMID: 18226685]; [DOI: 10.1016/j.gie.2007.09.047]
- Visser BC, Suh I, Way LW, Kang SM. Congenital choledochal cysts in adults. *Arch Surg*. 2004; **139**: 855-860; discussion 860-862. [PMID: 15302695]; [DOI: 10.1001/archsurg.139.8.855]
- Liu CL, Fan ST, Lo CM, Lam CM, Poon RT, Wong J. Choledochal cysts in adults. *Arch Surg*. 2002; **137**: 465-468. [PMID: 11926955]
- ASGE Standards of Practice Committee, Early DS, Acosta RD, Chandrasekhara V, Chathadi KV, Decker GA, Evans JA, Fanelli RD, Fisher DA, Fonkalsrud L, Hwang JH, Jue TL, Khashab MA, Lightdale JR, Muthusamy VR, Pasha SF, Saltzman JR, Sharaf RN, Shergill AK, Cash BD. Adverse events associated with EUS and EUS with FNA. *Gastrointest Endosc*. 2013; **77**: 839-843. [PMID: 23684089]; [DOI: 10.1016/j.gie.2013.02.018]
- Amouyal P, Palazzo L, Amouyal G, Ponsot P, Mompoin D, Vilgrain V, Gayet B, Fléjou JF, Paolaggi JA. Endosonography: promising method for diagnosis of extrahepatic cholestasis. *Lancet*. 1989; **2**: 1195-1198. [PMID: 2572911]
- de Lédinghen V, Lecesne R, Raymond JM, Gense V, Amouretti M, Drouillard J, Couzigou P, Silvain C. Diagnosis of choledocholithiasis: EUS or magnetic resonance cholangiography. A prospective controlled study. *Gastrointest Endosc*. 1999; **49**: 26-31. [PMID: 9869719]
- Scheiman JM, Carlos RC, Barnett JL, Elta GH, Nostrant TT, Chey WD, *et al.* Can endoscopic ultrasound or magnetic resonance cholangiopancreatography replace ERCP in patients with suspected biliary disease A prospective trial and cost analysis. *Am J Gastroenterol*. 2001; **96**: 2900-2904. [DOI: 10.1111/j.1572-0241.2001.04245.x]
- Anderson MA, Fisher L, Jain R, Evans JA, Appalaneni V, Ben-Menachem T, *et al.* Complications of ERCP. *Gastrointest Endosc*. 2012; **75**: 467-473. [DOI: 10.1016/j.gie.2011.07.010]
- Mercadier M, Chigot JP, Clot JP, Langlois P, Lansinaux P. Caroli disease. *World J Surg* 1984; **8**: 22-9. [PMID: 6367232]
- Kianmanesh R, Régimbeau JM, Belghiti J. Anomalies de la jonction biliopancréatique et dilatations kystiques congénitales des voies biliaires. *J Chir (Paris)* 2001; **138-4**: 196-204
- Olbourne NA. Choledochal cyst: a review of the cystic anomalous of the biliary tree. *Ann R Coll Surg Engl* 1975; **56**: 26-32. [PMID: 1096740]
- Nagata E, Sakai K, Kinoshita H, Hirohashi K. Choledochal cyst: complications of anomalous of the biliary tract. *World J Surg* 1986; **10**: 102-10. [PMID: 3962321]
- Lacheretz M, Debeugry YP, Bonnevalle M. Etiologie de la dilatation congénitale du choledoque chez l'enfant. *Chirurgie* 1986; **114**: 111-4
- Desmet VJ. Congenital diseases of intrahepatic bile ducts: variations on the theme "ductal plate malformation". *Hepatology* 1992; **16**: 1069-83. [PMID: 1398487]
- Babbit DP. Congenital choledochal cyst: new etiological concepts based on anomalous relationship of the common bile duct and pancreatic bulb. *Ann Radiol* 1969; **12**: 231-40. [PMID: 5401505]
- The Japanese study group on pancreatobiliary maljunction. Diagnostic criteria of pancreatobiliary maljunction. *J Hepatobiliary Pancreatol Surg* 1994; **1**: 219-21
- Iwai N, Tokiwa K, Yanagihara J, Takahashi T. Biliary manometry in choledochal cyst with abnormal choledochopancreatic ductal junction. *J Ped Surg* 1986; **21**: 873-6. [PMID: 2431131]
- Tsukada K, Takada T, Miyazaki M, Miyakawa S, Nagino M, Kondo S, Furuse J, Saito H, Tsuyuguchi T, Kimura F, Yoshitomi H, Nozawa S, Yoshida M, Wada K, Amano H, Miura F; Japanese Association of Biliary Surgery; Japanese Society of Hepato-Biliary-Pancreatic Surgery; Japan Society of Clinical Oncology. Japanese Association of Biliary Surgery; Japanese Society of Hepato-Biliary-Pancreatic Surgery; Japan Society of Clinical Oncology. Diagnosis of biliary tract and ampullary carcinomas. *J Hepatobiliary Pancreat Surg* 2008; **15**: 31-40. [PMID: 18274842]
- Crone-Münzebrock W, Rowedder A, Meyer-Pannwitz U, Kremer B. Comparative efficacy of sonography, computed tomography, ERCP and angiography in the diagnosis of primary papillary carcinomas. *Rontgenblätter* 1990; **43**: 266-9. [PMID: 2196668]
- Moreira VF, Meroño E, del Olmo L, Simón MA, Fernández Rodríguez C, Fernández Seara J, Gil Grande L, Ruiz del Arbol L. Endoscopic retrograde cholangiopancreatography in the diagnosis of carcinomas of Vater's ampulla (ampulloma). *Rev Esp Enferm*

Apar Dig 1985; **67**: 524-9. [PMID: 3895319]

34. Albores-Saavedra J, Scoazec JY, Wittekind C, Sripa B, Menck HR, Soehendra N. *et al.* in Hamilton SR, Aaltonen LA. World Health Organization Classification of Tumors. Pathology and Genetics Of tumors of the Digestive System. Lyon: IARC Press, 2000.
35. Lee SS, Kim MH, Lee SK, Jang SJ, Song MH, Kim KP, Kim HJ, Seo DW, Song DE, Yu E, Lee SG, Min YI. Clinicopathologic review of 58 patients with biliary papillomatosis. *Cancer* 2004; **100**: 783-93. [PMID: 14770435]; [DOI: 10.1002/cncr.20031]
36. S. Mannai *et al.* *Annales de chirurgie* 131 (2006) 369-374. [DOI: 10.1016/j.anchir.2006.03.008]