

Stricture post Hepatico-Jejunostomy. Radiological and Endoscopic Management

Morsi Mohamed¹, Wael Mansy¹, Samir Ibrahim², Sameh Saber³, Mohamed Farouk⁴

1 Assistant professor of hepato-biliary surgery, Faculty of medicine, Zagazig University, Egypt;

2 Professor of general surgery, Faculty of medicine, Zagazig University, Egypt;

3 Lecturer of intervention radiology, Faculty of medicine, Zagazig University; Zagazig University, Egypt;

4 Lecturer of general surgery, Faculty of medicine, Zagazig University, Egypt.

Conflict-of-interest statement: The authors declare that there is no conflict of interest regarding the publication of this paper.

Open-Access: This article is an open-access article which was selected by an in-house editor and fully peer-reviewed by external reviewers. It is distributed in accordance with the Creative Commons Attribution Non Commercial (CC BY-NC 4.0) license, which permits others to distribute, remix, adapt, build upon this work non-commercially, and license their derivative works on different terms, provided the original work is properly cited and the use is non-commercial. See: <http://creativecommons.org/licenses/by-nc/4.0/>

Correspondence to: Wael Mansy, Assistant professor of hepatobiliary surgery, Zagazig University, Egypt.
Email: drwaelmansy@hotmail.com

Received: August 16, 2019

Revised: October 18, 2019

Accepted: October 30, 2019

Published online: December 21, 2019

ABSTRACT

INTRODUCTION: The Roux-en-Y hepatico-jejunostomy (HJ) is the main and commonest approach in reconstruction of the biliary system after its injury. Stricture formation may be complicating this procedure, which can lead to multiple hospitalizations and procedures for management. Management options involve interventional radiology via percutaneous transhepatic drainage (PTD), endoscopic procedures or reoperation of the biliary tract.

PATIENTS AND METHODS: This study was carried out between May 2010 and December 2018 on 18 patients complaining from post

HJ stricture. Patients divided into two groups: Group A percutaneous trans-hepatic approach done for 11 patients. Group B included 7 patients with access loop technique, endoscopic approach done for them.

RESULTS: This study included 18 patients [15 females (83.3%) and 3 males (16.7%)] with mean ages of (32.09 ± 8.96) and (36.42 ± 7.06) of group A and B respectively. Success rate in Group A was (81.8%) in 9 patients, while failure rate was (18.2%) in 2 patients which necessitates redo of HJ. While success rate in Group B was (85.7%) in 6 patients, and failure rate was (14.3%) in 1 patient. Also HJ was done for this patient.

CONCLUSION: Minimally invasive procedures for post HJ biliary stricture either percutaneous or endoscopic via access loop must be considered as the first line of management.

Key words: Hepatico-Jejunostomy; Biliary Stricture; Percutaneous Transhepatic; Endoscopic Management

© 2019 The Authors. Published by ACT Publishing Group Ltd. All rights reserved.

Mohamed M, Mansy W, Ibrahim S, Saber S, Farouk M. Stricture post Hepatico-Jejunostomy. Radiological and Endoscopic Management. *Journal of Gastroenterology and Hepatology Research* 2019; **8(6)**: 3049-3053 Available from: URL: <http://www.ghrnet.org/index.php/joghr/article/view/2665>

INTRODUCTION

The Roux-en-Y HJ is the main way of management for reconstruction of the biliary system after its injury. Using the jejunum allows safe and permissive anastomosis with less frequent postoperative bile leakage even if the anastomosis involves small intrahepatic branches^[1]. It is recommended if a part of the CBD is lost as in such cases of bile duct injuries^[2].

Less common indications for HJ include trauma, choledochal cyst resections, previous biliary-enteric operations with subsequent stricture formation and liver transplantation. Gallbladder carcinomas infiltrating the CBD or hepatic ducts and cholangio-carcinomas may also be indications^[3].

Stricture is one of the long term complications after biliary-

enteric anastomosis, which can lead to multiple hospitalizations and management procedures. Postoperative stricture at the anastomotic site varies from (4-38%) of patients throughout the literature^[4]. Other complications involve intra-hepatic gallstones and chronic cholestasis^[5].

Management options involve interventional radiology, endoscopic procedures or reoperation of the biliary tract, are often challenging owing to multiple intra-hepatic surgical anastomoses. To access the biliary tract in cases of recurrent stenosis, an access loop from the HJ to the abdominal wall to permit further endoscopic approach to the biliary-enteric anastomosis^[5]. Also gastric access loop, jejuno-duodenostomy and Jejunal loop interposition may be used^[6].

In these patients, Double balloon endoscopy have been used as beneficial in performing ERCP with diagnostic success rate (82%-93%) and a therapeutic success rate (52%-75%)^[7]. PTD followed by stricture dilation with balloons often offers the patient a quicker recovery and far less morbidity than surgery^[8].

PATIENTS AND METHODS

This is a controlled study done between the period May 2010 and December 2018 in the General Surgery Department and Hepato-Pancreatico-Biliary unit at Zagazig University Hospitals. HJ was

done for different indications by hepato-biliary experienced surgeons in 102 patients, while HJ with access loop was done by general surgery doctors in 15 patients. We had 18 patients complained from biliary obstruction symptoms post HJ. Patients had been grouped into A and B; group A of (11/102) patients without access loop that were subjected to percutaneous trans-hepatic management. Group B of (7/15) patients with endoscopic access that were subjected to endoscopic management (Table 1).

Our patients were presented by biliary complications as jaundice, recurrent attacks of abdominal pain, dark urine, fever or itching. These patients were subjected to the following preoperative evaluations: history of previous surgical operations, demographic data, clinical examination and full laboratory investigation. MRCP was done in all patients to determine site, degree of stenosis and possible modality of management.

Management of these patients:

Group (A): Percutaneous transhepatic management: (1) 11 patients were managed through ultra-sonography guided percutaneous transhepatic intervention to access dilated biliary tree. (2) Biliary balloon dilatation was performed. The balloon is inflated with saline mixed radio-opaque dye for at least 1 minute and is usually re-inflated several times with sequential upsizing. (3)

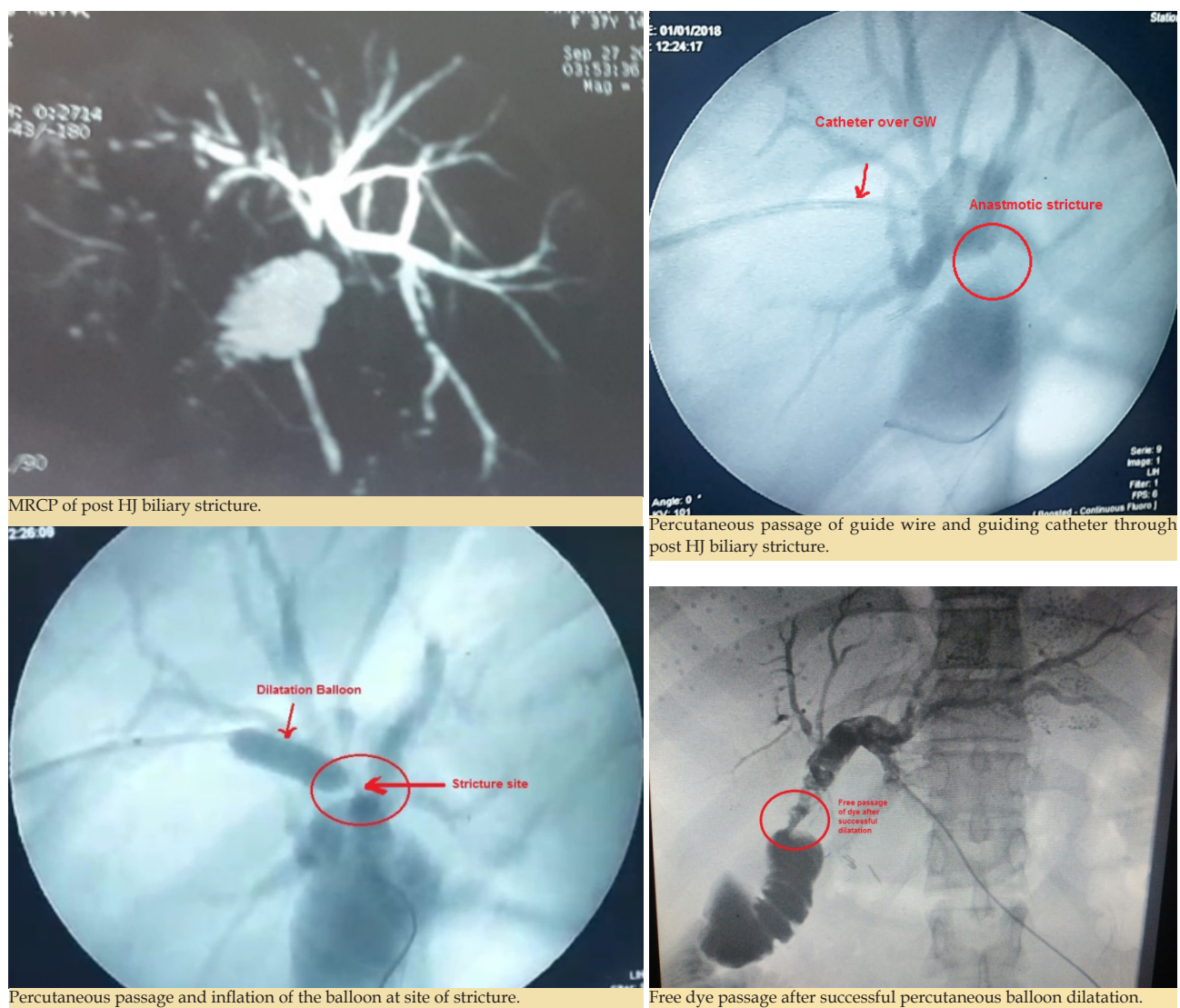


Figure 1 Percutaneous transhepatic balloon dilatation of HJ stricture.

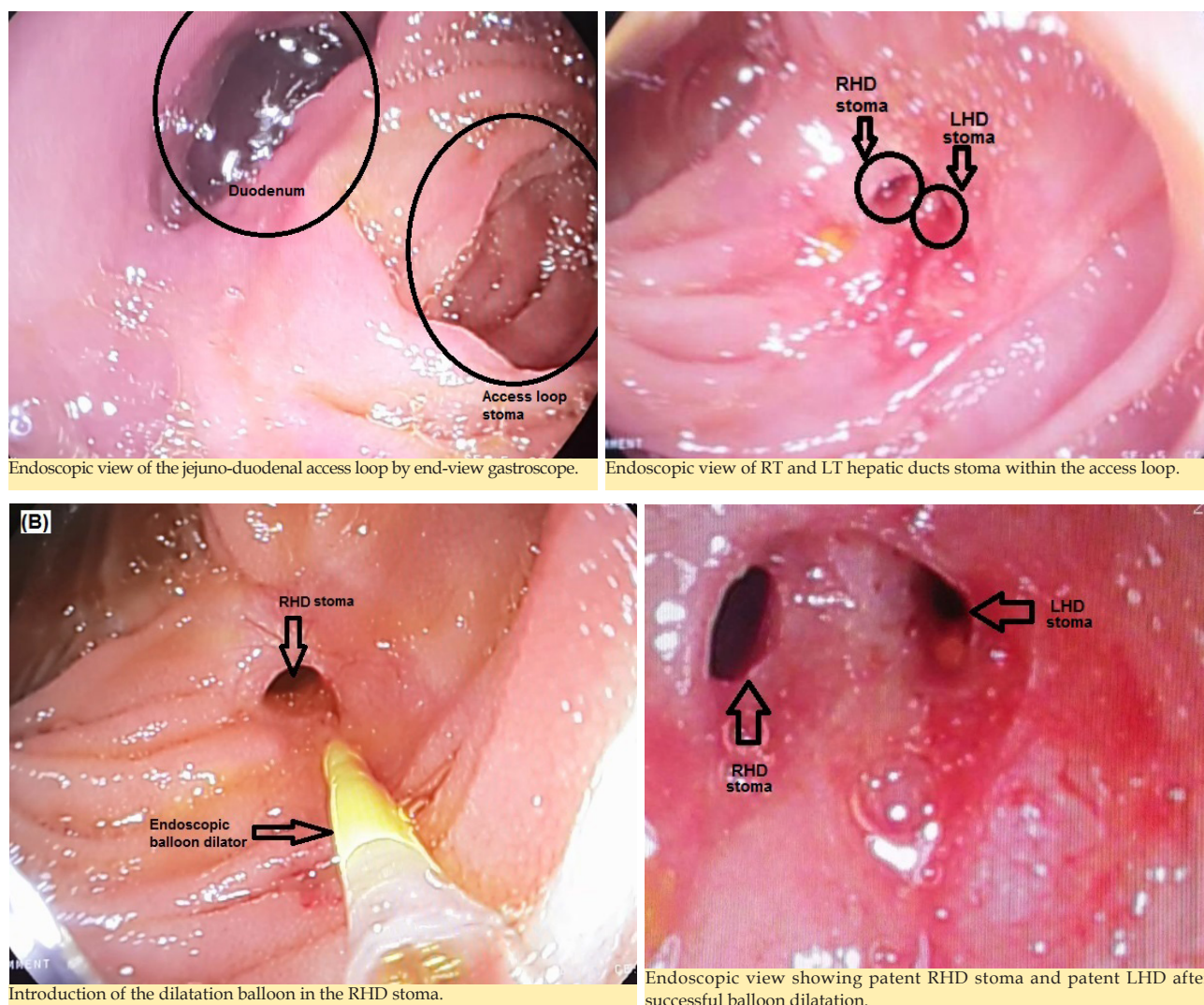


Figure 2 Endoscopic management of HJ stricture with access loop.

Table 1 Type of biliary anastomosis, stricture percentage and ways of management.

Type of Anastomosis	Post Biliary Injury (82 Patients)	Recurrent Primary CBD Stones (20 Patients)	Choledochal Cyst (15 Patients)	Stricture (18 Patients)	Management	Failure (3 Patients)
HJ (102 Patients)	72	15	15	11 (10.8%)	Percutaneous Management	2 (18.2%)
HJ with Access Loop (103 Patients)	10	5	0	7 (53.8%)	Endoscopic Management	1 (14.3%)

Table 2 Reasons for HJ and time of presentation.

			Group		Total (n = 18)	X ²	P
			A (n = 11)	B (n = 7)			
Reason for HJ	Post Cholecystectomy	N	8/72	6/10	14	0.76	0.001*
		%	11.10%	60%			
	Choledochal Cyst	N	1/15	0	1		
		%	6.70%				
Rec. 1ry CBD Stones	N	2/15	1/5	3	0.59		
	%	13.30%	20%				
Time of presentation	1-2 years	N	4	2	6	0.23	0.89
	6m-1 year	N	5	4	9		
	>2 years	N	2	1	3		
Total		N	11/102	7/15	18		0.001*
		%	10.80%	46.70%			

Successful dilation will be evident on cholangiography under C-arm or fluoroscopy guidance with passage of contrast without residual.

Group (B): Endoscopic management via access loop: (1) 7 patients were managed endoscopically via duodeno-jejunal access loop anastomosing the descending part of the Reux loop of

jejunum side to side to first part of duodenum just post pyloric. (2) Endoscopy was performed using end view gastro-scope through the new modification of the jejunoduodenal access loop for endoscope fashioned during HJ surgery. (3) Balloon biliary dilatation was performed with direct visualization. (4) Successful dilation will be

evident by direct visualization of the anastomotic site (Figures 1, 2).

Follow up of all patients

First visit of follow up was after one week of procedure to detect and manage its early complications. Then, visits were after one month, three months and six months respectively. The follow up included: clinical evaluation, laboratory (LFTs) and imaging (abdominal us during follow-up periods and MRCP if there were symptoms).

RESULTS

Most of our patients (14) suffered from stricture after biliary reconstruction in post cholecystectomy biliary injury. Stricture was higher post access loop (6/10), while only 8 patients of 72 patients suffered from stricture done by experienced HPB surgeons with significant difference (p value 0.001). 15 patients suffered from stricture at the first two years (9 in the 1st year and 6 in the 2nd year) (Table 2).

More than one third of our patients in both groups responded after one session and the same after two sessions. While, one patient responded after three sessions of trans-hepatic balloon dilatation but we used metallic stent for him. Failure of the technique occurred in three patients.

One female patient had past history of choledico-jejunostomy with access loop after post cholecystectomy biliary injury. The endoscope failed to pass due to very narrow jejuno-duodenostomy. So, redo of HJ was done at higher level by HPB surgeons. The other two patients were failed with trans-hepatic approach, which necessitates redo of HJ at a higher level also done by HPB surgeons. All now are well.

The hospital stay was 1-2 days with no significant difference between the two groups. There was no mortality and most of the complications were minor that managed with conservative measures. No significant difference between groups in post procedures complications.

DISCUSSION

The sex distribution in our study revealed that HJ were more common in females with a female to male ratio of 15:3. This was in agreement with Cunha *et al.*, Selvakumar *et al* and Abdel Rafee *et al*^[9,10,11] studies which found that gall bladder and CBD stones are more common in females with higher rate for HJ following bile duct injury.

The most common time of presentation of the biliary anastomotic stricture within the first year comprises 50% of our study population. These findings were in some agreement with Luo *et al*^[12] which reported that most cases presented about 9.5 to 11 months after surgery.

Abdominal pain was the most common complaint with different degrees commonly mild in (50%), moderate in (38.9%) and severe in (11.1%) and was followed by jaundice (83.3%) and cholangitis in (72.2%). These findings were nearly to Dadhwal, Kumarl, Cauchy and Belghiti^[13,14] which reported of (80%) of cases presented with cholangitis and most cases had abdominal pain with different degrees.

We used MRCP to diagnose post HJ biliary stricture and determination of level and severity of stricture as the diagnostic modality of choice. This was in agreement with Altman and Zangan, Costamagna and Boškoski and Krokidis *et al*^[15,16,17].

Eleven patients in group A were managed through percutaneous transhepatic intervention and according to Thomas and Köcher^[18]; it is the treatment of choice in these cases. Nine patients showed good

response to therapy over the duration of the study, only one of them needed metallic stent in the third session. And this was in agreement with Janssen *et al*^[19] study in which the success of percutaneous management of post HJ biliary stricture reached (98.5%). Two patients showed recurrent stenosis after repeated dilatation (3 sessions over 9 months) and were scheduled for redo HJ at a higher level and they were well after surgery. On the other hand, House *et al*^[20] study showed that (90%) of patients with benign bile duct stricture can be treated successfully with a percutaneous biliary approach.

Post procedure complications included minimal site of skin entry bleeding that readily controlled in three patients (27.3%) and cholangitis in five patients (45.5%). This was in contrary to Janssen *et al*^[19] study in which sepsis reported in (11.1%) of patients. This may be contributed to different sample sizes, durations of the studies and presentation of cases.

Seven patients in group B were managed endoscopically via jejuno-duodenal access loop. Six (85.8%) patients showed good response to therapy over the study duration; 3 patients (42.9%) needed repeated sessions of dilatation and 3 patients (42.9%) responded well after single session. While the procedure failed in one patient. This was in some agreement with Zepeda-Gómez and Baron^[21] that shows (90%) success rate of endoscopic balloon dilatation post anastomotic stricture. Post procedure complications included cholangitis in two (28.6%) patients. This was in some agreement to Prakash *et al*^[22] study in which cholangitis reported in (26%) of patients.

CONCLUSION

We can conclude that minimally invasive measures for post HJ biliary stricture either percutaneous or endoscopic via access loop must be considered as first line of its management. HJ is the standard technique used for bile duct injury with experienced HPB surgeons.

REFERENCES

- Hirano S, Tanaka E, Tsuchikawa T, Matsumoto J, Shichinohe T and Kato K. Techniques of Biliary Reconstruction Following Bile Duct Resection. *Journal of Hepato-Biliary-Pancreatic Sciences*. 2012; **19**: 203-209. [PMID: 22081253]; [PMCID: : PMC3311849]; [DOI: 10.1007/s00534-011-0475-5]
- Khalaf A. Management of bile duct injuries: comparative study between Roux-en-Y hepaticojejunostomy and primary repair with stent placement. *Journal of the Arab Society for Medical Research*. 2013; **8**: 89-95.
- Sarmiento J. Hepaticojejunostomy: Indications and surgical technique. *Operative Techniques in General Surgery*. 2000; **2**: 295-303.
- Moris D, Papalampros A, Vailas M, Petrou A, Kontos M, Felekouras Evangelos. The Hepaticojejunostomy Technique with Intra-Anastomotic Stent in Biliary Diseases and Its Evolution throughout the Years: A Technical Analysis. *Gastroenterol Res Pract*. 2016; **2016**: 3692096. [PMID: 27190504]; [PMCID: : PMC4846744]; [DOI: 10.1155/2016/3692096]
- Moricz A, Azevedo O, Campos T, Colaiacovo R, Akiba T, Silva R and Pacheco A. Modified "Roux En Y" Hepaticojejunostomy to Permit Transgastric Endoscopic Access. *Acta Cirúrgica Brasileira*. 2014; **29**: 14-16. [PMID: 25351150]; [DOI: 10.1590/s0102-86502014001700003]
- Hamad M and El-Amin H. Bilio-Entero-Gastrostomy: Prospective Assessment of a Modified Biliary Reconstruction with Facilitated Future Endoscopic Access. *BMC Surgery*. 2012; **12**: 9. [PMID: 22720668]; [PMCID: PMC3411507]
- Prachayakul V and Aswakul P. Hepaticojejunostomy Anasto-

- motric Stricture Successfully Treated With Double Stent-In-Stent Technique Using Gastroscope With Overtube Assisted. *Journal of Interventional Gastroenterology*. 2014; **4**: 132-134.
8. Lee A, Gregorius J, Kerlan R, Gordon R, Fidelman N. Percutaneous Transhepatic Balloon Dilatation of Biliary-Enteric Anastomotic Strictures after Surgical Repair of Iatrogenic Bile Duct Injuries. *PLoS ONE*. 2012; **7**: e46478. [PMID: 23110053]; [PMCID: PMC3482176]
 9. Cunha J, Herman P and Machado M, Penteadó S, Maluf Filho F, Jukemura J, Bacchella T and Abdo E. A New Biliary Access Technique for The Long-Term Endoscopic Management Of Intrahepatic Stones. *J Hepatobiliary Pancreat Surg*. 2002; **9**: 261-264.
 10. Selvakumar E, Rajendran E, Balachandar T, Kannan D, Jeswanth S, Ravichandran P, Surendran R. Long-Term Outcome of Gastric Access Loop In Hepaticojejunostomy. *Hepatobiliary Pancreatic diseases international*. 2008; **7**: 152-155. [PMID: 18397849]
 11. AbdelRafee A, El-Shobari M, Askar W, Sultan A, El Nakeeb A. Long-Term Follow-Up of 120 Patients after Hepaticojejunostomy for Treatment of Post-Cholecystectomy Bile Duct Injuries: A Retrospective Cohort Study. *International Journal of Surgery*. 2015; **18**: 205-210. [PMID: 25965917]
 12. Luo Z, Cheng L, Ren J, Tang L, Wang T, Tian F. Progressive Balloon Dilatation Following Hepaticojejunostomy Improves Outcome Of Bile Duct Stricture After Iatrogenic Biliary Injury. *BMC Gastroenterology*. 2013; **13**: 70. [PMID: 23607418]; [PMCID: PMC3637808]
 13. Dadhwal U and Kumar V. Benign Bile Duct Strictures. *Medical Journal Armed Forces India*. 2012; **68**: 299-303.
 14. Cauchy F and Belghiti J. Hepaticojejunostomy Anastomotic Strictures. In: *Gastrointestinal Surgery, Pawlik T, et al. (eds.)*. Springer. New York. 2015; **Ch 23**: 239-248.
 15. Altman A and Zangan S. Benign Biliary Strictures. *Semin Intervent Radiol*. 2016; **33**: 297-306. [PMID: 27904249]; [PMCID: PMC5088102]
 16. Costamagna G and Boškoski I. Current Treatment of Benign Biliary Strictures. *Annals of Gastroenterology*. 2013; **26**: 37-40. [PMID: 24714594]; [PMCID: PMC3959511]
 17. Krokidis M, Orgera G, Rossi M, Matteoli M, Hatzidakis A. Interventional Radiology in The Management of Benign Biliary Stenoses, Biliary Leaks And Fistulas: A Pictorial Review. *Insights Imaging*. 2013; **4**: 77-84. [PMID: 23361150]; [PMCID: PMC3609952]
 18. Thomas R and Köcher M. Percutaneous Treatment Of Benign Biliary Strictures And Biliary Manometric Perfusion Test. *Biomedical Papers of the Medical Faculty of Palacky University in Olomouc*. 2007; **151**: 85-90.
 19. Janssen J, Delden O, Lienden K, Rauws E, Busch O, Van Gulik T, Gouma D and Lameris J. Percutaneous Balloon Dilatation and Long-Term Drainage as Treatment of Anastomotic and Non anastomotic Benign Biliary Strictures. *Cardiovasc Intervent Radiol*. 2014; **37**: 1559-1567.
 20. House M, Cameron J, Schulick R, Campbell K, Sauter P, Coleman J, Lillemoë K, Yeo C. Incidence and Outcome of Biliary Strictures After Pancreaticoduodenectomy. *Annals of surgery*. 2006; **243**: 571-576. [PMID: 16632990]; [PMCID: PMC1570556]
 21. Zepeda-Gómez S and Baron T. Benign Biliary Strictures: Current Endoscopic Management. *Nature Reviews Gastroenterology and Hepatology*. 2011; **8**: 573-581. [PMID: 21894200]
 22. Prakash K, Ramesh H, Jacob G, Venugopal A, Lekha V, Varma D, Ramesh G and Augustine P. Multidisciplinary approach in the long-term management of intrahepatic stones: Indian experience. *Indian Journal of Gastroenterology*. 2004; **23**: 209-213. [PMID: 15627659]