

Persistent Elevation of Liver Enzymes during Pegylated Interferon Therapy of Chronic Hepatitis C Virus: Role of Occult Hepatitis B

Mohamed H Emara, Ehab M Darweish, Ahmed S Bihery, Salem Y Mohamed, Heba F Pasha

Mohamed H Emara, Ehab M Darweish, Ahmed S Bihery, Tropical Medicine Department, Faculty of Medicine, Zagazig University, Zagazig, 44519, Egypt

Salem Y Mohamed, Internal Medicine Department, Faculty of Medicine, Zagazig University, Zagazig, 44519, Egypt

Heba F Pasha, Medical Biochemistry Department, Faculty of Medicine, Zagazig University, Zagazig, 44519, Egypt

Correspondence to: Mohamed H Emara, Tropical Medicine Department, Faculty of Medicine, Zagazig University, Zagazig, 44519, Egypt. emara_20007@yahoo.com

Telephone: +0201002724482

Received: September 22, 2012 Revised: November 4, 2012

Accepted: November 8, 2012

Published online: December 21, 2012

ABSTRACT

AIM: Lack of liver enzymes normalization may discourage patients with chronic HCV from continuing therapy and may worry the clinician about treatment outcomes, raising the suspicion about the presence of concomitant causes of liver damage. The decision of discontinuing treatment solely on the basis of elevated liver enzymes in patients who are HCV-RNA-negative would result in a substantial proportion of patients not being cured of infection. We conducted this study to test the assumption that persistent liver enzymes elevation in patients with chronic HCV under pegylated interferon therapy who have achieved HCV clearance may be due to an underlying occult hepatitis B virus infection.

METHODS: Seventy six chronic HCV patients under treatment with pegylated-interferon/ribavirin therapy were included. Group I ($n=38$); patients with persistent liver enzymes elevation despite therapy, while group II ($n=38$); patients with persistently non elevated liver enzymes. All patients were not viremic for HCV at the time of examination to hepatitis B virus. All patients were investigated for occult hepatitis B virus infection.

RESULTS: HBV DNA was detected in 3 patients (3.9%), anti-HBc and anti-HBs were detected each in 14 patients (18.4%). None of the HBV markers showed statistical significance in relation to persistently elevated liver enzymes.

CONCLUSIONS: Occult hepatitis B virus infection is not a cause of persistent elevation of liver enzymes during pegylated-interferon therapy of chronic HCV.

© 2012 Thomson research. All rights reserved.

Key words: Occult hepatitis B; Chronic HCV; Liver enzymes; Pegylated-interferon

Emara MH, Darweish EM, Bihery AS, Mohamed SY, Pasha HF. Persistent Elevation of Liver Enzymes during Pegylated Interferon Therapy of Chronic Hepatitis C Virus: Role of Occult Hepatitis B. *Journal of Gastroenterology and Hepatology Research* 2012; 1(11): 327-331 Available from: URL: <http://www.ghrnet.org/index./joghr/>

INTRODUCTION

Hepatitis B virus (HBV) and hepatitis C virus (HCV) infections account for a substantial proportion of liver diseases worldwide. Since both viruses share many modes of transmission, their combined infection is hence common in areas where the two viruses are endemic and among subjects with a high risk of parenteral infections^[1,2].

HCV is the single most important cause of liver disease in Egypt^[3,4], with the latest anti-HCV antibody prevalence of 14.7%^[5]. It is a progressive disease that can lead to cirrhosis, liver failure, hepatocellular carcinoma (HCC), and death^[6]. Hence, it is very important that the disease be treated in its early stages, which will effectively reduce the morbidity and mortality associated with this disease^[7]. The currently recommended therapy for chronic HCV is the combination of pegylated interferon alpha (Peg-IFN) and ribavirin (RBV) that proved superior to standard interferon alpha and ribavirin^[8,9].

Elevated aminotransferases are considered a sign of hepatocellular damage due to their high hepatic concentration, and alanine aminotransferase (ALT) is more specific for liver damage than aspartate aminotransferase (AST)^[10].

Lack of ALT and AST normalization may discourage patients from continuing therapy and may worry the clinician about treatment outcomes, raising the suspicion about the presence of concomitant causes of liver damage. The decision of discontinuing treatment solely on the basis of elevated aminotransferases in patients who are HCV-RNA-negative would result in a substantial proportion of patients not being cured of infection^[7].

Occult hepatitis B virus infection (OBI) is defined as the

presence of HBV DNA, in serum and/or the liver tissue without detectable HBsAg with or without anti-HBc or anti-HBs outside the pre-seroconversion window period^[11]. OBI may contribute to liver inflammation through episodes of increased viral replication, increased immune activity and subsequent liver injury^[12].

In this paper, the authors assume that patients with chronic HCV infection who have achieved HCV clearance and are concomitantly infected with OBI can experience persistent liver enzymes elevation during HCV therapy due to flare of HBV infection.

METHODS

This study was conducted in Al-Ahrar General Hospital (local treatment centre for Hepatitis C virus), Sharkia Governorate, Egypt in the period from April 2011 to March 2012 and included 76 chronic HCV patients under Peg-IFN/RBV therapy. The diagnosis of HCV was done by detection of anti-HCV antibody and confirmed by HCV RNA and they were all candidates to begin combination therapy according to the modified guidelines of the national Committee for Control and Prevention of viral Hepatitis "C" in Egypt, with the following criteria:

Inclusion criteria

- 1- Age \geq 18 years.
- 2- White blood cell (WBC) count $>$ 3500/mm³.
- 3- Neutrophil count $>$ 1 500/mm³.
- 4- Platelets $>$ 8 5000/mm³.
- 5- Prothrombin time $<$ 2 seconds above upper limit of normal (ULN).
- 6- Direct bilirubin 0.3 mg/dL or within 20% ULN.
- 7- Indirect bilirubin 0.8 mg/dL or within 20% ULN.
- 8- Fasting blood sugar 115 mg or within 20% ULN.
- 9- Albumin $>$ 3.5 gm/dL.
- 10- Serum creatinine within normal limit (WNL).
- 11- TSH WNL.
- 12- HBsAg is negative.
- 13- Anti-nuclear antibody (ANA) $<$ 1:160.
- 14- Positive anti-HCV and HCV RNA.
- 15- If diabetic, HB A1C $<$ 8.5%.
- 16- Alpha Feto-Protein (AFP) $<$ 100 IU/mL.
- 17- If AFP is abnormal ($>$ 100 IU/mL) triphasic C.T. is normal.
- 18- Female patient should practice adequate contraception.
- 19- Male patient's wife practicing adequate contraception.
- 20- Signed written informed consent for the study.

Exclusion criteria

Exclusion of,

- 1- Any other cause of liver disease other than HCV (by laboratory and liver biopsy).
- 2- Co-infection with HBV
- 3- Haemochromatosis.
- 4- Alpha -antitrypsin deficiency.
- 5- Wilson's disease.
- 6- Autoimmune disease (by ANA).
- 7- Alcoholic liver disease.
- 8- Decompensated liver disease.
- 9- Hypersensitivity to Peg-IFN or ribavirin.
- 10- Pregnancy or breast feeding.
- 11- Poorly controlled diabetes.
- 12- Clinically significant retinal abnormalities.
- 13- Obesity -induced liver disease.
- 14- Drug-induced liver disease.

- 15- CNS trauma that requires medication.
- 16- Active seizures which requires medication
- 17- Ischemic cardiovascular disease within the last 6 months.
- 18- Immunologically mediated disease (Ulcerative colitis, Crohn's disease, idiopathic thrombocytopenic purpura, systemic lupus, autoimmune haemolytic anemia, scleroderma, severe psoriasis, rheumatoid arthritis).
- 19- Patients with organ transplant.
- 20- Substance abuse (alcohol $>$ 80 gm/d, IV drugs and inhaled drugs).
- 21- If past history of substance abuse, abstention for the last 12 months.
- 22- Immunosuppressive drugs.
- 23- History of manic element associated to prior history.
- 24- Severe pre-existing psychiatric conditions.

Patients

In this cross sectional study patients attending to HCV treatment outpatient clinic at Al-Ahrar General Hospital were included. Patients who showed persistent liver enzymes elevation during treatment with Peg-IFN/RBV ($n=38$) were investigated for HBV DNA, anti-HBc and anti-HBs antibodies (group I), another comparable group of patients ($n=38$) exhibiting persistently non elevated liver enzymes were included as a control group (group II). All included patients were negative for HCV RNA at time of examination for HBV markers.

All the studied patients were subjected to the following:

- I. Detailed history taking.
- II. Thorough clinical examination.
- III. Routine investigations; liver function tests, kidney functions, complete blood counts. Liver enzymes measured as times of ULN from reference values.
- IV. Revision of the pre-enrollment laboratory investigations with special concern to liver functions, kidney functions, complete blood count, serum HCV RNA.
- V. Liver biopsy for histological staging and grading of chronic HCV: Hepatitis grading and staging were evaluated according to the METAVIR scoring system.
- VI. Body mass index (BMI) assessment.
- VII. Serodiagnosis of HBV: anti-HBc total antibodies were detected by a rapid immunoassay (Gold Colloidal Conjugate Membrane, Cal-Tech Diagnostics, INC.- California, USA) while anti-HBs antibodies were determined by the electro-chemi-luminescence immunoassay technique using commercially available kits (Cobas e 411 analyzer, Hitachi, Japan).
- VIII. HBV DNA examination.

The assay and results were performed and interpreted by investigators who were blinded to the patients' baseline characteristics, HBV serology, stage of liver biopsy and clinical outcome. HBV DNA examination was done by COBAS® AmpliPrep/COBAS® TaqMan® HBV Test (Roche Diagnostics, Switzerland), it is a real time quantitative PCR technology. The concentration of HBV DNA in EDTA-plasma that can be detected with a positivity rate of greater than 95%, is 12 IU/mL or lower while its specificity is 100%.

Treatment regimens and follow up

The dose of Peg-IFN alpha-2a is 180 ug subcutaneously around the umbilicus once per week together with RBV, using 1000 mg/d for those \leq 75 kg in weight and 1200 mg/d for those $>$ 75 kg in weight; the dose of Peg-IFN alpha-2b is 1.5 ug/kg body weight subcutaneously around the umbilicus once per week together with RBV at dose of

Table 1 Characteristics of the studied patients.

	Group I (N=38)		Group II (N=38)		<i>t</i>	<i>P</i>
	N	%	N	%		
Age (years)						
$\bar{X} \pm SD$	43.3±10.9		41.3±8.2		0.38	>0.5
Range	20-59		28-59			
Gender						
Male	28	73.7	28	73.7	1.0	>0.5
Female	10	26.7	10	26.7		
BMI						
$\bar{X} \pm SD$	27.3±3.7		27.2±2.9		0.89	>0.5
Range	22-35		22-33			
Smoking status						
Negative	23	60.3	22	57.9		
Active	7	18.4	12	31.6	0.26	>0.5
X-smoker	8	21.1	4	10.5		
ALT (ULN)						
$\bar{X} \pm SD$	3.1±1.69		1±0.0		7.76	<0.001*
Range	1.5-7					
AST (ULN)						
$\bar{X} \pm SD$	2.76±1.3		1±0.0		8.3	<0.001*
Range	1.5-6					
HCV RNA						
(IU/ml)×10 ⁵						0.039
$\bar{X} \pm SD$	6.7±7.4		3.6±5.2			
Range	0.017-22.3		0.009-22			
Median	2.08		1.64			

\bar{X} : mean, SD: standard deviation; BMI: body mass index; ULN: upper limit of normal; *: highly significant.

Table 2 HBV markers in both groups.

	Group I		Group II		<i>P</i>
	N	%	N	%	
Anti-HBs					
Negative	32	84.2	30	78.9	0.76
Positive	6	15.8	8	21.1	
Anti-HBc					
Negative	32	84.2	30	78.9	0.76
Positive	6	15.8	8	21.1	
HBV DNA					
Negative	36		37		1.0
Positive	2		1		

Table 3 HBV DNA in relation to anti-HBc and anti-HBs.

Anti-HBs	HBV DNA				Total	%
	Negative		Positive			
	Negative	Positive	Negative	Positive		
Negative	49(64.5%)	10(13.1%)	2(2.6%)	1(1.3%)	62	81.6
Positive	10(13.1%)	4(5.3%)	0(0%)	0(0%)	14	18.4
Total	59(77.6%)	14(18.4%)	2(2.6%)	1(1.3%)	76	100

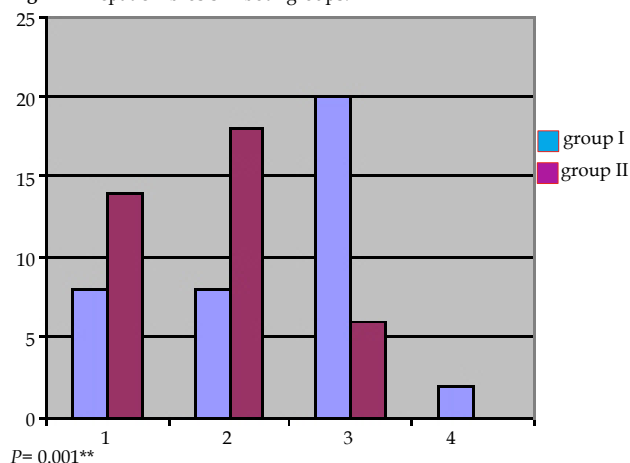
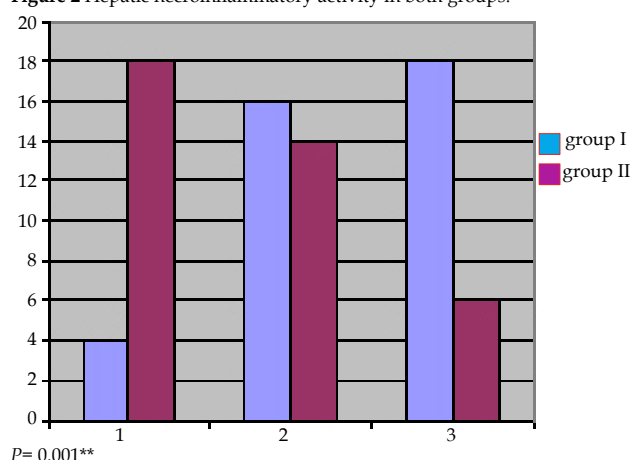
800 mg/d for those weighting <65 kg; 1000 mg for those >65 kg to 85 kg; 1200 mg for those >85 kg to 105 kg; and 1400 mg those >105 kg.

Patient Monitoring

Patients were assessed at weeks 0, 1, 2 and 4 of treatment and thereafter monthly. At each visit, laboratory tests were performed including serum ALT and AST, bilirubin, complete blood count, and serum creatinine. Body weight and symptom checklist were recorded at each visit and dose modifications to the Peg-IFN or RBV were made when appropriate. Qualitative HCV-RNA was determined at week 12, week 24. Quantitative serum HCV-RNA was determined at baseline and at week 12.

STATISTICAL ANALYSIS

Data were checked, entered and analyzed using SPSS (Statistical

Figure 1 Hepatic Fibrosis in both groups.**Figure 2** Hepatic necroinflammatory activity in both groups.

Package for the Social Sciences) version 15. Data were expressed as mean±SD for quantitative variable, number and percentage for qualitative one. Chi-squared (χ^2) or Fisher exact, *t* test and paired *t* test were used when appropriate. *P* < 0.05 was considered significant.

RESULTS

The base line characteristics of both groups are shown in table 1. All patients of this study were HBsAg negative. Patients in group I had both ALT and AST elevated throughout the study period with mean elevation of 3.1 and 2.76 times the ULN from the reference values respectively. None of the cases in persistent liver enzymes elevation group had levels >7 times the reference values.

Regarding the markers of HBV infection (Table 2); none showed statistical significance in relation to the persistent liver enzymes elevation. HBV DNA detected in 3 cases of the studied sample (3.9%), 2 with persistent enzymes elevation and one with non elevated enzymes. The three cases with confirmed HBV infection had a level of viremia >2 000 IU/mL (2 980, 2 112, 2 210 IU/ml respectively). HBV viremia can not be predicted by serological markers (Table 3), where only one patient in group II was anti-HBc positive.

While both anti-HBs and anti-HBc antibodies were detected in 14 cases (18.4%). Only 4 cases among all patients tested positive for both anti-HBs and anti-HBc and all were in group I, none of them was HBV DNA positive (Table 3).

In this study hepatic fibrosis (Figure 1) and histologic activity (Figure 2) seem to play role in persistent liver enzyme elevation

while on Peg-IFN/RBV therapy. Group I had advanced hepatic fibrosis (F3, F4) in comparison with group II ($p=0.001$), the same do occur for histologic activity, where patients in group I had advanced activity (A2, A3) than group II ($p=0.001$). The same is noticed with base line HCV RNA, where patients with group I had higher base line HCV viral load than group II ($p=0.039$).

DISCUSSION

Occult HBV infection has frequently been identified in patients with HCV-related chronic hepatitis. Considerable data suggested that occult infection may contribute to chronic liver damage, poor response to antiviral therapy, and the development of HCC^[13-15].

Liver enzymes flare due to OBI has been previously reported in persons with HCV infection in international^[16] and Egyptian^[17] studies. The ALT levels are usually mildly higher in OBI and HCV co-infection and seems to be either similar^[18,19], or mildly raised^[20,21], than in HCV mono-infection patients. Fujiwara *et al*^[22], found no correlation between HBV DNA and enzymes elevation, this agrees with our results. In the other hand several investigators^[16-19] demonstrated significant relation between flares in liver transaminases and OBI. These notions support the hypothesis that OBI replication is a cause of hepatocyte injury.

OBI occurs in 3.9% of the studied sample in this study and this is in agreement with previous rates reported from local Egyptian^[23] as well as international^[24] studies. In the subgroup analysis OBI occurs in 5.2%, in the group of persistent liver enzymes elevation and this is much lower than rates reported in Egypt by Selim *et al*^[17], who reported OBI in 63.3% of chronic HCV patients with ALT flares, this can be explained by the fact that OBI may be eradicated, if present, by the interferon therapy in our patients when compared to non treated patients in their study.

OBI is not a cause of persistent liver enzymes elevation in Egyptian chronic HCV patients under interferon therapy, where in this study 2 patients with detectable serum HBV DNA were detected in group I and one patient in group II. Also serological markers of HBV infection (anti-HBs, anti-HBc) were not associated with persistent liver enzymes elevation.

The observation that HBV DNA positivity cannot be predicted by serological markers is a finding of this study and agrees the previous findings in international^[25] as well as Egyptian studies^[23].

The finding of occult HBV infection among anti-HBc positive persons supports the notion that occult HBV infection is frequently a late phase of overt chronic HBV infection or serologically recovered acute HBV infection. Another possible hypothesis for this finding is that HCV infection may block the circulating viral expression of HBV but anti-HBc in the serum and HBV DNA in the hepatocytes may persist^[26]. The reason for existence of occult HBV infection in anti-HBc negative patients is less clear. It is possible that some of these patients had transient acute HBV infection with clearance of HBsAg initially and decline of anti-HBc to undetectable levels over time. It is also possible that some patients are infected with HBV variants that do not express any HBV proteins^[27].

Hung *et al*^[28] observed that 13% of chronic HCV patients who obtained sustained virological response to standard interferon and RBV treatment showed persistently elevated ALT during treatment, whereas in the study by Zeuzem *et al*^[29] 41% of patients did not achieve ALT normalization until the end of therapy. These findings suggest that lack of ALT normalization is not necessarily associated with a decreased efficacy of treatment. This observation together with our findings should encourage chronic HCV patients under interferon therapy to continue therapy in spite of persistent liver enzymes elevation.

We knew that a point of weakness in this work is that HBV markers were measured only once, and a reciprocal viral dominance may alter the results, but this is compensated by the notice that all cases achieved some sort of HCV clearance (all were HCV RNA negative) at the time of examination to HBV DNA.

Persistent liver enzymes elevation in chronic HCV patients despite pegylated interferon therapy in this study seem to be related to hepatic pathology. In particular, advanced fibrosis (F3, F4) and activity (A3) seemed to play a role, where patients in group I had advanced hepatic fibrosis and histologic activity than group II. The same is applied to base line viral load, where persistent elevation of liver enzymes is more likely associated with higher baseline HCV viemia.

In conclusion OBI is not a cause of persistent liver enzymes elevation during Peg-IFN/RBV therapy of chronic HCV.

REFERENCES

- Zarski JP, Bohn B, Bastie A, Pawlowsky JM, Baud M, Bost-Bezeaux F, Tran van Nhieu J, Seigneurin JM, Buffet C, Dhumeaux D. Characteristics of patients with dual infection by hepatitis B and C viruses. *J Hepatol* 1998; **28**: 27-33
- Saravanan S, Velu V, Nandakumar S, Madhavan V, Shanmugasundaram U, Murugavel KG, Balakrishnan P, Kumarasamy N, Solomon S, Thyagarajan SP. Hepatitis B virus and hepatitis C virus dual infection among patients with chronic liver disease. *J Microbiol Immunol Infect* 2009; **42**: 122-128
- el-Zayadi AR, Selim O, Ibrahim EH, Hamdy H, Dabbous H, Ahdy A, Moneim SA. Does schistosomiasis play a role in the high sero prevalence of HCV antibody among Egyptians? *Trop Gastroenterol* 1997; **18**: 98-100
- Habib M, Mohamed MK, Abdel-Aziz F, Magder LS, Abdel-Hamid M, Gamil F, Madkour S, Mikhail NN, Anwar W, Strickland GT, Fix AD, Sallam I. Hepatitis C virus infection in a community in the Nile Delta: risk factors for seropositivity. *Hepatology* 2001; **33**: 248-253
- El-Zanaty F, Way A. Egypt Demographic and Health Survey 2008. Egyptian: Ministry of Health (El-Zanaty and Associates and Macro International, Cairo). 2009: 431.
- National Institutes of Health Consensus Development Conference Statement: Management of hepatitis C 2002 (June 10-12, 2002). *Gastroenterology* 2002; **123**: 2082-2099
- Basso M, Giannini EG, Torre F, Bianchi S, Savarino V, Picciotto A. Elevations in alanine aminotransferase levels late in the course of antiviral therapy in hepatitis C virus RNA-negative patients are associated with virological relapse. *Hepatology* 2009; **49**: 1442-1448
- Hadziyannis SJ, Sette H, Morgan TR, Balan V, Diago M, Marcellin P, Ramadori G, Bodenheimer H, Bernstein D, Rizzetto M, Zeuzem S, Pockros PJ, Lin A, Ackrill AM. Peginterferon-alpha2a and ribavirin combination therapy in chronic hepatitis C: a randomized study of treatment duration and ribavirin dose. *Ann Intern Med* 2004; **140**: 346-355
- Ghany MG, Strader DB, Thomas DL, Seeff LB. Diagnosis, management, and treatment of hepatitis C: an update. *Hepatology* 2009; **49**: 1335-1374
- Giannini EG, Testa R, Savarino V. Liver enzyme alteration: a guide for clinicians. *CMAJ* 2005; **172**: 367-379
- Br  chet C, Thiers V, Kremsdorf D, Nalpas B, Pol S, Paterlini-Br  chet P. Persistent hepatitis B virus infection in subjects without hepatitis B surface antigen: clinically significant or purely "occult"? *Hepatology* 2001; **34**: 194-203
- Kannangai R, Vivekanandan P, Netski D, Mehta S, Kirk GD, Thomas DL, Torbenson M. Liver enzyme flares and occult hepatitis B in persons with chronic hepatitis C infection. *J Clin Virol* 2007; **39**: 101-105
- Carre  o V, Bartolom   J, Castillo I, Quiroga JA. Occult hepa-

- titis B virus and hepatitis C virus infections. *Rev Med Virol* 2008; **18**: 139-157
- 14 Mrani S, Chemin I, Menouar K, Guillaud O, Pradat P, Borghi G, Trabaud MA, Chevallier P, Chevallier M, Zoulim F, Trépo C. Occult HBV infection may represent a major risk factor of non-response to antiviral therapy of chronic hepatitis C. *J Med Virol* 2007; **79**: 1075-1081
 - 15 Miura Y, Shibuya A, Adachi S, Takeuchi A, Tsuchihashi T, Nakazawa T, Saigenji K. Occult hepatitis B virus infection as a risk factor for hepatocellular carcinoma in patients with chronic hepatitis C in whom viral eradication fails. *Hepatology* 2008; **38**: 546-556
 - 16 Shavakhi A, Norinayer B, Esteghamat FS, Seghatoleslami M, Khodadustan M, Somi MH, Masoodi M, Zali MR. Occult hepatitis B among Iranian hepatitis C patients. *J Res Med Sci* 2009; **14**: 13-17
 - 17 Selim HS, Abou-Donia HA, Taha HA, El Azab GI, Bakry AF. Role of occult hepatitis B virus in chronic hepatitis C patients with flare of liver enzymes. *Eur J Intern Med* 2011; **22**: 187-190
 - 18 Nirei K, Kaneko M, Moriyama M, Arakawa Y. The clinical features of chronic hepatitis C are not affected by the co-existence of hepatitis B virus DNA in patients negative for hepatitis B surface antigen. *Intervirology* 2000; **43**: 95-101
 - 19 Kazemi-Shirazi L, Petermann D, Müller C. Hepatitis B virus DNA in sera and liver tissue of HBsAg negative patients with chronic hepatitis C. *J Hepatology* 2000; **33**: 785-790
 - 20 Fukuda R, Ishimura N, Niigaki M, Hamamoto S, Satoh S, Tanaka S, Kushiyama Y, Uchida Y, Iihara S, Akagi S, Watanabe M, Kinoshita Y. Serologically silent hepatitis B virus coinfection in patients with hepatitis C virus-associated chronic liver disease: clinical and virological significance. *J Med Virol* 1999; **58**: 201-207
 - 21 Stránský J, Malina L, Cieslarová B, Stráteský J, Půtová I, Horák J. Overt and hidden coinfection with hepatitis B and C viruses in chronic liver disease and porphyria cutanea tarda. *Acta Virol* 2000; **44**: 23-28
 - 22 Fujiwara K, Tanaka Y, Orito E, Ohno T, Kato T, Sugauchi F, Suzuki S, Hattori Y, Sakurai M, Hasegawa I, Ozasa T, Kanie F, Kano H, Ueda R, Mizokami M. Lack of association between occult hepatitis B virus DNA viral load and aminotransferase levels in patients with hepatitis C virus-related chronic liver disease. *J Gastroenterol Hepatol* 2004; **19**: 1343-1347
 - 23 Emara MH, El-Gammal NE, Mohamed LA, Bahgat MM. Occult hepatitis B infection in Egyptian chronic hepatitis C patients: prevalence, impact on pegylated interferon/ribavirin therapy. *Virol J* 2010; **7**: 324
 - 24 Levast M, Larrat S, Thelu MA, Nicod S, Plages A, Cheveau A, Zarski JP, Seigneurin JM, Morand P, Leroy V. Prevalence and impact of occult hepatitis B infection in chronic hepatitis C patients treated with pegylated interferon and ribavirin. *J Med Virol* 2010; **82**: 747-754
 - 25 Ferraro D, Bonura C, Giglio M, Di Stefano R, Almasio PL, Di Marco V, Craxì A, Cacciola I, Squadrito G, Raimondo G. Occult HBV infection and suppression of HCV replication in the early phase of combination therapy for chronic hepatitis C. *J Biol Regul Homeost Agents* 2003; **17**: 172-175
 - 26 Zöllner B, Feucht HH, Sterneck M, Schäfer H, Rogiers X, Fischer L. Clinical reactivation after liver transplantation with an unusual minor strain of hepatitis B virus in an occult carrier. *Liver Transpl* 2006; **12**: 1283-1289
 - 27 Marrero JA, Lok AS. Occult hepatitis B virus infection in patients with hepatocellular carcinoma: Innocent bystander, cofactor, or culprit? *Gastroenterology* 2004; **126**: 347-350
 - 28 Hung CH, Lee CM, Lu SN, Wang JH, Tung HD, Chen TM, Chen CH, Changchien CS. Is delayed normalization of alanine aminotransferase a poor prognostic predictor in chronic hepatitis C patients treated with a combined interferon and ribavirin therapy? *J Gastroenterol Hepatol* 2002; **17**: 1307-1311
 - 29 Zeuzem S, Feinman SV, Rasenack J, Heathcote EJ, Lai MY, Gane E, O'Grady J, Reichen J, Diago M, Lin A, Hoffman J, Brunda MJ. Peginterferon alfa-2a in patients with chronic hepatitis C. *N Engl J Med* 2000; **343**: 1666-1672
- Peer reviewer:** György M. Buzás, Ferencváros Health Centre, Gastroenterology, Mester utca 45, 1095 Budapest, Hungary.