

Efficacy of Aloe Vera as A Pulpotomy Agent in Children Primary Teeth: Clinical and Radiographic Studies

Sara Gonna¹, PhD; Nagwa Ghoname², PhD; Amal Kabbash³, PhD; Akira Yagi⁴, PhD

1 Lecturer of Pediatric Dentistry, Tanta University, Japan;
2 Professor of Pediatric Dentistry, Tanta University, Japan;
3 Professor of Pharmacognosy Department, Faculty of Pharmacy, Tanta University, Japan;
4 Editor in-Chief of Journal of Gastroenterology and Hepatology Research; Emeritus Professor, Fukuyama University, Hiroshima, Japan.

Conflict-of-interest statement: The authors declare that there is no conflict of interest regarding the publication of this paper.

Open-Access: This article is an open-access article which was selected by an in-house editor and fully peer-reviewed by external reviewers. It is distributed in accordance with the Creative Commons Attribution Non Commercial (CC BY-NC 4.0) license, which permits others to distribute, remix, adapt, build upon this work non-commercially, and license their derivative works on different terms, provided the original work is properly cited and the use is non-commercial. See: <http://creativecommons.org/licenses/by-nc/4.0/>

Correspondence to: Akira Yagi, PhD, Professor Emeritus, Fukuyama University, Hiroshima, Japan.
Email: 0131akirayagi@gmail.com
Telephone: +81-92-938-2717
Telephone: +81-92-938-2717

Received: May 31, 2019
Revised: July 12, 2019
Accepted: July 15, 2019
Published online: October 21, 2019

ABSTRACT

AIM: The present study was conducted to compare effects of acemannan and formocresol as pulp-dressing agents clinically and radiographically in primary teeth.

MATERIALS AND METHODS: *Aloe vera* gel high molecular weight fractions (AHM) containing native ingredients of polysaccharide (acemannan) and glycoprotein (verectin) were obtained by using the patented hyper dry system after washing out coloured materials with running water from *Aloe vera* gel slurry. Thirty healthy children aged from four to eight years, they

were selected from patients attending outpatient clinic of Pediatric Dentistry department. Each child had at least bilateral deep carious lower primary molar indicated for pulpotomy. Pulpotomy was done in both groups; where group I treated by AHM, acemannan, as a dressing agent while formocresol used as a dressing agent in group II. The study cases were recalled after three, six, nine and twelve months for clinical and radiographic evaluation.

RESULTS: The overall clinical success rate of acemannan group was 96.5%, while formocresol group was 89.6%. The two groups were clinically successful with no statistically significant difference between them ($p = 0.148$). The radiographic success rate of acemannan group was 93.1%, while for formocresol group was 86.2%. There was no statistically significant difference between the two groups ($p = 0.385$).

CONCLUSION: The acemannan showed higher clinical and radiographic success rate compared to formocresol as a pulpotomy agent in molars. It can be considered as an acceptable biomaterial for vital pulp therapy of deep caries in primary teeth.

Key words: Acemannan; Formocresol; Primary teeth; Pulpotomy

© 2019 The Author(s). Published by ACT Publishing Group Ltd. All rights reserved.

Gonna S, Ghoname N, Kabbash A, Yagi A. Efficacy of Aloe Vera as A Pulpotomy Agent in Children Primary Teeth: Clinical and Radiographic Studies. *Journal of Gastroenterology and Hepatology Research* 2019; 8(5): 2946-2951 Available from: URL: <http://www.ghrnet.org/index.php/joghr/article/view/2700>

INTRODUCTION

Maintenance of the primary dentition in a non-pathologic and healthy condition is important for the well-being of the child as well as for proper mastication, esthetics, phonetics, space maintenance and prevention of aberrant habits^[1].

Pulpotomy is one of the most widely accepted clinical procedures for treating cariously exposed pulp in primary teeth. The rationale of this technique is based on the healing ability of the radicular pulp tissue following surgical amputation of the affected or infected coronal pulp^[2].

Pulpotomy can be performed using different techniques including;

non-pharmacotherapeutic treatments or using pharmacotherapeutic approaches by dressing the pulp tissue with different medicaments or biological materials^[3]. Formocresol (FC) has been the most widely used medicament universally taught and preferred for pulpotomized primary teeth; due to its ease in use, bacteriostatic and fixative properties and high clinical success rates up to 97%^[4].

In spite of the high success rate of FC pulpotomy, there are some concerns about its potential health hazards^[5], search for a medicament to replace formocresol became imperative after several negative reports questioning both its local and systemic toxic effect as well as its immunologic, biochemical, mutagenic effects and teratogenic changes in the host^[6].

The use of biocompatible materials has become a major interest in modern dentistry, especially when direct contact with the dental tissues is necessary. In this sense, the field of phytotherapy, which is the use of plants or plant extracts for medicinal purposes, has experienced a remarkable advance in recent years. Subsequently this has stimulated the investigation of different herbal products with potential therapeutic properties for dental applications^[7].

Aloe vera is one of herbal natural material; it has anti-inflammatory, antibacterial, antifungal, antiviral, moisturizing and pain relieving properties^[8]. Acemannan is a major polysaccharide of *Aloe vera* gel, it has been recognized for its cytocompatibility and wound healing inducer. It promote new dentine formation by stimulating primary human dental pulp cell proliferation, differentiation, extracellular matrix formation and mineralization^[9].

MATERIALS AND METHODS

This study was conducted as a clinical trial, it was carried out at Pediatric Dentistry Department, Faculty of Dentistry, Tanta University. This study was carried out on thirty healthy children aged from four to eight years, they were selected from patients attending outpatient clinic of Pediatric department. Each child had at least bilateral deep carious lower primary molars (D&E) indicated for pulpotomy Figure 1.

Approval for this research was obtained from Faculty of Dentistry, Tanta University Research Ethics Committee. The purpose of the present study was explained to the patients and informed consents were obtained according to the guidelines on human research adopted by the Research Ethics Committee Faculty of Dentistry, Tanta University.

Inclusion criteria

A-Clinical criteria^[10]: (1) No evidence of clinical signs and symptoms of pulp degeneration such as; spontaneous throbbing pain, pain on percussion, tooth mobility, soft tissue swelling, fistula or sinus tract. (2) Absence of pulp hyperemia that require additional procedure. (3) Healthy children free from any medical condition such as heart or leukemia that contraindicate pulp therapy. (4) Restorable teeth. (5) Patient and parent cooperation.

B-Radiographic criteria^[10]: (1) No pathological external or internal root resorption. (2) Absence of calcific pulp degeneration. (3) Absence of furcation radiolucency.

Preparation of acemannan sponge

Aloe vera polysaccharide fraction: Fresh *Aloe vera* gel (100g) was homogenized and centrifuges at 9×10^3 g for 10 min. The supernatant was dialyzed with molecular weight 8000 cut-off membrane against distilled water for 36 hours and the non-dialysate (1g) was obtained as polysaccharides fraction after lyophilization, 0.4% acemannan

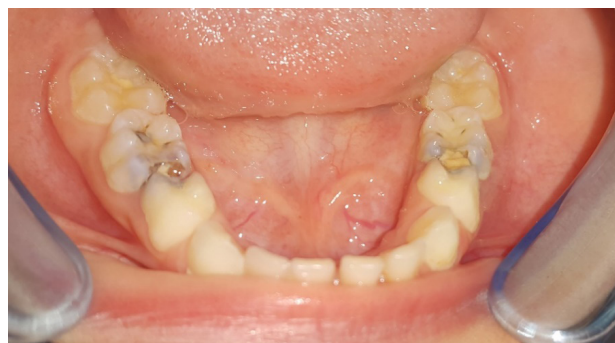

Figure 1 A photograph showing bilateral carious mandibular first primary molars.




Figure 2 Acemannan sponges.

solutions (w/v) were frozen at -80°C degree for 16 h and lyophilized overnight. Then the sponges are sterilized by gamma irradiation and tested for endotoxin contamination. The endotoxin level of the acemannan sponges are assessed using the Traditional Kinetic Limulus Amebocyte Lysate (LAL) assay kit (Lonza, Inc., Allendale, NJ, USA) following the manufacturer's instructions. The endotoxin level is measured using ELISA after mixing the sample with LAL reagent and comparing it to a standard curve. Endotoxin levels are 4.30 EU/mg sponge^[9]. Acemannan sponge, provided by Prof. Yagi A., Emeritus, Fukuyama University, Hiroshima, Japan (Figure 2).

Technique

Pre-operative periapical radiographs were obtained to assess the tooth condition and to ensure proper case selection. Size (0 or 1) radiographic films were used to accommodate the pediatric mouth using Extension Cone Parallel technique (XCP). The sixty selected primary molars out of thirty children were randomly divided into two groups of thirty teeth for each, according to the material used, Group I (Study group): Treated with acemannan and Group II (control group): Treated with formocresol.

Pulpotomy procedure

The procedure started with profound local anesthesia and rubber dam isolation, then caries was removed and conventional pulpotomy technique was performed. The roof of the pulp chamber was removed using a sterile high-speed bur No.330 with water spray, and the coronal tissue was then amputated by sharp sterile spoon excavator followed by irrigation with normal saline. Initial pulpal homeostasis was obtained using moistened cotton pellet gently pressed against the amputated pulp stump. In group I acemannan sponge was mixed with distilled water to form a viscous solution, then a cotton pellet

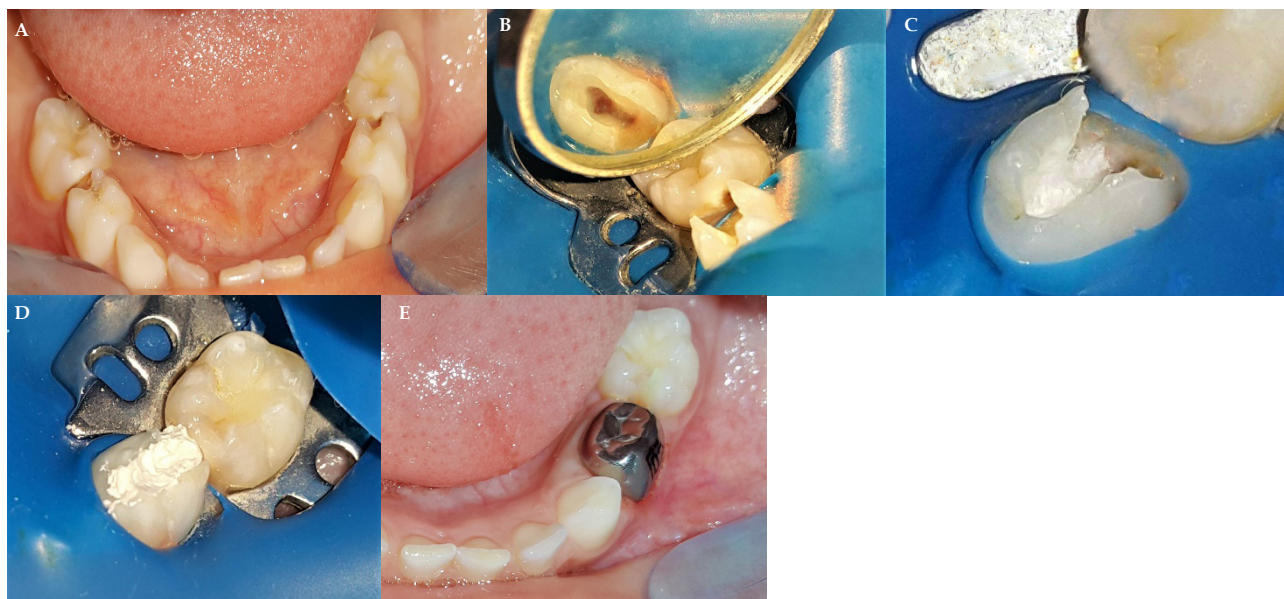


Figure 3 Clinical procedure using acemannan sponge.(A) Photograph shows the preoperative bilateral carious mandibular first molar. (B) Access opening of mandibular right second molar after removal of pulp tissue. (C) Applying moistened cotton with acemannan in the pulp chamber. (D) Stainless-steel crown in place at the same visit. (E) Application of reinforced zinc oxide eugenol.

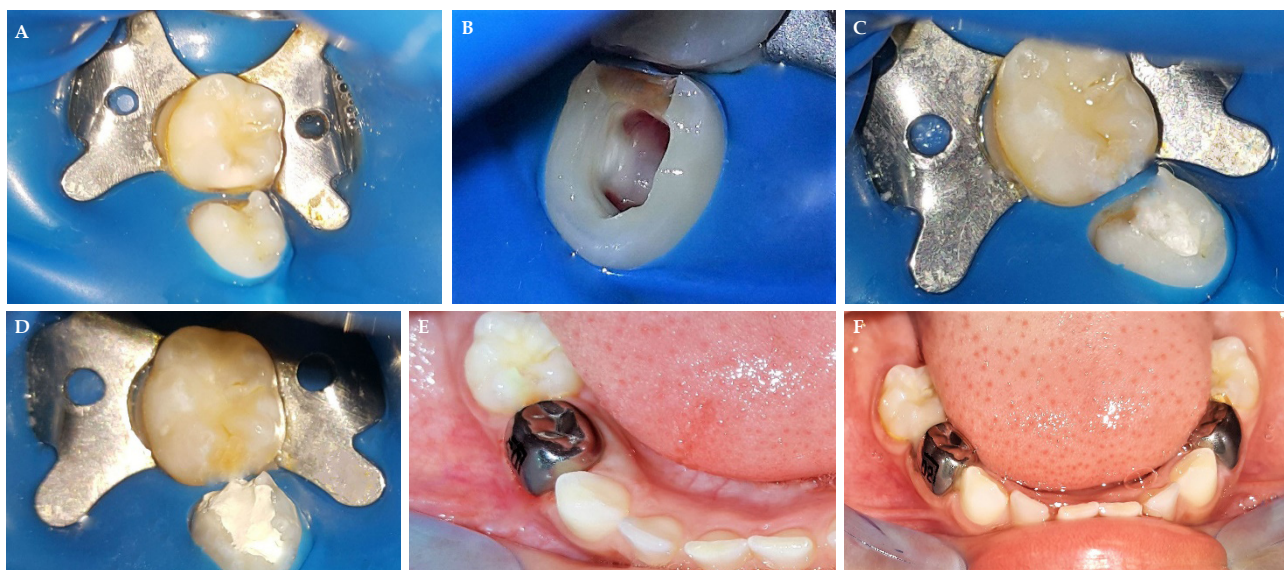


Figure 4 Clinical procedure using FC. (A) Preoperative photograph shows carious mandibular left second molar. (B) Access opening of mandibular second molar after removal of pulp tissue. (C) Application of cotton pellet moistened with Buckley's formocresol. (D) Application of reinforced zinc oxide eugenol. (E)Stainless-steel crowns in place at the same visit. (F) Stainless-steel crowns in both side.

moistened with it was applied on the pulp stump for 3 minutes, then the cotton will be removed, the cavity was sealed with reinforced zinc oxide eugenol. At the same visit, the tooth was restored with stainless-steel crown cemented with glass ionomer cement as a final restoration (Figure 3). In Group II, a small sterile cotton pellet moistened with Buckley's formocresol was placed over the pulp stumps for 5 minutes, then the pellet was removed and the cavity was sealed with reinforced zinc oxide eugenol. At the same visit, the tooth was restored with stainless-steel crown cemented with glass ionomer cement as a final restoration (Figure 4).

RESULTS

At the end of the study at twelve-month follow-up one patient was lost leaving 29 patients for evaluation, the overall clinical success rate of acemannan group was 96.5%, while FC group was 89.6%. The

two groups were clinically successful with no statistically significant difference between them. ($p = 0.148$) (Table 1).

In acemannan group, during the follow up periods all cases showed no sign of pain, gingival swelling or mobility, except at twelve month one case came with pain and gingival swelling. While, for formocresol group, one case represented with pain and gingival swelling at 3 month and another two cases at twelve month. There was no statistically significant difference between the two groups at different follow up periods as shown in Table 2. All the failed cases were managed by pulpectomy or extraction and space maintainer.

The overall radiographic success rate of acemannan group was 93.1%, while for formocresol group was 86.2%. There was no statistically significant difference between the two groups ($p = 0.385$) (Table 3 and Figures 5 and 6).

Throughout the follow-up periods, treated teeth in acemannan

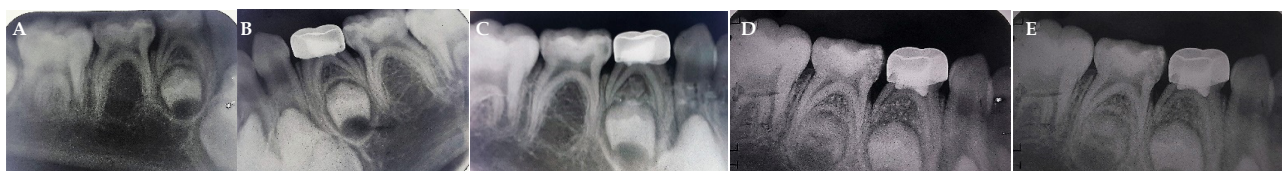

Figure 5 Overall radiographic success rate in the acemannan group. Periapical radiograph of mandibular first primary molar treated with acemannan: (a) Preoperative. (B) 3months postoperative. (C) 6 months postoperative. (D) 9 months postoperative. (E) 12 months postoperative.

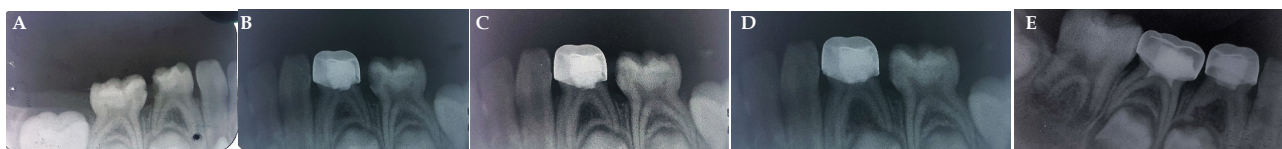

Figure 6 Overall radiographic success rate in the formocresol group. Periapical radiograph of mandibular first primary molar treated with formocresol: (A) Preoperative. (B) 3months postoperative. (C) 6 months postoperative. (d) 9 months postoperative. (E) 12 months postoperative.

group revealed no evidence of radiographic changes at three and six month follow-up. While, one tooth (3.3%) after nine months and another one (3.4%) after twelve months showed furcation radiolucency. In formocresol group, treated teeth showed no evidence of radiographic changes at three and six month follow-up. While, one tooth (3.3%) showed furcation radiolucency and another one (3.3%) showed abnormal root resorption and periodontal ligament space defect at nine month. At twelve month, one tooth (3.4%) showed also furcation radiolucency, and another one (3.4%) showed abnormal root resorption and widening of periodontal ligament space. There was no statically significant difference between the two groups at different follow up period as shown in Table 4.

DISCUSSION

An ideal pulpotomy material or drug must preserve healthy radicular pulp tissue, be highly biocompatible, prevent bacterial micro leakage, has the ability to promote healing, prevent bacterial microleakage and should not interfere with the physiological root resorption process.

Advances in biomedical research open avenues for design of new materials for pulpotomy treatment, aiming at regeneration of dentin-pulp complex. So, this study was conducted to assess the efficacy of acemannan as a pulpotomy agent compared to formocresol in primary teeth.

The age group selected for this study was from four to eight years to preserve the primary molars till the time of exfoliation, as premature loss of primary molars is one of the factors that are responsible for space loss and malocclusion. Also, the selected cases had bilateral deep carious primary molars, to perform the treatment of both groups under the same environmental factors for accurate comparable results.

In the current study, formocresol was used for comparison because it is still considered the gold standard when compared with all pulpotomy agents and medicaments due to its bacteriostatic, fixative properties and high clinical success rates.

It seems very important to identify novel and effective pulpotomy agents to increase the rate of success of pulpotomy procedures. Therefore, several investigations have been used to evaluate the clinical and radiographical success of the variable pulpotomy agents in primary teeth, such as the presence of pain or swelling as well as the indication of periapical or bifurcation change seen in radiograph^[11,12].

So, in this study, clinical as well as radiographic and

Table 1 Overall clinical success rates of the tested materials after twelve months follow up.

Groups	After 12 month (N =29)			
	Success N (%)	Failure N (%)	χ^2	FE p
AC	28 (96.5)	1 (3.4)	3.819	0.148
FC	26 (89.6)	3 (10.3)		

N: Total number of cases; χ^2 : Chi square test; FE: Fisher Exact for chi square test; AC: Acemannan; FC: Formocresol.

Table 2 Comparison of failure cases in the tested groups at different follow-up period.

Failure criteria	3 months		6 months		9 months		12 month	
	AC	FC	AC	FC	AC	FC	AC	FC
Pain	-	1	-	-	-	-	1	2
Gingival Swelling	-	1s	-	-	-	-	1s	2s
Mobility	-	-	-	-	-	-	-	-
Total	0	1	0	0	0	0	1	2
χ^2	1.403		1.403		0		0.357	
P value	0.236		0.236		1		0.55	

AC: Acemannan; FC: Formocresol; S: Same patient presented with different symptoms; χ^2 : Chi square test; FE: Fisher Exact for chi square test.

Table 3 Overall radiographic success and failure in the study groups.

Groups	After 12 months (N =29)			
	Success [N (%)]	Failure [N (%)]	χ^2	FE p
AC	27(93.1)	2(6.8)	0.754	0.385
FC	25 (86.2)	4(13.7)		

N: Total number of cases; χ^2 : Chi square test; FE: Fisher Exact for chi square test.

Table 4 Comparison of radiographic failure rates for the tested groups at different follow up period.

Failure criteria	Follow-up periods							
	3 months		6 months		9 months		12 month	
	AC	FC	AC	FC	AC	FC	AC	FC
Furcation radiolucency	-	-	-	-	1	1	1	1
Periapical radiolucency	-	-	-	-	-	-	-	-
Abnormal root resorption	-	-	-	-	-	1	-	1
Periodontal ligament defects	-	-	-	-	-	1s	-	1s
Total	-	-	-	-	1	2	1	2
χ^2	0		0		0.357		0.357	
P	1		1		0.55		0.55	

P: p value; χ^2 : Chi square test; FE: Fisher Exact for chi square test; s: same patient with different

histopathological examination were used during follow up, since the clinical and radiographic study of applied novel material are not sufficient. For overall evaluation, histopathological examination has long been suggested as the best method to evaluate the effectiveness of a biomaterial at the cellular and pulp tissue levels which may be difficult to feasible in the human especially in pediatric age group^[13,14].

In the present study, the overall clinical success rate of acemannan after one year was 96.5%. Most of the cases were clinically free from pain sensation, mobility and gingival abscess formation. These results may be contributed to anti-inflammatory, anti-bacterial, immunoregulatory function, healing and regenerative properties of *Aloe vera*^[15,16].

This result coincides with Songsiripraduboon *et al*^[17], they reported 100% success rate of acemannan as a direct pulp capping material. In addition Khairwa *et al*^[8], found that a mixture of zinc oxide powder and *Aloe vera* gel in primary teeth has showed 93% clinical success rate when used as a root canal filling material in primary teeth.

In the present study, radiographic success rate of acemannan was 93.1%, this results in accordance with Songsiripraduboon *et al*^[17], they reported 85% radiographic success rates when acemannan was used as a direct pulp capping material in human primary teeth. While, Khairwa *et al*^[8], reported 73% radiographic success rates when *Aloe vera* was mixed with zinc oxid powder as a root canal filling material in primary teeth.

Regarding FC evaluation in the present study, the clinical success rate was 89.6%. These findings agreed with the previous studies who reported (93.3%) by Eidelman *et al*^[18], 98.6% by Farsi *et al*^[19] and 100% by Noorollahian^[20]. While radiographic finding in FC group was 86.2%. These findings agreed with the results obtained by Farsi *et al*^[19], (86.8%); Huth *et al*^[21] (85%), and Mesut *et al*^[22] (90.4%).

The explanation for the difference in the overall clinical and radiographical success rates of both group in this study may be attributed to the fact that the clinical and radiographic success not always correspond. Fuks *et al*^[2] reported that chronic inflammation of the pulp may be present without periapical or interradicular abscess formation and the tooth may be clinically and radiographically normal.

Furcation radiolucency and abnormal root resorption were observed as common radiographic findings in formocresol group in the current study. These findings were in accordance with another different studies (Ibricevic and Al-Jame^[23]; Holan *et al*^[24]; Ruby *et al*^[25]; Havale *et al*^[26]; Yildirim *et al*^[27]): contributing the radiographic changes after FC pulpotomy to different factors, such as the possibility of penetration of formaldehyde through the pulpal floor with subsequent damage to the interradicular area. In the acemannan group, only one case presented with gingival swelling, this may be related to traumatic cutting during pulpotomy procedure or the presence of an extrapulpal blood clot that would cause chronic inflammation.

CONCLUSIONS

Within the context of observed results, it is possible to conclude that acemannan sponge (AHM) showed high clinical and radiographic success rate compared to formocresol as a pulpotomy agent in molars. It can be considered as an acceptable biomaterial for vital pulp therapy of deep caries in primary teeth.

ACKNOWLEDGMENTS

The authors express deep thanks to Mr.Yagi, S., CEO, Ellie

Corporation, Shizuoka, Japan for providing aloe vera high molecular weight fractions.

REFERENCES

1. Mortada A and King NM. A simplified technique for the restoration of severely mutilated primary anterior teeth. *J Clin Pediatr Dent*, 2004; **28**(3): 187-192. [PMID: 15163144]
2. Fuks AB, Guelmann M, Kupietzky A. Pulp therapy for the primary dentition. In: al C, editor. Pediatric dentistry infancy through adolescence. St Louis, Missouri: Elsevier Saunders, 2013; **3**(1): 333-51.
3. Parisay I, Ghoddusi J, and Forghani M. A review on vital pulp therapy in primary teeth. *Iranian endodontic journal*. 2015; **10**(1): 6-15. [PMID: 25598803]; [PMCID: PMC4293574].
4. Zurn D and Seale SN. Light-cured calcium hydroxide vs formocresol in human primary molar pulpotomies: a randomized controlled trial. *Pediatric dentistry*, 2008; **30**(1): 34-41. [PMID: 18402097]
5. Casas MJ, Layug M, Kenny D, Johnston DH and Judd P. Outcomes of primary molar ferric sulfate pulpotomy and root canal therapy. *Pediatr Dent*. 2004; **26**(1): 44-48. [PMID: 15080357]
6. Hunter M and Hunter B. Vital pulpotomy in the primary dentition: attitudes and practices of Specialists in Paediatric Dentistry practising in the United Kingdom. *International Journal of Paediatric Dentistry*, 2003; **13**(4): 246-50. [PMID: 12834384]
7. Purohit RN, Bhatt M, Purohit K, Acharya J, Kumar R and Garg R. Clinical and Radiological Evaluation of Turmeric Powder as a Pulpotomy Medicament in Primary Teeth: An in vivo Study. *Int J Clin Pediatr Dent*, 2017; **10**(1): 37-40. [PMID: 28377653]; [PMCID: PMC5360801]; [DOI: 10.5005/jp-journals-10005-1404]
8. Khairwa A, Bhat M, Sharma R, Satish V, Maganur P and Goyal A K. Clinical and radiographic evaluation of zinc oxide with aloe vera as an obturating material in pulpectomy: an in vivo study. *J Indian Soc Pedod Prev Dent*, 2014; **32**(1): 33-8. [PMID: 24531599]; [DOI: 10.4103/0970-4388.127051]
9. Jittapiromsak N, Sahawat D, Banlunara W, Sangvanich P and Thunyakitpisal P. Acemannan, an extracted product from *Aloe vera*, stimulates dental pulp cell proliferation, differentiation, mineralization, and dentin formation. *Tissue Eng Part A*, 2010; **16**(6): 1997-2006. [PMID: 20088703]; [DOI: 10.1089/ten.TEA.2009.0593]
10. Mohammad SG, Raheel SA, and Baroudi K. Histological Evaluation of Allium sativum Oil as a New Medicament for Pulp Treatment of Permanent Teeth. *The journal of contemporary dental practice*, 2015; **16**(2): 85-90. [PMID: 25906796]
11. Fuks AB and Eidelman E. Pulp therapy in the primary dentition. *Curr Opin Dent*, 1991; **1**(5): 556-63. [PMID: 1807455].
12. Markovic, D, Zivojinovic V and Vucetic M. Evaluation of three pulpotomy medicaments in primary teeth. *Eur J Paediatr Dent*, 2005; **6**(3): 133-8. [PMID: 16216093].
13. Kfir A and Basrani B. General Principles of radiology in endodontics. *Endodontic radiology*. 2nd ed. West Sussex: Wiley-Blackwell, 2012; **6**(3): 5-17.
14. Woehrlen AE. Evaluation of techniques and materials used in pulpal therapy based on a review of the literature: part I. *J Am Dent Assoc*, 1977; **95**: 1154-8. [DOI: <https://doi.org/10.14219/jada.archive.1977.0194>]
15. Reynolds T and Dweck AC. Aloe vera leaf gel: a review update. *J Ethnopharmacol*, 1999; **68**(1-3): 3-37. [PMID: 10624859]
16. Hamman J. Composition and applications of Aloe vera leaf gel. *Molecules*, 2008; **13**(8): 1599-616. [PMID: 18794775]; [PMCID: PMC6245421]
17. Songsiripraduboon SB, Sangvanich W, Trairatvorakul P, Thunyakitpisal C. Clinical, radiographic, and histologic analysis of the effects of acemannan used in direct pulp capping of human

- primary teeth: short-term outcomes. *Odontology*, 2016; **104(3)**: 329-37. [PMID: 26264630]; [DOI: 10.1007/s10266-015-0215-4]
18. Eidelman E, Holan G, Fuks AB. Mineral trioxide aggregate vs. formocresol in pulpotomized primary molars: a preliminary report. *Pediatr Dent*, 2001; **23(1)**: 15-8. [PMID: 11242724]
 19. Farsi N, Alamoudi NB, Khalid MA. Success of mineral trioxide aggregate in pulpotomized primary molars. *Journal of Clinical Pediatric Dentistry*, 2005; **29(4)**: 307-311. [PMID: 16161395].
 20. Noorollahian H. Comparison of mineral trioxide aggregate and formocresol as pulp medicaments for pulpotomies in primary molars. *British dental journal*, 2008; **204(11)**: 20-28. [PMID: 18425074]; [DOI: 10.1038/sj.bdj.2008.319]
 21. Huth KC, Paschos E, Hajek AN, Hollweck R, Crispin A, Hickel R, Folwaczny M. Effectiveness of 4 pulpotomy techniques--randomized controlled trial. *Dent Res*, 2005; **84(12)**: 1144-8. [PMID: 16304444]; [DOI: 10.1177/154405910508401210]
 22. Mesut EO, Haluk B and Emre B. Clinical, Radiographic, and Histopathologic Evaluation of Nd: YAG Laser Pulpotomy on Human Primary Teeth. *J Endod*, 2007; **33**: 415-21. [PMID: 17368330]; [DOI: 10.1016/j.joen.2006.12.013]
 23. Ibricevic H, Al-Jame Q. Ferric sulphate as pulpotomy agent in primary teeth: twenty month clinical follow up. *J Clin Pediatr Dent*, 2000; **24**: 269-272. [PMID: 11314410].
 24. Holan G, Eidelman E and Fuks AB. Long-term evaluation of pulpotomy in primary molars using mineral trioxide aggregate or formocresol. *Pediatric dentistry*, 2005; **27(2)**: 129-36. [PMID: 15926290].
 25. Ruby JD, Cox CF, Mitchell SC, Makhija S and Jackson J. A randomized study of sodium hypochlorite versus formocresol pulpotomy in primary molar teeth. *International Journal of Paediatric Dentistry*, 2013; **23(2)**: 145-52. [PMID: 22502601]; [DOI: 10.1111/j.1365-263X.2012.01237.x]
 26. Havale R, Anegundi RT, Indushekar K and Sudha P. Clinical and radiographic evaluation of pulpotomies in primary molars with formocresol, glutaraldehyde and ferric sulphate. *Oral Health Dental Management*, 2013; **21(1)**: 24-31. [PMID: 23474578].
 27. Yildirim A, Ceren B, Feridun A, Ozlem M and Günseli G. Clinical and radiographic evaluation of the effectiveness of formocresol, mineral trioxide aggregate, Portland cement, and enamel matrix derivative in primary teeth pulpotomies: a two year follow-up. *Journal of Clinical Pediatric Dentistry*, 2016; **40(1)**: 14-20. [PMID: 26696101]; [DOI: 10.17796/1053-4628-40.1.14]