

Successful Repeated Laparoscopic Liver Resection for Multiple Colorectal Metastasis in an Elderly Patient with Multiple Antiplatelets for High Thromboembolic Risks

Takahisa Fujikawa¹

¹ Department of Surgery, Kokura Memorial Hospital, Kitakyushu, Fukuoka, Japan.

Conflict-of-interest statement: The authors declare that there is no conflict of interest regarding the publication of this paper.

Open-Access: This article is an open-access article which was selected by an in-house editor and fully peer-reviewed by external reviewers. It is distributed in accordance with the Creative Commons Attribution Non Commercial (CC BY-NC 4.0) license, which permits others to distribute, remix, adapt, build upon this work non-commercially, and license their derivative works on different terms, provided the original work is properly cited and the use is non-commercial. See: <http://creativecommons.org/licenses/by-nc/4.0/>

Correspondence to: Takahisa Fujikawa, MD, PhD, FACS, Department of Surgery, 3-2-1 Asano, Kokurakita-ku, Kitakyushu, Fukuoka 802-8555, Japan.

Email: fujikawa-t@kokurakinen.or.jp

Telephone: +81-93-511-2000

Fax: +81-93-511-3240

Received: October 16, 2019

Revised: October 18, 2019

Accepted: October 19, 2019

Published online: December 21, 2019

ABSTRACT

We experienced a case of an elderly dual antiplatelet-burdened woman with high thromboembolic risks, undergoing repeated laparoscopic liver resection combined with multidrug chemotherapy for multiple bilobar liver metastases from colorectal cancer. Finally, R0 resection followed by the long-term survival was achieved. Combination of multidrug chemotherapy, repeated laparoscopic liver resection, and rigorous perioperative antithrombotic management with continuous aspirin monotherapy is one of the promising options for such high thromboembolic cases.

Key words: Laparoscopic liver resection; Repeated liver resection; Colorectal liver metastasis; Antiplatelet therapy; Arterial

thromboembolic risk

© 2019 The Authors. Published by ACT Publishing Group Ltd. All rights reserved.

Fujikawa T. Successful Repeated Laparoscopic Liver Resection for Multiple Colorectal Metastasis in an Elderly Patient with Multiple Antiplatelets for High Thromboembolic Risks. *Journal of Gastroenterology and Hepatology Research* 2019; **8(6)**: 3033-3035 Available from: URL: <http://www.ghrnet.org/index.php/joghr/article/view/2707>

LETTER TO THE EDITOR

We herein describe a case of an elderly antiplatelet-burdened woman with high thromboembolic risks, undergoing repeated laparoscopic liver resection (LLR) combined with multidrug chemotherapy for multiple bilobar liver metastases from colorectal cancer (CRC), and achieving R0 resection. A 71-year-old Japanese woman with reduced performance status due to decreased physical activity was diagnosed with advanced transverse colon cancer and concomitant multiple liver metastases (Figure 1A-1C). Because of impending obstruction of the colon, laparoscopic partial colon resection with regional lymph node dissection was initially performed, and the patient recovered soon postoperatively. Due to the patient's status of high thromboembolic risks, all the operative procedures were performed under continuation of aspirin monotherapy perioperatively according to the rigid antithrombotic management protocol^[1,2], and the patient experienced neither bleeding nor thromboembolic complications postoperatively. The patient received 5 cycles of FOLFOX plus panituzumab due to the wild type of Kras mutation, experienced no significant adverse drug events, and the tumor response was assessed as partial response. She underwent successful LLR (lateral sectionectomy combined with S5 and S8 partial resection). The patient quickly recovered postoperatively with minimal pain, and postoperative adjuvant chemotherapy was carried out using oral capecitabine for three months. Subsequently solitary liver metastasis at S5 region was detected (Figure 1D), and secondary LLR (S5 subsectionectomy) was performed without any complications. Although another adjuvant chemotherapy using 12 cycles of FOLFIRI was performed, two liver metastases in S6 and S7 were detected and again resected (two partial liver resection, Figure 1E). The patient was followed without

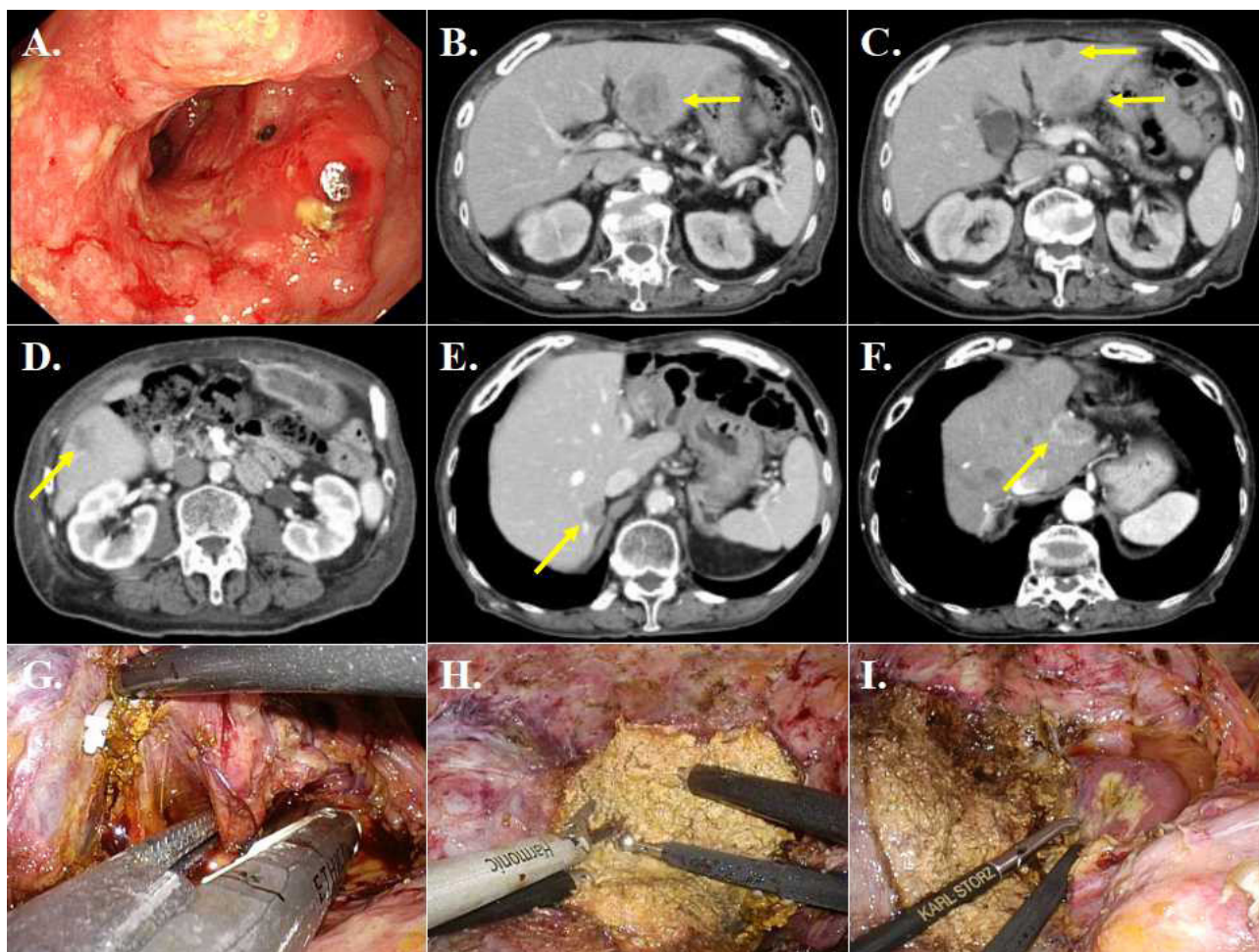


Figure 1 (A-C) Colonoscopy and enhanced CT scan of the abdomen demonstrated advanced transverse colon cancer and concomitant multiple liver metastases, all of which was resected after multidrug chemotherapy (S2, S3 yellow arrows, S5 and S8 lesions were not shown). (D) Subsequently, solitary S5 liver metastasis was detected and secondary resection (S5 subsectionectomy) was performed. (E) Third liver resection for two lesions (S7 and S8) were performed. (F) The new S4 lesion close to the cut margin was again detected. (G-I) Even after the history of multiple resection of bilobar legions, she also underwent successful laparoscopic medial sectionectomy under perioperative continuation of aspirin monotherapy (G: severing the left glissonean pedicle, H: liver parenchymal transection using two surgeon technique, I: After the resection of medial section).

chemotherapy for 18 months, and the new lesion was again detected in the residual left lobe. Even after the history of multiple resection of bilobar legions, she also underwent successful LLR (laparoscopic medial sectionectomy) under perioperative continuation of aspirin monotherapy (Figure 1G-I). The patient again quickly recovered postoperatively without any thromboembolic events, and discharged. She currently remained asymptomatic and free of any signs of recurrence for 18 months after the last operation (55 months after the first operation, Figure 2).

CRC is one of the most common causes of cancer-related death, and liver metastases comprise the most frequently encountered distant metastases, which generally occur with the rate of 10% to 15%. Liver resection for liver metastases from CRC is considered to be the standard of care and the only potentially curative therapy. Although the prognosis clearly improves as a result of liver resection, surgery is indicated in only around 20-40% of patients with colorectal liver metastases^{3,4}. However, recent reports demonstrated that various procedures aimed at improving the rate of surgical resection, including radical resection following chemotherapy^{5,6}. Especially, the role of systemic preoperative chemotherapy has been gradually recognized, and standard chemotherapy regimens such as FOLFOX or FOLFIRI in combination with molecular targeted drugs have been reported to facilitate a resection rate of up to 40% among patients

with initially unresectable liver metastases⁶. These multidisciplinary approaches may give us a chance to not only improve patients' long-term quality of life, but also expand indication of intensive treatment to previously excluded elderly patients.

On the other hand, with the advent of minimally invasive surgery and its expected benefits, many surgical procedures are now being performed or attempted laparoscopically. Laparoscopic advantages over open liver resection include reduced postoperative pain, less operative morbidity, shorter hospital stay, and faster recovery period⁷. Recent advances in surgical technique and laparoscopic devices allowed us to expand indication of laparoscopic liver resection (LLR) to malignant lesions, with acceptable short-term and long-term results⁷.

Although optimal perioperative management of high thromboembolic risk patients during major surgery like liver resection is still controversial, it is suggested that performing surgical intervention under single platelet continuation in order to prevent fatal thromboembolism is reasonable^{11,21}. In the present case, since the patient was regarded as high risk for thromboembolism, repeated LLRs were performed under preoperative continuation of aspirin monotherapy. From the previously reported studies concerning antiplatelet management for major abdominal surgery, it is recommended to carry out surgery under preoperative continuation of

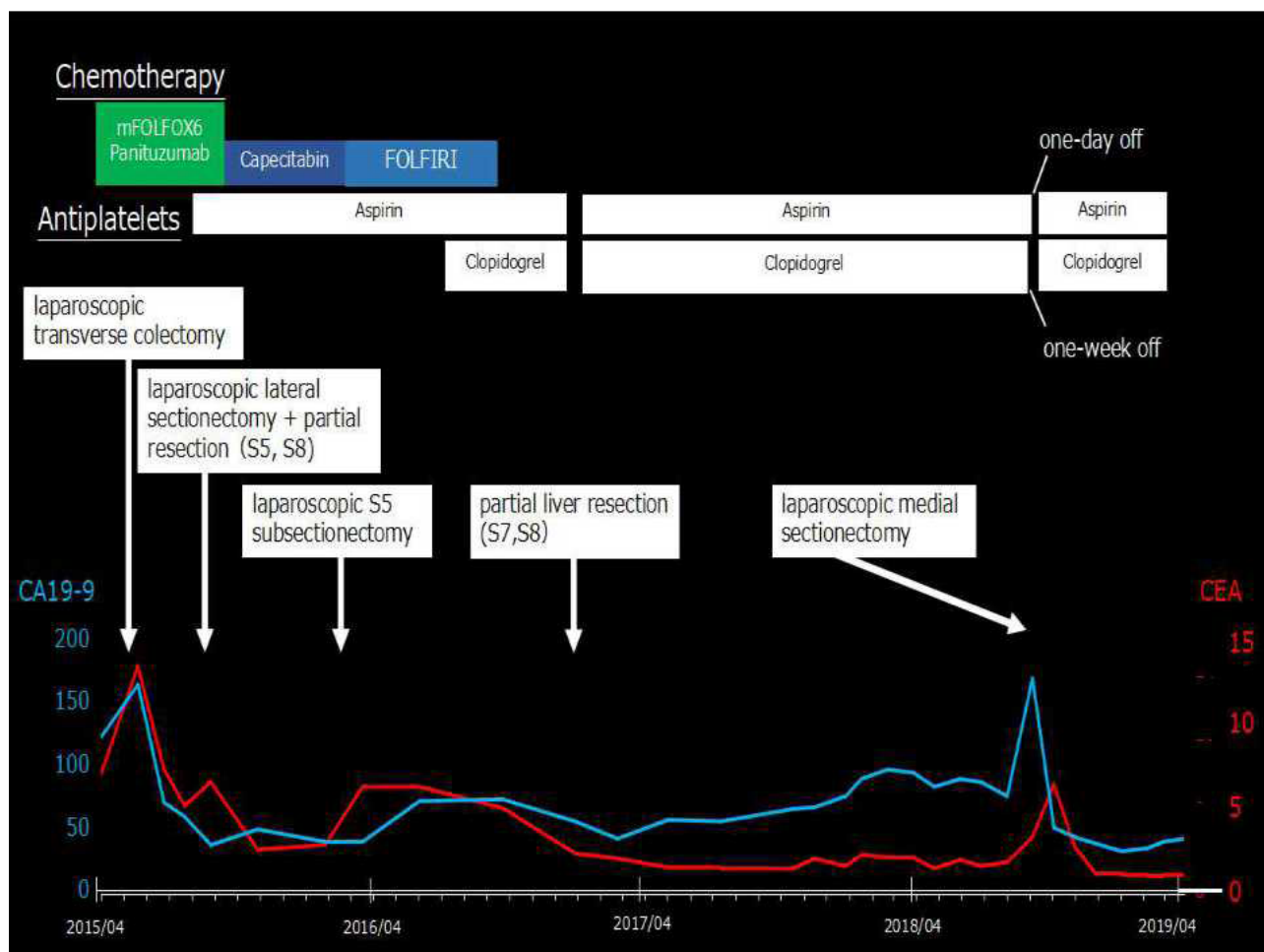


Figure 2 The whole clinical course of the current patient with serial changes in serum CA19-9 and CEA values.

single antiplatelet therapy such as aspirin. The current case highlights combination of repeated LLR and multidrug chemotherapy as one of the promising options even in high thromboembolic cases, and it is recommended to perform major digestive surgery under single aspirin continuation to prevent fatal thromboembolism.

REFERENCES

1. Fujikawa T1, Tanaka A, Abe T, Yoshimoto Y, Tada S, Maekawa H, Shimoike N. Does antiplatelet therapy affect outcomes of patients receiving abdominal laparoscopic surgery? Lessons from more than 1,000 laparoscopic operations in a single tertiary referral hospital. *J Am Coll Surg.* 2013;217(6):1044-1053. [PMID: 24051069]; [DOI: 10.1016/j.jamcollsurg.2013.08.005]
2. Fujikawa T, Tanaka A, Abe T, Yoshimoto Y, Tada S, Maekawa H. Effect of antiplatelet therapy on patients undergoing gastroenterological surgery: thromboembolic risks versus bleeding risks during its perioperative withdrawal. *World J Surg.* 2015;39(1):139-149. [PMID: 25201469]; [DOI: 10.1007/s00268-014-2760-3]
3. Sugihara K, Uetake H. Therapeutic strategies for hepatic metastasis of colorectal cancer: overview. *J Hepatobiliary Pancreat Sci.* 2012;19(5):523-527. [PMID: 22706522]; [DOI: 10.1007/s00534-012-0524-8]
4. Wang C-C, Li J. An update on chemotherapy of colorectal liver metastases. *World J Gastroenterol.* 2012;18(1):25-33. [PMID: 22228967]; [PMCID: PMC3251802]; [DOI: 10.3748/wjg.v18.i1.25]
5. Adam R, Delvart V, Pascal G, Valeanu A, Castaing D, Azoulay D, Giacchetti S, Paule B, Kunstlinger F, Ghémard O, Levi F, Bismuth H. Rescue surgery for unresectable colorectal liver metastases downstaged by chemotherapy: a model to predict long-term survival. *Ann Surg.* 2004;240(4):644-57; discussion 657-8. [PMID: 15383792]; [PMCID: PMC1356466]; [DOI: 10.1097/01.sla.0000141198.92114.f6]
6. Nordlinger B, Sorbye H, Glimelius B, Poston GJ, Schlag PM, Rougier P, Bechstein WO, Primrose JN, Walpole ET, Finch-Jones M, Jaeck D, Mirza D, Parks RW, Mauer M, Tanis E, Van Cutsem E, Scheithauer W, Gruenberger T; EORTC Gastro-Intestinal Tract Cancer Group; Cancer Research UK; Arbeitsgruppe Lebermetastasen und-tumoren in der Chirurgischen Arbeitsgemeinschaft Onkologie (ALM-CAO); Australasian Gastro-Intestinal Trials Group (AGITG); Fédération Francophone de Cancérologie Digestive (FFCD). Perioperative FOLFOX4 chemotherapy and surgery versus surgery alone for resectable liver metastases from colorectal cancer (EORTC 40983): long-term results of a randomised, controlled, phase 3 trial. *Lancet Oncol.* 2013;14(12):1208-1215. [PMID: 24120480]; [DOI: 10.1016/S1470-2045(13)70447-9]
7. Nguyen KT1, Laurent A, Dagher I, Geller DA, Steel J, Thomas MT, Marvin M, Ravindra KV, Mejia A, Lainas P, Franco D, Cherqui D, Buell JF, Gamblin TC. Minimally invasive liver resection for metastatic colorectal cancer: a multi-institutional, international report of safety, feasibility, and early outcomes. *Ann Surg.* 2009;250(5):842-848. [PMID: 19806058]; [DOI: 10.1097/SLA.0b013e3181bc789c]