

Mucinous Adenocarcinoma of the Rectum in a 13-Year-Old Child - A Case Report

Mostafa Zain¹, Mostafa Kotb¹, Basmal Abdulkareem¹, Yasmine Elwany², Dina Abdallah¹, Hanan Tayel¹

1 Alexandria Faculty of Medicine, Alexandria, Egypt;
2 Alexandria Medical Research Institute, Alexandria, Egypt.

© 2020 The Authors. Published by ACT Publishing Group Ltd. All rights reserved.

Conflict-of-interest statement: The authors declare that there is no conflict of interest regarding the publication of this paper.

Open-Access: This article is an open-access article which was selected by an in-house editor and fully peer-reviewed by external reviewers. It is distributed in accordance with the Creative Commons Attribution Non Commercial (CC BY-NC 4.0) license, which permits others to distribute, remix, adapt, build upon this work non-commercially, and license their derivative works on different terms, provided the original work is properly cited and the use is non-commercial. See: <http://creativecommons.org/licenses/by-nc/4.0/>

Correspondence to: Mostafa Kotb, Alexandria Faculty of Medicine, Alexandria, Egypt.

Email: rashad@alexmed.edu.eg

Telephone: +201062333868

Received: January 3, 2020

Revised: February 22, 2020

Accepted: February 27, 2020

Published online: June 21, 2020

ABSTRACT

Although colorectal carcinoma (CRC) is the second most common primary gastrointestinal system malignancies in children after liver tumors, it is extremely rare in pediatric age. Due to the lack of awareness of the disease, diagnosis is usually delayed till it is in advanced stage, leading to a poor prognosis as compared to adults. We present a case of CRC in a 13-year-old girl who presented with abdominal pain, vomiting and unintentional weight loss. Clinical examination and imaging did not reveal a clear pathology. On exploration, a marked circumferential thickening of the wall of the sigmoid colon and the rectum was noted. Biopsies proved to be a mucinous adenocarcinoma of the rectosigmoid, infiltrating the wall till subserosal fat.

Key words: Colorectal cancer; Mucinous adenocarcinoma; Signet-ring cells

Zain M, Kotb M, Abdulkareem B, Elwany Y, Abdallah D, Tayel H. Mucinous Adenocarcinoma of the Rectum in a 13-Year-Old Child - A Case Report. *Journal of Gastroenterology and Hepatology Research* 2020; **9(3)**: 3228-3230 Available from: URL: <http://www.ghrnet.org/index.php/joghr/article/view/2771>

INTRODUCTION

Colorectal carcinoma (CRC) comprises around 1% of pediatric neoplasms, and after primary liver tumors, it is the second most common primary gastrointestinal system malignancies in children^[1]. Due to the lack of awareness of the disease, diagnosis is usually delayed till it is in advanced stage, leading to a poor prognosis as compared to adults^[2]. We report a case of mucinous adenocarcinoma of the rectum in a 13-year-old boy without any risk factors. We also review the clinical and pathological characteristics of such a rare entity.

CASE REPORT

A 13-year-old boy presented to our department with fever, bilious vomiting and abdominal pain since 6 days. There was a history of weight loss (about 25 kg) and loss of appetite for the last 3 months. On examination, there was generalized tenderness and rigidity all over the abdomen. Computed tomography (CT) of the abdomen and pelvis showed mild supra and infracolic pneumoperitoneum as well as moderate to marked partially loculated fluid collection all over the abdomen.

On entry to the abdomen, about 1 liter of pus was aspirated. Moreover, a marked circumferential thickening of the wall of the sigmoid colon and the rectum was noted (Figure 1). This lesion was extending down to about 2 cm above the anal verge. Resection of this mass was not feasible due to severe inflammation and friability of the surrounding tissues as well as its distance from the anal verge. Therefore, two full thickness biopsies were taken from the sigmoid and subsequently the procedure was terminated.

Multiple greyish brown tissue fragments were submitted to the pathology department, they were totally processed. Microscopic examination of H&E stained sections revealed an infiltrative

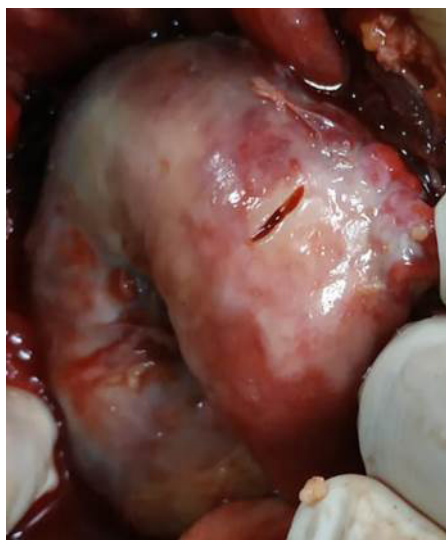

Figure 1 Intraoperative photo showing a marked circumferential thickening of the wall of the sigmoid colon and the rectum.

neoplastic growth infiltrating through the whole wall thickness: mucosa, submucosa and musculosa. The tumor is composed of mucin secreting signet ring cells forming nests and acini and were floating within mucin lakes. The cells showed pleomorphism, hyperchromatism, with marked nuclear atypia. Foci of necrosis were noted as well (Figure 2).

DISCUSSION

CRC is uncommon in children, with only few cases had been reported in literature^[3-9]. The reported peak age among the reported case is 15 years old, whilst the youngest reported case was a 9-month-old female infant^[5].

Vomiting and abdominal pain are among the most common symptoms in pediatric CRC patients^[9]. Other possible symptoms include weight loss, change in bowel habits and anemia depending on the location of the tumor^[10]. Unfortunately, these symptoms are nonspecific in children, and they may mimic many common functional gastrointestinal disorders^[11]. The duration of symptoms before diagnosis is usually long, ranging from 2 to 6 months (median of 3 months)^[10].

The disease usually occurs sporadically^[12]; nevertheless, 10% to 30% of CRCs in children have predisposing factors for instance, familial adenomatous polyposis (FAP), Crohn's disease, ulcerative colitis and Peutz-Jegher syndrome. One of the most important genetic mutations in pediatrics CRC is high microsatellite instability (MSI) that results from a DNA mismatch repair system. It is considered the hallmark of the early-onset CRC, Lynch syndrome, which is also known as hereditary nonpolyposis colorectal cancer syndrome (HNPCC)^[5].

Regrettably, due to the vague nature of its presentation, children usually present with an advanced stage of the disease at initial diagnosis and a higher incidence of more aggressive tumors as well^[5,9]. Whilst adults are usually affected with moderately differentiated adenocarcinoma, mucinous adenocarcinoma predominates in the pediatric age group despite being rare in adults^[26]. The mucin is known to absorb water, swell and invade the nearby tissues; thus, promoting spread of malignant cells. The tumors has the capability to attain a huge size as the result of the pooling mucin as well as the interference made by mucopolysaccharide coating to the

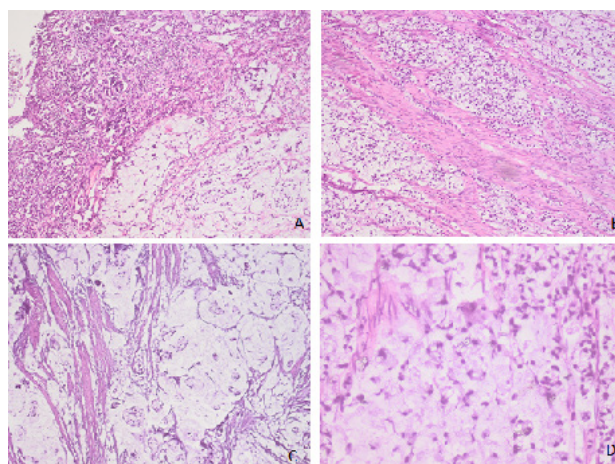


Figure 2 Histologic features of the tumor. A: H&E stained section showing infiltration of mucosa and submucosa by tumor masses (H&Ex100). B: H&E stained section showing splayed musculosa by tumor nests (H&Ex100). C: A section showing acini and clusters of signet ring cells within mucin lakes (H&Ex100). D: High power image showing signet ring cells (H&Ex400).

immune recognition of carcinoma cells^[14]. The signet ring subtype is notorious for its worst prognosis owing to its very rapid growth, regional lymph node involvement and diffuse peritoneal seeding at the initial presentation^[14].

Surgery offers the only curative modality for localized CRCs. Nevertheless, patients with stage \geq III should undergo adjuvant chemotherapy to eradicate micrometastases in order to reduce disease recurrence and increase the cure rate^[15]. Compared to adults, metastasis during initial presentation is considerably higher in pediatrics compared to adults (37% vs 18%)^[16]. The most common sites of distant metastasis are liver, lung, lymph nodes, and peritoneum^[16]. Indicators of poor prognosis are high tumor staging, incomplete excision, mucinous histology, signet-ring cells proportion $>$ 10% and absence of in-situ component^[13]. Despite the advances in diagnosis and treatments, the overall 5-year survival is around 75% in adult patients but, unfortunately, only 51% in pediatric population^[4].

To sum up, should there is a significant unintentional loss of weight along with change in bowel habits, a search for underlying malignancy, even in the absence of a positive family history or predisposing cancer syndromes, should be made.

REFERENCES

1. Khan AM, Doig CM, Dickson AP. Advanced colonic carcinoma in children. *Postgrad Med J.* 1997; **73**: 169-170. [PMID: 9135836]; [PMCID: PMC2431270]; [DOI: 10.1136/pgmj.73.857.169]
2. Wyllie R, Hyams JS, Kay M, (eds). *Pediatric Gastrointestinal and Liver Disease.* 4th ed. Philadelphia: Saunders; 2011.
3. Jeong YJ, Lee MR, Kim JC, Hwang PH, Moon WS, Chung MJ. Carcinosarcoma of the rectosigmoid colon in a 13-year-old girl. *Pathol Int.* 2008; **58**: 445-450. [PMID: 18577115]; [DOI: 10.1111/j.1440-1827.2008.02252.x]
4. Ferrari A, Rognone A, Casanova M, Zaffignani E, Piva L, Collini P, Bertario L, Sala P, Leo E, Belli F, Gallino G. Colorectal carcinoma in children and adolescents: the experience of the Istituto Nazionale Tumori di Milan, Italy. *Pediatr Blood Cancer.* 2008; **50**: 588-593.
5. Salas-Valverde S, Lizano A, Gamboa Y, Vega S, Barrantes M, Santamaria S, Zamora JB. Colon carcinoma in children and adolescents: prognostic factors and outcome-a review of 11 cases. *Pediatr Surg Int.* 2009; **25**: 1073-1076. [PMID: 19816697]; [DOI: 10.1007/s00383-009-2491-y]

6. Chattopadhyay S, Gupta P, Aich RK, Deb AR. Colorectal carcinoma in a ten-year-old girl: a case report. *J Cancer Res Ther.* 2012; **8**: 120-122. [PMID: 22531529]; [DOI: 10.4103/0973-1482.95189]
7. Al-Tonbary Y, Darwish A, El-Hussein A, Fouda A. Adenocarcinoma of the colon in children: case series and mini-review of the literature. *Hematol Oncol Stem Cell Ther.* 2013; **6**: 29-33. [PMID: 23664603]; [DOI: 10.1016/j.hemonc.2013.02.003]
8. Malik R, Kamath N. Anorectal mucinous adenocarcinoma in child: a case report. *Eur J Pediatr.* 2011; **170**: 1461-1463. [PMID: 21743985]; [DOI: 10.1007/s00431-011-1527-1]
9. Agrawal P, Rajwanshi A, Gupta N, Rao KL. Mucinous adenocarcinoma of rectum in an 11-year-old boy: a case report. *Diagn Cytopathol.* 2012; **40**: 252-554. [DOI: 10.1002/dc.21627]
10. Hill DA, Furman WL, Billups CA, Riedley SE, Cain AM, Rao BN, Pratt CB, Spunt SL. Colorectal carcinoma in childhood and adolescence: a clinicopathologic review. *J Clin Oncol.* 2007; **25**: 5808-5814. [PMID: 18089879 DOI: 10.1200/JCO.2007.12.6102]
11. Smith D, Ballal M, Hodder R, Sojn G, Selvachandran SN, Cade D. Symptomatic presentation of early colorectal cancer. *Ann R Coll Surg Engl* 2006; **88**: 185-190. [PMID: 16551416]; [PMCID: PMC1964069]; [DOI: 10.1308/003588406X94904]
12. Yamagishi H, Kuroda H, Imai Y, Hiraishi H. Molecular pathogenesis of sporadic colorectal cancers. *Chin J Cancer.* 2016; **35**: 4. [PMID: 26738600]; [PMCID: PMC4704376]; [DOI: 10.1186/s40880-015-0066-y]
13. Singer G, Hoellwarth ME. Colorectal carcinomas in children: an institutional experience. *Pediatr Surg Int.* 2012; **28**: 591-595. [PMID: 22526552]; [DOI: 10.1007/s00383-012-3090-x]
14. Furman WL, Tricoli JV. Important considerations in treating children, adolescents and young adults with colorectal carcinoma. *Colorectal Cancer.* 2013; **2**: 347-358. [DOI: 10.2217/crc.13.40]
15. Koh KJ, Lin LH, Huang SH, Wong JU. CARE - pediatric colon adenocarcinoma: a case report and literature review comparing differences in clinical features between children and adult patients. *Medicine.* 2015; **94**: e503. [PMID: 25674743]; [PMCID: PMC4602740]; [DOI: 10.1097/MD.0000000000000503]
16. Riihimäki M, Hemminki A, Sundquist J, Hemminki K. Patterns of metastasis in colon and rectal cancer. *Sci Rep.* 2016; **6**: 29765. [PMID: 27416752]; [PMCID: PMC4945942]; [DOI: 10.1038/srep29765]