

Journal of Gastroenterology and Hepatology Research

Online Submissions: <http://www.ghrnet.org/index./joghr/>
doi: 10.17554/j.issn.2224-3992.2020.09.919

Journal of GHR 2020 April 21; 9(2): 3150-3154
ISSN 2224-3992 (print) ISSN 2224-6509 (online)

CASE REPORT

Gastric Adenocarcinoma in a Young Nigerian – A Case Report

Oguntoye Oluwatosin Oluwagbenga¹, Yusuf Musah¹, Olowoyo Paul¹, Erinomo Olagoke², Omoseebi Oladipo², Soje Michael Osisio¹, Oguntoye Oluwafunmilayo Adenike³, Fatudimu Oluwafemi⁴

1 Department of Internal Medicine, Federal Teaching Hospital Ido-Ekiti and Afe Babalola University Ado-Ekiti, Nigeria;

2 Department of Morbid Anatomy, Federal Teaching Hospital Ido-Ekiti and Afe Babalola University Ado-Ekiti, Nigeria;

3 Department of Internal Medicine, Federal Teaching Hospital Ido-Ekiti, Nigeria;

4 Department of Surgery, Federal Teaching Hospital Ido-Ekiti and Afe Babalola University Ado-Ekiti, Nigeria.

Conflict-of-interest statement: The authors declare that there is no conflict of interest regarding the publication of this paper.

Open-Access: This article is an open-access article which was selected by an in-house editor and fully peer-reviewed by external reviewers. It is distributed in accordance with the Creative Commons Attribution Non Commercial (CC BY-NC 4.0) license, which permits others to distribute, remix, adapt, build upon this work non-commercially, and license their derivative works on different terms, provided the original work is properly cited and the use is non-commercial. See: <http://creativecommons.org/licenses/by-nc/4.0/>

Correspondence to: Oguntoye Oluwatosin Oluwagbenga. MBBS (Ibadan), FWACP(Gastroenterol), Lecturer 1 and Consultant Physician / Gastroenterologist and Hepatologist, Department of Internal Medicine, Federal Teaching Hospital Ido-Ekiti and Afe Babalola University Ado-Ekiti, Ekiti State, Nigeria.

Email: proflast@yahoo.com

Telephone: +2348086638538

Received: February 27, 2020

Revised: March 20, 2020

Accepted: March 26, 2020

Published online: April 21, 2020

ABSTRACT

Gastric adenocarcinoma is uncommon among young Nigerians. We present Mrs O.V. a 41year old Nigerian who presented with one year history of recurrent epigastric pain that was peppery/burning in nature, non-radiating, aggravated by eating and temporarily relieved with the use of antacids. There is associated progressive weight loss and secondary amenorrhea since the onset of her illness. She started vomiting two weeks prior to presentation which was non-projectile,

containing both recently ingested meals and partially digested stale food substances, vomitus was non-bilious. Episodes of vomiting is usually preceded by abdominal bloating or feeling of indigestion. Clinical examination revealed a chronically ill-looking young woman with a positive succussion splash on abdominal examination. Examination of the other systems was normal. Provisional diagnosis was suspected Chronic Gastric Antral Ulcer complicated by Gastric Outlet Obstruction to rule out Gastric Antral Adenocarcinoma. Abdominal ultrasound and CT scans showed features consistent with Gastric Outlet Obstruction. Upper GI Endoscopy revealed Gastric Antral Adenocarcinoma with Duodenal extension and Chronic Duodenal Ulcer complicated by Gastric Outlet Obstruction. Histology showed well differentiated Gastric Antral Adenocarcinoma. She had a Bilroth II procedure(Partial Gastrectomy and Gastro-Jejunostomy)and was commenced on adjunct chemotherapy: FAM regimen(5-Fluorouracil, Adriamycin and Mitomycin). She was also placed on long term proton pump inhibitor therapy. She has sustained remarkable clinical improvement with resolution of all her initial symptoms and she is currently on regular clinic follow-up. More cases of Gastric Adenocarcinoma among young Nigerians are being reported. There is a need for more extensive studies on this and possibly an indication for commencing endoscopy screening at an earlier age among individuals presenting with recent onset dyspepsia.

Key words: Gastric; Adenocarcinoma; Young; Nigerians

© 2020 The Authors. Published by ACT Publishing Group Ltd. All rights reserved.

Oguntoye OO, Yusuf M, Olowoyo P, Erinomo O, Omoseebi O, Soje MO, Oguntoye OA, Fatudimu O. Gastric Adenocarcinoma in a Young Nigerian - A Case Report. *Journal of Gastroenterology and Hepatology Research* 2020; 9(2): 3150-3154 Available from: URL: <http://www.ghrnet.org/index.php/joghr/article/view/2815>

INTRODUCTION

Gastric cancer is the sixth most common malignancy worldwide, after cancers of the lung, breast, prostate, colon and rectum, and skin (non-melanoma), and it is the third cause of death of all malignancies worldwide^[1]. The World Health Organization estimates that in 2018, gastric cancer accounted for 783,000 deaths worldwide^[2].

The incidence of gastric cancer shows wide geographical variation.

The high-risk areas are East Asia (China and Japan), Eastern Europe, Central and South America^[1,3]. The low-risk areas are Southern Asia, North and East Africa, North America, Australia, and New Zealand.^[1,3] Gastric cancer has a low prevalence in sub-Saharan Africa with the lowest incidence rates in Western Africa^[4,5]. The majority of Gastric cancers occurs sporadically and mainly affects people over the age of 45 years and they are commonly caused by a combination of many environmental factors^[6,7]. The incidence of Gastric cancer increases with age. In the United States the median age at diagnosis is 68 years^[8]. In Nigeria, Gastric cancer accounts for 1.1-6.0%^[5,9] of all cancers and the mean age at diagnosis is 56 years^[5,10,11]. Gastric cancer is uncommon among young Nigerians.

Early gastric cancer has no specific symptoms, most symptoms of gastric cancer reflect advanced disease^[12]. Therefore, patients with dyspepsia with any of the following ALARM features should be evaluated with upper GI endoscopy for early diagnosis of a possible gastric cancer: Age \geq 50 years, Family history of upper GI malignancy in a first-degree relative, Unintended weight loss, GI bleeding or iron deficiency anemia, Dysphagia, Odynophagia, Persistent vomiting and Abnormal imaging suggesting organic disease^[13].

In Nigeria and sub-Saharan Africa most patients present with advanced disease often complicated by gastric outlet obstruction, bleeding or perforation^[10,14]. We report a case of Gastric adenocarcinoma in a young Nigerian presenting with features of gastric outlet obstruction.

CASE PRESENTATION

We present Mrs O.V. a 41year old Nigerian of the Yoruba tribe who presented at our Gastroenterology clinic with recurrent upper abdominal pain and weight loss of one year duration and vomiting of two weeks duration. She was apparently well until one year ago when she developed upper abdominal pain worse in the epigastrium of insidious onset, peppery/burning in nature, non-radiating, aggravated by eating and temporarily relieved with the use of antacids. Not a known patient with peptic ulcer disease, no history of NSAID or steroid use, no cigarette smoking, no consumption of alcohol, no consumption of smoked food items, no family history of gastric cancer. The pain became worse a month prior to presentation and has been progressive. There is associated progressive unintentional weight loss over the last one year despite intact appetite but she is afraid to eat because it worsens the epigastric pain. There is lethargy and occasional dizziness. No anterior neck swelling, no heat intolerance, no risk factors for HIV infection. There is amenorrhea; her last menstrual period was one year ago.

She started vomiting two weeks prior to presentation which was non-projectile, containing both recently ingested meals and partially digested stale food substances, vomitus was non-bilious. Episodes of vomiting is usually preceded by abdominal bloating or feeling of indigestion. No haematemesis or melaena. No abdominal swelling, no constipation, no tenesmus, no jaundice.

Review of other systems was not contributory.

Clinical examination revealed a young woman, chronically ill-looking, not pale, anicteric, acyanosed, afebrile, had some dehydration, no digital clubbing, no significant peripheral lymph node enlargement, no pedal oedema and no asterixis. The Abdomen was scaphoid, moved with respiration, mild epigastric tenderness, no epigastric mass felt but had a positive succussion splash. The liver, spleen and kidneys were not palpably enlarged. No Ascites and the bowel sounds were normoactive. Digital rectal examination was

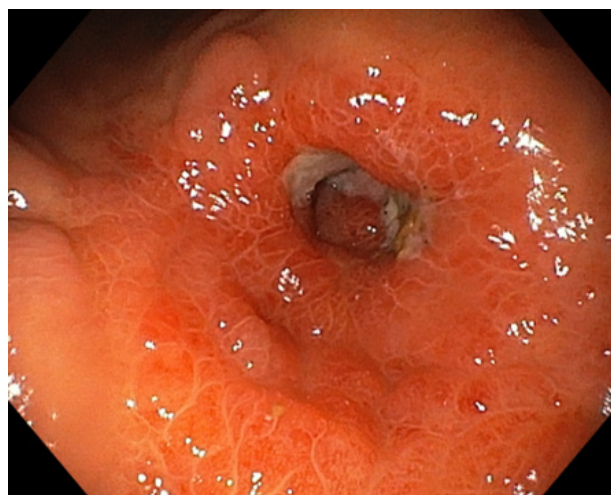


Figure 1 An Endoscopic image of the Gastric Antrum showing inflamed antrum (hyperaemic and oedematous) with friable, unhealthy appearing mucosa. The mucosa is uneven with multiple swellings / elevations, these lesions extend to involve the pylorus and the duodenal bulb.

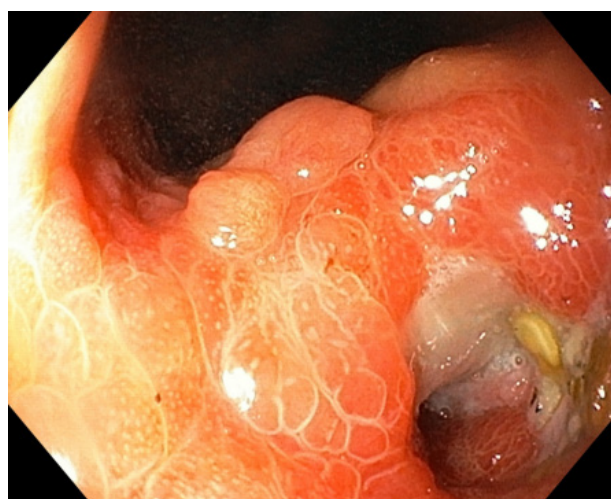


Figure 2 An Endoscopic image of the Duodenum Bulb showing extensive ulcers with significant luminal narrowing due to fibrosis/cicatrizization that made it impossible to advance the scope further. This is the cause of the Gastric outlet obstruction in this patient.

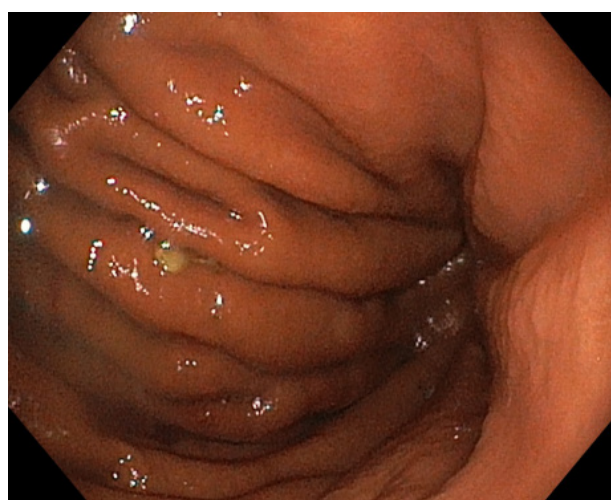

Figure 3 An Endoscopic image of the Descending colon.

normal. Examination of the other systems was also normal.

Provisional diagnosis was suspected Chronic Gastric Antral or

Pyloric Channel Ulcer complicated by gastric outlet obstruction from cicatrization of the chronic ulcer to rule out Gastric Antral Adenocarcinoma.

Investigation results are as follows: Full Blood Count - PCV=47%, WBC=9,700 × 10⁶/L (Neutrophils=54.6%, Lymphocytes=34.7%, Monocytes=9.8%, Eosinophils=0.3%, Basophils=0.6%), Platelets=259,000 × 10⁶/L. ESR=14mm/hr. FBG=4.5mmol/L and 2HPP=5.7mmol/L. E,U&Cr - Na⁺=133mmol/L, K⁺=3.8mmol/L, Cl⁻=98mmol/L, HCO₃⁻=27mmol/L, Urea=4.6mmol/L, Creatinine=93umol/L.

Abdominal ultrasound scan: The stomach is markedly dilated and contains multiple floating coarse echoes, some of which settle at the dependent part consistent with food residues. There is abrupt tapering at the pylorus and associated pyloric wall thickening. No Ascites. The other intra-abdominal and pelvic organs and structures are within normal limits. Conclusion: Features are consistent with Gastric Outlet Obstruction.

Abdominal CT scan: Circumferential thickening of the gastric pyloric wall is seen with some narrowing of its lumen. The thickest part measures 12.6mm and the parts of the stomach is preserved. The other demonstrated bowel loops appear normal. No obvious enlarged lymph node seen. The Liver (span - 13.9 cm), intrahepatic ducts, vascular channels, gallbladder, pancreas, spleen (span - 7.34 cm) are preserved. No ascites seen. Both kidneys are normal positions, orientations, outlines, parenchymal density and preserved corticomedullary differentiation. The uterus, both adnexa and pouch of Douglas are normal. Conclusion: Pyloric antral mass? Carcinoma.

Upper GI Endoscopy: Inflamed antrum (hyperaemic and oedematous) with friable, unhealthy appearing mucosa that bleeds with contact with the scope. Mucosa is uneven with multiple swellings / elevations (Figure 1). These lesions extend to involve the pylorus and the duodenal bulb sparing the gastric corpus, cardia and fundus. There are multiple areas of ulceration in the duodenal bulb with mucosal hyperaemia and oedema, and significant luminal narrowing that made it impossible to advance the scope further (Figure 2). Thus, the rest of the duodenum could not be visualized. Normal gastric rugae and minimal fluid collection in the stomach cavity containing few food debris (Figure 3-5). Conclusion: (1) Suspected Gastric Antral Adenocarcinoma with Duodenal extension (2) Chronic Duodenal Ulcer complicated by Gastric Outlet Obstruction.

Histology

Macroscopy: Gastric Antrum: Specimen consists of 10 tiny pieces of firmly greyish white tissues which altogether measures 0.8cm in length.

Duodenum: Received 4 tiny pieces of firmly greyish white tissues which altogether measures 0.4cm in length.

Microscopy

Gastric Antrum: Histologic sections show bizzare well to moderate well-formed glands lined by pleomorphic epithelial cells sharing large hyperchromatic nuclei with intracellular and extracellular mucin production. These are seen within an inflamed fibro-collagenous tissue.

Diagnosis: Gastric Antral, well differentiated adenocarcinoma (Figures 6 and 7).

Duodenum: Histologic sections are not remarkable.

She was reviewed by the surgeons and a diagnosis of Distal Gastric Cancer was made. She had an elective exploratory laparotomy done under general anaesthesia. A Bilroth II procedure was performed: Partial Gastrectomy and Gastro-Jejunostomy. She subsequently was

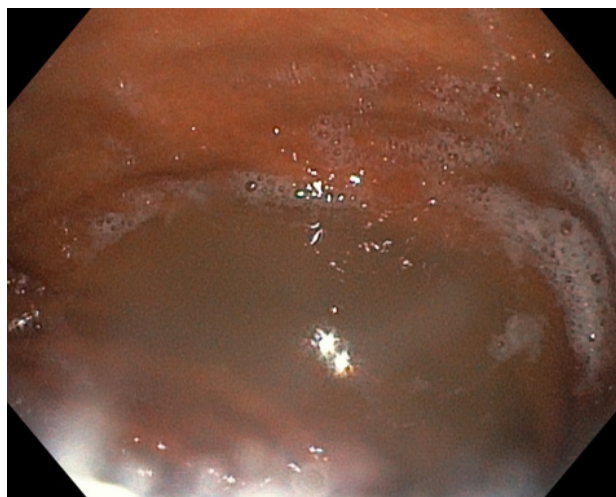


Figure 4 Significant fluid collection in the gastric cavity despite an overnight fast of the patient in keeping with Gastric outlet obstruction.

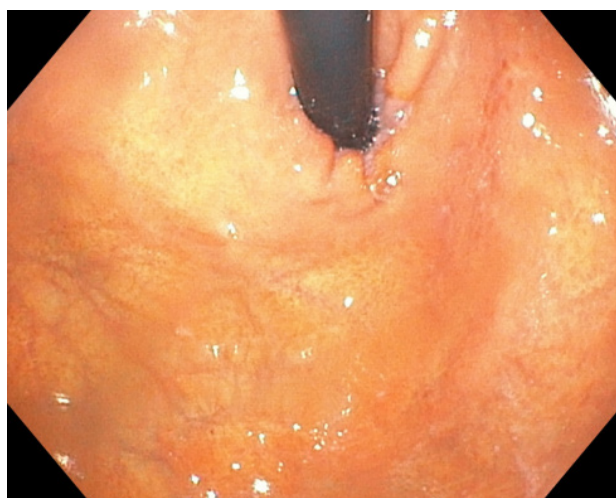

Figure 5 An Endoscopic image of the Gastric Fundus showing normal appearance.

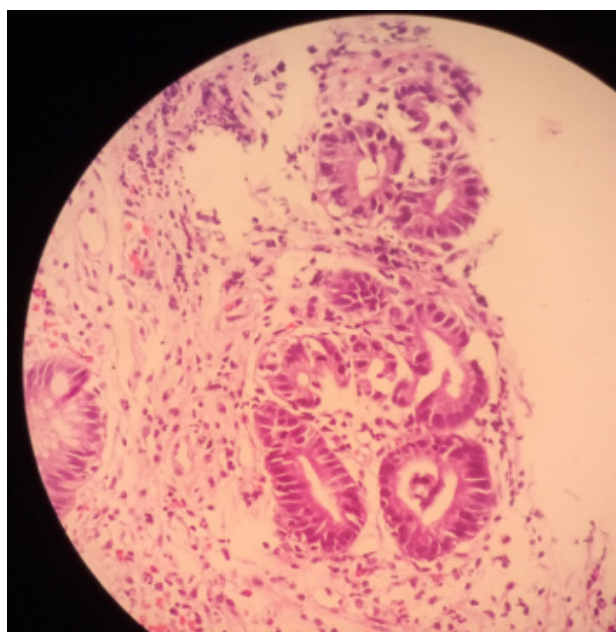


Figure 6 Micrograph showing malignant glands infiltrating the submucosa within a pool of mucin (x10 magnification).

commenced on adjunct chemotherapy: FAM regimen (5-Fluorouracil, Adriamycin and Mitomycin). She was also placed on a proton pump inhibitor (Rabeprazole 20mg twice daily). She has sustained remarkable clinical improvement with resolution of all her initial symptoms and she is currently on regular clinic follow-up.

CONCLUSION

Gastric cancer is uncommon among young Nigerians but more cases of Gastric cancers among young Nigerians are being reported. There is a need for more extensive studies on this and possibly an indication for commencing endoscopy screening at an earlier age among individuals presenting with recent onset dyspepsia. Early gastric cancer has no specific symptoms, most symptoms of gastric cancer reflect advanced disease.

In Nigeria and many developing countries, most patients present late with advanced disease or complications, and curative treatment is often impossible. Therefore, in order to significantly reduce the morbidity and mortality associated with Gastric cancers particularly in poor resource countries, important measures need to be put in place including health education of the populace on the value of seeking medical attention early; avoidance of the risk factors of the disease; and primary prevention strategies directed at eradicating *H. pylori* infection.

Endoscopy should be considered for dyspeptic patients with Alarm features because of the risk of underlying gastric malignancy. Gastroscopy offers early detection, treatment and surveillance of gastric cancer. There is a need for a national guideline in Nigeria as regards at what age to commence screening endoscopy for dyspeptic patients for the early detection of premalignant lesions or early gastric cancers. This is important because gastric cancers occur at an earlier age in our population compared to the Western countries. In the United States, Age ≥ 50 years is used for the commencement of screening; Nigeria should recommend Age ≥ 40 years.

ACKNOWLEDGEMENT

Special thanks to the House Officers and Resident Doctors in the Gastroenterology unit of the Department of Internal Medicine for their support in making this publication a reality. The authors did not receive any financial support from any individual, group or organization towards this research work.

REFERENCES

1. Bray F, Ferlay J, Soerjomataram I, Siegel RL, Torre LA, Jemal A. Global cancer statistics 2018: GLOBOCAN estimates of incidence and mortality worldwide for 36 cancers in 185 countries. *CA Cancer J Clin.* 2018 Nov. **68(6)**: 394-424. [PMID: 30207593]; [DOI: 10.3322/caac.21492].
2. World Health Organization. Cancer. WHO. Available at <http://www.who.int/mediacentre/factsheets/fs297/en/>. 12 September 2018; Accessed: February 5, 2020.
3. Stock M, Otto F. Gene deregulation in gastric cancer. *Gene.* 2005; **360(1)**: 1-19. [PMID: 16154715]; [DOI: 10.1016/j.gene.2005.06.026].
4. Parkin DM. Global cancer statistics in the year 2000. *Lancet Oncol.* 2001; **2**: 533-543. [PMID: 11905707]; [DOI: 10.1016/S1470-2045(01)00486-7].
5. Oluwasola AO, Ogunbiyi JO. Gastric cancer: aetiological, clinicopathological and management pattern in Nigeria. *Niger J Med.* 2003; **12**: 177-186. [PMID: 14768190].
6. Sitarz R, Skieruchab M, Mielko J, Offerhaus G, Maciejewski R, Polkowski W. Gastric cancer: epidemiology, prevention,

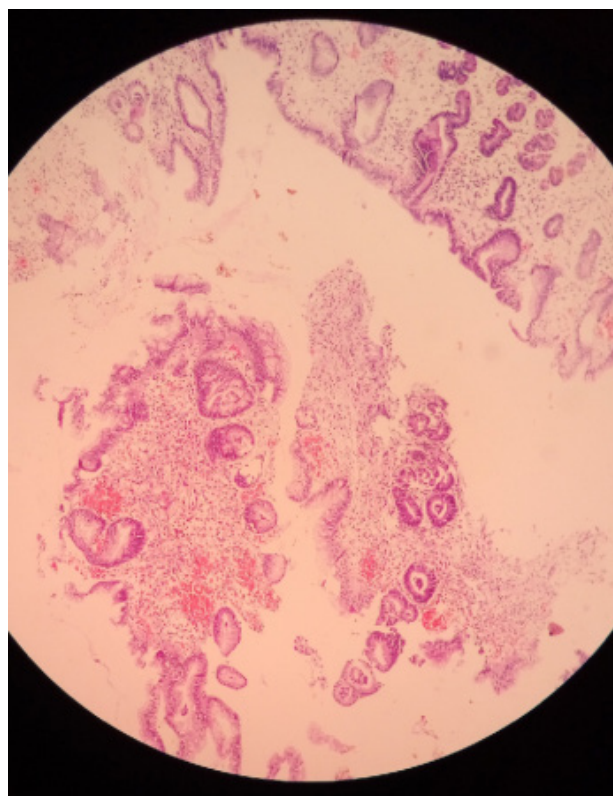


Figure 7 Micrograph showing group of well differentiated malignant glands infiltrating the gastric submucosa and surrounded by pool of mucin ($\times 4$ magnification).

- classification, and treatment. *Cancer Manag Res.* 2018; **10**: 239-248. [PMID: 29445300]; [PMCID: PMC5808709]; [DOI: 10.2147/CMAR.S149619].
7. Forman D, Burley VJ. Gastric cancer: Global pattern of the disease and an overview of environmental risk factors. *Best Pract Res Clin Gastroenterol.* 2006; **20(4)**: 633-649. [PMID: 16997150]; [DOI: 10.1016/j.bpg.2006.04.008].
8. Surveillance, Epidemiology, and End Results Program. SEER Stat Fact Sheets: Stomach Cancer. National Cancer Institute. Available at <http://seer.cancer.gov/statfacts/html/stomach.html>. Accessed: February 5, 2020.
9. Bakari AA, Ibrahim AG, Gali BM, Dogo D, Ngadda HA. Pattern of gastric cancer in Northeastern Nigeria: A clinicopathological study. *J Chinese Med.* 2010; **5**: 211-215. Record Number: 20103245446.
10. Afuwape OO, Irabor DO, Ladipo JK, Ayandipo B. A review of the current profile of gastric cancer presentation in the university college hospital Ibadan, a tertiary health care institution in the tropics. *J Gastrointest Cancer.* 2012; **43(2)**: 177-180. [PMID: 21298558]; [DOI: 10.1007/s12029-011-9259-z].
11. Abdulkareem FB, Onyekwere CA, Awolola NA, Ajekigbe AT. Clinico-pathological review of malignant gastric tumours in Lagos, Nigeria. *Nig Q J Hosp Med.* 2010; **20(2)**: 49-54. [PMID: 21243852]; [DOI: 10.4314/nqjhm.v20i2.58021].
12. Cabebe EC. Gastric Cancer. <https://emedicine.medscape.com/article/278744-overview#a1> Updated: Feb 24, 2020. Accessed: Feb 27, 2020.
13. Shaukat A, Wang A, Acosta RD, Bruining DH, Chandrasekhara V, Chathadi KV, Eloubeidi MA, Fanelli RD, Faulx AL, Fonkalsrud L, Gurudu SR, Kelsey LR, Khashab MA, Kothari S, Lightdale JR, Muthusamy VR, Pasha SF, Saltzman JR, Yang J, Cash BD, DeWitt JM. The role of endoscopy in dyspepsia. *Gastrointestinal Endoscopy* 2015; **82(2)**: 227-232. [PMID: 26032200]; [DOI: 10.1016/j.gie.2015.04.003].

14. Ahmed A, Ukwenya AY, Makama JG, Mohammad I. Management and outcome of gastric carcinoma in Zaria, Nigeria. *Afr Health*

Sci. 2011; **11(3)**: 353-361. [PMID: 22275924]; [PMCID: PMC3261017].