

Journal of Gastroenterology and Hepatology Research

Online Submissions: <http://www.ghrnet.org/index./joghr/>
doi: 10.17554/j.issn.2224-3992.2020.09.907

Journal of GHR 2020 April 21; 9(2): 3146-3149
ISSN 2224-3992 (print) ISSN 2224-6509 (online)

CASE REPORT

Ulcerative Colitis in A Nigerian – A Case Report

Oguntoye Oluwatosin Oluwagbenga¹, Yusuf Musah¹, Olowoyo Paul¹, Erinomo Olagoke², Omoseebi Oladipo², Soje Michael Osisio¹, Oguntoye Oluwafunmilayo Adenike³, Fatudimu Oluwafemi⁴

1 Department of Internal Medicine, Federal Teaching Hospital Ido-Ekiti and Afe Babalola University Ado-Ekiti, Nigeria;

2 Department of Morbid Anatomy, Federal Teaching Hospital Ido-Ekiti and Afe Babalola University Ado-Ekiti, Nigeria;

3 Department of Internal Medicine, Federal Teaching Hospital Ido-Ekiti, Nigeria;

4 Department of Surgery, Federal Teaching Hospital Ido-Ekiti and Afe Babalola University Ado-Ekiti, Nigeria.

Conflict-of-interest statement: The authors declare that there is no conflict of interest regarding the publication of this paper.

Open-Access: This article is an open-access article which was selected by an in-house editor and fully peer-reviewed by external reviewers. It is distributed in accordance with the Creative Commons Attribution Non Commercial (CC BY-NC 4.0) license, which permits others to distribute, remix, adapt, build upon this work non-commercially, and license their derivative works on different terms, provided the original work is properly cited and the use is non-commercial. See: <http://creativecommons.org/licenses/by-nc/4.0/>

Correspondence to: Oguntoye Oluwatosin Oluwagbenga. MBBS (Ibadan), FWACP(Gastroenterol), Lecturer 1 and Consultant Physician / Gastroenterologist and Hepatologist, Department of Internal Medicine, Federal Teaching Hospital Ido-Ekiti and Afe Babalola University Ado-Ekiti, Ekiti State, Nigeria.

Email: proflast@yahoo.com

Telephone: +2348086638538

Received: February 2, 2020

Revised: April 3, 2020

Accepted: April 8, 2020

Published online: April 21, 2020

ABSTRACT

Ulcerative colitis is a rare condition among Nigerians. We present a 37-year old male Nigerian who presented with recurrent passage of bloody stool of seven years duration. He has been passing watery, mucoid and bloody stool of about 3 to 5 bowel motions per day with each episode lasting for about three to six weeks following which there will be remission that lasts for about 1 to 2 months. There is associated tenesmus, low grade fever and abdominal pain during

each episode. There is weight loss despite intact appetite. No family history of inflammatory bowel disease or colorectal cancer. He does not take alcohol nor smoke cigarette. Clinical examination was not remarkable. On digital rectal examination however, the examining finger was stained with maroon-colored blood, no rectal mass was felt. Other systems were essentially normal. Provisional diagnosis was suspected Ulcerative colitis to rule out Crohn's disease and to rule out Colorectal cancer. Colonoscopy revealed circumferential mucosa inflammation with multiple areas of erosion and presence of numerous mucosal debris extending from the rectum to involve the sigmoid colon, descending colon, transverse colon and the ascending colon. No diverticula, no polyps or masses seen. Endoscopic features indicate Extensive Ulcerative Colitis (Proctitis with Pancolitis). Histologic sections show features consistent with Ulcerative Colitis. Upper GI Endoscopy revealed essentially normal findings. He was commenced on long-term Amino-salicylate (Mesalamine), antioxidants and a short course of antibiotics (Ofloxacin and Metronidazole). He presented at our clinic three months later with complete resolution of all the symptoms and was scheduled for regular clinic follow-up. Although ulcerative colitis is uncommon among Nigerians, a high index of suspicion with colonoscopy work-up will help to make the diagnosis.

Key words: Ulcerative Colitis; Colonoscopy; Nigerians

© 2020 The Authors. Published by ACT Publishing Group Ltd. All rights reserved.

Oguntoye OO, Yusuf M, Olowoyo P, Erinomo O, Omoseebi O, Soje MO, Oguntoye OA, Fatudimu O. Ulcerative Colitis in A Nigerian - A Case Report. *Journal of Gastroenterology and Hepatology Research* 2020; 9(2): 3146-3149 Available from: URL: <http://www.ghrnet.org/index.php/joghr/article/view/2869>

INTRODUCTION

Ulcerative colitis is one of the two major types of inflammatory bowel disease, along with Crohn's disease^[1]. Unlike Crohn's disease, which can affect any part of the gastrointestinal tract, ulcerative colitis characteristically involves the large bowel^[1,2]. Ulcerative Colitis is a chronic relapsing disease characterized by diffuse mucosal inflammation that involves the rectum and extends proximally in a symmetrical, circumferential, and uninterrupted pattern to involve

parts or all of the large intestine^[1]. Patients with Ulcerative Colitis predominantly complain of rectal bleeding, frequent stools, mucous discharge from the rectum, tenesmus, lower abdominal pain and a low-grade fever^[1].

Ulcerative colitis is more common in the Western and Northern hemispheres; the incidence is low in Asia and the Far East^[2]. In the United States adult population (18years and above), the overall prevalence of Inflammatory bowel disease was 478.4 per 100,000 people in 2016; the prevalence rates of Ulcerative Colitis and Crohn's Disease were 181.1 per 100,000 people and 197.7 per 100,000 people respectively^[3]. Ulcerative colitis is reportedly rare in Black Africans^[4,5] and indeed Nigerians^[6,7,8] compared to Western populations^[9,10,11]. There is no national data on the prevalence of Ulcerative Colitis in Nigeria; only few reports are available, mainly as case reports and case series^[12,13,14,15].

We report a case of Ulcerative Colitis which was histologically confirmed following a colonoscopy.

CASE PRESENTATION

We present Mr S.A. a 37 year old Nigerian of the Yoruba tribe who presented at our Gastroenterology clinic with recurrent passage of bloody stool of seven years duration. He was apparently well until about seven years ago when he started having intermittent passage of watery, mucoid and bloody stool of about 3 to 5 bowel motions per day with each episode lasting for about three to six weeks following which there will be remission that lasts for about 1 to 2 months. There is associated low grade fever and generalized abdominal pain during each episode; pain is minimally relieved following a bowel motion. There is associated history of tenesmus. No history of constipation alternating with the diarrhea. No history of abdominal swelling, no anal protrusion or perianal ulcers or mouth ulcers and no dyspeptic symptoms. Episodes of bowel motion are not associated with meal intake. Patient has lost some weight since the onset of the illness despite intact appetite. No risk factors for immunosuppression, not a known patient with HIV infection or diabetes mellitus. Not a known patient with systemic hypertension or peptic ulcer disease. Patient had taken different kinds of antibiotics during each episode with no appreciable improvement. No family history of similar illness. No family history of inflammatory bowel disease or colorectal cancer. He does not take alcohol nor smoke cigarette. Review of other systems was not contributory.

Clinical examination revealed a young man, conscious, not pale, anicteric, not cyanosed, not febrile, not dehydrated, no digital clubbing, no significant peripheral lymph node enlargement and no pedal oedema. The Abdomen was full, moved with respiration, no area of tenderness, liver span was 10cm, spleen and kidneys were not palpably enlarged, no ascites and the bowel sounds were normoactive. Digital rectal examination - examining finger was stained with maroon coloured blood, no rectal mass was felt. Other systems were essentially normal. A Provisional diagnosis of suspected Inflammatory bowel disease was made likely Ulcerative colitis to rule out Crohn's disease and to rule out Colorectal cancer.

Investigation results are as follows: HIV screening was negative, FBC - PCV=40%, WBC=5,600 × 10⁶/L (Neutrophils=55%, Lymphocytes=29%, Monocytes=9%, Eosinophils=6%, Basophils=1%), Platelets=373,000 × 10⁶/L. ESR=34mm/hr. FBG=4.4mmol/L and 2HPP=5.6mmol/L. E,U&Cr - Na⁺=129mmol/L, K⁺=3.9mmol/L, Cl⁻=103mmol/L, HCO₃⁻=27mmol/L, Urea=2.0mmol/L, Creatinine=72umol/L.

Colonoscopy revealed circumferential mucosa inflammation with

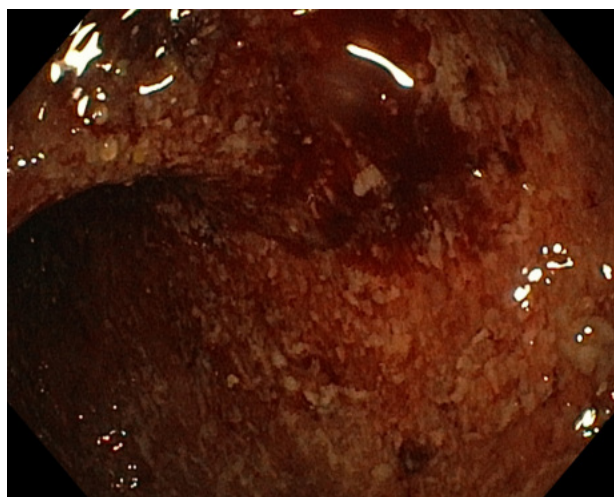


Figure 1 An Endoscopic image of the Rectum.

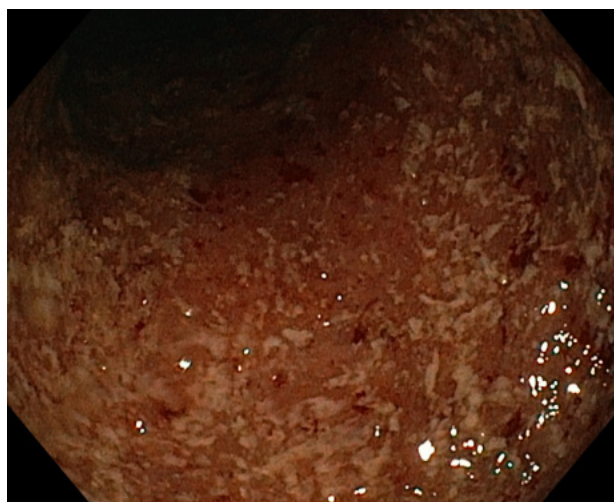


Figure 2 An Endoscopic image of the Sigmoid colon.

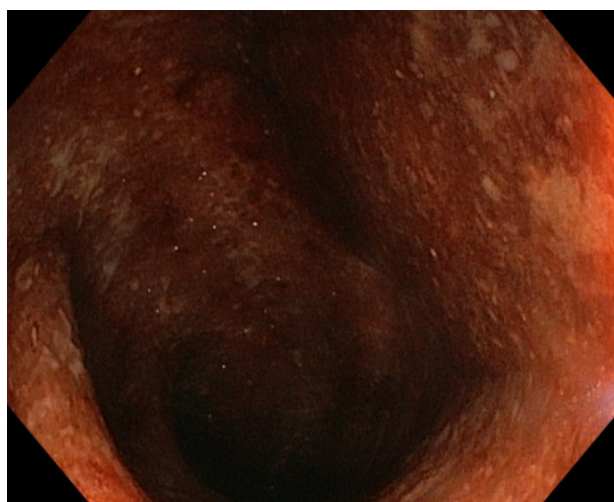


Figure 3 An Endoscopic image of the Descending colon.

multiple areas of erosion and presence of numerous mucosal debris extending from the rectum to involve the sigmoid colon, descending colon, transverse colon and the ascending colon. No diverticula, no polyps or masses seen (Figures 1-5).

Diagnosis: Endoscopic features of an Extensive Ulcerative Colitis (Proctitis with Pancolitis).

Histology

Macroscopy: (1) Ascending colon: Specimen consists of 4 pieces of tiny greyish white tissue all together measuring 0.8cm × 0.5cm; (2) Transverse colon: Specimen consists of 5 pieces of tiny greyish white tissue all together measuring 0.8cm × 0.5cm; (3) Descending colon: Specimen consists of 5 pieces of tiny greyish white tissue all together measuring 0.7cm × 0.5cm; (4) Sigmoid colon: Specimen consists of multiple pieces of tiny greyish white tissue all together measuring 1cm × 0.4cm; (5) Rectum: Specimen consists of 4 pieces of tiny greyish white tissue all together measuring 0.5cm × 0.5cm

Microscopy: Sections from the ascending, transverse, descending, sigmoid colon and rectum are essentially the same. The sections show focal erosions to variable ulcerations, crypts distortion, variable glandular atrophy, focal loss of mucin, glandular destruction, glandular distortion and glandular regeneration. There are neutrophils infiltrating and destroying some of the glands. There are foci of abscesses in the mucosa and submucosa. However, chronic changes are accentuated. The lamina propria shows a dense infiltration by lymphocytes, plasma cells and eosinophils.

Diagnosis: Features strongly indicate Ulcerative Colitis (Figure 6). Upper GI Endoscopy revealed essentially normal findings. No abnormality was detected.

Histology

Macroscopy: (1) Gastric antrum: Specimen consists of 4 pieces of tiny greyish white tissue measuring 0.5cm x 0.5cm; (2) Gastric corpus: Specimen consists of 3 pieces of tiny greyish white tissue measuring 0.5cm x 0.3cm

Microscopy: Gastric antrum: Histologic sections of gastric antral biopsy with intact mucosa. There is infiltration of lamina propria by lymphocytes, plasma cells and few neutrophils. There is mild glandular atrophy, no dysplasia, no intestinal metaplasia and no HLOs seen.

Diagnosis: Chronic non-specific antral gastritis with mild atrophy, no activity, no metaplasia.

Gastric corpus: Histologic sections of gastric corpus show intact mucosa. The lamina propria shows no significant inflammation. There is no glandular atrophy, no dysplasia, no intestinal metaplasia and no HLOs seen.

Diagnosis: No histologic diagnosis,

He was commenced on Tab Mesalamine 800mg three times daily and antioxidants to be taken initially for three months. He was at the same time also commenced on Tabs Ofloxacin and Metronidazole for one week. He presented at our clinic three months later with complete resolution of all the symptoms. He was unwilling to undergo another colonoscopy for follow-up despite adequate counselling. The Tab Mesalamine was reduced to 800mg twice daily and he was scheduled for regular clinic follow-up.

CONCLUSION

Ulcerative Colitis is rare in our environment. It runs a chronic relapsing course and patients usually present with recurrent rectal bleeding, frequent stools, mucous discharge from the rectum, tenesmus, lower abdominal pain and a low-grade fever. The diagnosis of ulcerative colitis is best made with colonoscopy and mucosal biopsy for histopathology. The treatment of ulcerative colitis is mainly medical and includes use of amino-salicylates (such as mesalamine, sulphasalazine), corticosteroids, anti-inflammatory agents, antidiarrheal agents, and rehydration. Surgery is only considered if medical treatment fails or if a surgical emergency

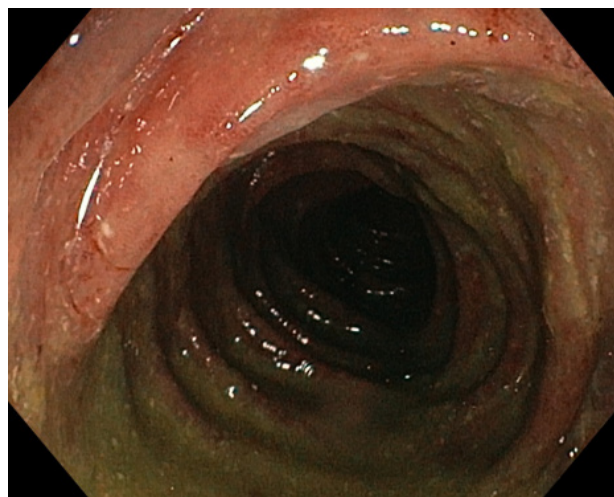


Figure 4 An Endoscopic image of the Transverse colon.

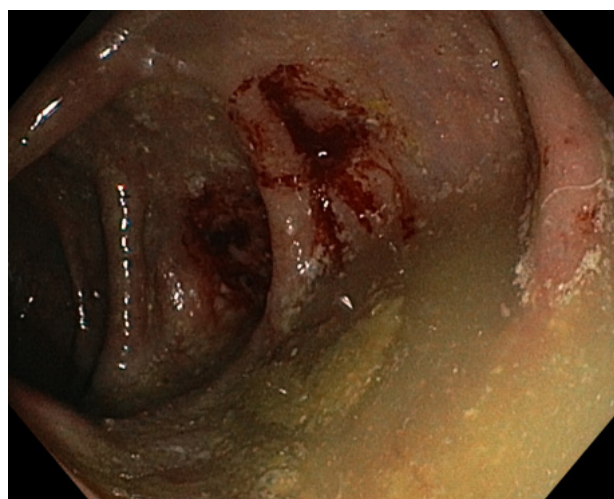


Figure 5 An Endoscopic image of the Ascending colon.

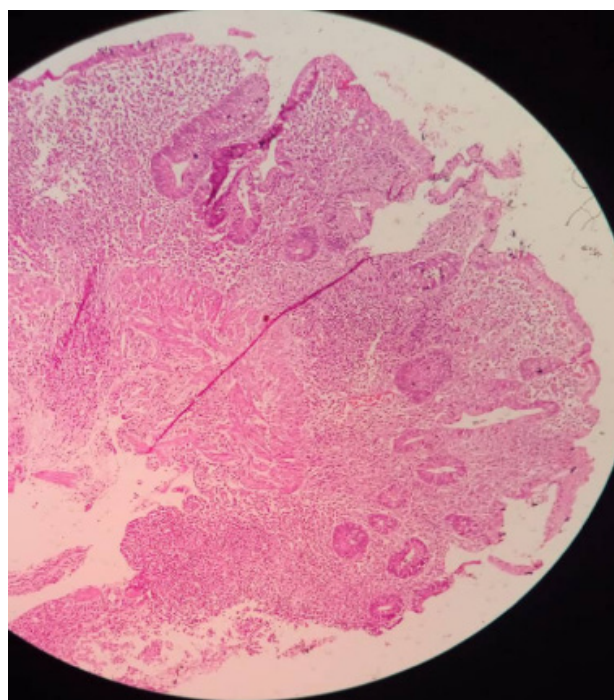


Figure 6 Micrograph of the colon (× 10 magnification) showing features of Ulcerative Colitis.

develops such as toxic megacolon or intestinal perforation. Even though Ulcerative Colitis is uncommon in our environment, it is important for physicians to have a high index of suspicion for this condition particularly in a young individual with recurrence of the characteristic symptoms. Early diagnosis and treatment will prevent complications that could develop if untreated. There is a need to have a national database on Ulcerative Colitis in Nigeria and availability of colonoscopy services across the country to aid early diagnosis of this condition.

ACKNOWLEDGEMENT

Special thanks to the House Officers and Resident Doctors in the Gastroenterology unit of the Department of Internal Medicine for their support in making this publication a reality. The authors did not receive any financial support from any individual, group or organization towards this research work.

REFERENCES

1. Basson MD. Ulcerative Colitis. <https://emedicine.medscape.com/article/183084-overview>. Updated: Jul 26, 2019. Assessed: Feb 25,2020.
2. Dahlhamer JM, Zammit EP, Ward BW, Wheaton AG, Croft JB. Prevalence of Inflammatory Bowel Disease Among Adults Aged ≥18 Years -- United States, 2015. *CDC MMWR* / October 28, 2016 / **65(42)**: 1166-1169. [PMID: 27787492]; [DOI: 10.15585/mmwr.mm6542a3].
3. Ye Y, Manne S, Treem WR, Bennett D. Prevalence of Inflammatory Bowel Disease in Pediatric and Adult Populations: Recent Estimates From Large National Databases in the United States, 2007-2016. *Inflamm Bowel Dis*. 2019 Aug **24**. pii: izz182. [PMID: 31504515]; [DOI: 10.1093/ibd/izz182].
4. Alese OB, Irabor DO. Pyoderma gangrenosum and ulcerative colitis in the tropics. *Rev Soc. Bras. Med. Trop.* 2008; **41**: 6647. [PMID: 19142449]; [DOI: 10.1590/s0037-86822008000600020].
5. Mayberry J, Mann R. Inflammatory bowel disease in Sub Saharan Africa: Rarity of diagnosis in patients attending mission hospitals. *Digestion*. 1989; **144**: 1726. [PMID: 2628138]; [DOI: 10.1159/000199907]
6. Alatise OI, Arigbabu AO, Agbakwuru EA, Lawal OO, Ndububa DA, Ojo OS. Spectrum of colonoscopy findings in Ile-Ife Nigeria. *Niger Postgrad Med J*. 2012; **19(4)**: 219-224. [PMID: 23385677].
7. Ukwenya AY, Ahmed A, Odigie VI, Mohammed A. Inflammatory bowel disease in Nigerians: Still a rare diagnosis? *Ann Afr Med* 2011; **10**: 175-179. [PMID: 21691027]. [DOI: 10.4103/1596-3519.82067].
8. Akere A, Oke TO, Otegbayo JA. Colonoscopy at a tertiary healthcare facility in Southwest Nigeria: Spectrum of indications and colonic abnormalities. *Ann Afr Med*. 2016; **15(3)**: 109-113. [PMID: 27549414]; [PMCID: PMC5402806]; [DOI: 10.4103/1596-3519.188889].
9. Molodecky NA, Soon IS, Rabi DM, Ghali WA, Ferris M, Chernoff G, Benchimol EI, Panaccione R, Ghosh S, Barkema HW, Kaplan GG. Increasing incidence and prevalence of the inflammatory bowel diseases with time, based on systematic review. *Gastroenterology*. 2012; **142**: 46-54. [PMID: 22001864]; [DOI: 10.1053/j.gastro.2011.10.001].
10. Bernstein CN, Wajda A, Svenson LW, MacKenzie A, Koehoorn M, Jackson M, Fedorak R, Israel D, Blanchard JF. The epidemiology of inflammatory bowel disease in Canada: a population-based study. *Am J Gastroenterol*. 2006; **101**: 1559-1568. [PMID: 16863561]; [DOI: 10.1111/j.1572-0241.2006.00603.x].
11. Kaplan GG, Ng SC. Understanding and preventing the global increase of inflammatory bowel disease. *Gastroenterology*. 2017; **152**: 313-321. [PMID: 27793607]; [DOI: 10.1053/j.gastro.2016.10.020].
12. Alatise OI, Otegbayo JA, Nwosu MN, Lawal OO, Ola SO, Anyanwu SN, Ndububa DA, Akere A, Odike MA, Agbakwuru EA, Soyemi OM, Okonkwo UC. Characteristics of inflammatory bowel disease in three tertiary health centers in southern Nigeria. *West Afr J Med*. 2012; **31(1)**: 28-33. [PMID: 23115093].
13. Obaseki DE, Forae GD. Clinicopathological features of inflammatory bowel disease in Benin City, Nigeria. *Int J Adv Med Health Res* 2014; **1**: 16-19. [DOI: 10.4103/2349-4220.134445].
14. Oludara M, Akinola R, Popoola A, Makanjuola S. Inflammatory Bowel Disease, a Rare or Under Diagnosed Disease in Nigeria. *British Journal of Medicine & Medical Research*.2014; **4(35)**: 5620-5628. [DOI: 10.9734/BJMMR/2014/10863].
15. Ekwunife CN, Nweke IG, Achusi IB, Ekwunife CU. Ulcerative colitis prone to delayed diagnosis in a Nigerian Population: Case series. *Ann Med Health Sci Res* 2015; **5**: 311-313. [PMID: 26229722]; [DOI: 10.4103/2141-9248.160188].