

Hepatocellular Carcinoma Arising After Hepatitis B Seroconversion without Cirrhosis, When and How Surveillance is done?

Muhammad Begawan Bestari¹, Ignatius Ronaldi Joewono¹, Ivonne Golda Palungkun², Siti Aminah Abdurachman¹

1 Division of Gastroenterohepatology, Department of Internal Medicine, Hasan Sadikin General Hospital, Faculty of Medicine, Universitas Padjadjaran, Bandung, Indonesia;

2 Santo Boromeus Hospital Bandung, Bandung, Indonesia.

Conflict-of-interest statement: The authors declare that there is no conflict of interest regarding the publication of this paper.

Open-Access: This article is an open-access article which was selected by an in-house editor and fully peer-reviewed by external reviewers. It is distributed in accordance with the Creative Commons Attribution Non Commercial (CC BY-NC 4.0) license, which permits others to distribute, remix, adapt, build upon this work non-commercially, and license their derivative works on different terms, provided the original work is properly cited and the use is non-commercial. See: <http://creativecommons.org/licenses/by-nc/4.0/>

Correspondence to: Muhammad Begawan Bestari, Division of Gastroenterohepatology, Department of Internal Medicine, Hasan Sadikin General Hospital, Faculty of Medicine, Universitas Padjadjaran, Bandung, Indonesia.

Email: begawanb@yahoo.com

Telephone: +62816629795

Received: April 18, 2020

Revised: May 3, 2020

Accepted: May 8, 2020

Published online: June 21, 2020

ABSTRACT

Approximately 18 million people chronically infected with Hepatitis B Virus (HBV) in Indonesia. HBV is a major contributor for the development of hepatocellular carcinoma (HCC). The therapy endpoint for chronic HBV is HBsAg seroclearance or seroconversion. However, in small percentage, HCC can still develop even after seroconversion. This is the first case of such occurrence reported in Indonesia. We report a case of 57-years old male diagnosed with chronic HBV infection 9 years ago by serologic marker and quantitative HBV DNA. The patient was given Entecavir therapy for 6 years and resulted in HBV DNA clearance and HBeAg

seroconversion, however HBsAg persisted at lower levels. The treatment then switched to PegIFN α -2a 180 mg for 1 year, in which resulted in HBsAg seroclearance with normal abdominal ultrasound and hepatic elastography showed no sign of cirrhosis. Three months later, he developed anti-HBsAg and subsequently the patient was loss to follow up. After 2 years the patient showed up with right upper quadrant pain. Abdominal ultrasound and CT scan were performed in which suggestive of HCC confirmed by liver biopsy. Two months after admission the patient experienced esophageal varices ruptured and treated with ligation. With this development of HCC after seroconversion, it is crucial for physicians to establish the surveillance criteria for resolved Hepatitis B patients.

Key words: Hepatocellular Carcinoma; Hepatitis B; Seroconversion; Surveillance

© 2020 The Authors. Published by ACT Publishing Group Ltd. All rights reserved.

Bestari MB, Joewono IR, Palungkun IG, Abdurachman SA. Hepatocellular Carcinoma Arising After Hepatitis B Seroconversion without Cirrhosis, When and How Surveillance is done? *Journal of Gastroenterology and Hepatology Research* 2020; **9(3)**: 3234-3237 Available from: URL: <http://www.ghrnet.org/index.php/joghr/article/view/2873>

INTRODUCTION

Hepatitis infection contributed to 1.34 million deaths in 2015, even higher than HIV based on WHO Global Hepatitis Report 2017^[1]. In Indonesia, approximately 18 million people chronically infected with Hepatitis B Virus (HBV)^[2]. The risk for developing Chronic Hepatitis B (CHB) infection is age dependent, approximately 90% infants become chronically infected and only <5% adults developed chronic HBV infection, with the long-term consequence such as cirrhosis and hepatocellular carcinoma (HCC)^[3,4]. Hepatitis B is a major contributor for the development of hepatocellular carcinoma, approximately 60% of all cases in Asia and Africa^[5].

In patients with Chronic Hepatitis B infection, seroconversion of HBeAg to the development Anti-HBeAg is associated with low HBV-DNA levels and remission of the disease in the majority of the patients. In some uncommon cases the patients also undergo HBsAg

seroclearance or even seroconversion to Anti-HBsAg that can occur in 6.77% after antiviral therapy and even lower spontaneously. However, since HBV can still present at low replicative and transcriptional levels, therefore causing HCC which is the most frequent liver-related complication after HBsAg seroclearance with the rate of 1.86%^[6]. This is the first case of such occurrence reported in Indonesia.

CASE DESCRIPTION

A 57-year old male with abdominal pain on right upper quadrant was diagnosed with HBV 9 years ago by serologic marker HBsAg 3688 IU/mL, HBeAg (+), anti HBeAg (-), HBV DNA 2.57×10^7 IU/mL, AST 560 IU/L, and ALT 440 IU/L. After entecavir therapy for 6 years HBV DNA clearance and HBeAg seroconversion were achieved, however HBsAg persisted at 19.66 IU/mL. The treatment then switched to PegIFN α -2a 180mg for 1 year. The patient reached HBsAg seroclearance at the end of treatment with normal abdominal ultrasound (US) and hepatic elastography of 5.6 kPa. Three months later he developed anti HBsAg 14 mIU/mL. The patient was lost to follow up for 2 years, until current symptoms appeared with serologic markers HBsAg (-), anti HBsAg 121.5 mIU/mL, HBeAg (-), anti HBeAg (+), anti HBcAg (+), HBV DNA (-), anti HCV (-) and AFP 1.93 IU/mL. US suggestive HCC in right lobe and CT scan suggestive of HCC with multiple nodules on both lobes, minimal ascites and portal vein thrombus. Liver biopsy revealed columnar cells arranged in irregular tubular pattern, with nuclear polymorphism, coarse chromatin and presence of mitotic activity (Figures 1-3). Stroma consisted of fibrous collagen bands, with lymphocytes and polymorphonuclear neutrophils. No family history of HCC nor habitual alcohol intake identified. Two months after current admission, the patient experienced hematemesis from ruptured esophageal varices which successfully treated with endoscopic ligation.

DISCUSSION

This is the first case of hepatocellular carcinoma arising from resolved hepatitis B after HBsAg seroconversion and seroclearance reported in Indonesia. This patient has been successfully reached ideal endpoint of therapy using switch strategy of entecavir and Peg-IFN α -2a. HBsAg seroclearance is achieved by the end of therapy with no cirrhosis, and HBsAg seroconversion developed three months afterward. Nevertheless, HCC still developed in this patient in period of two years after HBsAg seroconversion and seroclearance. The risk of Hepatocellular carcinoma (HCC) is 15-20 times greater among HBV-infected individuals compared with the uninfected population.^[7] The chance of developing HCC is significantly lower with patients that has undetectable HBV DNA, HBsAg seroclearance, and HBeAg seroconversion.

However, 1.86% of patients with seroclearance still developed HCC^[8,9]. Covalently closes circular DNA (cccDNA) may still persist intrahepatically, also known as occult hepatitis B infection (OBI). Unfortunately, cccDNA examination was not commercially available and did not performed in this patient. Study of OBI in Indonesia is still limited, because it is not commonly practiced. Most of the study are using only serum HBV DNA, while HBV DNA in the hepatocyte were not measured. Despite the limitations, a study by Thedja, et al. found 8.1% prevalence of OBI in regular blood donors.^[10] The presence of HBV DNA at low replicative and transcriptional level is a risk factor for HCC development, and studies show that HCC is the most frequent complication related to liver after HBsAg seroclearance^[11,12].

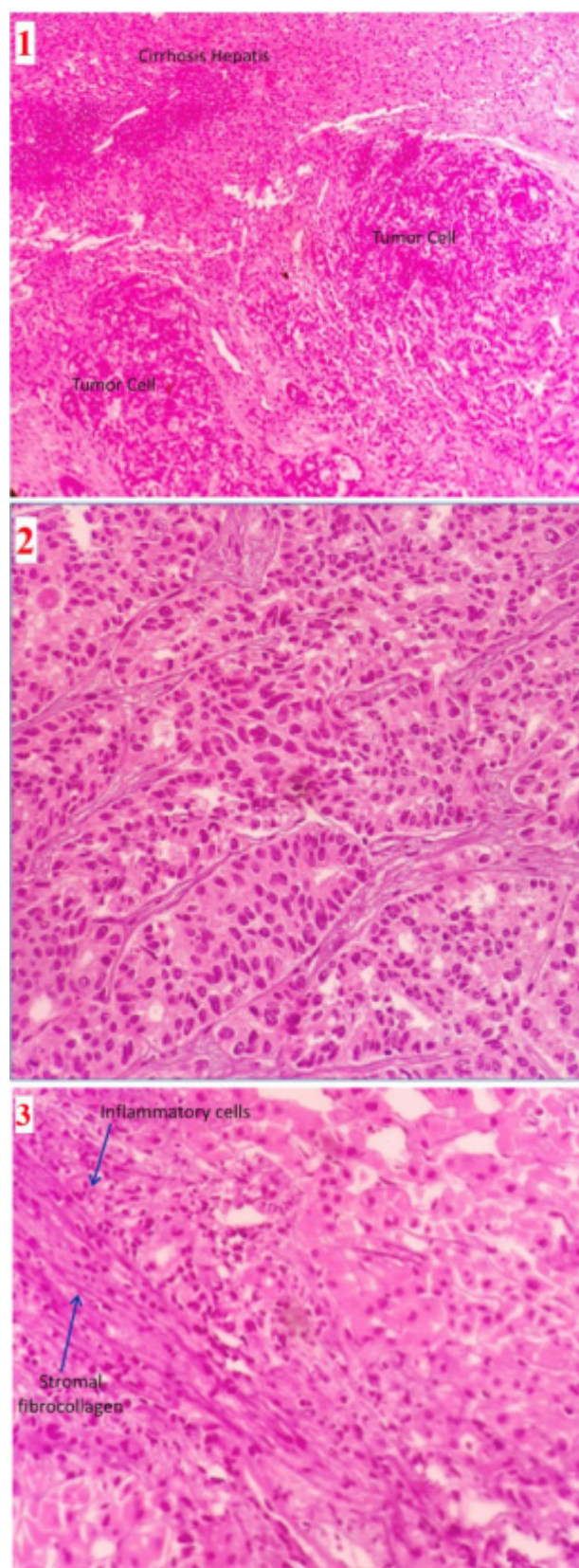


Figure 1-3 Histopathologic examination of the tissue sample. (1) Liver biopsy (low power field/100x) revealed presence of tumor cells and cirrhosis. (2) Tumor cells (High Power Field/ 400x) columnar cells arranged in irregular tubular pattern, with nuclear polymorphism, coarse chromatin, and presence of mitotic activity. (3) Infiltration of inflammatory cells (mononuclear and polymorphonuclear) on fibro collagen septa.

Similar reported cases by Wong *et al*^[13] with same gender and age

group which is ≥ 50 years old, in their case the patient was treated with lamivudine for 3 years which resulted in HBsAg seroconversion and undetectable HBV DNA. However, after 7 years of seroconversion the patient presented with HCC with detectable HBV DNA, which remained undetected in our case. Another case by Shigematsu, *et al*^[14], mentioned the development of HCC after 17 years of seroconversion using steroid therapy, but the patient had liver fibrosis by the time seroconversion occurs. The last similar case that we found was spontaneous seroconversion from HBV and HDV superinfection, yet after 5 years developed HCC with HBsAg remained negative^[15].

This highlights the urgency of surveillance for HCC, even in patient with HBsAg seroclearance. This patient was lost to follow up for two years before diagnosed with HCC. APASL, AASLD and EASL suggesting US examinations with or without AFP for surveillance of HCC every 6 months for high risk group. US result in this patient is suggestive of HCC in the right lobe, but AFP result was 1.93 IU/mL, which is below expected value for suggestive of HCC. AFP sensitivity and specificity are 22.4% and 99.4% at 200 ng/mL (165.28 IU/mL) respectively, while US are 58-89% and $> 90\%$ respectively^[15,16]. Combined examination resulting in higher sensitivity of 63% but lower specificity of 84%^[17]. Despite the high specificity, study by Chan, *et al*^[18] showed AFP has low negative predictive value (NPV) of 27.3% in ruling out HCC in HBV infected patient, which give rise to false negative result that happened in this patient^[16,18]. There are other serologic markers such as Des-gamma-carboxyprothrombin (DCP), also known as prothrombin induced by vitamin K absence-II (PIVKA-II); Lens culinaris agglutinin-reactive fraction of AFP (AFP-L3); Glypican-3 (GPC3) and other proposed tumor markers. Nevertheless, none of these are recommended by EASL, APASL, or AASLD for surveillance of HCC development at the moment.

Justifications regarding follow up are whether risk of HCC sufficient to overcome the cost. In AASLD and APASL guideline, HCC surveillance considered to be cost-effective when annual risk of HCC exceeds 0.2% per year or all patients in cirrhosis condition, yet it remains inconclusive for patients with HBsAg seroclearance like this patient^[7,19]. Meta-analysis study by Kuang *et al*^[6] identified cirrhosis, male gender, and age ≥ 50 years at HBsAg seroclearance are the risk factors, while family history of HCC may also be a risk factor in developing HCC after seroclearance. Therefore, surveillance is deemed necessary for patients with any of these risk factor. We suggest Asian descent to be more susceptible to develop HCC even after seroconversion and seroclearance, since the incidence is higher in Asian race^[6,9]. Further demographic study is required to confirm this statement to narrow down the surveillance criteria.

CONCLUSIONS

This case demonstrated the development of HCC from resolved Hepatitis B with no cirrhosis in a period of 2 years from seroconversion. Currently there is no definitive guideline regarding when to follow up these kind of patient, as early detection of HCC can benefit the patient by reducing morbidity and mortality.

ACKNOWLEDGMENT

We would like to thank the patient for allowing us to share the clinical history.

Statements

This case has been published as abstract on American Journal of Gastroenterology 114(Supplement): S1706, October 2019, the full manuscript has not been submitted/published elsewhere.

Funding

This research did not receive any specific grant from funding agencies in the public, commercial, or not-for-profit sectors.

REFERENCES

1. WHO. Global hepatitis report. 2017(83). [ISBN: 978-92-4-156545-5]
2. National Institute of Health Research and Development Indonesian Ministry of Health (Balitbangkes Kemenkes). Indonesia Basic Health Research; Riskesdas. 2018. [URL: http://labdata.litbang.kemkes.go.id/images/download/laporan/RKD/2018/Laporan_Nasional_RKD2018_FINAL.pdf]
3. Lampertico P, Agarwal K, Berg T, Buti M, Janssen HLA, Papatheodoridis G, Zoulim F, Tacke F. EASL 2017 Clinical Practice Guidelines on the management of hepatitis B virus infection. *J Hepatol*. 2017; **67**(2): 370-98. [PMID: 28427875]; [DOI: 10.1016/j.jhep.2017.03.021]
4. Trépo C, Chan HL, Lok A. Hepatitis B virus infection. *Lancet* 2014; **384**(9959): 2053-63. [PMID: 24954675]; [DOI: 10.1016/S0140-6736(14)60220-8]
5. Galle PR, Forner A, Llovet JM, Mazzaferro V, Piscaglia F, Raoul JL, Schirmacher P, Vilgrain V. EASL Clinical Practice Guidelines: Management of hepatocellular carcinoma. *J Hepatol* 2018; **69**(1): 182-236. [PMID: 29628281]; [DOI: 10.1016/j.jhep.2018.03.019]
6. Kuang XJ, Jia RR, Huo RR, Yu JJ, Wang JJ, Xiang BD, Li LQ, Peng Z, Zhong JH. Systematic review of risk factors of hepatocellular carcinoma after hepatitis B surface antigen seroclearance. *J Viral Hepat*. 2018; **25**(9): 1026-37. [PMID: 29624821]; [DOI: 10.1111/jvh.12905]
7. Omata M, Cheng AL, Kokudo N, Kudo M, Lee JM, Jia J, Tateishi R, Han KH, Chawla YK, Shiina S, Jafri W, Payawal DA, Ohki T, Ogasawara S, Chen PJ, Lesmana CRA, Lesmana LA, Gani RA, Obi S, Dokmeci AK, Sarin SK. Asia-Pacific clinical practice guidelines on the management of hepatocellular carcinoma: a 2017 update. *Hepatol Int*. 2017; **11**(4): 317-70. [PMID: 28620797]; [DOI: 10.1007/s12072-017-9799-9]
8. Arase Y, Suzuki F, Suzuki Y, Saitoh S, Kobayashi M, Akuta N, Someya T, Hosaka T, Sezaki H, Sato J, Kobayashi M, Ikeda K, Kumada H. Long-Term Presence of HBV in the Sera of Chronic Hepatitis B Patients with HBsAg Seroclearance. *Intervirology* 2007; **50**(3): 161-5. [PMID: 17259734]; [DOI: 10.1159/000098958]
9. Yuen MF, Wong DK, Fung J, Ip P, But D, Hung I, Lau K, Yuen JC, Lai CL. HBsAg Seroclearance in chronic hepatitis B in Asian patients: replicative level and risk of hepatocellular carcinoma. *Gastroenterology*. 2008; **135**(4): 1192-9. [PMID: 18722377]; [DOI: 10.1053/j.gastro.2008.07.008]
10. Thedja MD, Roni M, Harahap AR, Siregar NC, Ie SI, Muljono DH. Occult hepatitis B in blood donors in Indonesia: altered antigenicity of the hepatitis B virus surface protein. *Hepatol Int* 2010; **4**(3): 608-14. [PMID: 21063484]; [DOI: 10.1007/s12072-010-9203-5]
11. Gounder PP, Bulkow LR, Snowball M, Negus S, Spradling PR, Simons BC, McMahon BJ. Nested case-control study: hepatocellular carcinoma risk after hepatitis B surface antigen seroclearance. *Aliment Pharmacol Ther* 2016; **43**(11): 1197-207. [PMID: 27061300]; [DOI: 10.1111/apt.13621]
12. Chen YC, Jeng WJ, Chien RN, Chu CM, Liaw YF. Clinical outcomes after spontaneous and nucleos(t)ide analogue-treated HBsAg seroclearance in chronic HBV infection. *Aliment Pharmacol Ther* 2016; **43**(12): 1311-8. [PMID: 27072504]; [DOI: 10.1111/apt.13630]
13. Wong SY, Ren XD, Hann HW. Development of Hepatocellular Carcinoma in Patients with Chronic Hepatitis B Long After Achieving Hbsag Seroconversion: A Need for an Improved Hepatitis B Virus DNA Assay. *Clin Microbiol* 2013; **2**(6). [DOI: 10.4172/2327-5073.1000127]

14. Shigematsu S, Kumagi T, Y.Hiasa, Yoshida T, Hirooka M, Tokumoto Y, Matsuura B, Michitaka K, Horiike N, Tohyama T, Onji M. Development of hepatocellular carcinoma (HCC) in a patient 17 years after recovery from chronic hepatitis B and seroconversion to anti-HBs. *Intern Med* 2007; **46**(1): 29-33. [PMID: 17202730]; [DOI: 10.2169/internalmedicine.46.1586]
15. Escolà-Vergé L, Riveiro-Barciela M, Buti M. A Case Report of Hepatocellular Carcinoma 5 Years After HBsAg Loss in Chronic Hepatitis Delta: How Long Surveillance is Required? *Annals of hepatology*. 2017; **16**(4): 630-2. [PMID: 28611272]; [DOI: 10.5604/01.3001.0010.0314]
16. Trevisani F, D'Intino PE, Morselli-Labate AM, Mazzella G, Accogli E, Caraceni P, Domenicali M, Notariis SD, Roda E, Bernardi M. Serum alpha-fetoprotein for diagnosis of hepatocellular carcinoma in patients with chronic liver disease: influence of HBsAg and anti-HCV status. *J Hepatol* 2001; **34**(4): 570-5. [PMID: 11394657]; [DOI: 10.1016/s0168-8278(00)00053-2]
17. Tzartzeva K, Obi J, Rich NE, Parikh ND, Marrero JA, Yopp A, Waljee AK, Singal AG. Surveillance Imaging and Alpha Fetoprotein for Early Detection of Hepatocellular Carcinoma in Patients With Cirrhosis: A Meta-analysis. *Gastroenterology*. 2018; **154**(6): 1706-18.e1. [PMID: 29425931]; [DOI: 10.1053/j.gastro.2018.01.064]
18. Chan SL, Mo F, Johnson PJ, Siu DY, Chan MH, Lau WY, Lai PB, Lam CW, Yeo W, Yu SC. Performance of serum α -fetoprotein levels in the diagnosis of hepatocellular carcinoma in patients with a hepatic mass. *HPB (Oxford)*. 2014; **16**(4): 366-72. [PMID: 23980880]; [DOI: 10.1111/hpb.12146]
19. Terrault NA, Lok ASF, McMahon BJ, Chang KM, Hwang JP, Jonas MM, Brown RS Jr, Bzowej NH, Wong JB. Update on prevention, diagnosis, and treatment of chronic hepatitis B: AASLD 2018 hepatitis B guidance. *Hepatology*. 2018; **67**(4): 1560-99. [PMID: 29405329]; [DOI: 10.1002/hep.29800]