

A Cross-sectional Case-controlled Study on the Significance of Intestinal Lymphangiectasia Incidentally found in the Duodenum on EGD

Chee K Hui¹, Kit Hui¹

¹ Department of Gastroenterology, Center for Digestive Diseases, Kuala Lumpur, Wilayah Persekutuan, Malaysia.

Conflict-of-interest statement: The authors declare that there is no conflict of interest regarding the publication of this paper.

Open-Access: This article is an open-access article which was selected by an in-house editor and fully peer-reviewed by external reviewers. It is distributed in accordance with the Creative Commons Attribution Non Commercial (CC BY-NC 4.0) license, which permits others to distribute, remix, adapt, build upon this work non-commercially, and license their derivative works on different terms, provided the original work is properly cited and the use is non-commercial. See: <http://creativecommons.org/licenses/by-nc/4.0/>

Correspondence to: Chee K Hui, Department of Gastroenterology, Center for Digestive Diseases, Kuala Lumpur, Wilayah Persekutuan, Malaysia.

Email: chee23hui@gmail.com

Telephone: +60342566798

Received: February 27, 2020

Revised: March 20, 2020

Accepted: March 23, 2020

Published online: April 21, 2020

ABSTRACT

BACKGROUND/AIM: Intestinal lymphangiectasia (IL) is associated with co-existing pathology such as autoimmune diseases or tumors. It can also be incidentally found on esophagogastroduodenoscopy (EGD). However, the clinical significance of this finding is still uncertain. The aim of this study is to determine if those with incidental finding of IL on EGD have a higher risk of co-existing pathology.

METHODS: This is a cross-sectional case-controlled study. A total of 4948 patients underwent EGD.

RESULTS: One-hundred and twenty seven of these 4948 patients (2.6%) had histologically confirmed IL (IL group). Seven hundred and six patients without IL on EGD performed in the same session

as those with IL were recruited as control (Control group). Twenty-two of the 127 patients (17.3%) in the IL group had co-existing pathology when compared with 54 of the 706 patients (7.6%) in the Control group ($p = 0.001$). Patients with co-existing pathology were more likely to have IL in the duodenum [22/76 (28.9%) vs. 105/757 (13.9%), $p = 0.001$], be older in age [median (range) 56 (34-79) years vs. 53 (21-82) years, $p = 0.015$], have a higher serum erythrocyte sedimentation rate [median (range) 19 (3-108) mm/hr vs. 15 (1-96) mm/hr, $p < 0.001$] and to have an elevated serum erythrocyte sedimentation rate [21/76 (27.6%) vs. 56/757 (7.4%), $p < 0.001$] when compared with patients without co-existing pathology. On multiple analyses, IL in the duodenum [$p = 0.036$, Odds Ratio 1.043, 95% confidence interval 0.925-1.175] was an independent factor associated with co-existing pathology.

CONCLUSION: Those with IL are more likely to have co-existing pathology.

Key words: Intestinal lymphangiectasia; Co-existing pathology; Erythrocyte sedimentation rate; Clinical significance; Prevalence

© 2020 The Authors. Published by ACT Publishing Group Ltd. All rights reserved.

Hui CK, Hui K. A Cross-sectional Case-controlled Study on the Significance of Intestinal Lymphangiectasia Incidentally found in the Duodenum on EGD. *Journal of Gastroenterology and Hepatology Research* 2020; **9(2)**: 3128-3133 Available from: URL: <http://www.ghrnet.org/index.php/joghr/article/view/2876>

INTRODUCTION

The prevalence of intestinal lymphangiectasia (IL) has been reported to be as high as 13.3%^[1]. IL can appear as either multiple scattered white spots, diffuse prominent villi with whitish discoloured tips or focal whitish nodule in the duodenum on esophagogastroduodenoscopy (EGD). It can be focal or diffuse, and is caused by dilatation of intestinal lymphatic ducts^[1].

IL can cause protein losing enteropathy, malabsorption and malnutrition^[2,3]. However, IL has also been reported to occur in those without malabsorption^[1]. Furthermore, IL may be a primary or a

secondary disorder, and, can be caused by diseases such as pancreatic tumor, lymphoma, tuberculosis, liver cancer or autoimmune diseases^[2,3,5,6,7].

IL has also been found incidentally in those undergoing routine EGD^[2,8]. One important question facing endoscopists is whether to perform costly thorough investigations in those who were incidentally found to have IL on EGD in order to rule out any possible co-existing pathology associated with the IL.

Therefore, this cross-sectional case-controlled study was conducted to determine the clinical significance in those with incidental finding of IL in the duodenum on EGD.

MATERIALS AND METHODS

Patients

All patients with dyspepsia, heartburn, epigastric pain, right upper quadrant pain, left upper quadrant pain, melena or belching seen at The Centre For Digestive Diseases from February 2009 to May 2019 were included into this study.

Patients with a history of co-existing pathology^[2,3,5,6,7] known to be associated with IL such as solid organ malignancy, haematological malignancy, pancreatic pathology, autoimmune diseases, tuberculosis, liver cirrhosis or chronic rheumatic heart diseases were excluded from the study. Patients with serum creatinine ≥ 160 $\mu\text{mol/L}$ were also excluded from the study as all patients recruited into the study will undergo a computerized tomography of the thorax, abdomen and pelvis (plain and contrast).

EGD

One experienced endoscopist (CKH) performed all the conventional white-light EGD (Olympus, Tokyo, Japan) under conscious sedation with intravenous midazolam and pethidine. All patients were fasted for more than 12 hours before EGD.

Patients with endoscopic appearance suggestive of IL as defined by Kim *et al*^[8] such as (1) multiple scattered white spots, (2) diffuse prominent villi with whitish discoloured tips or (3) focal whitish nodule detected in the first or second part of the duodenum on EGD will have four biopsies taken for histology. All biopsy specimens were interpreted by one experienced histopathologist (K.L.).

All biopsies taken were fixed with 10% formalin solution and embedded in paraffin. The biopsies were then stained with haematoxylin and eosin staining and examined for Giardiasis and *Cryptosporidium* spp. Periodic acid-Schiff staining was also performed to detect Whipple's disease. Patients whose duodenal biopsies showed prominent dilated lymphatic channels as previously described^[3,7,9,10] were confirmed to have IL histologically. Those with histologically confirmed IL were all recruited into the IL group.

All patients undergoing EGD had *helicobacter pylori* checked with both a Rapid Urease Test (CLOtest; Halyard Sales, Alpharetta, Georgia, USA) and histologically for *helicobacter pylori* status by haematoxylin and eosin stains and Giemsa stain from two blind biopsies taken from the antrum as previously described^[11]. *Helicobacter pylori* was identified by its curved-shaped morphology, located on the epithelial cell surface within the gastric pits or in the overlying mucus layer and positive results on Giemsa staining. Patients were considered to be *helicobacter pylori* positive when both the rapid urease test and histology was positive for *helicobacter pylori*^[11].

Control Group

All patients without endoscopic appearance suggestive of IL such

as (1) multiple scattered white spots, (2) diffuse prominent villi with whitish discoloured tips or (3) focal whitish nodule detected in the first or second part of the duodenum on EGD during the same endoscopy session as those with endoscopic features of IL were recruited as the Control group.

Further Investigation on those with IL and Control Group

Every patient in the IL and Control groups had a complete physical examination, complete blood picture, erythrocyte sedimentation rate, liver biochemistry, urea, creatinine, electrolytes, lactate dehydrogenase, anti-nuclear antibody, anti-neutrophilic cytoplasmic antibody, immunoglobulin (Ig) G, IgM, IgA, and a computerized tomography of the thorax, abdomen and pelvis (plain and contrast) performed. Further investigation based on the result of the physical examination and preliminary investigation would be performed as appropriate.

Those found with low serum albumin, serum IgG, serum IgM, serum IgA, ankle edema, radiological ascites or radiological pleural effusion will be investigated for malabsorption.

This study was approved by the Institutional Review Board of the Centre for Digestive Diseases (Protocol approval number CDD09-00002). Written informed consent was obtained from all patients.

The primary outcome of this study was to determine if those with IL will have a higher chance of co-existing pathology such as autoimmune diseases, solid organ malignancy, haematological malignancy, pancreatic diseases, tuberculosis or infection associated with IL^[2,3,5,6,7]. The secondary outcome was to determine the prevalence of IL in our locality and the prevalence of malabsorption in those with IL in the duodenum on EGD.

Statistical Analysis

All statistical analyses were performed using the SPSS software (IBM SPSS Statistics for Windows, Version 20.0, IBM Corp, Armonk, New York, USA). Mann-Whitney *U*-test was used for continuous variables with skewed distribution and chi-square with Yates' correction factor or Fisher's exact test for categorical variables. Continuous variables were expressed as median (range). Variables were analyzed in a univariate analysis in order to determine any factors associated with co-existing pathology. Variables with a *p* value ≤ 0.10 in the univariate analysis were subsequently incorporated into a logistic regression analyses to identify the most important factors for co-existing pathology. All statistics were performed on the intention to treat the population. Statistical significance was defined as *p* < 0.05 (two-tailed).

RESULTS

Study population

A total of 4948 consecutive Chinese patients underwent EGD during the study period (Figure 1).

Three hundred and four of these 4948 patients (6.1%) had multiple scattered white spots, diffuse prominent villi with whitish discoloured tips or focal whitish nodule seen on EGD. One hundred and twenty seven of these 4948 patients (2.6%) had IL on histology. The remaining 177 patients had non-specific duodenitis on biopsy (Figure 1).

Seven hundred and six of these 4948 patients (14.3%) underwent EGD in the same session as these 304 patients with multiple scattered white spots, diffuse prominent villi with whitish discoloured tips or focal whitish nodule seen on EGD. All these 706 patients who did not have multiple scattered white spots, diffuse prominent villi with

Table 1 Demographics in the IL and Control groups. Continuous variables were expressed as median (range).

	IL Group (n = 127)	Control Group (n = 706)	P-value
Age, years	54 (21-69)	53 (22-83)	0.202
Sex, M: F	55:72	335:371	0.222
Helicobacter pylori, n (%)	21 (16.5%)	105 (14.9%)	0.357
Haemoglobin, g/dL	13.3 (6.2-18)	13.8 (8.3-17.3)	0.103
Platelet, X 10 ⁹ /L	248 (116-437)	240 (93-519)	0.609
Total white cell count, X 10 ⁹ /L	6.2 (2.9-14.4)	6.3 (3.0-11.9)	0.815
Erythrocyte sedimentation rate, mm/hr	18 (1-108)	10 (1-96)	0.01
Elevated Erythrocyte sedimentation rate, n (%)	15 (11.7%)	62 (8.9%)	0.178
Albumin, g/L	44 (35-52)	43 (36-52)	0.379
Globulin, g/L	30 (26-42)	30 (27-51)	0.207
Aspartate aminotransaminase, U/L	20 (10-105)	20 (8-409)	0.475
Alanine aminotransaminase, U/L	22 (5-116)	24 (6-236)	0.212
Alkaline phosphatase, U/L	67 (29-307)	71 (18-536)	0.139
Gamma glutamyl transpeptidase, U/L	22 (10-474)	27 (7-1520)	0.215
Serum immunoglobulin G level, kIU/L	12.35 (0.81-21)	13.2 (6.97-34.6)	0.088
Serum immunoglobulin M level, kIU/L	1.06 (0.13-2.73)	1.05 (0.15-3.99)	0.47
Serum immunoglobulin A level, kIU/L	2.48 (0.6-26.8)	2.65 (0.8-12.5)	0.632
Lactate Dehydrogenase, U/L	210 (127-567)	194 (131-499)	< 0.001

whitish discoloured tips or focal whitish nodule detected in the first or second part of the duodenum were recruited as the Control group (Figure 1).

Non-specific duodenitis and IL were the cause for white spots in duodenum

In these 304 patients with endoscopic white spots or patches in the duodenum, the most common cause was non-specific duodenitis [177 of these 304 patients (58.2%)] followed by IL [127 of these 304 patients (41.8%)].

No patients had Whipple’s disease, Celiac disease or Giardiasis on duodenal biopsy.

None of these 4948 patients (0%) developed post-EGD complications.

Baseline characteristics of our cohort

The characteristics of patients in the IL and Control groups are shown in Table 1. Patients in the IL group had a higher erythrocyte sedimentation rate ($p = 0.010$) and a higher serum lactate dehydrogenase level ($p < 0.001$) when compared with the Control group (Table 1).

IL was an independent risk for co-existing pathology

Twenty-two of the 127 patients (17.3%) in the IL Group when compared with 54 of the 706 patients (7.6%) in the Control Group had co-existing pathology ($p = 0.001$).

The co-existing pathology in both groups is listed in Table 2. The most common co-existing pathology in the IL group was autoimmune diseases (63.6%) followed by pancreatic diseases (13.6%) and solid organ malignancy (13.6%). Similarly, the most common co-existing pathology in the Control group was also autoimmune diseases (40.7%) followed by pancreatic diseases (16.7%) and solid organ malignancy (11.1%). There was no significant difference in the type of co-existing pathology between the two groups ($p = 0.913$) (Table 2).

Patients in the co-existing pathology were more likely to have IL in the duodenum ($p = 0.001$), older in age ($p = 0.015$) and a higher serum erythrocyte sedimentation rate ($p < 0.001$) when compared with those without co-existing pathology (Table 3).

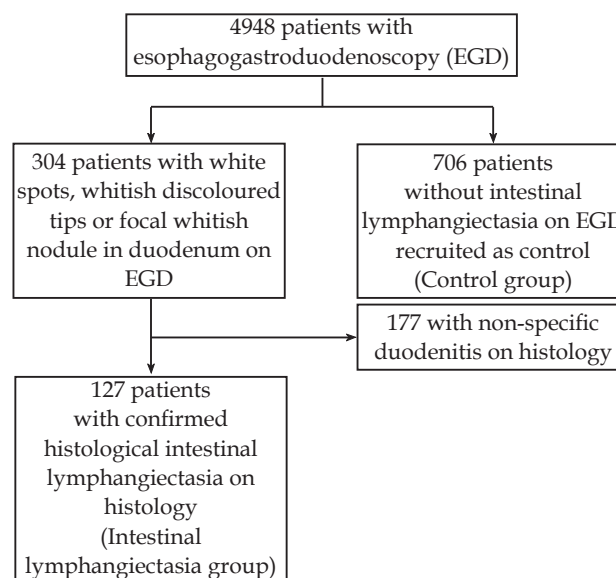


Figure 1 Study population.

Furthermore, those with co-existing pathology were also more likely to have an elevated serum erythrocyte sedimentation rate ($p < 0.001$) and an elevated serum IgA level ($p = 0.003$) (Table 3).

The presence of IL in the duodenum [$p = 0.036$, Odds Ratio (OR) 1.043, 95% confidence interval (CI) 0.925-1.175] was an independent factor associated with co-existing pathology on multiple analyses.

Elevated erythrocyte sedimentation rate was an independent risk factor for co-existing pathology in those with IL

In the 127 patients with IL, those with co-existing pathology had higher serum erythrocyte sedimentation rate ($p=0.005$), a higher serum IgA level ($p = 0.048$) and a higher serum lactate dehydrogenase level ($p = 0.016$) when compared with those without co-existing pathology [Table 4]. Patients with co-existing pathology were also more likely to have an elevated serum erythrocyte sedimentation rate when compared with those without co-existing pathology ($p = 0.005$) (Table 4).

An elevated serum erythrocyte sedimentation rate ($p = 0.010$, OR 1.008, 95%CI 0.892-1.018) was an independent factor associated with co-existing pathology in those with IL on multiple analyses.

Incidental finding of IL in the duodenum was not associated with protein losing enteropathy

None of the 127 patients (0%) in the IL group had either low serum albumin, protein, IgG, IgA or IgM level.

None of the 127 patients in the IL group either ankle edema on clinical examination (0%), pleural effusion (0%) on computerized tomography or ascites (0%) on computerized tomography, diarrhea (0%) or steatorrhea (0%).

Table 2 Co-existing pathology in the IL and Control groups.

	IL Group (n = 22)	Control group (n = 54)	P-value
Autoimmune disease, n (%):	14 (63.6%)	22 (40.7%)	0.913
Systemic lupus erythematosus	7	12	
Psoriasis and psoriatic arthropathy	3	3	
Dermatomyositis	2	0	
Ankylosing spondylitis	1	3	
Mixed connective tissue disease	1	3	
Polyarteritis nodosa	0	1	
Pancreatic disease, n (%):	3 (13.6%)	9 (16.7%)	
Pancreatic cancer	3	9	
Solid organ malignancy, n (%):	3 (13.6%)	6 (11.1%)	
Cancer of colon with peritoneal or liver metastases	2	4	
Ovarian cancer with peritoneal metastases	1	0	
Cancer of lung with liver metastases	0	1	
Metastatic malignant chondroma	0	1	
Hematological malignancy, n (%):	0 (0%)	4 (7.4%)	
Stage III Non-Hodgkin's lymphoma	0	2	
Multiple myeloma	0	2	
Pulmonary tuberculosis, n (%)	2 (9.1%)	7 (13.0%)	
Liver cirrhosis with portal hypertension, n (%)	0 (0%)	3 (5.6%)	
IgG4 disease, n (%)	0 (0%)	2 (3.7%)	
Chronic rheumatic heart disease with atrial fibrillation, n (%)	0 (0%)	1 (1.9%)	

Table 3 Demographic data in patients with and without co-existing pathology. Continuous variables were expressed as median (range).

	Co-existing pathology (n = 76)	No co-existing pathology (n = 757)	P-value
Age, years	56 (34-79)	53 (21-82)	0.015
Sex, M: F	41:35:00	349:408	0.118
Helicobacter pylori, n (%)	11 (14.5%)	115 (15.2%)	0.513
Haemoglobin, g/dL	13.6 (9.0-17.0)	13.8 (6.0-18.0)	0.408
Platelet, X 10 ⁹ /L	246 (93-468)	241 (116-519)	0.946
Total white cell count, X 10 ⁹ /L	6.4 (2.9-11.7)	6.3 (3.0-14.4)	0.62
Erythrocyte sedimentation rate, mm/hr	19 (3-108)	15 (1-96)	<0.001
Elevated Erythrocyte sedimentation rate, n (%)	21 (27.6%)	56 (7.4%)	<0.001
Albumin, g/L	43 (34-52)	43 (30-52)	0.32
Globulin, g/L	31 (22-61)	30 (20-43)	0.53
Aspartate aminotransaminase, U/L	20 (10-94)	20 (8-409)	0.921
Alanine aminotransaminase, U/L	24 (7-133)	22 (5-236)	0.854
Alkaline phosphatase, U/L	73 (32-536)	70 (7-307)	0.285
Gamma glutamyl transpeptidase, U/L	27 (7-438)	27 (7-699)	0.462
Serum immunoglobulin G level, kIU/L	10.4 (2.0-34.6)	12.0 (0.81-21)	0.1
Serum immunoglobulin M level, kIU/L	1.04 (0.22-3.99)	1.06 (0.13-3.21)	0.815
Serum immunoglobulin A level, kIU/L	2.70 (1.2-26.8)	2.57 (0.6-17.0)	0.122
Lactate Dehydrogenase, U/L	197 (127-567)	195 (134-334)	0.22
Elevated immunoglobulin A, n (%)	4 (5.3%)	4 (0.5%)	0.003
Elevated immunoglobulin G, n (%)	6 (7.9%)	10 (1.3%)	0.114
Elevated immunoglobulin M, n (%)	1 (1.3%)	4 (0.5%)	0.381
Elevated serum lactate dehydrogenase, n (%)	3 (3.9%)	37 (4.9%)	0.495
Intestinal lymphangiectasia in duodenum	22 (28.9%)	105 (13.9%)	0.001

DISCUSSION

Histologically confirmed IL was found in 2.6% of our cohort. This is almost similar to the reported 1.4%-3.2% reported in the literature^[7,12,13]. So, it is not unusual for endoscopists to find IL while performing EGD for other symptoms. The important question facing endoscopists is what to do when someone is incidentally found to have IL while undergoing EGD for investigation of other symptoms. Do we investigate further for possible co-existing pathology or do we just observe these patients?

In this study, 17.3% of those with IL had a co-existing pathology. In fact, IL in the duodenum was an independent factor associated with co-existing pathology on multiple analyses. This relatively high percentage of co-existing pathology in those with IL would indicate that those with IL found incidentally on EGD should be thoroughly investigated to rule out co-existing pathology.

In those with IL, a higher serum erythrocyte sedimentation rate, higher serum lactate dehydrogenase, a higher serum IgA levels and an elevated serum erythrocyte sedimentation rate were associated with a higher chance of co-existing pathology. In fact an elevated serum erythrocyte sedimentation rate was an independent risk factor for co-existing pathology. This can be easily explained as 72.7% or those with co-existing pathology were suffering from autoimmune disease or pulmonary tuberculosis (Table 2). These two diseases are usually associated with an elevated serum erythrocyte sedimentation rate.

So it would be prudent for those incidentally found to have IL on EGD to have at least their serum erythrocyte sedimentation rate, lactate dehydrogenase and Ig pattern tested. And, further investigations conducted if either any of these tests were abnormal in order to exclude co-existing pathology that may be the cause of the IL.

However, without imaging, it may be difficult to exclude the presence of solid organ malignancy or pancreatic pathology. As we can observe in this study, 13.6% had pancreatic pathology

and typically pancreatic pathology is difficult to detect without a computerized tomography or magnetic resonance imaging of the abdomen.

Furthermore, 13.6% had cancer of colon or cancer of the ovary with peritoneal or liver metastases. Therefore, despite the cost incurred, clinicians may need to consider performing radiological tests on those incidentally found to have IL on EGD in order to exclude pancreatic, peritoneal and liver lesions that may have caused the IL. Or else, 27.2% of those with malignancy might be missed. This will result in a fatal outcome for those afflicted with these co-existing pathologies.

On the other hand, even among adult patients with IL, 82.7% had primary IL as this large group of patients with IL did not have any co-existing pathology. The etiology of IL in those without co-existing pathology is unknown. It has been hypothesized that the formation of IL in those without co-existing pathology may be due to a transient disturbance of fat transport^[14]. However, this may not be the cause in our cohort as all of our patients were fasted for more than 12 hours before EGD.

None of our cohort with primary IL had any clinical or biochemical evidence of malabsorption. In fact, none of the 127 patients with IL (0%) had low serum albumin, low serum protein level, low serum globulin level, low serum immunoglobulin levels, ankle edema on clinical examination, radiological ascites or radiological pleural effusion. This finding is comparable to previous reports in the literature where those with IL did not have malabsorption^[7,12,15,16]. Therefore, developing malabsorption or protein losing enteropathy is not a common occurrence in adults with IL. Those with protein losing enteropathy may represent the severe end of a disease spectrum that is uncommon in adults with IL.

Out of the 304 patients with endoscopic white spots or white patches detected in duodenum, 41.8% was confirmed with histological IL. This is similar to the 44% reported by Tas *et al*^[12], 57% reported by Biyikoglu *et al*^[17] and 59% reported by Kim *et al*^[8].

Table 4 Demographic data in patients with and without co-existing pathology in the IL group. Continuous variables were expressed as median (range).

	IL with co-existing pathology (n = 22)	IL without co-existing pathology (n = 105)	P-value
Age, years	52 (34-83)	49 (21-69)	0.226
Sex, M: F	9:13	46:59:00	0.498
Helicobacter pylori, n (%)	4 (18.2%)	17 (16.2%)	0.515
Haemoglobin, g/dL	13.0 (9.6-16.9)	13.4 (6.2-18.0)	0.928
Platelet, X 10 ⁹ /L	251 (162-398)	243 (116-437)	0.724
Total white cell count, X 10 ⁹ /L	6.0 (2.9-9.1)	6.2 (3.5-14.4)	0.27
Erythrocyte sedimentation rate, mm/hr	21 (3-69)	8 (1-96)	0.005
Elevated Erythrocyte sedimentation rate, n (%)	7 (31.8%)	8 (7.6%)	0.005
Albumin, g/L	44 (37-48)	44 (35-52)	0.453
Globulin, g/L	30 (26-38)	30 (26-42)	0.69
Aspartate aminotransaminase, U/L	21 (12-57)	19 (10-41)	0.625
Alanine aminotransaminase, U/L	25 (9-65)	17 (5-116)	0.171
Alkaline phosphatase, U/L	70 (37-119)	65 (29-307)	0.949
Gamma glutamyl transpeptidase, U/L	28 (14-149)	22 (10-474)	0.989
Serum immunoglobulin G level, kIU/L	11.3 (8.1-18.5)	12.5 (0.8-21.0)	0.698
Serum immunoglobulin M level, kIU/L	1.04 (0.2-1.88)	1.06 (0.13-2.73)	0.705
Serum immunoglobulin A level, kIU/L	2.91 (1.15-26.80)	2.45 (0.63-17.00)	0.048
Lactate Dehydrogenase, U/L	219 (127-567)	198 (137-334)	0.016
Elevated immunoglobulin A, n (%)	1 (4.5%)	2 (1.9%)	0.438
Elevated immunoglobulin G, n (%)	1 (4.5%)	3 (2.9%)	0.487
Elevated immunoglobulin M, n (%)	0 (0%)	2 (1.9%)	0.682
Elevated serum lactate dehydrogenase, n (%)	3 (13.6%)	28 (26.7%)	0.153

In this study, non-specific duodenitis and IL were the two causes of white spots or white patches in the duodenum. This is similar to the findings reported by Tas *et al*^[12]. However, unlike the study by Biyikoglu *et al*^[17], none of the patients with white spots or white patches in the duodenum in this cohort had Celiac disease or Giardiasis. This study also failed to show an association between *helicobacter pylori* infection and IL as previously reported^[12].

This study has a few limitations. Firstly, IL can appear as multiple small white spots, diffuse whitening of villi and nodular focal lesions. This study did not seek to determine which of these appearances are associated with a higher risk of co-existing pathology. Secondly, we did not perform quantitative evaluation of alfa-1 antitrypsin in the stool to assess for the presence of protein losing enteropathy or malabsorption. However, since none of the subjects in our cohort had symptoms or signs suggestive of malabsorption, low serum albumin or protein, or low serum immunoglobulin levels, it is unlikely that a case or cases of protein losing enteropathy were missed. Finally, the prevalence of histological IL may have been underestimated since only four biopsies were taken. In order to minimize the effect of this possible bias on the study, those with endoscopic appearance of IL but was not confirmed to have IL histologically were excluded from the Control group (Figure 1).

In conclusion, those with IL are more likely to have a co-existing pathology. This group of patients necessitates a thorough investigation in order to ensure that a co-existing pathology can be diagnosed and appropriate treatment is initiated as soon as possible. This sense of urgency is increased in those with IL who have an elevated serum erythrocyte sedimentation rate as this is an independent risk factor associated with co-existing pathology in those with IL.

REFERENCES

- Bellutti M, Monkemuller K, Fry LC, Dombrowski F, Malfertheiner P. Characterization of yellow plaques found in the small bowel during double-balloon enteroscopy. *Endoscopy* 2007; **39** (12): 1059-1063. [DOI: 10.1055/s-2007-966824]; [PMID: 18072056].
- Alshiko MJ, Talas JM, Noureldine SI, Zazou S, Addas A, Kurabi H, Nasser M. Intestinal lymphangiectasia: insights on management and literature review. *Am J Case Rep* 2016; **17** (21): 512-522. [DOI: 10.12659/ajcr.899636]; [PMID: 27440277].
- Wong WM, Hui CK, Yuen MF, Lai CL, Ng IO, Trendell-Smith N, Ooi GC, Fan ST. Reversal of protein-losing enteropathy by liver transplantation. *J Clin Gastroenterol* 2003; **36** (1): 86-87. [DOI: 10.1097/00004836-200301000-00030]; [PMID: 12488724].
- Wen J, Tang Q, Wu J, Wang Y, Cai W. Primary intestinal lymphangiectasia : four case reports and a review of the literature. *Dig Dis Sci* 2010; **55** (12): 3466-3472. [DOI: 10.1007/s10620-010-1161-1]; [PMID: 20198428]
- Mari J, Kovacs T, Pasztor G, Tiszlavicz, L, Bereczki C, Szucs D. Pediatric localized intestinal lymphangiectasia treated with resection. *Int Med Case Rep J* 2019; **12** (11): 23-27. [DOI: 10.2147/IMCRJ.S192940]; [PMID: 30804688]
- Tominaga K, Tsuchiya A, Kawata Y, Yokoyama J, Terai S. Novel magnified single-balloon enteroscopy enables observation of jejunal white spots associated with lymphangiectasia. *Dig Dis Sci* 2019; **37** (2): 170-174. [DOI: 10.1159/000493578]; [PMID: 30466073]
- Hui CK. Intestinal lymphangiectasia associated with recurrence of histiocytosis X. *Singapore Med J* 2011; **52** (10): e177-179. [DOI: 10.1159/000493578]; [PMID: 21947159]
- Kim JH, Bak YT, Kim JS, Seol SY, Shin BK, Kim HK. Clinical significance of duodenal lymphangiectasia incidentally found during routing upper gastrointestinal endoscopy. *Endoscopy* 2009; **41** (6): 510-515. [DOI: 10.1055/s-0029-1214611]; [PMID: 19533556]
- Freeman HJ, Nimmo M. Intestinal lymphangiectasia in adults. *World J Gastrointest Oncol* 2011; **3** (2): 19-23. [DOI: 10.1159/000493578]; [PMID: 21364842]
- Freeman HJ. Small intestinal mucosal biopsy for investigation of diarrhea and malabsorption in adults. *Gastrointest Endosc Clin N Am* 2000; **10**: 739-753. [DOI: 10.4251/wjgo.v3.i2.19]; [PMID: 30466073]
- Wong WM, Gu O, Chu KM, Yee YK, Fung FM, Tong TS, Chan AO, Lai KC, Chan CK, Wong BC. Lansoprazole, levofloxacin and amoxicillin triple therapy vs. quadruple therapy as second line treatment for resistant *Helicobacter pylori* infection. *Aliment Pharmacol Ther* 2006; **23** (3): 421-427. [DOI: 10.1111/j.1365-2036.2006.02764.x]; [PMID: 16423001]
- Tas A, Koklu S, Beyazit Y, Akbal E, Kocak E, Celik H, Biyikoglu I. The endoscopic course of scattered white spots in the descending duodenum: a prospective study. *Gastroenterol Hepatol* 2012; **35** (2): 57-64. [DOI: 10.1016/j.gastrohep.2011.11.010]; [PMID: 22260755]
- Ohmiya N, Nakamura M, Yamamura T, Yamada K, Nagura A, Yoshimura T, Hirooka Y, Hirata I, Goto H. Classification of intestinal lymphangiectasia with protein-losing enteropathy: white villi and non-white villi type. *Digestion* 2014; **90** (3): 155-166. [DOI: 10.1159/000365987]; [PMID: 25278259]
- Femppel J, Lux G, Kaduk B, Roesch W. Functional lymphangiectasia of the duodenal mucosa. *Endoscopy* 1978; **10** (1): 44-46. [DOI: 10.1055/s-0028-1098260]; [PMID: 631094]
- Patel AS, DeRidder PH. Endoscopic appearance and significance of functional lymphangiectasia of the duodenal mucosa. *Gastrointest Endosc* 1990; **36** (4): 376-378. [DOI: 10.1016/s0016-5107(90)71068-1]; [PMID: 2210279]
- Barnes RE, DeRidder PH. Fat absorption in patients with functional intestinal lymphangiectasia and lymphangiectic cysts. *Am J Gastroenterol* 1993; **88** (6): 887-890. [PMID: 8503385]
- Biyikoglu I, Babali A, Cakal B, Köklü S, Filik L, Astarci MH, Ustün H, Ustündağ Y, Akbal E. Do scattered white spots in the duodenum mark a specific gastrointestinal pathology? *J Dig Dis* 2009; **10** (4): 300-304. [DOI: 10.1111/j.1751-2980.2009.00399.x]; [PMID: 19906109]