

Efficacy of Endoscopic Injection Sclerotherapy for Rectal Varices

Takahiro Sato

Takahiro Sato, MD, Department of Gastroenterology, Sapporo Kosei General Hospital, Kita 3 Higashi 8, Chuo-ku, Sapporo 060-0033, Japan

Correspondence to: Takahiro Sato, MD, Department of Gastroenterology, Sapporo Kosei General Hospital, Kita 3 Higashi 8, Chuo-ku, Sapporo 060-0033, Japan. taka.sato@j-hokkaidoukouseiren.or.jp

Telephone: +081-11-261-5331 Fax: +081-11-261-6040

Received: July 3, 2012 Revised: September 23, 2012

Accepted: September 24, 2012

Published online: January 21, 2013

ABSTRACT

AIM: The study's aim was to evaluate the efficacy of endoscopic injection sclerotherapy (EIS) in treating rectal varices.

METHODS: Data from 32 consecutive patients who underwent EIS for rectal varices were analyzed the clinical outcomes, including complications related to EIS. EIS was performed weekly using 5% ethanolamine oleate with iopamidol, which was injected to rectal varices intermittently under fluoroscopy.

RESULTS: In all 32 patients, EIS was performed weekly 2 to 5 times (mean, 2.7), and the total amount of sclerosant ranged from 3.2 to 12.0 mL (mean, 5.3 mL). After EIS, colonoscopy revealed shrinkage of the rectal varices in all 32 patients. There were no serious complications such as portal thrombosis and peritonitis. Colonoscopy revealed oozing bleeding from ulcers after EIS, however, no additional treatments were required. The recurrence rate for rectal varices was 6 of 25 (24.0%) receiving EIS, over a 1-year follow-up period. The recurrence of bleeding was only one patient.

CONCLUSION: EIS is useful and safety treatment for rectal varices with regard to effectiveness and complications.

© 2013 Thomson research. All rights reserved.

Key words: Ectopic varices; Endoscopic injection sclerotherapy; Endoscopic treatment; Portal hypertension; Rectal varices

Sato T. Efficacy of Endoscopic Injection Sclerotherapy for Rectal Varices. *Journal of Gastroenterology and Hepatology Research* 2013; 2(1): 359-361 Available from: URL: <http://www.ghrnet.org/in->

[dex./joghr/](http://www.ghrnet.org/in-)

INTRODUCTION

Esophagogastric varices are considered to be the most common complication in patients with portal hypertension, while ectopic varices, that is, those outside of the esophagogastric region, are less common. Rectal varices represent portal systemic collaterals that are manifested as discrete dilated submucosal veins and constitute a pathway for portal venous flow between the superior rectal veins of the inferior mesenteric system and the middle inferior rectal veins of the iliac system. Rectal varices are a potentially serious cause of hematochezia. Rectal varices have been reported to occur with high frequency in patients with hepatic abnormalities^[1-3]. Massive bleeding from rectal varices occurs rarely, with a frequency ranging from 0.5% to 3.6%^[4-6].

Although endoscopic injection sclerotherapy (EIS) and endoscopic band ligation (EBL) for esophageal varices are well-established therapies, there is no standard treatment for rectal varices. In this article, we retrospectively evaluated the clinical outcomes, including complications related to EIS on rectal varices in patients with portal hypertension.

PATIENTS AND METHODS

Patients

This study retrospectively evaluated 32 consecutive patients with portal hypertension who had undergone EIS for rectal varices in Department of Gastroenterology, Sapporo Kosei Hospital. There were 12 males and 20 females, ranging in age from 38 to 88 years (mean, 68.3 year). Eighteen of the 32 patients had histories of rectal bleeding, and colonoscopy revealed the high risk sign of variceal rupture in the other 14 patients^[7].

The underlying pathologies causing portal hypertension included liver cirrhosis (LC) in 16 patients, cirrhosis associated with hepatocellular carcinoma (HCC) in 8 patients, idiopathic portal hypertension (IPH) in 4 patients, primary biliary cirrhosis (PBC) in 3 patients, and extrahepatic portal vein obstruction (EHO) in 1 patient (Table 1). In terms of the clinical staging of cirrhosis, 15 patients were graded Child-Pugh class A, 16 class B, and 1 class C.

Twenty-nine of 32 patients with portal hypertension had previously received emergency or prophylactic EIS for esophageal varices.

Table 1 Clinicopathological features of patients with rectal varices.

	EIS(n=32)
Gender (male/female)	12/20
Rectal bleeding	18/32 (56.3%)
Child-Pugh classification	
A	15
B	16
C	1
Pathogenesis	
LC	16
LC+HCC	8
IPH	4
PBC	3
EHO	1
Endoscopic findings	
F ₂	28/32 (87.5%)
F ₃	4/32 (12.5%)
RC (+)	32/32 (100%)

LC: liver cirrhosis; HCC: hepatocellular carcinoma; PBC: primary biliary cirrhosis; EHO: extrahepatic portal vein obstruction; IPH: idiopathic portal hypertension; F₂: enlarged tortuous varices; F₃: large, coil-shaped varices; RC: red color sign.

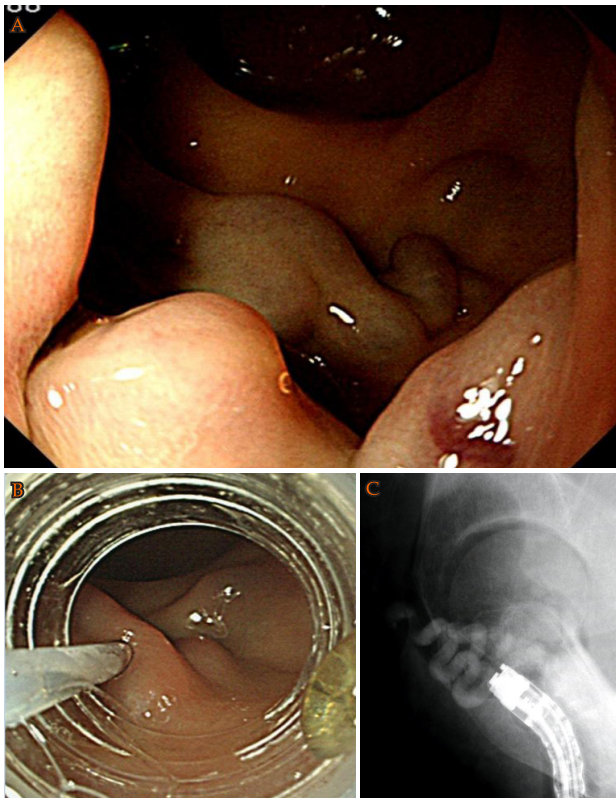


Figure 1 A: Cb F₃, RC-positive rectal varices; B: Endoscopic injection sclerotherapy was performed using a device; C: Fluoroscopic observation with infusion of 5% ethanolamine oleate with iopamidol was performed to determine the extent of the varices.

Endoscopic findings for rectal varices

The endoscopic findings for rectal varices were evaluated according to the grading system outlined in 'The General Rules for Recording Endoscopic Findings of Esophago-gastric Varices' prepared by the Japanese Research Committee on Portal Hypertension^[8]. The form (F) of the varices was classified as small and straight (F1), enlarged and tortuous (F2), large and coil-shaped (F3), or no varices after treatment (F0). The fundamental color of the varices was classified as either white (Cw) or blue (Cb). The red color sign (RC) referred to dilated, small vessels or telangiectasia on the variceal surface. Rectal varices with grades of Cb, F2, and RC-positive were observed in 28

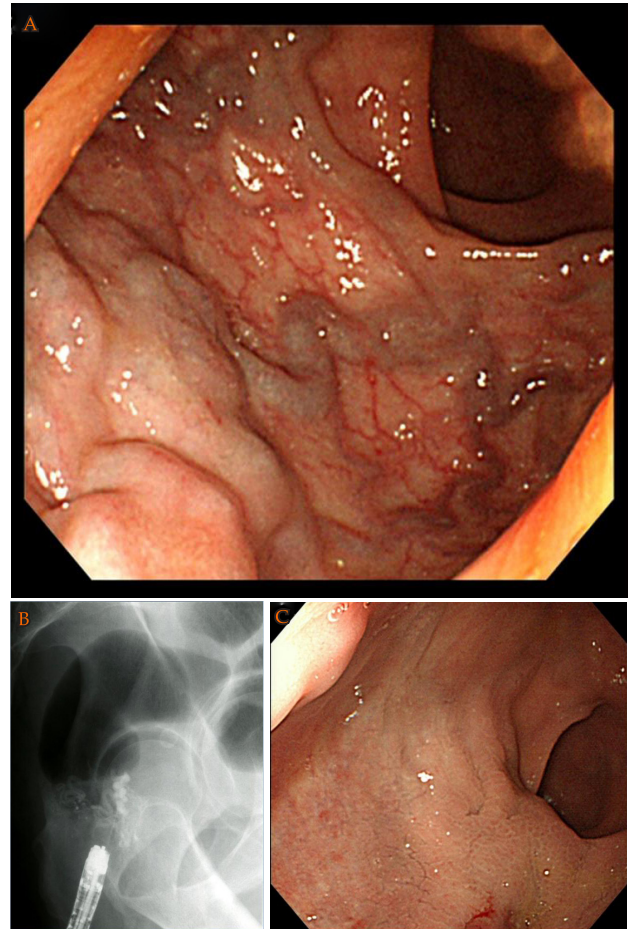


Figure 2 A: Cb F₂, RC-positive rectal varices; B: Fluoroscopic observation during endoscopic injection sclerotherapy; C: After endoscopic injection sclerotherapy, colonoscopy revealed shrinkage of the rectal varices.

of the 32 patients, and grades of Cb, F₃, and RC-positive in the other 4 patients (Table 1).

The study was performed according to the principles of the Declaration of Helsinki. Written informed consent was obtained from all patients prior to the procedure. The study was approved by the ethics committee of Sapporo Kosei Hospital (Sapporo, Japan).

Methods

EIS was performed weekly using 5% ethanolamine oleate with iopamidol (5% EOI), which was injected to rectal varices intermittently under fluoroscopy. Figure 1A shows Cb, F₃, RC positive rectal varices, and EIS was performed under fluoroscopy (Figure 1B). The procedure was performed using a 25-gauge injection needle. The fluoroscopic observation with infusion of 5% EOI was performed to determine the extent of the varices (Figure 1C). We decided the amount of 5% EOI on depiction of passageways (superior rectal vein) of rectal varices.

EIS was repeated every week until the disappearance of all rectal varices was confirmed by endoscopy. We evaluated the therapeutic effects, complications, and recurrence rates after EIS. We defined variceal recurrence as bleeding from rectal varices or possible RC sign. Regarding recurrence rate, the patients received over 1-year follow-up after EIS were enrolled.

RESULTS

EIS was performed weekly from 2 to 5 times (mean, 2.7), and the total amount of sclerosant injected ranged from 3.2 to 12.0 mL (mean,

5.3 mL). After EIS, colonoscopy revealed shrinkage of the rectal varices in all 32 patients. Figure 2A shows Cb, F2, RC positive rectal varices, and EIS was performed under fluoroscopy (Figure 2B). After EIS, colonoscopy revealed shrinkage of the rectal varices (Figure 2C).

The worseness of liver function was not recognized in all 32 patients including one patient of Child-Pugh class C. There was no serious complication such as portal vein thrombosis or infection after EIS. One week later after EIS, colonoscopy revealed oozing type bleeding from ulcers after EIS in 2 patients, however, no additional treatments were required.

Mean follow-up after EIS is 28.9 months (range, 6 to 66 months). The recurrence rate for rectal varices was 6 of 25 (24.0%) receiving EIS, over the 1-year follow-up period. Fourteen months later after treatment, the recurrence of bleeding was only one patient, and additional EIS was successfully performed for this case.

DISCUSSION

Various medical treatments have been used to control bleeding from rectal varices, but none of these is currently considered to be a standard method. Surgical approaches include portosystemic shunting, ligation, and under-running suturing^[1]. Some investigators have reported that interventional radiologic techniques such as transjugular intrahepatic portosystemic shunts were successfully employed for rectal variceal bleeding^[9-11].

Several cases of successful treatment of rectal varices with endoscopic treatments have been reported. Wang *et al*^[12] first reported the usefulness of EIS in treating rectal varices and found it to be effective for controlling bleeding. On the other hand, EBL was introduced as a new method for treating esophageal varices, and it is reportedly both easier to perform and safer than EIS. Several cases of successful treatment of rectal varices using EBL have been reported^[13-15]. Levine *et al*^[13] treated rectal varices initially with EIS, and 1 week later, EBL was performed on the remaining rectal varices. These investigators described EBL as a safe and effective therapy for rectal varices^[15]. EBL may be suitable as an initial treatment for rectal varices, but it appears that the varices can easily recur after EBL^[16, 17].

In this study, we performed EIS in 32 patients, who were successfully treated without serious complications such as portal vein thrombosis or infection. EIS was performed using 5% EOI, which was injected intermittently under fluoroscopy. Fluoroscopic observation with infusion of 5% EOI was performed to determine the extent of the varices, taking care that 5% EOI did not flow into the systemic circulation. It is necessary to evaluate the hemodynamics of the rectal varices before EIS to avoid severe complications such as pulmonary embolism, and the sclerosant should be injected slowly under fluoroscopy.

The recurrence rate for rectal varices was 6 of 25 (24.0%) receiving EIS, over the 1-year follow-up period. We suspected that the high recurrence rate after endoscopic therapies was caused by not using the mucosal-fibrosis method^[18] on the rectum. However, the recurrence of bleeding was only one patient after EIS.

CONCLUSION

EIS appears to be useful and safety with regard to long-term effectiveness and complications following endoscopic treatment of rectal varices in patients with portal hypertension. More investigations are necessary in larger numbers of patients before

evidence-based treatment recommendations can be made.

REFERENCES

- Hosking SW, Smart HL, Johnson AG, Triger DR. Anorectal varices, haemorrhoids, and portal hypertension. *Lancet* 1989; **1**: 349-352
- Wang TF, Lee FY, Tsai YT, Lee SD, Wang SS, Hsia HC, Lin WJ, Lin HC, Lai KH, Chan CY. Relationship of portal pressure, anorectal varices and hemorrhoids in cirrhotic patients. *J Hepatol* 1992; **15**: 170-173
- Chawla Y, Dilawari JB. Anorectal varices—their frequency in cirrhotic and non-cirrhotic portal hypertension. *Gut* 1991; **32**: 309-311
- McCormack TT, Bailey HR, Simms JM, Johnson AG. Rectal varices are not piles. *Br J Surg* 1984; **71**: 1635
- Johansen K, Bardin J, Orloff MJ. Massive bleeding from hemorrhoidal varices in portal hypertension. *JAMA* 1980; **244**: 2084-2085
- Wilson SE, Stone RT, Christie JP, Passaro E. Massive lower gastrointestinal bleeding from intestinal varices. *Arch Surg* 1979; **114**: 1158-1161
- Beppu K, Inokuchi K, Koyanagi N, Nakayama S, Sakata H, Kitano S, Kobayashi M. Prediction of variceal hemorrhage by esophageal endoscopy. *Gastrointest Endosc* 1981; **27**: 213-218
- Idezuki Y. General rules for recording endoscopic findings of esophagogastric varices (1991). Japanese Society for Portal Hypertension. *World J Surg* 1995; **19**: 420-423;
- Katz JA, Rubin RA, Cope C, Holland G, Brass CA. Recurrent bleeding from anorectal varices: successful treatment with a transjugular intrahepatic portosystemic shunt. *Am J Gastroenterol* 1993; **88**: 1104-1107
- Shibata D, Brophy DP, Gordon FD, Anastopoulos HT, Sentovich SM, Bleday R. Transjugular intrahepatic portosystemic shunt for treatment of bleeding ectopic varices with portal hypertension. *Dis Colon Rectum* 1999; **42**: 1581-1585
- Fantin AC, Zala G, Risti B, Debatin JF, Schöpke W, Meyenberger C. Bleeding anorectal varices: successful treatment with transjugular intrahepatic portosystemic shunting (TIPS). *Gut* 1996; **38**: 932-935
- Wang M, Desigan G, Dunn D. Endoscopic sclerotherapy for bleeding rectal varices: a case report. *Am J Gastroenterol* 1985; **80**: 779-780
- Levine J, Tahiri A, Banerjee B. Endoscopic ligation of bleeding rectal varices. *Gastrointest Endosc* 1993; **39**: 188-190
- Firoozi B, Gamagaris Z, Weinshel EH, Bini EJ. Endoscopic band ligation of bleeding rectal varices. *Dig Dis Sci* 2002; **47**: 1502-1505
- Sato T, Yamazaki K, Toyota J, Karino Y, Ohmura T, Suga T. Two cases of rectal varices treated by endoscopic variceal ligation. *Dig Endosc* 1999; **11**: 66-69
- Shudo R, Yazaki Y, Sakurai S, Uenishi H, Yamada H, Sugawara K. Endoscopic variceal ligation of bleeding rectal varices: a case report. *Dig Endosc* 2000; **12**: 366-368
- Sato T, Yamazaki K, Toyota J, Karino Y, Ohmura T, Suga T. The value of the endoscopic therapies in the treatment of rectal varices: a retrospective comparison between injection sclerotherapy and band ligation. *Hep Res* 2006; **34**: 250-255.
- Obara K, Sakamoto H, Kasukawa R. Prevention of recurrence and rebleeding of esophageal varices with a new method of sclerotherapy-EO-AS combination method followed by mucosal fibrosis with AS-. *Dig Endosc* 1990; **2**: 1257-1263

Peer reviewer: Takuto Hikichi, Department of Endoscopy, Fukushima Medical University Hospital, Fukushima, Japan.