

## Factors Associated With Post-Endoscopic Retrograde Cholangiopancreatography Cholangitis in Patients Undergoing Endoscopic Stone Extraction at a Japanese Tertiary Care Center

Gen Maeda<sup>1</sup>, MD; Yasuaki Tagashira<sup>2,3</sup>, MD, PhD; Dai Inoue<sup>1</sup>, MD; Hideyuki Horike<sup>1</sup>, MD; Shin Namiki<sup>1</sup>, MD, PhD

1 Department of Gastroenterology, Tokyo Metropolitan Tama Medical Center, Tokyo, Japan;

2 Division of Infectious Diseases, Tokyo Metropolitan Tama Medical Center, Tokyo, Japan;

3 Department of Microbiology, Juntendo University Graduate School of Medicine, Tokyo, Japan.

**Conflict-of-interest statement:** The authors declare that there is no conflict of interest regarding the publication of this paper.

**Open-Access:** This article is an open-access article which was selected by an in-house editor and fully peer-reviewed by external reviewers. It is distributed in accordance with the Creative Commons Attribution Non Commercial (CC BY-NC 4.0) license, which permits others to distribute, remix, adapt, build upon this work non-commercially, and license their derivative works on different terms, provided the original work is properly cited and the use is non-commercial. See: <http://creativecommons.org/licenses/by-nc/4.0/>

**Correspondence to:** Gen Maeda, MD, Department of Gastroenterology, Tokyo Metropolitan Tama Medical Center, 2-8-29, Musashi-dai, Fuchu, Tokyo, Japan.

Email: [smokewaterthe@gmail.com](mailto:smokewaterthe@gmail.com)

Telephone: +81-42-323-5111

Fax: +81-42-323-9209

Received: May 16, 2020

Revised: May 26, 2020

Accepted: May 28, 2020

Published online: August 21, 2020

### ABSTRACT

**AIM:** Endoscopic retrograde cholangiopancreatography (ERCP) plays an important role in the management of patients with pancreaticobiliary disorders, including cholangitis. Although complications of ERCP can develop even when skilled physicians perform the procedure, there are few studies on the association between endoscopic stone extraction and post-ERCP cholangitis.

**MATERIALS AND METHODS:** The present report is of a retrospective cohort study of patients with choledocholithiasis and

post-ERCP cholangitis. Clinical, microbiological, and procedural data were collected from the patients' electronic medical records. The relationship between each clinical feature and post-ERCP cholangitis was analyzed using univariate and multivariate logistic regression analysis.

**RESULTS:** Of 376 patients with acute cholangitis due to choledocholithiasis, 200 consecutive patients meeting the inclusion criteria were identified. Among these, 23 (11.5%) received the diagnosis of post-ERCP cholangitis. In multivariate analysis, a duration of  $\geq 11$  days from biliary drainage to endoscopic stone extraction (adjusted odds ratio [aOR]: 8.57; 95% confidence interval [CI], 2.68-27.50) and the use of endoscopic papillary balloon dilation (aOR 6.04; 95% CI, 1.88-19.40) were identified as independent risk factors of post-ERCP cholangitis.

**CONCLUSIONS:** The risk of post-ERCP cholangitis can be reduced by performing endoscopic stone extraction as soon as the patient achieves clinical stability after biliary stent insertion and by using endoscopic sphincterotomy instead of endoscopic papillary balloon dilation.

**Key words:** Cholangitis; Endoscopic stone extraction; ERCP

© 2020 The Authors. Published by ACT Publishing Group Ltd. All rights reserved.

Maeda G, Tagashira Y, Inoue D, Horike H, Namiki S. Factors Associated With Post-Endoscopic Retrograde Cholangiopancreatography Cholangitis in Patients Undergoing Endoscopic Stone Extraction at a Japanese Tertiary Care Center. *Journal of Gastroenterology and Hepatology Research* 2020; 9(4): 3255-3260 Available from: URL: <http://www.ghrnet.org/index.php/joghr/article/view/2902>

### INTRODUCTION

The endoscopic retrograde cholangiopancreatography (ERCP) is a well-established procedure for diagnosing and treating pancreaticobiliary disorders, including acute cholangitis, choledocholithiasis, and malignant biliary obstruction. Although ERCP is considered safe, it can cause fatal complications even when performed by skilled physicians<sup>[1,2]</sup>. The incidence of post-ERCP complications differs widely depending on the complexity of the

interventions and the individual patients. Moreover, the incidence of complications in therapeutic ERCP tends to be higher than in diagnostic ERCP<sup>[3]</sup>.

One of the most serious post-ERCP complications is cholangitis, which reportedly occurs in 0.5% to 3% of cases<sup>[4]</sup>. Previous studies indicated that ERCP for malignant hepatobiliary disorder is a risk factor of post-ERCP infection due to the use of combined percutaneous and endoscopic procedures, stent placement in malignant strictures, the presence of jaundice, and incomplete or failed biliary drainage<sup>[4]</sup>.

Common bile duct (CBD) stones are one of the most frequent causes of acute cholangitis, especially among the elderly<sup>[5]</sup>. Primary CBD stones in particular are common in Southeast Asian populations<sup>[6]</sup> and are also the chief cause of biliary obstruction in patients with acute cholangitis in Japan<sup>[7,8]</sup>. However, data on the association between therapeutic ERCP, endoscopic stone extraction, and post-ERCP cholangitis in patients with CBD stones are scarce.

We herein aimed to analyze the risk factors associated with post-ERCP cholangitis in patients undergoing endoscopic stone extraction.

## METHODS AND MATERIALS

### Study design and setting

The present retrospective single-center case control study conducted from January 2014 to December 2017 at Tokyo Metropolitan Tama Medical Center, a public tertiary care center in Tokyo, aimed to evaluate the incidence and risk factors of post-ERCP cholangitis. Our Division of Gastroenterology conducts on average 700 cases of ERCP annually on a 24-hour basis. However, only the initial biliary drainage is performed; emergency endoscopic stone extraction is not performed due to the scarcity of medical staff, especially during the night shift and on weekends and holidays, who are needed to perform this procedure safely. An endoscopic stone extraction is normally performed after the initial biliary drainage when the patients are clinically stable.

### Patient selection

All patients with the diagnosis of acute cholangitis due to CBD stones following a successful endoscopic biliary drainage, antimicrobial therapy, and common bile duct stone removal were enrolled. The exclusion criteria were patients (a) aged < 18 years; (b) with common bile duct stenosis; (c) a history of biliary stenting at another facility; (d) who received no antimicrobials; (e) had a peroral cholangioscopy; (f) and underwent both biliary drainage and endoscopic biliary stone extraction at the same time.

### Data collection

Demographic, clinical, and microbiological data were extracted from the electronic medical records. The Charlson Comorbidity Index (CCI), quick SOFA, and severity grading of acute cholangitis were calculated after reviewing the electronic medical records. The CCI scores were categorized as 0-1, 2-3 or > 3<sup>[9]</sup>. Data on any of the following procedures, etc. during ERCP were also collected: endoscopic nasobiliary drainage (ENBD), endoscopic biliary drainage (EBD), biliary cannulation, endoscopic sphincterotomy (EST), endoscopic papillary balloon dilation (EPBD), endoscopic papillary large balloon dilation (EPLBD), use of devices for stone removal (basket catheter, balloon catheter), duration of cannulation and biliary stenting remaining after stone removal. The ERCP method was determined by each gastroenterologist in accordance with institutional protocol.

### Definition

The diagnostic criteria for acute cholangitis were based on the Tokyo Guidelines 2018 (TG18)<sup>[10]</sup>. Our study included patients with a definitive or suspected diagnosis based on the TG18 diagnostic criteria for CBD stone-related acute cholangitis. The diagnostic criteria for post-ERCP cholangitis had not yet been defined; therefore, in the present study, post-ERCP cholangitis was also defined by the diagnostic criteria of the TG18.

### Outcome

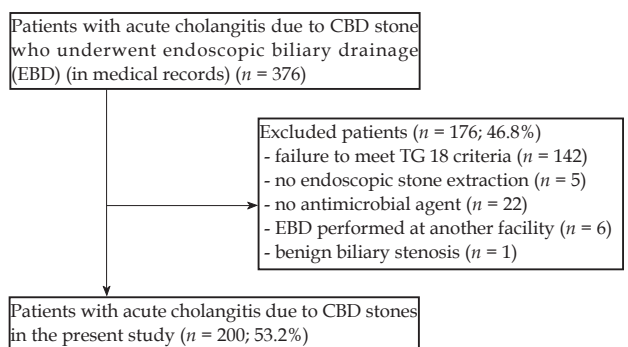
The primary outcome was the incidence of post-ERCP cholangitis due to choledocholithiasis and the risk factors associated with post-ERCP cholangitis.

### Statistical analysis

Categorical variables were compared between patients with and without post-ERCP cholangitis using the  $\chi^2$  test or Fisher's exact test. Continuous variables were compared using the Mann-Whitney U test. All tests for significance were two-tailed, with  $p < 0.05$  considered significant. Multivariate logistic regression was done to predict post-ERCP cholangitis. Predictors of post-ERCP cholangitis in a previous study, including age and past history of ERCP, were included in the multivariate logistic regression model<sup>[2]</sup>. In addition, variables with  $p < 0.10$  on univariate analysis were also assessed for the plausibility of clinical relevancies, then were included in the final model. Backward stepwise regression was used with a cut off value of  $p < 0.05$ . Variables were retained in the final model if  $p < 0.05$ . The Hosmer Lemeshow test was used for goodness of fit for logistic regression. All analyses were performed using SPSS Statistics 25 (IBM, Armonk, NY, USA). This study was approved by the institutional review board of Tokyo Metropolitan Tama Medical Center. The requirement for the patients' written informed consent was waived due to the retrospective nature of the study. The patients were allowed to opt out of participation via our hospital website.

## RESULTS

In total, 376 patients were listed as having acute cholangitis due to CBD stones in our endoscopic database. Among these, 176 (46.8%) did not fulfill the inclusion criteria, leaving 200 (53.2%) patients (121 males, 79 females) for analysis (Figure 1). The details of the patient demographics and characteristics are summarized in Table 1. Of the 200 patients, 23 (11.5%) had the diagnosis of post-ERCP cholangitis. Most of the patients with acute cholangitis received an emergency ERCP on admission day, and 181 patients underwent endoscopic biliary stent placement (90.5%). The median waiting period until



**Figure 1** Description of the study population. Abbreviations: CBD; common bile duct, TG 18; Tokyo Guidelines 2018.

endoscopic stone extraction was ten days (range: 3-368 days). The median time for endoscopic stone extraction was 49 minutes (range: 16-180 minutes). Basket catheters (68/200, 34.0%) and balloon catheters (48/200, 24.0%) were used individually or in combination (84/200, 42.0%). Ninety-three patients (93/200, 46.5%) had EST, and 56 patients (56/200, 28.0%) had EPBD at endoscopic stone extraction

**Table 1** Baseline characteristics of patients with acute cholangitis related-CBD stones.

Characteristics	Total (n = 200)
<b>Demographics</b>	
Age, year, median (range)	77 (26-96)
Male sex	121 (60.5)
BMI, median (range)	23.1 (14.3-33.8)
<b>Comorbidity/past medical history</b>	
Myocardial infarction	18 (5.0)
Congestive heart failure	10 (5.0)
Peripheral vascular disease	4 (2.0)
Dementia	16 (8.0)
Cerebrovascular disease	40 (20.0)
Connective tissue disease	12 (6.0)
Peptic ulcer	9 (4.5)
Hemiplegia	23 (11.5)
Chronic pulmonary disease	11 (5.5)
Chronic kidney disease (Cr > 3 mg/dl)	4 (2.0)
Chronic liver disease	12 (6.0)
Active malignant disease	12 (6.0)
Diabetes mellitus	49 (24.5)
Systemic steroid use (≥ 5 mg) in last 28 days	8 (4.0)
Chemotherapeutic agent use in last 28 days	1 (0.5)
<b>Charlson comorbidity index, median</b>	
Score 0-1	124 (62.0)
Score 2-3	56 (28.0)
Score >3	19 (9.5)
Cholangitis more than 3 months ago	47 (23.5)
Cholelithiasis	51 (25.5)
Post-cholecystectomy	28 (14.0)
Cholecystolithiasis	111 (55.5)
<b>Characteristics at presentation of cholangitis</b>	
Quick SOFA >2	21 (10.5)
<b>Severity of cholangitis (Tokyo Guidelines 2018)</b>	
Grade I	100 (50.0)
Grade II	64 (32.0)
Grade III	36 (18.0)
Complication of bacteremia	82 (41.0)
Time to ERCP, days, median (range)	0 (0-38)
<b>Biliary stent</b>	
EBD tube	181 (90.5)
ENBD	19 (9.5)
Appropriate initial antimicrobial therapy <sup>a</sup>	130 (65.0)
Duration from stent insertion to stabilization, days, median (range)	1 (0-27)
Duration of antimicrobial use, days, median (range)	11 (4-69)

Abbreviations: CBD, common bile duct; BMI, body mass index; SD, standard deviation; SpO<sub>2</sub>, saturation of percutaneous oxygen; ERCP, endoscopic retrograde cholangiopancreatography; EBD, endoscopic biliary drainage; ENBD, endoscopic nasobiliary drainage. <sup>a</sup> Defined as effectiveness against organisms isolated from blood and bile cultures and no administration of antimicrobial agent on admission day. Data are presented as a number (%) unless otherwise specified.

(Table 2).

On univariate analysis, the baseline characteristics and past medical history did not differ significantly between the groups. There was also no significant difference between the groups in terms of jaundice, the severity of cholangitis on admission, procedural time for stone extraction, cannulation time, past history of procedures for papillae, method of cannulation or biliary stent insertion after the procedure (Table 3). The complication as post-ERCP cholangitis was associated with a waiting period ≥ 11 days until stone extraction (adjusted odds ratio (aOR) 8.57; 95 %CI 2.68-27.50) and the use of EPBD (aOR 6.04; 95%CI 1.88-19.40), which differed significantly between the groups on multivariate analysis (Table 4).

## DISCUSSION

The present retrospective study investigated the incidence rate and risk factors of cholangitis after endoscopic stone extraction in patients who underwent antimicrobial therapy and prompt endoscopic drainage for CBD stone cholangitis. The incidence rate of post-ERCP cholangitis was 11.5%, and a duration ≥ 11 days from endoscopic biliary drainage to endoscopic stone extraction and the use of EPBD were independent risk factors of post-ERCP cholangitis.

One of our major findings was that a waiting period longer than ten days for endoscopic stone extraction was an independent risk factor of post-ERCP cholangitis. This waiting period corresponded to the duration of biliary stent placement. The biliary tree is usually a sterile environment. However, biliary stent placement is known to destroy the function of the sphincter of Oddi and to cause duodenal-biliary reflux<sup>[11]</sup>, inducing backflow from the intestinal tract to the bile duct and leading to the introduction of intestinal bacteria into the bile duct. Compromising the function of the sphincter of Oddi eventually contributes to post-ERCP cholangitis. Previous studies have pointed out that longer the waiting period for endoscopic stone extraction, the greater the intestinal bacterial colonization of the common bile duct<sup>[12]</sup>.

The use of EPBD was also found to be an independent risk factor of post-ERCP cholangitis. Using EPBD is recommended as an alternative to EST in stone extraction in patients without any clinical contraindications, such as coagulopathy or altered anatomy<sup>[13]</sup>, because it prevents duodenobiliary reflux and bacterial colonization

**Table 2** Details of ERCP for stone extraction.

Variables	Total (n = 200)
<b>Procedure for papilla</b>	
None	29 (14.5)
EST	93 (46.5)
EPBD	56 (28.0)
EST plus EPLBD	22 (11.0)
<b>Device used to extract stones</b>	
Basket catheter	68 (34.0)
Balloon catheter	48 (24.0)
Basket plus balloon catheter	84 (42.0)
Waiting period until stone extraction, days, median (range)	10 (3-368)
Antibiotics used for stone extraction	116 (58.0)
Duration of stone extraction, minutes, median (range)	49 (16-180)
Duration of cannulation, minutes, median (range)	4 (1-69)

Abbreviations: ERCP, endoscopic retrograde cholangiopancreatography; EBD, endoscopic biliary drainage; EST, endoscopic sphincterotomy; EPBD, endoscopic papillary balloon dilation; EPLBD, endoscopic papillary large balloon dilation. Data are presented as a number (%) unless otherwise specified.

**Table 3** Univariate analysis of post-ERCP cholangitis

Variables	Post-ERCP cholangitis [Yes ( <i>n</i> = 23)]	Post-ERCP cholangitis [No ( <i>n</i> = 177)]	P value
<b>Age</b>			
< 65	1 (4.3)	29 (16.4)	Ref
65-80	11 (47.8)	82 (46.3)	0.87
> 80	11 (47.8)	66 (37.3)	0.34
Male sex	17 (73.9)	104 (58.8)	0.18
<b>BMI</b>			
< 18.5	13 (59.1)	110 (62.1)	Ref
18.5-25	5 (22.7)	48 (27.1)	0.82
> 25	4 (18.2)	19 (10.7)	0.35
<b>Comorbidity/past medical history</b>			
Myocardial infarction	1 (4.3)	17 (9.6)	0.7
Congestive heart failure	2 (8.7)	8 (4.5)	0.32
Peripheral vascular disease	0 (0)	4 (2.3)	N/A
Dementia	1 (4.3)	15 (8.5)	0.7
Cerebrovascular disease	5 (21.7)	35 (19.8)	0.79
Connective tissue disease	1 (4.3)	11 (6.2)	0.59
Peptic ulcer	3 (13.0)	6 (3.4)	0.71
Hemiplegia	2 (8.7)	21 (11.9)	0.87
Chronic pulmonary disease	2 (8.7)	9 (5.1)	0.62
Chronic kidney disease (Cr > 3 mg/dl)	0 (0)	4 (2.3)	N/A
Chronic liver disease	1 (4.3)	11 (6.2)	0.59
Active malignant disease	2 (8.7)	10 (5.6)	0.41
Diabetes mellitus	4 (17.4)	45 (25.4)	0.6
<b>Charlson co-morbidity index</b>			
Score 0-1	15 (65.2)	109 (61.9)	Ref
Score 2-3	6 (26.1)	50 (28.4)	0.81
Score >3	2 (8.7)	17 (9.7)	0.88
Systemic steroid use (≥ 5 mg) in last 28 days	1 (4.3)	7 (4.0)	0.63
Chemotherapeutic agent use in last 28 days	0 (0)	1 (0.6)	N/A
Cholangitis more than 3 months ago	5 (21.7)	42 (23.7)	1
Choledocholithiasis	9 (39.1)	42 (23.7)	0.13
Post-cholecystectomy	5 (21.7)	23 (13.0)	0.33
Cholecystolithiasis	13 (56.5)	98 (55.4)	1
<b>Characteristics at presentation</b>			
Quick SOFA ≥ 2	5 (21.7)	16 (9.0)	0.07
<b>Severity of cholangitis (Tokyo Guidelines 2018)</b>			
Grade I	10 (43.5)	90 (50.8)	Ref
Grade II	6 (26.1)	58 (32.8)	0.51
Grade III	7 (30.4)	29 (16.4)	0.1
Complication of bacteremia	71 (42.3)	11 (52.4)	0.48
Appropriate initial antimicrobial therapy	18 (78.3)	112 (63.3)	0.12
<b>Details of ERCP at stone extraction</b>			
<b>Waiting period until stone extraction (days)</b>			
1-10	4 (17.4)	113 (64.8)	Ref
≥ 11	19 (82.6)	64 (36.2)	<0.001
Antibiotics used for stone extraction <sup>a</sup>	7 (30.4)	109 (177.0)	0.004
Duration of stone extraction >50 min	13 (56.5)	82 (46.9)	0.51
Duration of cannulation >10 min	1 (4.3)	30 (17.1)	0.14
<b>Past history of procedure for papilla</b>			
None	17 (73.9)	130 (73.4)	Ref
EST	5 (21.7)	42 (23.7)	0.82
EPBD	1 (4.3)	2 (1.1)	0.23
EPLBD	0 (0)	3 (1.7)	N/A
Parapapillary diverticulum	13 (56.5)	88 (49.7)	0.61

Method of cannulation			
Stent side	13 (56.5)	122 (68.9)	Ref
Wire guided cannulation	9 (39.1)	49 (27.7)	0.16
Pancreatic dust guide wire method	1 (4.3)	6 (3.4)	0.7
Procedure for papilla at stone extraction			
EST	6 (26.1)	87 (49.2)	Ref
None	2 (8.7)	27 (15.3)	0.93
EPBD	12 (52.2)	44 (24.9)	0.01
EST plus EPLBD	3 (13.0)	19 (10.7)	0.21
Devise to extract stones			
Basket catheter	11 (47.8)	57 (32.2)	Ref
Balloon catheter	2 (8.7)	46 (26.0)	0.07
Basket plus balloon catheter	10 (43.5)	74 (41.8)	0.9
Stenting after the procedure	13 (56.5)	118 (66.7)	0.36

Abbreviations: BMI, body mass index; ERCP, endoscopic retrograde cholangiopancreatography; EST, endoscopic sphincterotomy; EPBD, endoscopic papillary balloon dilation; EPLBD, endoscopic papillary large balloon dilation; Ref, reference; N/A, not applicable. Values are presented as a number (%) unless otherwise specified. <sup>a</sup> The variable, 'Antibiotics used during stone extraction' was not included in multivariate analysis due to strong collinearity with the waiting period until stone extraction ( $r_s = 0.496$ ;  $p < 0.001$ ).

of the common bile duct, which might contribute to CBD stone recurrence<sup>[14]</sup>. However, EPBD has a lower complete stone removal rate than the EST and thus may lead to increased biliary duct pressure due to common bile duct stones remaining from the endoscopic stone extraction<sup>[15]</sup>. Increased biliary duct pressure > 25 mmHg due to papillary edema and small, remaining stones may lead to the development of post-ERCP cholangitis<sup>[16]</sup>. As described above, papillary edema usually occurs after ERCP due to the incomplete dilation of the papilla, intra-mucosal bleeding, and local edema<sup>[17]</sup>. Moreover, papillary edema can induce an increase in bile duct pressure among patients who have undergone an endoscopic stone extraction. This is apparently one reason why post-ERCP cholangitis occurs more frequently in patients with CBD stones than in patients with malignant or benign biliary stenosis, whose common bile duct is usually sterile.

The present study had several limitations. First, it was a retrospective study enrolling a small number of patients with post-ERCP cholangitis at a single Japanese tertiary care center. Second, other, unassessed factors may have contributed to our findings. However, as seen in the Table 1, most of the baseline characteristics of the patients showed no significant difference between groups, suggesting that selection bias had been largely reduced. Third, the results are generalizable only to patients who receive prompt endoscopic biliary drainage, antimicrobial agents, and endoscopic stone extraction at least once after the initial therapy. The generalizability of the findings to patients with CBD stones who received endoscopic stone extraction without acute cholangitis is unknown.

## CONCLUSION

In conclusion, we examined factors associated with post-ERCP cholangitis in patients undergoing endoscopic stone extraction who received endoscopic biliary drainage and antimicrobial agents. Endoscopic stone extraction should be done as soon as possible after endoscopic biliary stent placement. EPBD is not recommended as means in patients with CBD stones. These findings may help to predict which patients are at higher risk of post-ERCP cholangitis.

### Ethical approval

This study was approved by the Ethics Committee of Tokyo Metropolitan Tama Medical Center (No. 29-143).

**Table 4** Multivariate analysis of post-ERCP cholangitis.

Variables	Adjusted OR (95% CI)	P value
Age (years) <sup>a</sup>		
<65	Reference	
65-80	6.37 (0.68-59.68)	0.11
>80	7.78 (0.82-74.02)	0.07
Cholangitis more than 3 months ago <sup>a</sup>	0.72 (0.46-5.45)	0.59
Waiting period until stone extraction (days)		
1-10	Reference	
≥11	8.57 (2.68-27.50)	< 0.001
Procedure for papilla at stone extraction		
EST	Reference	
None	1.08 (0.19-19.40)	0.93
EPBD	6.04 (1.88-19.40)	0.003
EST plus EPLBD	2.17 (0.45-10.60)	0.34

Abbreviations: ERCP, endoscopic retrograde cholangiopancreatography; OR, odds ratio; CI, confidence interval; EST, endoscopic sphincterotomy; EPBD, endoscopic papillary balloon dilation; EPLBD, endoscopic papillary large balloon dilation. <sup>a</sup> Risk factors associated with post-ERCP cholangitis in previous studies; age and past medical history of cholangitis were included in multivariate analysis. The Hosmer-Lemeshow goodness of fit chi-squared test was 9.98 ( $p = 0.27$ ).

## ACKNOWLEDGEMENT

We are indebted to James R. Valera for his assistance in editing the manuscript. Contributions: GM and YT designed the study protocol. GM and HH collected the patient data. GM performed the data analysis. GM and YT drafted the first version of the manuscript. DI performed the critical review. GM and YT revised the manuscript, and all the authors contributed to the final version of manuscript.

## REFERENCES

1. Talukdar R. Complications of ERCP. *Best Practice and Research: Clinical Gastroenterology* 2016; **30(5)**: 793-805. [PMID: 27931637]; [DOI: 10.1016/j.bpg.2016.10.007]
2. Chen M, Wang L, Wang Y, Wei W, Yao YL, Ling TS, et al. Risk factor analysis of post-ERCP cholangitis: A single-center experience. *Hepatobiliary and Pancreatic Diseases International* 2018; **17(1)**: 55-58. [PMID: 29428105]; [DOI: 10.1016/j.hbpd.2018.01.002]

3. Thompson AM, Wright DJ, Murray W, Ritchie GL, Burton HD, Stonebridge PA. Analysis of 153 deaths after upper gastrointestinal endoscopy: Room for improvement? *Surgical Endoscopy and Other Interventional Techniques* 2004; **18(1)**: 22-25. [PMID: 14625742]; [DOI: 10.1007/s00464-003-9069-x]
4. Chandrasekhara V, Khashab MA, Muthusamy VR, Acosta RD, Agrawal D, Bruining DH, et al. Adverse events associated with ERCP. *Gastrointestinal Endoscopy* 2017; **85(1)**: 32-47. [PMID: 27546389]; [DOI: 10.1016/j.gie.2016.06.051]
5. Siegel JH, Kasmin FE. Biliary tract diseases in the elderly: Management and outcomes. *Gut* 1997; **41**: 433-435. [PMID: 9391238]; [PMCID: PMC1891511]; [DOI: 10.1136/gut.41.4.433]
6. Lee D, Ahn YJ, Lee HW, Chung JK, Jung IM. Prevalence and characteristics of clinically significant retained common bile duct stones after laparoscopic cholecystectomy for symptomatic cholelithiasis. *Annals of Surgical Treatment and Research* 2016; **91(5)**: 239-246. [PMID: 27847796]; [PMCID: PMC5107418]; [DOI: 10.4174/ast.2016.91.5.239]
7. Gigot JF, Leese T, Dereme T, Coutinho J, Castaing D, Bismuth H. Acute cholangitis. Multivariate analysis of risk factors. *Annals of Surgery* 1989; **209(4)**: 435-438. [PMID: 2930289]; [PMCID: PMC1493983]; [DOI: 10.1097/0000658-198904000-00008]
8. Kimura Y, Takada T, Strasberg SM, Pitt HA, Gouma DJ, Garden OJ, et al. TG13 current terminology, etiology, and epidemiology of acute cholangitis and cholecystitis. *Journal of Hepato-Biliary-Pancreatic Sciences* 2013; **20(1)**: 8-23. [PMID: 23307004]; [DOI: 10.1007/s00534-012-0564-0]
9. Tagashira Y, Sakamoto N, Isogai T, Hikone M, Kosaka A, Chino R, et al. Impact of inadequate initial antimicrobial therapy on mortality in patients with bacteraemic cholangitis: a retrospective cohort study. *Clinical Microbiology and Infection* 2017; **23(10)**: 740-747. [PMID: 28254686]; [DOI: 10.1016/j.cmi.2017.02.027]
10. Kiriya S, Kozaka K, Takada T, Strasberg SM, Pitt HA, Gabata T, et al. Tokyo Guidelines 2018: diagnostic criteria and severity grading of acute cholangitis. *Journal of Hepato-Biliary-Pancreatic Sciences* 2018; **25(1)**: 17-30. [PMID: 29032610]; [DOI: 10.1002/jhbp.512]
11. Scheithauer BK, Wos-Oxley ML, Ferslev B, Jablonowski H, Pieper DH. Characterization of the complex bacterial communities colonizing biliary stents reveals a host-dependent diversity. *ISME Journal* 2009; **3(7)**: 797-807. [PMID: 19360025]; [DOI: 10.1038/ismej.2009.36]
12. Basioukas P, Vezakis A, Zarkotou O, Fragulidis G, Themeli-Digalaki K, Rizos S, et al. Isolated microorganisms in plastic biliary stents placed for benign and malignant diseases. *Annals of Gastroenterology* 2014; **27(4)**: 399-403. [PMID: 25331687]; [PMCID: PMC4188940]
13. Testoni PA, Mariani A, Aabakken L, Arvanitakis M, Bories E, Costamagna G, et al. Papillary cannulation and sphincterotomy techniques at ERCP: European Society of Gastrointestinal Endoscopy (ESGE) Clinical Guideline. *Endoscopy* 2016; **48**: 657-683. [PMID: 27299638]; [DOI: 10.1055/s-0042-108641]
14. Disario JA, Freeman ML, Bjorkman DJ, MacMathuna P, Petersen BT, Jaffe PE, et al. Endoscopic balloon dilation compared with sphincterotomy for extraction of bile duct stones. *Gastroenterology* 2004; **127(5)**: 1291-1299. [PMID: 15520997]; [DOI: 10.1053/j.gastro.2004.07.017]
15. Zhao HC, He L, Zhou DC, Geng XP, Pan FM. Meta-analysis comparison of endoscopic papillary balloon dilatation and endoscopic sphincterotomy. *World Journal of Gastroenterology* 2013; **19(24)**: 3883-3891. [PMID: 23840129]; [PMCID: PMC3699051]; [DOI: 10.3748/wjg.v19.i24.3883]
16. Chang WH, Chu CH, Wang TE, Chen MJ, Lin CC. Outcome of simple use of mechanical lithotripsy of difficult common bile duct stones. *World Journal of Gastroenterology* 2005; **11(4)**: 593-6. [PMID: 15641153]; [PMCID: PMC4250818]; [DOI: 10.3748/wjg.v11.i4.593]
17. Liao WC, Lee CT, Chang CY, Leung JW, Chen JH, Tsai MC, et al. Randomized trial of 1-minute versus 5-minute endoscopic balloon dilation for extraction of bile duct stones. *Gastrointestinal Endoscopy* 2010; **72(6)**: 1154-1162. [PMID: 20869710]; [DOI: 10.1016/j.gie.2010.07.009]