

## Endoscopic Sphincterotomy With Balloon Dilatation Versus Sphincterotomy Alone For Common Bile Duct Stones Removal

Mostafa R. Elkeleny<sup>1</sup>, Mohamed M. Kandel<sup>2</sup>, Ahmed I. Ellakany<sup>3</sup>, Mohamed H. Sultan<sup>4</sup>, Islam A. El-Sayes<sup>1</sup>

1 General surgery department, Faculty of Medicine, Alexandria University, Egypt;

2 General surgery department, Faculty of Medicine, Port Said University, Egypt;

3 Internal medicine department, Faculty of Medicine, Alexandria University, Egypt;

4 General surgery department, Medical Research Institute, Alexandria University, Egypt.

**Conflict-of-interest statement:** The authors declare that there is no conflict of interest regarding the publication of this paper.

**Open-Access:** This article is an open-access article which was selected by an in-house editor and fully peer-reviewed by external reviewers. It is distributed in accordance with the Creative Commons Attribution Non Commercial (CC BY-NC 4.0) license, which permits others to distribute, remix, adapt, build upon this work non-commercially, and license their derivative works on different terms, provided the original work is properly cited and the use is non-commercial. See: <http://creativecommons.org/licenses/by-nc/4.0/>

**Correspondence to:** Mostafa Refaie Elkeleny M Elkeleny MD, MRCS, Lecturer of General surgery, Faculty of medicine, Alexandria University, 20 Mohamed Saeed Basha, Tharwat, Alexandria, Egypt.

Email: [Mostafa.refaie910@gmail.com](mailto:Mostafa.refaie910@gmail.com)

Telephone: +00201005814622

Received: May 20, 2020

Revised: June 1, 2020

Accepted: June 4, 2020

Published online: June 21, 2020

### ABSTRACT

**INTRODUCTION:** Endoscopic sphincterotomy (EST) is now known as the main endoscopic treatment of stone in common bile duct. However, it is difficult to extract multiple (3 or more) or large ( $\geq 10$ mm) common bile duct stones with EST. EST plus endoscopic large balloon papillary dilation (EPLBD) balloon was identified as a valid treatment option for these bile duct stones.

**AIM OF THIS WORK:** To compare the EST alone versus EST plus EPBD regarding efficacy, feasibility, advantages, and complications.

**METHODS:** Forty patients with large common bile duct stones (CBD) ( $\geq 10$  mm) or multiple stones ( $\geq 3$ ) underwent EST + EPLBD (20 cases) or EST alone (20 cases). We compared the stone removal rates in the first session, procedure times and complications recorded in both groups.

**RESULTS:** The rates of stone extraction were comparable between the both groups (EST plus EPLBD: 95% versus EST: 90%). Regarding the procedure time a shorter procedure time was observed in EST plus EPLBD group (EST + EPLBD: 52 min versus EST: 54 min;  $p = 0.545$ ). Complications like pancreatitis occurred in one case in the EST + EPLBD group and in two cases in the EST group, but without significance difference (EST + EPLBD: 5% vs. EST: 10%).

**CONCLUSIONS:** EST + EPLBD is safe and an effective method for treatment of the patients with either large or multiple CBD stones, as fewer sessions were required, and shorter operative times was observed than EST alone.

**Key words:** Endoscopic sphincterotomy (EST); EST plus endoscopic papillary large-balloon dilation (EPLBD); Post ERCP pancreatitis

© 2020 The Authors. Published by ACT Publishing Group Ltd. All rights reserved.

Elkeleny MR, Kandel MM, Sultan MH, Ellakany AI, El-Sayes I. Endoscopic Sphincterotomy With Balloon Dilatation Versus Sphincterotomy Alone For Common Bile Duct Stones Removal. *Journal of Gastroenterology and Hepatology Research* 2020; 9(3): 3223-3227 Available from: URL: <http://www.ghrnet.org/index.php/joghr/article/view/2924>

### INTRODUCTION

Endoscopic retrograde cholangiopancreatography (ERCP) is commonly used method for extracting common bile duct (CBD) stones and eventually replaced traditional surgery. Endoscopic sphincterotomy (EST), was first introduced in 1974<sup>[1]</sup>. The procedure with 8-12% risk of complications like hemorrhage, perforation<sup>[2]</sup> and long-term drawbacks like sphincter dysfunction.

Endoscopic papillary balloon dilation (EPBD), introduced by Staritz *et al*<sup>[3]</sup>, could bring down the danger of bleeding and perforation, but with higher risk of post-ERCP pancreatitis<sup>[4-6]</sup>. It could also only be used to extract small to moderate sized stones less than 10

mm<sup>[6]</sup>.

Roughly 10-15% of stones could not be extracted by both of the previously mentioned methods, especially difficult stones<sup>[7]</sup> (bigger than 10-15 mm, numerous, barrel-shaped and impacted stones). In addition, difficult access to papilla (periampullary diverticulum or postoperative variation), tortuosity and tightening of the distal common bile duct<sup>[8,9]</sup> increase the failure rate of stone extraction.

Ersoz *et al.*<sup>[10]</sup>, in 2003 suggested an alternation of the EPBD through the combination of large balloon dilation (15-20 mm) with a constrained precut of the papilla. It was designed to reduce the risk of complication by avoiding a complete incision, shortening the time of the procedure, and reducing the need of mechanical lithotripsy<sup>[11]</sup>.

Aim of the work: to compare the EST alone versus EST plus EPBD regarding efficacy, feasibility, advantages, and complications.

## PATIENTS

40 patients were enrolled prospectively (22 females & 18 males), all patients were having common bile duct stones documented by Magnetic Resonance Cholangiopancreatography (MRCP) presented to the GIT surgery unit, Main Alexandria university hospital, Alexandria, Egypt. Signed consent was obtained from all patients. Procedures were approved by both the institutional and the regional ethics committees.

Patients with multiple CBD stones or single large stone more than 10 mm were included. We excluded patients with bleeding tendency (INR > 1.5, thrombocytopenia < 50000/mL, patient on anticoagulation therapy within 3 days of the procedure), acute cholecystitis, acute pancreatitis, cholangitis, intrahepatic duct stones and pancreatobiliary malignancies.

Thorough history and clinical examination done for all patients and laboratory investigations including liver functions and enzymes and pancreatic enzymes performed before and after the procedure. Imaging included abdominal ultrasound and MRCP (Figure 1).

Selected cases were divided into two groups randomly by the closed envelop technique. Group A: Twenty patients underwent (EST) plus (EPBD). Group B: Twenty patients underwent (EST) alone.

### Procedure

Endoscopic Retrograde Cholangio-Pancreatography (ERCP): was achieved with endoscopic side-viewing (Olympus Optical Co.). The electro-surgical unit was adjusted (cut coagulation ratio, 4:1).

Midazolam and meperidine were used for patient sedation. preoperative antibiotics prophylaxis usually used. They sedated patients with a midazolam. They were regularly given antibiotics. After the endoscope was introduced into the second part of duodenum, cymetropium bromide was intravenously administered to reduce peristalsis.

The initial cholangiogram was taken after cannulation of the CBD (Figure 2). If it was not possible to cannulate the CBD, then a precut needle-knife-sphincterotomy was performed to obtain an access (Figure 3).

**In the EST group:** EST was extended to the full length of major duodenal papilla, but not exceeding the major duodenal horizontal fold avoiding crossing the intramural part of the CBD (Figure 4).

**EBS plus EPBD group:** The length of the sphincterotomy was limited to one third the length of sphincterotomy the first group (Minor EBS). The catheter of the balloon (Boston Scientific Microvasive) was passed over a guidewire with a diameter of between 12 and 20 mm. The balloon diameter corresponded to the diameter of the bile duct. The balloon was positioned in front of

the major duodenal papilla, with the balloon's middle portion at the biliary sphincter site (Figure 5). The balloon was then slowly loaded with diluted contrast medium guided by endoscopy and fluoroscopy to see the waist progressively vanishing in the balloon. Once the waist had vanished, which was taken to suggest gradual dilation of the orifice; the balloon remained inflated for 60 seconds and then extraction for stones (Figure 6).

Stones with a basket or extraction balloon were then collected from the bile duct. When the balloon was not big enough to expel the stones, we repeated it in the order of 15, 16.5- or 18-mm larger balloon. Insertion of plastic sent for biliary drainage indicated in some cases.

Stones number and size (Figure 7) were recorded during ERCP, taken during and after visualization of the biliary system on the C-arm screen. The size of the stone was calculated based on the relation between the stone diameter and the endoscope shaft diameter as estimated on the cholangiogram screen.

24 hours after the procedure laboratory tests were obtained included serum amylase and lipase concentrations, complete blood cell count and liver functions to detect possible complications.

ERCP related pancreatitis was characterized as upper abdominal pain, with elevated serum amylase and/or serum lipase 3-fold or more one day after the procedure. Significant Hemorrhage was considered by evidence of melena or hematemesis, decrease in Hb concentration of at least 2 g / dL, or blood transfusion.

## RESULTS

From May 2019 to May 2020, forty patients were included in our study. Twenty patients were included in group A (endoscopic sphincterotomy with balloon dilatation) and the same number in group B (endoscopic sphincterotomy). (1) Sex Group A included 12 female patients (60%) and 8 male patients (40%). while group B included 10 female patients (50%) and 10 male patients (50%). (2) Table 1 illustrate baseline characteristics between both study groups, regarding the age, sex number of stones within the common bile duct, size of stones and pre-endoscopy laboratory investigation. (3) The CBD diameter was ranged from 13 to 22 mm (mean =  $17.25 \pm 2.51$  mm) in group A and from 13 to 22 mm (mean =  $16.85 \pm 2.39$  mm) in group B. (4) Precut sphincterotomy was done in 3 patients in group A (15%) and in 7 patients in group B (34%), which was an insignificant difference as regard pre-cut sphincterotomy ( $p$  value = 0.144). (5) The procedure duration ranged from 40 to 75 minutes (mean =  $52.80 \pm 9.76$  minutes) in group A and from 40 to 80 minutes (mean =  $54.90 \pm 11.86$  minutes), which was an insignificant difference as regard procedure duration ( $p$  value 0.545). (6) Stone extraction in the first session failed in one case in group A (5%) while it occurred in two cases in group B (10%). (7) There was one case of clinically and laboratory pancreatitis in group A while there were two case of pancreatitis in group B. (8) Table 2: Comparing both groups regarding pre-ERCP and post-ERCP data between both study groups. (9) There was insignificant difference as regard hemoglobin levels before ( $p$  value 0.552) and after the procedure ( $p$  value 0.915) in the two groups. (10) In our study perforation was not encountered in any patients of the two groups. (11) We initiated univariable logistic regression to search for predictors of post ERCP pancreatitis. We evaluated all baseline characteristics, stone size, number and duration of the procedure. We could not identify any independent predictors for post ERCP pancreatitis. In addition, type of sphincterotomy was not correlated to the pancreatitis risk.

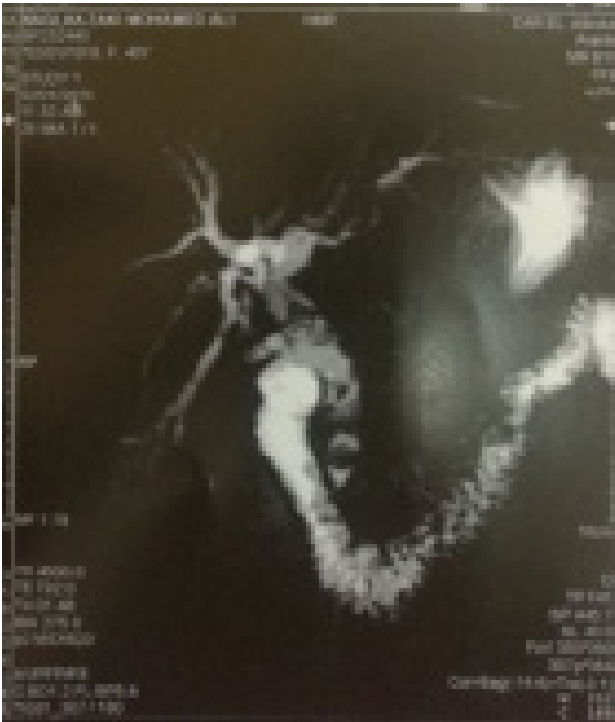

Figure 1 Illustrating dilated intra and extra-hepatic biliary radicles with multiple CBD stones.

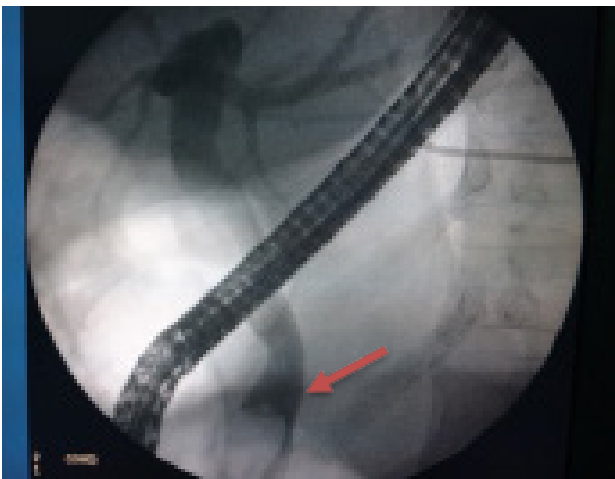


Figure 2 Initial cholangiogram showing large distal CBD stone (arrow).

## DISCUSSION

Treatment of CBD stones over the last decades has undergone various changes. Although there has been much controversy about whether the ampulla should be cut or dilated during ERCP stones extraction, the optimal procedure should have the lowest complication rates with the greatest effectiveness<sup>[2]</sup>.

EBS is the commonest used method for extraction of CBD stones, it has a high success rate exceed 90%. However, EBS carries substantial procedure-related risks, include bleeding, duodenal perforation, and pancreatitis furthermore, the potential sequels of destruction of the biliary sphincter. Loss of sphincter function, may lead to enteric biliary reflux with bacterial colonization and inflammation of the biliary system which leading to cholangitis and stones formation especially in younger patients<sup>[4]</sup>.

Staritz *et al.* developed EPBD (Endoscopic Papillary Balloon Dilatation) in 1983 as an effective procedure for removing bile duct

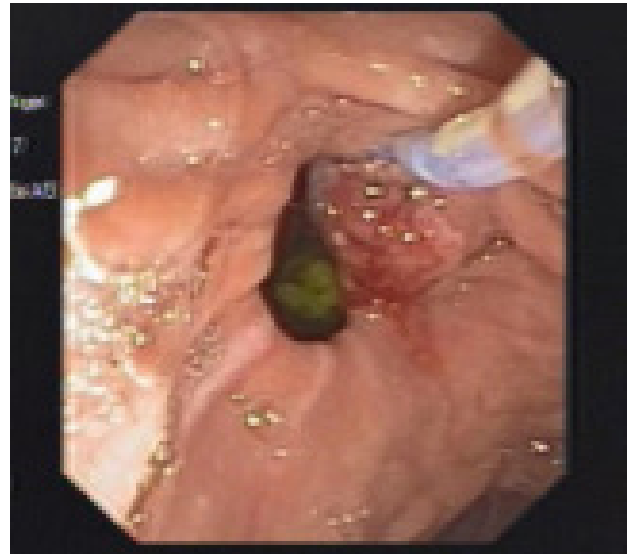


Figure 3 Needle knife precut-sphincterotomy in a duodenal diverticulum.

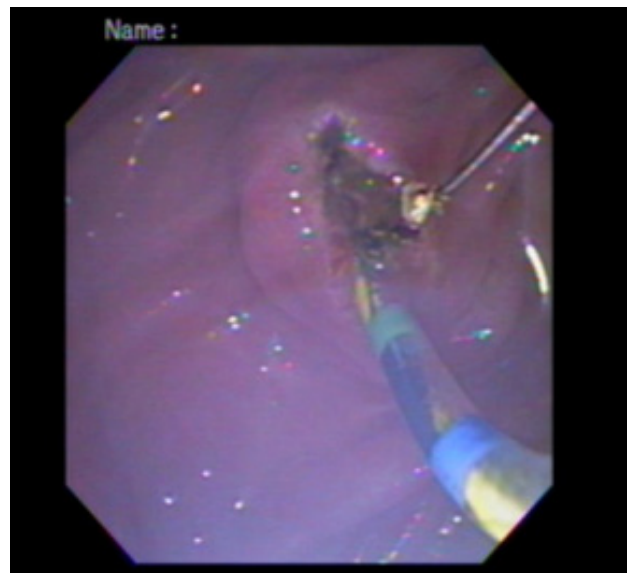


Figure 4 Major Endoscopic biliary sphincterotomy (EBS).

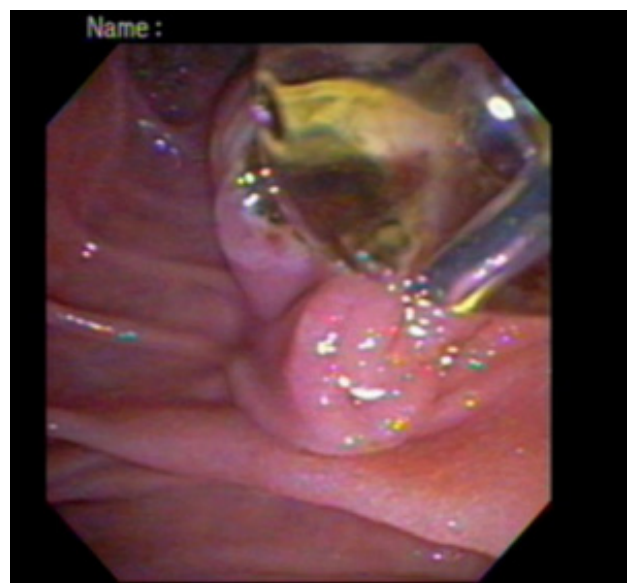

Figure 5 Illustrating sphincterotomy followed by papillary balloon dilatation.

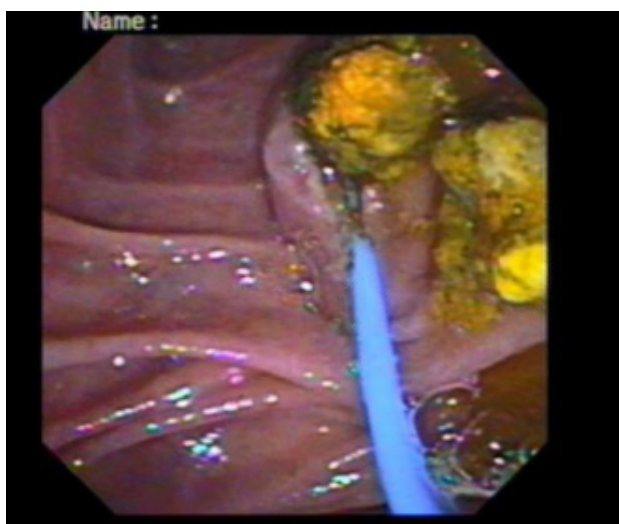


Figure 6 Showing extraction balloon with retrieval of multiple stones.

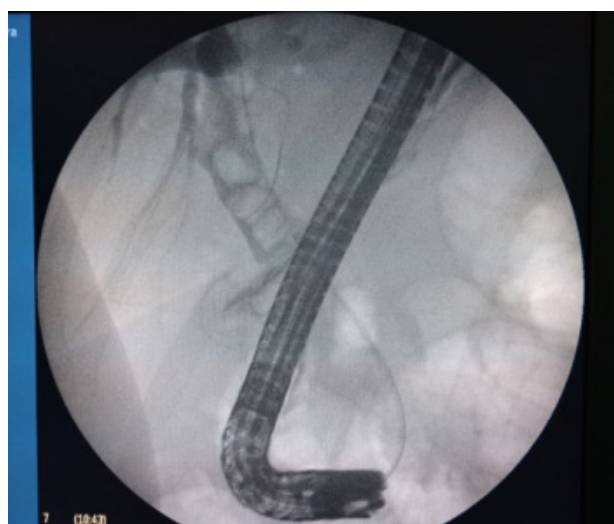

Figure 7 Showing the endoscope with multiple CBD stone 3 stones 1.5 mm.

stones. The key benefit of this strategy is that it does not require cutting the biliary sphincter, thus retaining its function with low risk of bleeding and perforation. However, there are significant drawbacks of EPBD, including difficulties in removing large stones and high incidences of post-ERCP pancreatitis<sup>[5]</sup>.

Balloon dilation does not expand sphincter of Oddi to the same degree as EST therefore, large stone removal with EPBD is difficult and mechanical lithotripsy is more frequently needed than with EST<sup>[6]</sup>. Experimental study results showed mostly that balloon dilation of uninterrupted sphincter is potentially more dangerous than sphincterotomy in inducing pancreatitis. The process most definitely is mechanical squeezing of the pancreatic sphincter as well as the duct by the balloon<sup>[7]</sup>.

The success rate for clearing of CBD stones in our study was 95% in group (A), versus success rate 90% in group (B). The higher number of stones, and the bigger the stones, the more sessions were needed for successful stones extraction. These results are in agreement with many studies. Heo *et al* accomplished a similar rate of success in stone extraction<sup>[1]</sup>. Our results are also in agreement with de Clemente Junior *et al* in their study which showed a comparable efficacy for stone extraction between EPBD and EBS in 202 patients with choledocholithiasis (EPBD 90% vs. EBS 91%, in one endoscopic session, *p* value= 0.81)<sup>[8]</sup>.

The variability in successful stone extraction from other studies could be linked to multiple variables, such as the extent of EBS, stone and balloon size, and stone and CBD shape, we believe that full EBS is the most important independent factor for successful large CBD stone extraction and reducing the need of mechanical lithotripsy<sup>[9]</sup>.

Our study revealed one cases developed post-ERCP pancreatitis (5%) in group (A) (EPBD + EBS) and two cases (10%) in group (B) (EBS). This is in agreement with 2 large-clinical trial studies by Baron and Harewood study and Tsujino<sup>[10]</sup> Kanazawa *et al*<sup>[12]</sup> study indicated that EBS followed by EPBD may have a lower chance of post-ERCP pancreatitis as EBS conducted before EPBD that leading to separation biliary orifice from pancreatic duct, and make the forces of the balloon dilation away from the pancreatic duct<sup>[12]</sup>. It has been indicated in other series that the minimal or mid-incision EBS before balloon dilation can reduce the risk of post-ERCP pancreatitis as it can lead the path of balloon dilation towards the CBD rather than the pancreatic duct<sup>[13]</sup>.

In our present study none of the patients developed bleeding in the two groups (0%). The endoscopic bleeding rates for EBS plus EPBD

Table 1 Comparison of baseline characteristics between both study groups.

	EPBD (n = 20)	EST (n = 20)	P-value
Age (years)	53.0 (47.3-59.8)	58.0 (49.3-61.5)	0.242
Sex M/F	8/12	10/10	0.525
Stone number	2 (1.0-3.0)	3 (2.0-3.0)	0.063
Stone size in mm	12.5 (10.0-15.8)	12.0 (0.9-14.8)	0.478
Periampullary diverticulum	2 (10.0%)	2 (10.0%)	1.0*
<b>Pre-ERCP lab. investigations</b>			
Total bilirubin	7.3 (5.1-9.0)	6.3 (4.6-8.0)	0.445
Direct bilirubin	5.2 (4.1-6.4)	4.5 (3.4-6.5)	0.529
ALP	250.0 (202.5-304.8)	292.5 (219.5-330.0%)	0.183
Serum albumin (g/dl)	3.9 (3.7-4.1)	3.8 (3.5-4.0)	0.327
INR	1.1 (1.0-1.2)	1.1 (1.0-1.4)	0.253
Serum amylase	62.0 (55.3-78.8)	71.0 (58.5-86.0)	0.355
Serum lipase	51.0 (41.0-57.8)	65.0 (46.3-76.8)	0.043
Serum creatinine	1.1 (0.9-1.3)	1.0 (0.7-1.2)	0.157
Serum Urea	35.5 (25.3-49.5)	37.5 (24.0-45.0)	0.799
Hemoglobin	11.4 (10.1-12.5)	11.0 (10.3-12.0)	0.698
Platelet count	302 (282.5-370.3)	273 (199.3-346.5)	0.253
White blood count	7900 (5825-9925)	7650 (5925-9875)	0.862

Categorical variables are expressed in counts (percentages). Continuous variables are expressed in median values (interquartile range). \*Fischer's exact test.

Table 2 Comparison of the endoscopic and post-ERCP data between both study groups.

	EPBD (n = 20)	EST (n = 20)	P-value
Procedure duration (min)	50.0 (45.0-58.8)	50.0 (45.0-65.0)	0.565
Precut	3 (15.0%)	7 (35.0%)	0.144
Successful stone extraction	18 (94.7%)	18 (94.7%)	1.0*
Post ERCP pancreatitis	0 (0.0%)	2 (10.0%)	0.487
<b>Post-ERCP lab.</b>			
Total bilirubin	5.6 (4.1-7.5)	4.5 (3.9-6.9)	0.461
Direct bilirubin	3.5 (2.4-5.3)	2.9 (2.2-4.4)	0.461
Serum amylase	73.0 (56.0-84.8)	81.0 (67.5-89.5)	0.102
Serum lipase	64.5 (50.0-74.0)	70.0 (57.8-77.3)	0.201
Hemoglobin	11.1 (10.0-12.4)	10.9 (10.3-12.0)	0.968

Categorical variables are expressed in counts (percentages). Continuous variables are expressed in median values (interquartile range). \*Fischer's exact test



and EBS were 3.0 percent and 10.0 percent respectively in a report by Heo *et al.*; 2 cases had clinically relevant bleeding from EBS<sup>[11]</sup>. While the bleeding rates between groups were not considerably different, attention should be given to EBS plus EPBD in selected patients with serious coagulopathy and large stones.

We initiated univariable logistic regression to search for predictors of post ERCP pancreatitis. We evaluated all baseline characteristics, stone size, number, and duration of the procedure. We could not identify any independent predictors for post-ERCP pancreatitis. furthermore, type of sphincterotomy was not correlated to the pancreatitis risk and that may be due to small sample size (Table 3).

## CONCLUSIONS

EST is recognized as standard treatment option for CBD stone, but it is associated with elevated risk of bleeding.

EST plus LBD is a safe and effective treatment option for common bile duct stones extraction. This procedure is more effective in some cases, such as those with tapered distal CBD; large, rectangular stone, or several stones and anatomical variants, such as periampullary diverticulum.

## ACKNOWLEDGMENTS

Professor, Mohamed Elriwini MD our Godfather of Endoscopy.

## REFERENCES

- Gerasimos Stefanidis, Christos Christodoulou, Spilios Manolakopoulos, Ram Chuttani. "Endoscopic Extraction of Large Common Bile Duct Stones: A Review Article." *World J Gastrointest Endosc.* 2012 May 16; **4(5)**: 167-79. [PMID: 22624068]; [PMCID: PMC3355239]; [DOI: 10.4253/wjge.v4.i5.167]
- Suissa A, K Yassin, A Lavy, J Lachter, I Chermech, A Karban, A Tamir, R Eliakim. "Outcome and Early Complications of Ercp: A Prospective Single Center Study." *Hepatogastroenterology.* Mar-Apr 2005; **52(62)**: 352-5. [PMID: 15816433]
- Costi R, A Gnocchi, F Di Mario, L Sarli. "Diagnosis and Management of Choledocholithiasis in the Golden Age of Imaging, Endoscopy and Laparoscopy." *World J Gastroenterol.* 2014 Oct 7; **20(37)**: 13382-401. [PMID: 25309071]; [PMCID: PMC4188892]; [DOI: 10.3748/wjg.v20.i37.13382]
- Andriulli A, S Loperfido, G Napolitano, G Niro, MR Valvano, F Spirito, A Pilotto, R Forlano. "Incidence Rates of Post-Ercp Complications: A Systematic Survey of Prospective Studies." *Am J Gastroenterol.* 2007 Aug; **102(8)**: 1781-8. [PMID: 17509029]; [DOI: 10.1111/j.1572-0241.2007.01279.x]
- Fu BQ, YP Xu, LS Tao, J Yao, CS Zhou. "Endoscopic Papillary Balloon Intermittent Dilatation and Endoscopic Sphincterotomy for Bile Duct Stones." *World J Gastroenterol.* 2013 Apr 21; **19(15)**: 2425-32. [PMID: 23613639]; [PMCID: PMC3631997]; [DOI: 10.3748/wjg.v19.i15.2425]
- Shim CS, JW Kim, TY Lee, YK Cheon. "Is Endoscopic Papillary Large Balloon Dilation Safe for Treating Large Cbd Stones?" *Saudi J Gastroenterol.* Jul-Aug 2016; **22(4)**: 251-9. [PMID: 27488319]; [PMCID: PMC4991195]; [DOI: 10.4103/1319-3767.187599]
- Attam R, ML Freeman. "Endoscopic Papillary Large Balloon Dilation for Large Common Bile Duct Stones." *J Hepatobiliary Pancreat Surg.* 2009; **16(5)**: 618-23. [PMID: 19551331]; [DOI: 10.1007/s00534-009-0134-2]
- Cesar Capel de Clemente Junior, Wanderley Marques Bernardo, Tomazo Prince Franzini, Gustavo Oliveira Luz, Marcos Eduardo Lera Dos Santos, Jonah Maxwell Cohen, Diogo Turiani Hourneaux de Moura, Fábio Ramalho Tavares Marinho, Martin Coronel, Paulo Sakai, Eduardo Guimarães Hourneaux de Moura. "Comparison between Endoscopic Sphincterotomy Vs Endoscopic Sphincterotomy Associated with Balloon Dilation for Removal of Bile Duct Stones: A Systematic Review and Meta-Analysis Based on Randomized Controlled Trials." *World J Gastrointest Endosc.* 2018 Aug 16; **10(8)**: 130-144. [PMID: 30147845]; [PMCID: PMC6107471]; [DOI: 10.4253/wjge.v10.i8.130]
- Xu XD, B Chen, JJ Dai, JQ Qian, CF Xu. "Minor Endoscopic Sphincterotomy Followed by Large Balloon Dilation for Large Choledocholith Treatment." *World J Gastroenterol.* 2017 Aug 21; **23(31)**: 5739-5745. [PMID: 28883699]; [PMCID: PMC5569288]; [DOI: 10.3748/wjg.v23.i31.5739]
- Baron TH, GC Harewood. "Endoscopic Balloon Dilation of the Biliary Sphincter Compared to Endoscopic Biliary Sphincterotomy for Removal of Common Bile Duct Stones During Ercp: A Metaanalysis of Randomized, Controlled Trials." *Am J Gastroenterol.* 2004 Aug; **99(8)**: 1455-60. [PMID: 15307859]; [DOI: 10.1111/j.1572-0241.2004.30151.x]
- Heo JH, DH Kang, HJ Jung, DS Kwon, JK An, BS Kim, KD Suh, SY Lee, JH Lee, GH Kim, TO Kim, J Heo, GA Song, M Cho. "Endoscopic Sphincterotomy Plus Large-Balloon Dilation Versus Endoscopic Sphincterotomy for Removal of Bile-Duct Stones." *Gastrointest Endosc.* 2007 Oct; **66(4)**: 720-6. [PMID: 17905013]; [DOI: 10.1016/j.gie.2007.02.033]
- Kanazawa R, JK Sai, T Ito, H Miura, S Ishii, H Saito, K Tomishima, R Shimizu, K Sato, M Hayashi, S Watanabe, S Shiina. "Prior Minimal Endoscopic Sphincterotomy to Prevent Pancreatitis Related to Endoscopic Balloon Sphincteroplasty." *World J Gastrointest Endosc.* 2016 Oct 16; **8(18)**: 663-668. [PMID: 27803773]; [PMCID: PMC5067473]; [DOI: 10.4253/wjge.v8.i18.663]
- Chung JW, JB Chung. "Endoscopic Papillary Balloon Dilation for Removal of Choledocholithiasis: Indications, Advantages, Complications, and Long-Term Follow-up Results." *Gut Liver.* 2011 Mar; **5(1)**: 1-14. [PMID: 21461066]; [PMCID: PMC3065083]; [DOI: 10.5009/gnl.2011.5.1.1]

**Table 3** Logistic regression analysis for independent predictors of post-ERCP pancreatitis.

Variable	Univariable analysis		
	P	HR	95% CI
Age (y)	0.116	0.001	0.89-1.83
Sex*	0.998	0.001	-
Stone number	0.954	0.967	0.31-3.00
Stone size	0.355	1.225	0.79-1.88
Periampullary diverticulum	0.11	11.67	0.57-237.2
Precut	0.424	3.22	0.18-56.8
Procedure duration	0.173	1.09	0.96-1.25
Type of sphincterotomy**	0.998	<0.001	-

\*Male sex is the reference. \*\* EPBD is the reference.