

Hepatitis A Infection and Autoimmune Hepatitis: Inducing or Unmasking, That's the Question

Eyad Altamimi^{1,2}, Hussam Telfah³

1 Pediatric Department, Faculty of Medicine, Jordan University of Science and Technology, Irbid, Jordan;

2 Pediatric Department, King Abdullah University Hospital, Irbid, Jordan;

3 Department of Pathology, University Hospital Crosshouse, Kilmarnock, United Kingdom.

Conflict-of-interest statement: The authors declare that there is no conflict of interest regarding the publication of this paper.

Open-Access: This article is an open-access article which was selected by an in-house editor and fully peer-reviewed by external reviewers. It is distributed in accordance with the Creative Commons Attribution Non Commercial (CC BY-NC 4.0) license, which permits others to distribute, remix, adapt, build upon this work non-commercially, and license their derivative works on different terms, provided the original work is properly cited and the use is non-commercial. See: <http://creativecommons.org/licenses/by-nc/4.0/>

Correspondence to: Eyad Altamimi, MD, Pediatric Gastroenterologist, Hepatologist, Associate Professor of Pediatrics, Pediatric Department, Faculty of Medicine, Jordan University of Science and Technology, Irbid- Jordan.

Email: emaltamimi@just.edu.jo

Telephone: +962797464254

Received: April 12, 2020

Revised: May 8, 2020

Accepted: May 12, 2020

Published online: June 25, 2020

ABSTRACT

A 13-year-old girl presented with a three months history of abdominal pain, jaundice, and fatigue. Three cousins developed symptoms at the same time. She sought medical help. Examination revealed HAV IgM positivity, and clinical suspicion of Hepatitis A was confirmed. After four weeks, her jaundice had not resolved, although all her three cousins who developed jaundice had experienced resolution of their symptoms. The patient visited her pediatrician. Her transaminases persisted at ALT of 633 U/L and AST of 905 U/L with direct hyperbilirubinemia. Her coagulation profile showed a slightly prolonged prothrombin time (PT 15.9 sec) and INR 1.29.

Liver ultrasonography showed features of hepatitis with no evidence of obstruction. Upon presentation to the gastroenterology clinic; she was still jaundiced, with abdominal pain, fatigue, loss of appetite, and loose bowel movement. She had lost almost 4 kgs over a period of 3 months. She received no medications. On Physical examination she appeared deeply jaundiced. There was mild hepatomegaly with soft edge and no features of chronic liver dysfunction or portal hypertension were detected. Her weight and body mass index (BMI) were on the 50th centile for age. Her work-up showed negative hepatitis markers except for HAV IgG. Her immunological investigations revealed hypergammaglobulinemia and positive ASMA. She underwent liver biopsy which showed the features of autoimmune hepatitis. Patient received steroids followed by Thiopurine. On follow up, two years off treatment, the patient had no relapse.

Key words: Autoimmune; Virus; Hepatitis; Child; Steroids; Imuran

© 2020 The Authors. Published by ACT Publishing Group Ltd. All rights reserved.

Altamimi E, Telfah H. Hepatitis A Infection and Autoimmune Hepatitis: Inducing or Unmasking, That's the Question. *Journal of Gastroenterology and Hepatology Research* 2020; **9(3)**: 3238-3241 Available from: URL: <http://www.ghrnet.org/index.php/joghr/article/view/2927>

INTRODUCTION

Hepatitis A virus (HAV) is an enveloped RNA virus of the Picornaviridae family. This hepatotropic virus is transmitted enterically^[1] and is the most common cause of acute hepatitis worldwide^[2]. Acute hepatitis A infection in young children mimics acute gastroenteritis and is usually anicteric. Older children present with acute hepatitis, including jaundice, fever, malaise, abdominal pain, nausea, vomiting, diarrhea, dark urine, headache, and weight loss^[3]. Hepatitis A infection is confirmed by detecting HAV IgM in the patient's blood^[1]. This infection is self-limiting, requires no specific treatment, and resolves without chronic sequelae in the liver, although a protracted course and disease relapse are not uncommon^[1,3].

Autoimmune hepatitis (AIH) is a chronic necro-inflammatory disease of the liver, secondary to loss of immune tolerance to liver antigen^[4]. AIH is diagnosed based on a combination of features, including clinical manifestations of hepatitis; laboratory evaluation

indicating the presence of autoantibodies and hypergammaglobulinemia; characteristic histopathological features; and exclusion of other common chronic liver diseases^[4,5]. AIH appears to affect all ages and races with female predominance. Although adolescents are the most affected age group, young infants are also affected^[4-6].

The exact etiology of AIH is not well understood, but it is believed to be multifactorial (e.g. environmental, genetic, and immunologic)^[7]. One possibility is that viruses that share liver antigen homology may induce AIH through cross reactivity to viral proteins, causing liver damage^[8-10].

Subtle presentation with nonspecific symptoms as; fatigue, lethargy, nausea, right upper quadrant pain sometimes with no jaundice is the most common phenotype. Less common are acute hepatitis and cirrhosis^[11].

Here, we present the case of a patient diagnosed with AIH post confirmed hepatitis A infection. The patient was treated with steroids and thiopurines and followed for two years while off medications without relapse.

CASE PRESENTATION

No ethical approval needed, parents gave their consent for reporting the case. No patient's identifiers used in this case.

Three months prior to presentation, a 13-year-old girl developed abdominal pain, jaundice, and fatigue. Three of her cousins developed symptoms at the same time. She sought medical help. Examination revealed HAV IgM positivity, and clinical suspicion of Hepatitis A was confirmed. Her family was assured that the symptoms would resolve spontaneously within couple of weeks, leaving no sequelae. After four weeks, her jaundice had not resolved, although all her three cousins who developed jaundice had experienced resolution of their symptoms. The patient visited her pediatrician. Examination again showed jaundice, and her blood work-up showed persistent hypertransaminasemia (ALT 633 U/L, AST 905 U/L) with direct hyperbilirubinemia (3.4/2.9 mg/dl). Her coagulation profile showed a slightly prolonged prothrombin time (PT 15.9 sec) and INR 1.29. Her

urine exam was positive for bilirubin. Abdominal ultrasonography showed features of hepatitis with no evidence of obstruction. The patient was referred to our clinic for further evaluation and management.

Upon presentation to our clinic, she was still jaundiced, with abdominal pain, fatigue, loss of appetite, and loose bowel movement. She had lost almost 4 kgs over the last 3 months. She received no medications. Physical examination showed a deeply jaundiced child, with mild hepatomegaly with a soft edge and no features of chronic liver dysfunction or portal hypertension. Her weight and body mass index [BMI] were on the 50th centile for age.

Workup at our clinic showed continued hypertransaminasemia (ALT 796 U/L, AST 990 U/L) and direct hyperbilirubinemia (12.9/11.7 mg/dL). Her alkaline phosphatase (ALP), albumin, total protein and coagulation profiles were normal. Her hepatitis profile showed HAV IgM negative, HAV IgG positive, HBsAg negative, and HCV non-reactive. She had no anemia or thrombocytopenia.

Her immunological workup showed hypergammaglobulinemia [total IgG 1870 (608-1572) mg/dl], while rest of the immunoglobulins were within normal levels. ANA and AMA were negative, but ASMA was positive. Ferritin levels were mildly elevated; ceruloplasmin was not available at presentation. Her lipids were mildly elevated (Table 1).

Liver ultrasonography revealed an enlarged liver with coarse echotexture. The gallbladder wall appeared thickened with surrounding a pericholecystic fluid collection. No stones were seen. The portal vein was patent with normal blood flow.

A liver biopsy showed expanded portal tracts which are infiltrated by chronic inflammatory cells (mainly lymphocytes). Most of the portal tracts showed interface hepatitis, with no eosinophils or neutrophils. Plasma cells were scanty, and no granulomas were identified (Figure 1).

Further findings included formation of hepatocyte rosettes, with rarefaction of the hepatocyte cytoplasm. Foci of spotty necrosis were seen, and no cytoplasmic globules were identified. Moderate fibrosis was observed (highlighted by reticulin and van Gieson stains) with septal to septal bridging (Figures 2 and 3). The appearance was of

Table 1 Laboratory parameters of the patient since diagnosis and during follow up.

	Upon HAV diagnosis	2 months later	On diagnosis of AIH Steroid started	One month on Steroids	Imuran Started	Treatment stopped	Six months off treatment	Two years off treatment
ALT (U/L)	960	633	796	163	49.5	17.1	16	16.3
AST (U/L)	862	905	990	74	41	19.5	9	6
BIL T (umol/L)	6.2	3.4	14.2	5.2	2	0.2	0.6	0.5
BIL D (umol/L)	4.3	2.9	11.7	4.2	1.7	----	----	
ALP(U/L)			359	206	195	175	135	130
GGT (U/L)			43	55	51	18		
PRTN (g/L)			79.4	79.1	80.2	78.8		
ALBUMIN (g/L)			44	52.3	52.4	52		
PT (sec)			15					
INR		1.29	1.19					
Hb. (g/dL)		13.8	12.2			14	13.8	
WBC (10 ³ /mm ³)		5.56	6.2			8.5	7.45	
PLT (10 ³ /mm ³)		382	377			372	320	
Lipase (U/L)							16	
AMYLASE (U/L)						104	9	
IgG (mg/dL)			1870	1210	1000	1050		
HEPATITIS A IgM*	Positive		Negative					
HEPATITIS A IgG*	Negative		Positive					
HAV RNA	Not available							

*Titer were not available; HAV: Hepatitis A virus

active chronic hepatitis with moderate fibrosis consistent with AIH findings.

The patient was started on prednisolone, 60 mg daily with acid suppression and calcium and vitamin D supplementation. One week after treatment began, her liver enzymes, IgG levels, and bilirubin levels began to drop (Table 1). While on steroids, the patient gained weight, developed hyperglycemia, and had hypertension. Dietary advice and rapid tapering of steroids controlled her weight gain, while hyperglycemia and hypertension resolved without medications while tapering the steroids. Thipourine at a dose of 1 mg/kg/day was added to her treatment protocol upon starting her steroid tapering. While on azathioprine, she had a non-symptomatic, mild elevation of amylase, which required no intervention and resolved completely after stopping the medication.

The family refused prolonged treatment and repeat liver biopsy. Her medication were tapered down and stopped after her liver enzymes, immunoglobulins, and autoimmune antibodies were normal for six months. She has now been off medication for 12 months and is doing well with no relapse.

DISCUSSION

This case report describes the development of AIH in a young girl after hepatitis A infection. In our patient, hepatitis A was confirmed through HAV IgM positivity with typical clinical manifestations, and her AIH was a very likely definite diagnosis according to the revised Original Scoring System of the International Autoimmune Hepatitis Group^[12].

The diagnostic dilemma still unsolved, whether this patient's autoimmune hepatitis is the original problem that was unmasked by the acute viral hepatitis or this patient's autoimmune hepatitis induced by viral hepatitis.

Most children affected by hepatitis A resolve their infection and have normal laboratory findings within 1-6 weeks of onset. Persistence of symptoms and abnormal laboratory findings beyond the expected duration was alarming for pathology beyond hepatitis A and warranted further evaluation. The chloestatic variant^[13], which consists of persistent jaundice associated with elevated alkaline phosphatase and normal transaminases, and biphasic variant^[14], which is characterized by recurrence of symptoms after complete resolution, were excluded.

Persistence of HAV infection, manifested by persistence of symptoms and HAV IgM positivity, is linked to the development of AIH^[10]. In our case, anti-HAV IgM became negative while the patient was still jaundiced and symptomatic, which is against persistent HAV infection.

Although adolescent girls have an increased incidence of AIH^[12,15], children are more likely to be affected by hepatitis A infection. Hepatitis A infection inducing autoimmune hepatitis is a known phenomenon in older patients. Multiple theories proposed to explain such complication; homology between the virus antigen and liver proteins is a plausible theory. HLA-DR13 has been considered responsible for protracted courses of hepatitis A^[10], although this was not universal. Other HLA factors may be involved in this process. Unfortunately, HLA testing was not available in our facility.

It is possible that this patient had pre-existing AIH and acquisition of hepatitis A infection unmasked the condition. This theory is supported by the presence of histopathological features of chronic hepatitis. Denial of the patient and her family any relevant history of prior liver disease can't exclude this diagnosis of AIH. Two thirds of patients with autoimmune hepatitis can present with non-specific

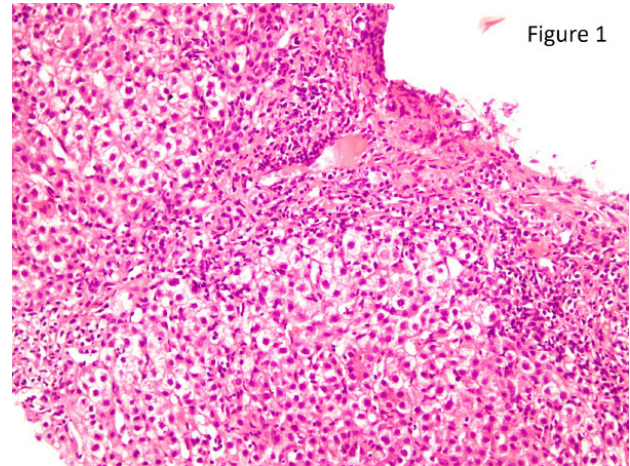


Figure 1 H&E stain: Interface hepatitis with dense lymphocytic infiltrate into the hepatocytes. Most of the portal tracts show interface hepatitis. No obvious eosinophils or neutrophils are seen. Plasma cells are scanty. No granulomas are identified. Foci of spotty necrosis are seen. No cytoplasmic globules are identified ($\times 20$).

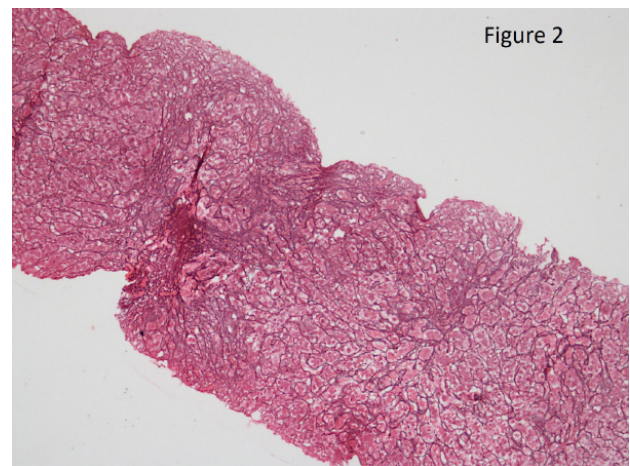


Figure 2 Reticulin stain: Increased reticulin staining within the portal tracts and the fibrous septa ($\times 10$).

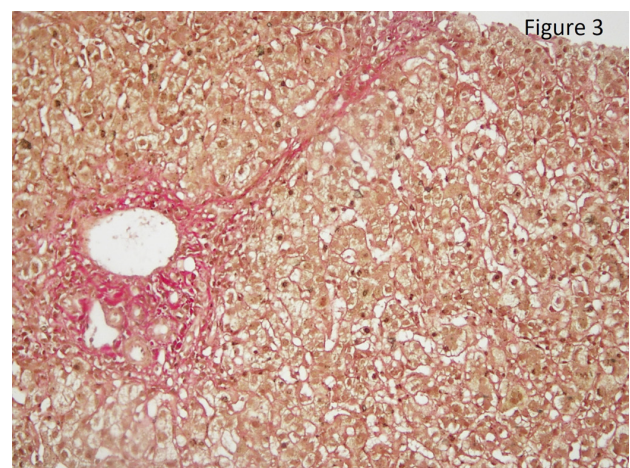


Figure 3 Van Gieson stain: Fibrosis of one of the portal tracts and formation of a fibrous septum ($\times 20$).

symptoms with fluctuating jaundice^[11].

Steroids are an effective treatment for AIH, and a steroid-only protocol can be used^[16]. However, given the side effects of steroids, efforts need to be taken to avoid maintaining patients on steroids for prolonged periods. In our case, the patient responded to steroids with

normalization of liver enzymes and total immunoglobulin. However, she developed multiple side effects, including voracious appetite, significant weight gain, hyperglycemia, irregular menstrual cycle, skin striae, and steroid-induced hypertension.

Upon tapering her steroids, all of these side effects resolved except the skin striae, which continued to bother the patient although they did fade over time. Azathioprine caused her amylase to increase, but she did not have frank pancreatitis, and the levels normalized upon stopping the medication. Azathioprine toxicity can be anticipated in patients with low and intermediate dosage of thiopurine methyltransferase (TPMT). Some authorities recommend TPMT testing prior to starting thiopurines. Unfortunately, the test is not available at our facility.

AIH is known to have an inherent tendency to relapse not only after stopping treatment but also during treatment tapering^[16,17]. Adolescents are at increased risk of relapse secondary to non-adherence to the prolonged treatment course. The ESPGHAN Hepatology Committee Position Statement on AIH in pediatric patients recommends treatment for 2-3 years, and cessation of treatment needs to be guided by liver biopsy^[16]. Our patient's family insisted on stopping all the medications once the liver enzymes, immunoglobulins, and autoantibodies were normal for six months. She had been followed for two year since stopping treatment, and her liver enzymes are normal. Long-term follow up is still needed. In conclusion, hepatitis A infection in children is common. Most cases resolve spontaneously without any complications. Prolonged symptoms should alert physicians for other possibilities including autoimmune hepatitis.

REFERENCES

- Centers for Disease Control and Prevention. Hepatitis A FAQs for health professionals. <http://www.cdc.gov/hepatitis/HAV/HAVfaq.htm>. Accessed January 14, 2019.
- Koslap-Petraco MB, Shub M, Judelsohn R. Hepatitis A: disease burden and current childhood vaccination strategies in the United States. *J Pediatr Health Care*. 2008 Jan-Feb; **22**(1): 3-11. [PMID: 18174084]; [DOI: 10.1016/j.pedhc.2006.12.011]
- Matheny SC, Kingery JE. Hepatitis A. *Am Fam Physician*. 2012 Dec 1; **86**(11): 1027-34; quiz 1010-2. [PMID: 23198670]
- Alvarez F. Autoimmune hepatitis and primary sclerosing cholangitis. *Clin Liver Dis*. 2006 Feb; **10**(1): 89-107, vi. [PMID: 16376796]; [DOI: 10.1016/j.cld.2005.10.009]
- Pathak S, Kamat D. Autoimmune Hepatitis in Children. *Pediatr Ann*. 2018 Feb 1; **47**(2): e81-e86. [PMID: 29446799]; [DOI: 10.3928/19382359-20180126-01]
- Lohse AW, Mieli-Vergani G. Autoimmune hepatitis. *J Hepatol*. 2011 Jul; **55**(1): 171-82. [DOI: 10.1016/j.jhep.2010.12.012]. Epub 2010 Dec 15. [PMID: 21167232]
- Czaja AJ, Manns MP. Advances in the diagnosis, pathogenesis, and management of autoimmune hepatitis. *Gastroenterology*. 2010 Jul; **139**(1): 58-72.e4. Epub 2010 May [PMID: 20451521]; [DOI: 10.1053/j.gastro.2010.04.053]
- Vento S, Cainelli F. Is there a role for viruses in triggering autoimmune hepatitis? *Autoimmun Rev*. 2004 Jan; **3**(1): 61-9. [PMID: 14871651]; [DOI: 10.1016/S1568-9972(03)00053-3]
- Strassburg CP, Vogel A, Manns MP. Autoimmunity and hepatitis C. *Autoimmun Rev*. 2003 Oct; **2**(6): 322-31. [PMID: 14550873]; [DOI: 10.1016/s1568-9972(03)00036-3]
- Tabak F, Ozdemir F, Tabak O, Erer B, Tahan V, Ozaras R. Autoimmune hepatitis induced by the prolonged hepatitis A virus infection. *Ann Hepatol*. 2008 Apr-Jun; **7**(2): 177-9. [PMID: 18626439]
- Gatselis NK, Zachou K, Koukoulis GK, Dalekos GN. Autoimmune hepatitis, one disease with many faces: etiopathogenetic, clinico-laboratory and histological characteristics. *World J Gastroenterol*. 2015 Jan 7; **21**(1): 60-83. [PMID: 25574080; PMCID: PMC4284362]; [DOI: 10.3748/wjg.v21.i1.60]
- Alvarez F, Berg PA, Bianchi FB, Burroughs AK, Cancado EL, Chapman RW, Cooksley WG, Czaja AJ, Desmet VJ, Donaldson PT, Eddleston AL, Fainboim L, Heathcote J, Homberg JC, Hoofnagle JH, Kakumu S, Krawitt EL, Mackay IR, MacSween RN, Maddrey WC, Manns MP, McFarlane IG, Meyer zum Büschenfelde KH, Zeniya M, et al. International Autoimmune Hepatitis Group Report: review of criteria for diagnosis of autoimmune hepatitis. *J Hepatol*. 1999 Nov; **31**(5): 929-38. [PMID: 10580593]; [DOI: 10.1016/s0168-8278(99)80297-9]
- Sagnelli E, Coppola N, Marrocco C, Onofrio M, Scarano F, Marotta A, Scolastico C, Catuogno A, Salzillo A, Sagnelli C, Piccinino F, Filippini P. HAV replication in acute hepatitis with typical and atypical clinical course. *J Med Virol*. 2003 Sep; **71**(1): 1-6. [PMID: 12858402]; [DOI: 10.1002/jmv.10455]
- Koff RS. Hepatitis A. *Lancet*. 1998 May 30; **351**(9116): 1643-9. [PMID: 9620732]; [DOI: 10.1016/S0140-6736(98)01304-X]
- Grünhage F, Spengler U, Fischer HP, Sauerbruch T. Autoimmune hepatitis--sequel of a relapsing hepatitis A in a 75-year-old woman. *Digestion*. 2004; **70**(3): 187-91. Epub 2004 Nov 19. [PMID: 15557764.]; [DOI: 10.1159/000082253]
- Mieli-Vergani G, Vergani D, Baumann U, Czubkowski P, Debray D, Dezsöfi A, Fischler B, Gupte G, Hierro L, Indolfi G, Jahnle J, Smets F, Verkade HJ, Hadžić N. Diagnosis and Management of Pediatric Autoimmune Liver Disease: ESPGHAN Hepatology Committee Position Statement. *J Pediatr Gastroenterol Nutr*. 2018 Feb; **66**(2): 345-360. [PMID: 29356770]; [DOI: 10.1097/MPG.0000000000001801]
- Manns MP, Czaja AJ, Gorham JD, Krawitt EL, Mieli-Vergani G, Vergani D, Vierling JM; American Association for the Study of Liver Diseases. Diagnosis and management of autoimmune hepatitis. *Hepatology*. 2010 Jun; **51**(6): 2193-213. [PMID: 20513004]; [DOI: 10.1002/hep.23584]