

Journal of Gastroenterology and Hepatology Research

Online Submissions: <http://www.ghrnet.org/index./joghr/>
doi: 10.17554/j.issn.2224-3992.2020.09.922

Journal of GHR 2020 August 21; 9(4): 3253-3254
ISSN 2224-3992 (print) ISSN 2224-6509 (online)

HIGHLIGHT TOPIC

Redo GPOEM for Refractory Gastroparesis: is it Feasible and Useful?

Baiwen Li^{1,2}, Lucie F. Calderon¹, Huimin Chen^{1,3}, Jennifer Xu¹, Qiang Cai¹

1 Department of Medicine, Division of Digestive Diseases, Emory University School of Medicine, Atlanta, GA, United States;

2 Department of Gastroenterology, Shanghai General Hospital, Shanghai Jiao Tong University School of Medicine, Shanghai, China;

3 Department of Gastroenterology, Renji Hospital, Shanghai Jiao Tong University School of Medicine, Shanghai, China

Conflict-of-interest statement: The authors declare that there is no conflict of interest regarding the publication of this paper.

Open-Access: This article is an open-access article which was selected by an in-house editor and fully peer-reviewed by external reviewers. It is distributed in accordance with the Creative Commons Attribution Non Commercial (CC BY-NC 4.0) license, which permits others to distribute, remix, adapt, build upon this work non-commercially, and license their derivative works on different terms, provided the original work is properly cited and the use is non-commercial. See: <http://creativecommons.org/licenses/by-nc/4.0/>

Correspondence to: Qiang Cai, MD, PhD, Professor of Medicine, Director of Advanced Endoscopy Fellowship, Emory University, Atlanta, GA, United States.

Email: qcai@emory.edu

Telephone: +81-42-323-5111

Fax: +81-42-323-9209

Received: April 16, 2020

Revised: July 6, 2020

Accepted: July 10, 2020

Published online: August 21, 2020

ABSTRACT

Per oral endoscopic pyloromyotomy (GPOEM or POP) is relatively new endoscopic therapy for gastroparesis. Studies indicate that the short term and long term efficacy are promising. However, some patients may have recurrence with nausea and vomiting again certain time after the index GPOEM. We present cases here with the short term outcome of second GPOEM. The result is promising. This is the first report of the outcome of second GPOEM and more patients are needed for further study.

Key words: GPOEM; POP; Gastroparesis; Myotomy

© 2020 The Authors. Published by ACT Publishing Group Ltd. All rights reserved.

Li B, Calderon LF, Chen H, Xu J, Cai Q. Redo GPOEM for Refractory Gastroparesis: is it Feasible and Useful? *Journal of Gastroenterology and Hepatology Research* 2020; 9(4): 3253-3254 Available from: URL: <http://www.ghrnet.org/index.php/joghr/article/view/2956>

HIGHLIGHT TOPIC

Since gastric per oral endoscopic myotomy (GPOEM) was first reported in 2013^[1], it has become a promising minimally invasive interventional for refractory gastroparesis with encouraging short-term efficacy rate of 80%^[2,3]. However, its mid-term data suggested that some patients might lose clinical response over time^[3]. It is challenging to manage patients. Those patients are usually very sick with daily symptoms of nausea and vomiting. They are frequent emergency room visitors and are hospitalized many times a year^[4-5]. In this case report, we have 2 patients with recurrence who achieved remission after the redo GPOEM (Figure 1). To our knowledge, this is the first report of the outcome of redo GPOEMs.

Case 1: A 36-year-old Caucasian female with refractory idiopathic gastroparesis suffered from failure to thrive as she had no response to medications, Botulinum injection, or gastric electrical stimulator. After the first GPOEM, she achieved satisfactory clinical response. Her gastroparesis cardinal symptoms index (GCSI) significantly improved from 2.9 to 0.6, gastric retention at 2-hour during the gastric emptying study (GES) decreased from 95% to 75%. The clinical response had sustained for 18 months then symptoms recurred and GCSI went up to 3.3 (Figure 2). She could not tolerate a repeat GES. Her redo GPOEM was performed at 25 months after the index procedure. She felt better again and at 6 months follow up, her GCSI was 0.7. She gained weight with an increased body mass index from 18 to 23, and gastric retention at 2-hour was 71%.

Case 2: A 66-year-old Caucasian female with longstanding years of idiopathic gastroparesis and had previously failed medical therapy. She couldn't tolerate GES due to repeated vomiting before the first GPOEM. After the first GPOEM, her symptoms significantly improved for 15 months. Three months after the first GPOEM, GES

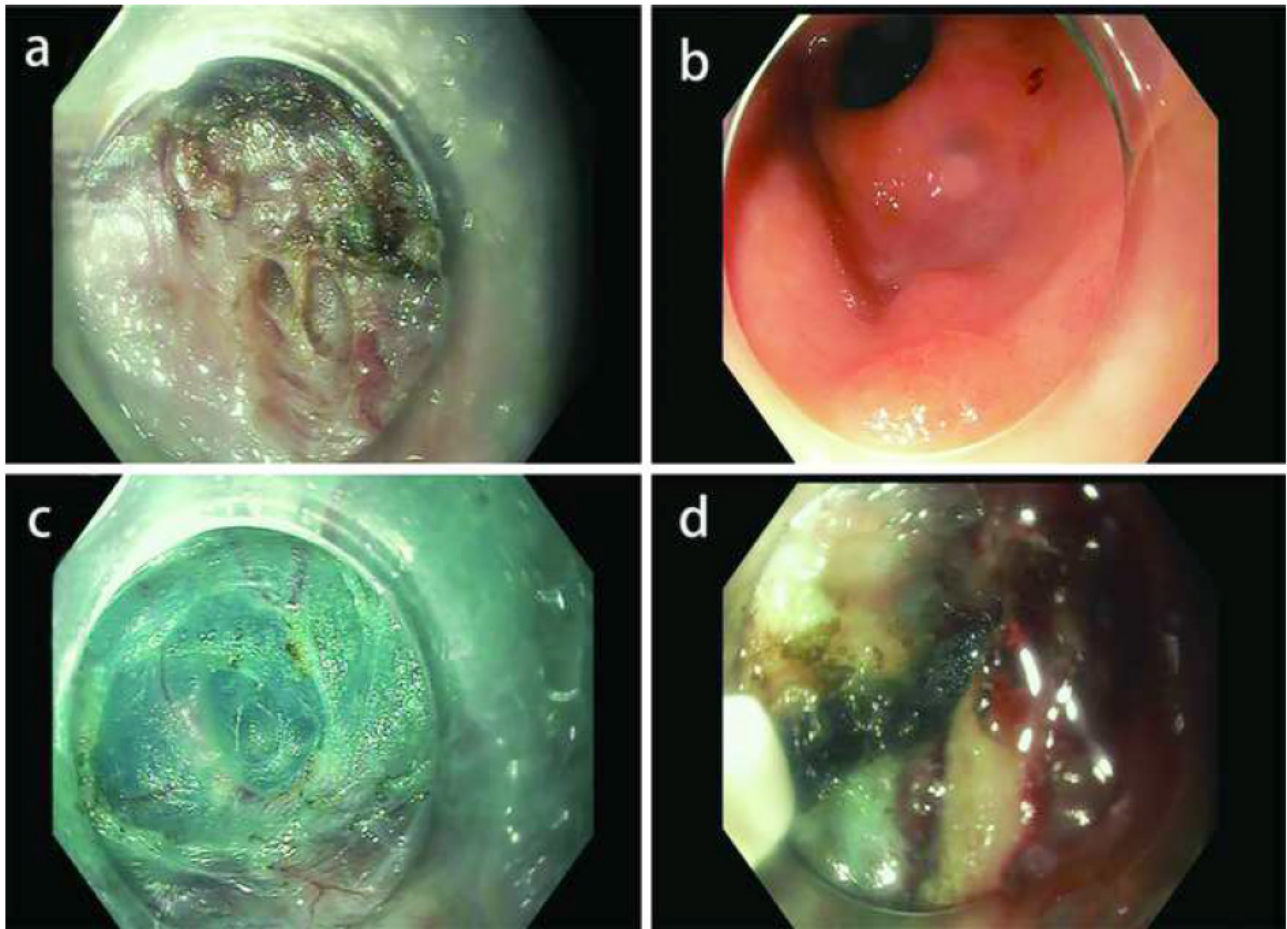


Figure 1 Endoscopic images of redo GPOEM procedure. A) Myotomy at the first GPOEM. B) Antrum scar after initial GPOEM. C) Fibrosis after initial GPOEM. D) Second myotomy.

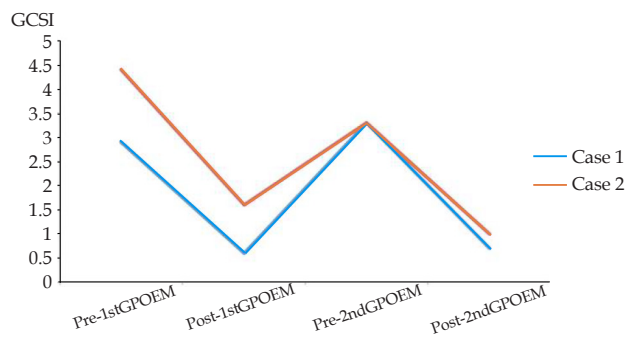


Figure 2 GCSI before and after 1st and 2nd GPOEMs.

became normal. Meanwhile, her GCSI significantly improved from 4.4 to 1.6 at the 6-month follow-up. Approximately 15 months after the initial procedure, she began having worsened nausea, vomiting, early satiety, bloating, and GCSI went up to 3.3 (Figure 2). Another GES showed significantly delayed gastric emptying with 87% at 2 hours and 15% at 4 hours. Her redo GPOEM was performed at that time. Her symptoms significantly improved to 1.0 after the redo GPOEM with completely resolved vomiting symptom. She gained 2lbs in two months. Management of those patients with recurrent symptoms after GPOEM is difficult. They had failed medical treatment and other endoscopic therapies, such as gastric electrical stimulator or botox injection. As there were no additional therapeutic options that provided relief for our patient's recurrent symptoms, a redo GPOEM may be an option for patients recur symptoms. Technically, redo GPOEM is difficult due to fibrosis from the index

GPORM and thus required an extended mucosotomy to avoid scarring tissue. Also, dissection and myotomy were at relatively difficult angle. Despite these challenges, the outcome of those two redo GPOEM were promising. Further studies on more patients and long term follow up are needed to further determine the outcome of redo GPOEMs.

REFERENCES

- Gonzalez JM, Vanbiervliet G, Vitton V, et al. First European human gastric peroral endoscopic myotomy, for treatment of refractory gastroparesis. *Endoscopy* 2015; **47**: E135-E136. [PMID: 25857477]; [DOI: 10.1055/s-0034-1391821]
- Dacha S, Mekaroonkamol P, Li L, et al. Outcomes and quality-of-life assessment after gastric per-oral endoscopic pyloromyotomy (with video). *Gastrointestinal Endoscopy* 2017 Aug; **86**(2): 282-289. [PMID: 28161449]; [DOI: 10.1016/j.gie.2017.01.031]
- Mekaroonkamol P, Dacha S, Patel V, et al. Outcomes of Per Oral Endoscopic Pyloromyotomy in the United States. *Gastrointest Endosc Clin N Am.* 2019; **29**: 151-160. [PMID: 30396525]; [DOI: 10.1016/j.giec.2018.08.009]
- Mekaroonkamol P1, Dacha S1, Wang L, et al. Gastric Peroral Endoscopic Pyloromyotomy Reduces Symptoms, Increases Quality of Life, and Reduces Health Care Use For Patients With Gastroparesis. *Clin Gastroenterol Hepatol.* 2019; **17**: 82-89. [PMID: 29660525]; [DOI: 10.1016/j.cgh.2018.04.016]
- Khashab MA, Stein E, Clarke JO, et al. Gastric peroral endoscopic myotomy for refractory gastroparesis: first human endoscopic pyloromyotomy (with video). *Gastrointestinal Endoscopy* 2013; **78**: 764-768. [PMID: 24120337]; [DOI: 10.1016/j.gie.2013.07.019]