

## Prevention of PEG Tube Misplacement in the Transverse Colon: Method of Introducing a Gastrografin into the Stomach

Hiromi Ono<sup>1</sup>, MD; Hitoshi Yokoyama<sup>1</sup>, MD, PhD; Haruyuki Yoshida<sup>1</sup>, MD; Hiraku Fukushima<sup>1</sup>, MD, PhD; Masato Kawakami<sup>1</sup>, MD; Mikio Okamura<sup>2</sup>, MD; Takanori Aoki<sup>2</sup>, MD; Naoki Asakage<sup>2</sup>, MD; Kimimoto Nagashima<sup>3</sup>, MD; Yasushi Danjo<sup>4</sup>, MD, PhD; Hideyuki Hayashi<sup>1,5</sup>, MD, PhD; Hiroshi Nishihara<sup>1,5</sup>, MD, PhD; Yuichi Shimizu<sup>1,6</sup>, MD, PhD; Tsuyoshi Shimamura<sup>2,7</sup>, MD, PhD; Mitsuo Kusano<sup>8</sup>, MD, PhD

1 Department of Internal Medicine, Seiwa Memorial Hospital, 1-1, 1-Jo, 5-Chome, Kotoni, Nishi-ku, Sapporo, Hokkaido, 063-0811, Japan;

2 Department of Surgery, Seiwa Memorial Hospital, 1-1, 1-Jo, 5-Chome, Kotoni, Nishi-ku, Sapporo, Hokkaido, 063-0811, Japan;

3 Department of Anesthesiology, Shin-Sapporo Orthopedic Hospital, 2-32, 2-Chome, Atsubetsuminami, Atsubetsu-ku, Sapporo, Hokkaido, 004-0022, Japan;

4 Department of Surgery, Heiwa Hospital, 2-1, 2-Jo, 11-Chome, Heiwa, Nishi-ku, Sapporo, Hokkaido, 063-0022, Japan;

5 Genomics Unit, Keio Cancer Center, Keio University School of Medicine, 35 Shinanomachi, Shinjuku-ku, Tokyo, 160-8582, Japan;

6 Division of Endoscopy, Hokkaido University Hospital, Kita 14, Nishi 5, Kita-ku, Sapporo, Hokkaido, 060-8648, Japan;

7 Division of Organ Transplantation, Central Clinical Facilities, Hokkaido University Hospital, Kita 14, Nishi 5, Kita-ku, Sapporo, Hokkaido, 060-8648, Japan;

8 Division of Internal Medicine, Hokkaido Social Welfare Corporation Yoichi Hospital, 19-1-1, Kurokawa-cho, Yoichi, Hokkaido, 046-0003, Japan.

**Conflict-of-interest statement:** The authors declare that there is no conflict of interest regarding the publication of this paper.

**Open-Access:** This article is an open-access article which was selected by an in-house editor and fully peer-reviewed by external reviewers. It is distributed in accordance with the Creative Commons Attribution Non Commercial (CC BY-NC 4.0) license, which permits others to distribute, remix, adapt, build upon this work non-commercially, and license their derivative works on different terms, provided the original work is properly cited and the use is non-commercial. See: <http://creativecommons.org/licenses/by-nc/4.0/>

**Correspondence to:** Hiromi Ono, Department of Internal Medicine, Seiwa Memorial Hospital, 1-1, 1-Jo, 5-Chome, Kotoni, Nishi-ku, Sapporo, Hokkaido, 063-0811, Japan.

**Email:** [ohiromi74@ab.auone-net.jp](mailto:ohiromi74@ab.auone-net.jp)

**Telephone:** +81116111111

**Fax:** +81116316271

Received: July 22, 2020

Revised: September 20, 2020

Accepted: September 21, 2020

Published online: October 21, 2020

### ABSTRACT

**AIM:** A colocolic fistula is a rare late complication of percutaneous endoscopic gastrostomy (PEG) feeding placement that occurs as a result of the interposition of the colon between the anterior abdominal and gastric walls. In the current study, we sought to retrospectively study the method of introducing the water-soluble contrast agent into the stomach by using a nasogastric tube before PEG feeding placement, with the intention to develop a method to prevent PEG-related colocolic fistula.

**MATERIALS AND METHODS:** Between October 2003 and April 2020, 341 patients underwent PEG placement at Seiwa Memorial Hospital. Patients were divided into two groups: 232 patients in Group A were given water-soluble contrast agent and 109 patients in Group B were not. All patients underwent PEG using introducer method placement after gastropexy under fluoroscopy.

**RESULTS:** In Group A, 139 (59.9%) patients received PEG with a water-soluble contrast agent placed into the transverse colon, 75 (32.3%) received PEG with gas in the colon, and 7 (3.0%) patients received surgical gastrostomy. In Group B, 38 (34.8%) patients received PEG with gas in the colon, 60 (55.1%) patients received PEG with finger palpation and transillumination, and 10 (9.2%) patients received surgical gastrostomy. Colocolic fistula was not observed in either group, but there was a significant difference in the frequency of surgical gastrostomy between Group A and B ( $p = 0.0148$ ).

**CONCLUSION:** The use of water-soluble contrast agent in the stomach was safe, reliable, and cost effective for PEG tube placement, and is recommended to decrease surgical gastrostomy.

**Key words:** Colocolic fistula; Diatrizoate meglumine and diatrizoate sodium; Gastrografin; Percutaneous endoscopic gastrostomy; Transverse colon

© 2020 The Authors. Published by ACT Publishing Group Ltd. All

rights reserved.

Ono H, Yokoyama H, Yoshida H, Fukushima H, Kawakami M, Okamura M, Aoki T, Asakage N, Nagashima K, Danjo Y, Hayashi H, Nishihara H, Shimizu Y, Shimamura T, Kusano M. Prevention of PEG Tube Misplacement in the Transverse Colon: Method of Introducing a Gastrografin into the Stomach. *Journal of Gastroenterology and Hepatology Research* 2020; **9**(5): 3320-3324 Available from: URL: <http://www.ghrnet.org/index.php/joghr/article/view/2971>

## INTRODUCTION

Percutaneous endoscopic gastrostomy (PEG) is a safe and effective technique for enteral feeding<sup>[1]</sup>. Despite the widespread use of PEG tubes, this procedure is associated with a variety of complications, including peristomal infection, aspiration pneumonia, stomal leakage, and peritonitis<sup>[2]</sup>. Colocutaneous fistula is a delayed and rare complication of PEG tubes<sup>[3-7]</sup> that is believed to occur in a small minority (0.5%-1%) of adults undergoing PEG insertion<sup>[8,9]</sup>, and more frequently in children, at a rate of 2%-3.5%<sup>[10,11]</sup>. It is well known that PEG tubes can occasionally migrate from the stomach into the transverse colon via a gastrocolic fistula. In most cases, the tube can be removed without the need for surgery, but emergent laparotomy or surgery is indicated in cases with perforation or peritonitis<sup>[12]</sup>. The conservative approach needs several days or weeks for complete healing of the colocutaneous fistula<sup>[3]</sup>, and patients require the PEG to be replaced; therefore, it is important to avoid this complication. The aim of the current study was to prevent the occurrence of colocutaneous fistula. To this end, we changed the method of introduction of the water-soluble contrast agent into the stomach to involve insertion of the nasogastric tube prior to the PEG placement.

## METHODS

### Patients

We included 341 patients (141 males and 200 females, 46–103 years old; mean age, 83.3±9.1 years) who underwent PEG due to dysphagia from October 2003 to April 2020 at Seiwa Memorial Hospital. Of the 341 patients, 124 cases (36.4%) had cerebrovascular disease, 114 had dementia, and 21 had malignancy. None of the patients underwent surgery of the gastrointestinal tracts before PEG placement, and none of the patients had an ileus. This study was performed according to the principles of the Declaration of Helsinki, and approval was given by the Ethics Committee of Seiwa Memorial Hospital. Written informed consent was obtained from all patients or their families.

### Protocol for PEG placement

Patients were divided into two groups. In Group A patients (232 cases; from March 2007 to April 2020), 40 ml of diatrizoate meglumine and diatrizoate sodium, and Gastrografin (Schering AG, Berlin, Germany) was administered through a nasogastric tube into the stomach at the semi-Fowler position 4 hours before PEG placement. With the patients in supine position, fluoroscopy of the abdomen was performed, and the state of the transverse colon was confirmed before using the endoscope. Next, we observed the transverse colon and stomach after inserting an endoscope into the stomach. In Group B patients (109 cases; from October 2003 to February 2007), no diatrizoate meglumine and diatrizoate sodium was administered. The patients underwent PEG under fluoroscopy and were retrospectively evaluated using hospital charts and abdominal X-rays. Nutritional indicators were evaluated by blood sampling 3 days before gastrostomy. All patients underwent PEG

placement using the introducer's method with an introducer type kit (Create Medic Co., Yokohama, Japan) after gastropexy using Funada's gastropexy device (Create Medic Co., Yokohama, Japan) under fluoroscopy. We checked for misplacement of the PEG tube into the transverse colon or not and that a frequency of surgical gastrostomy.

### Statistical analysis

The age and nutritional conditions of the patients in each group were compared using the *t*-test. Gender, cerebrovascular disease, dementia, nutritional methods, and frequency of surgical gastrostomy in each group were compared using the chi-square test. Values are expressed as mean ± standard deviation, and a *p*-value < 0.05 was considered statistically significant. All statistical analyses were performed using SPSS version 20 software (SPSS Japan Inc., Tokyo, Japan).

## RESULTS

There were no significant differences between Group A and B with regards to gender and nutritional methods, but there were significant differences in age, cerebrovascular diseases, dementia, and serum albumin before the placement of PEG (Table 1).

In Group A, Gastrografin was observed in the transverse colon before insertion of the endoscope in 182 cases (78.4%), while Gastrografin was observed in the transverse colon only after inserting the endoscope in 94 cases (40.5%) (Figure 1). A total of 55 cases (23.7%) with both Gastrografin and gas in the transverse colon (Figure 2), and 77 cases (33.2%) had gas only in the transverse colon (Figure 3). A total of six cases had neither Gastrografin nor gas. In Group B, 49 cases (45.0%) had gas only in the transverse colon, and the remaining 60 cases (55.0%) had no gas in the transverse colon, and the transverse colon could not be recognized. There were significant differences between Group A and B as the cases who could not recognize the transverse colon ( $p < 0.0001$ ) (Table 2).

In Group A, 139 cases (59.9%) were constructed with clues of Gastrografin, 75 cases (32.3%) were conformed with clues of gas, five cases were constructed by finger palpation and transillumination, seven cases were conformed at a later by the surgical gastrostomy, and six cases were constructed at a later using the colonoscope (Figure 4). In Group B, 38 cases (34.8%) were conformed with clues of gas, 60 cases (55.1%) were constructed by finger palpation and transillumination, 10 cases were conformed at a later by surgical gastrostomy, and one case was constructed at a later using the colonoscope. There were significant differences between Group A and B as the cases who performed by the finger palpation and transillumination ( $p < 0.0001$ ), and those who underwent surgical gastrostomy ( $p = 0.0148$ ) (Table 3).

## DISCUSSION

The exact mechanism for formation of fistulous communication between the stomach and colon is unknown, but various theories have been postulated, especially in children where the complication is encountered more frequently. The five most popular theories are as follows: (1) Following introduction of the endoscope, air is insufflated in the stomach to facilitate transillumination. Although the stomach is mobile, the gastrocolic ligaments limit its rotation. In the paediatric population, these ligaments may be more rudimentary, allowing for rotation of the stomach<sup>[4]</sup>. (2) Adhesions from a previous laparotomy may tent the colon, and prohibit close apposition of the stomach to the anterior abdominal wall. The colon is closely juxtaposed to the

anterior abdominal wall, leading to subsequent erosion and fistulous communication<sup>[4,7,13]</sup>. (3) When the transverse colon is short, the colon is raised and easily moved to the anterior wall of the stomach<sup>[7,14]</sup>. (4) The transverse colon may be accidentally punctured when the PEG insertion site is too low at the mid-kidney level near the umbilicus due to gastropothesis<sup>[15]</sup>. (5) Patients with neurologic disorders tend to have abnormal posture and spinal deformity, which may contribute to abnormal positioning of the stomach, resulting in injury of other viscera during gastrostomy tube insertion<sup>[9,16]</sup>.

In the current study, we modified the previously described Gastrografin method for the prevention. Gastrografin was administered 4 hours before PEG placement, because it has been reported that water-soluble contrast generally reaches the right colon 4-6 hours after ingestion in cases without significant small bowel obstruction<sup>[17,18]</sup>. Distilled water was initially mixed, but it was difficult to distinguish under fluoroscopy, and so the undiluted solution was administered. The amount of Gastrografin was started at 80 mL, but 10 mL each was weight loss because we wanted to reduce the amount even a little. Since it was difficult to image the transverse colon at 30 mL, the final dose was 40 mL. As a result of adopting this method, the transverse colon with Gastrografin or gas images was observed in 226 cases (97.4%), and the transverse colon could not be observed in only six cases. A total of five cases underwent finger palpation and transillumination, and one was constructed using a colonoscope at a later date.

The number of patients that were changed to surgical gastrostomy was significantly decreased with the described method. In Group A, the transverse colon was raised due to colon puncture or mesenteric puncture (Figure 5), or the stomach was raised and was not present under the rib. In Group B, no gas image was observed in the transverse colon; thus, these cases were finally surgically constructed. When Gastrografin was administered, the gas image in the transverse colon became clear, even if only gas was admitted, and the transverse colon could be observed easily.

Furthermore, the frequency of finger palpation and transillumination test were also significantly reduced. Techniques using both transillumination and finger pressure as a guide to place the puncture site are useful for preventing this complication<sup>[7,15,19]</sup>. This method is basic, but the position of transverse colon can not be

determined completely.

Abdominal plain X-ray examination after 500 mL of air insufflation into the stomach is a useful method to determine the abdominal puncture point for PEG<sup>[20,21]</sup>; however, the position of the transverse colon cannot be determined completely. Although abdominal ultrasound examination under gastrostomy is useful to prevent colcutaneous fistula<sup>[22]</sup>, this method may not become apparent on the transverse colon. Computed tomography-guided PEG placement is an optional method for the estimation of intra-abdominal, anatomical orientations that may minimize the risk of complications<sup>[23,24]</sup>; however, CT scan cannot be use under gastrostomy. Another CT-guided PEG placement is useful under gastrostomy when an endoscope cannot pass through the stenosis or occlusion of pharynx due to head and neck cancer<sup>[25]</sup>, but the manipulation of gastrostomy is complicated, has a long procedure time, and required exposure to radiation. Therefore, although

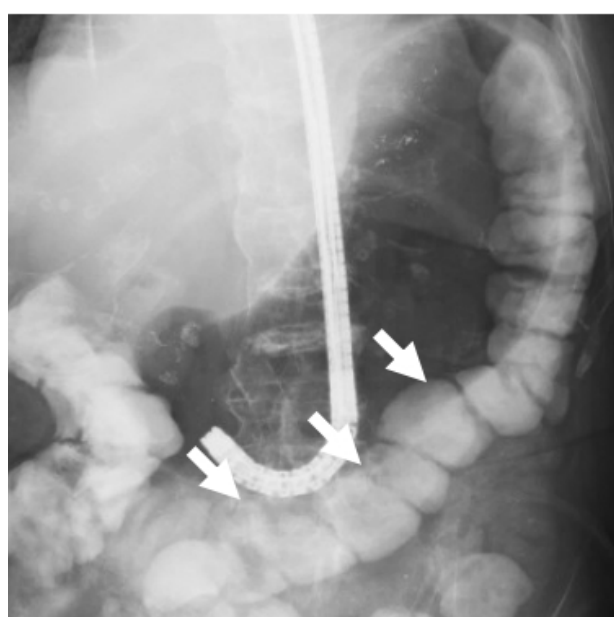


Figure 1 Introduction of Gastrografin into the transverse colon. Arrows show the Gastrografin in the transverse colon.

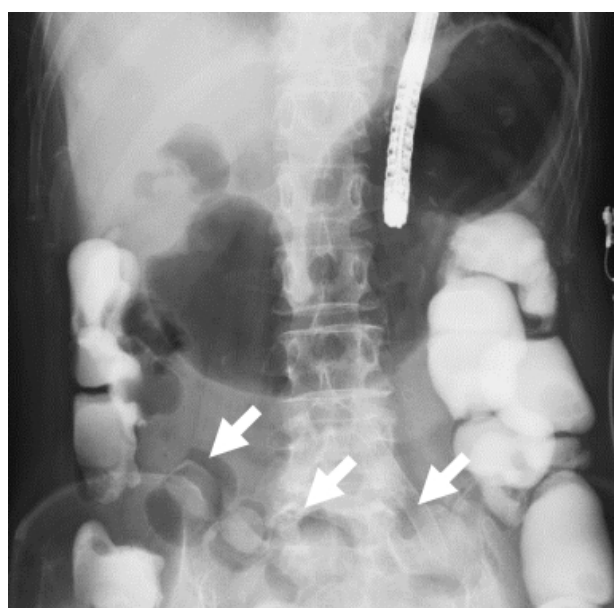


Figure 2 Introduction of Gastrografin and gas into the transverse colon. Arrows show both the Gastrografin and gas in the transverse colon.

Table 1 Comparisons of the pre-PEG patients between Group A and B.

Parameter	Group A (232 cases)	Group B (109 cases)	p value
Age (years)	84.1±9.0 (46-100)	81.6±9.3 (46-103)	0.011
Gender (male)	92 (39.7)	49 (45.0)	0.354
<b>Principle diseases</b>			
CVD	76 (32.8)	48 (44.0)	0.044
Dementia	88 (37.9)	26 (23.9)	0.010
<b>Nutritional methods</b>			
PN	121 (52.2)	69 (63.3)	0.053
EN	111 (47.8)	40 (36.7)	0.053
<b>Nutritional conditions</b>			
Serum albumin (g/dL)	3.1±0.4 (1.8-4.2)	3.3±0.5 (2.3-4.6)	0.006
Total cholesterol (mg/dL)	156.1±43.9 (49-363)	150.9±33.3 (70-247)	0.113
Cholinesterase (U/L)	179.9±69.9 (36-471)	190.4±67.5 (67-366)	0.095
Total lymphocyte (/μL)	1341.8±608.9 (276-6669)	1376.7±496.2 (387-3003)	0.287

CVD: cerebrovascular disease, PN: parenteral nutrition, EN: enteral nutrition, Data on age and nutritional conditions are demonstrated as mean±SD and a range. Numbers in parenthesis on gender, principle diseases, and nutritional methods are shown as percentage.

**Table 2** Comparisons of the condition of the transverse colon between Group A and B (post EGD).

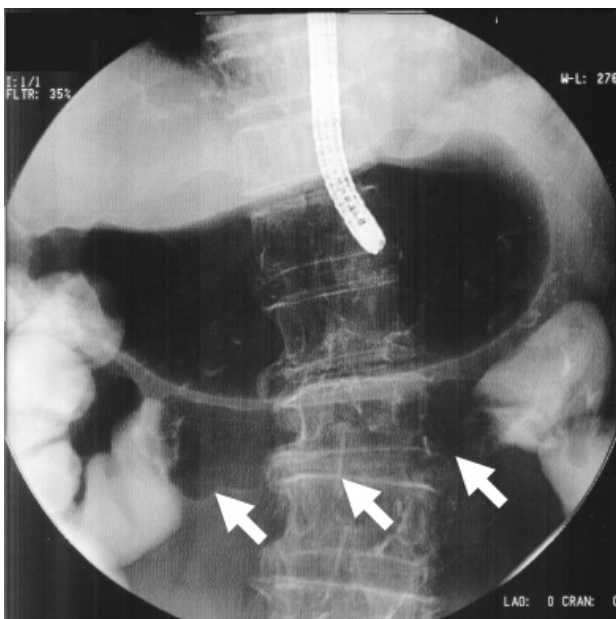
Parameter	Group A (232 cases)	Group B (109 cases)	p value
Cases with introduction of Gastrografin only into the transverse colon	94 (40.5)	-	-
Cases with introduction of both Gastrografin and gas into the transverse colon	55 (23.7)	-	-
Cases with introduction of gas only into the transverse colon	77 (33.2)	49 (45.0)	0.036
Cases with no introduction into the transverse colon	6 (2.6)	60 (55.0)	<0.0001

EGD:esophagogastroduodenoscope, Numbers in parenthesis on all of them are shown as percentage.

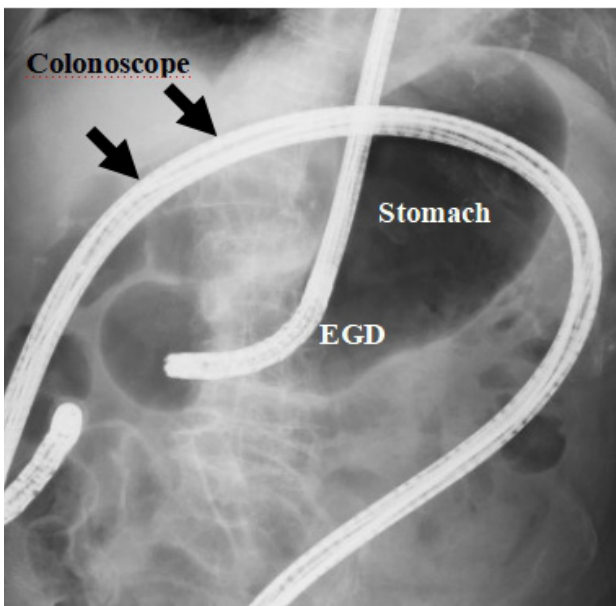
**Table 3** Comparisons of percutaneous endoscopic gastrostomy placement between Group A and B (post EGD).

Parameter	Group A (232 cases)	Group B (109 cases)	p value
Cases who received Gastrografin	139 (59.9)	-	-
Cases who received gas	75 (32.3)	38 (34.8)	0.643
Cases who received finger palpation and transillumination	5 (2.2)	60 (55.1)	<0.0001
Cases who received surgical gastrostomy	7 (3.0)	10 (9.2)	0.015
Cases who received EGD and CS	6 (2.6)	1 (0.9)	0.311

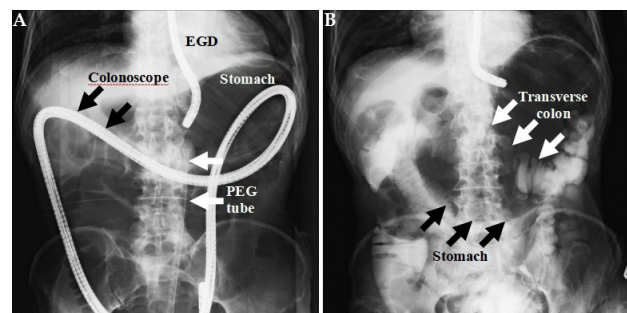
EGD:esophagogastroduodenoscope, CS:colonoscope, Numbers in parenthesis on all of them are shown as percentage.



**Figure 3** Introduction of gas into the transverse colon. Arrows show the gas in the transverse colon.



**Figure 5** An 89-year-old female underwent surgical gastrostomy because the transverse colon was positioned high behind the ribs.



**Figure 4** An 87-year-old male underwent PEG placement with use of a colonoscope [A (left)] due to the interposition of the transverse colon between the anterior abdominal and gastric walls [B (right)].

guidance by abdominal plain X-ray, ultrasound, and CT scan can be used selectively, they may have limited benefit. Another study suggested that an aspirating syringe filled with saline could be used to identify the intervening colon between the skin and the stomach if air bubbles appeared in the syringe prior to the endoscopic visualization of the needle in the gastric lumen<sup>[26]</sup>; however, this method is not necessarily safe.

## CONCLUSION

To decrease surgical gastrostomy, the use of Gastrografin into the stomach was safe, reliable, and cost effective for PEG tube placement and is recommended. However, as a disadvantage, this method is not possible in the endoscopic chamber without fluoroscopy.

## ACKNOWLEDGMENTS

**Guarantors of the article:** Hiromi Ono.

**Specific author contributions:** Acquisition of data: Ono. Analysis and interpretation of data: Ono, Yokoyama, Yoshida, Fukushima, Okamura, Aoki, and Nagashima. Drafting of the manuscript: Ono. Critical revision of the manuscript for important intellectual content: Asakage, Danjo, Hayashi, Nishihara, Shimizu, and Shimamura. Statistical analysis: Ono. Obtaining funding: Kawakami. Administrative, technical, or material support: Asakage, Shimizu, Shimamura, and Kusano. Study supervision: Asakage and Kusano. All authors had access to the study data and reviewed and approved the final manuscript.

**Financial support:** This study was supported in part by funds from the Seiwa Memorial Hospital, which paid for the Gastrografin and the nasogastric tube.

## REFERENCES

- Gauderer MW, Ponsky JL, Izant RJ. Gastrostomy without laparotomy: a percutaneous endoscopic technique. *J Pediatr Surg.* 1980; **15**(6): 872-5. [PMID: 6780678]; [DOI: 10.1016/s0022-3468(80)80296-x]
- Mamel JJ. Percutaneous endoscopic gastrostomy. *Am J Gastroenterol.* 1989; **84**(7): 703-10. [PMID: 2500845]
- Saltzberg DM, Anand K, Juvan P, Joffe I. Colocutaneous fistula: An unusual complication of percutaneous endoscopic gastrostomy. *J Parenter Enteral Nutr.* 1987; **11**(1): 86-7. [PMID: 2950249]; [DOI: 10.1177/014860718701100186]
- Stefan MM, Holcomb GW, Ross AJ. Cologastric fistula as a complication of percutaneous endoscopic gastrostomy. *J Parenter Enteral Nutr.* 1989; **13**(5): 554-6. [PMID: 2607593]; [DOI: 10.1177/0148607189013005554]
- Lee HJ, Choung RS, Park MS, Pyo JH, Kim SY, Hyun JJ, Jung SW, Koo JS, Lee SW, Choi JH. Two cases of uncommon complication during percutaneous endoscopic gastrostomy tube replacement and treatment. *Korean J Gastroenterol.* 2014; **63**(2): 120-4. [PMID: 24561699]; [DOI: 10.4166/kjg.2014.63.2.120]
- Huang SY, Levine MS, Raper SE. Gastrocolic fistula with migration of feeding tube into transverse colon as a complication of percutaneous endoscopic gastrostomy. *Am J Roentgenol.* 2005; **184**(3): S65-6. [PMID: 15728025]; [DOI: 10.2214/ajr.184.3\_supplement.01840s65]
- Friedmann R, Feldman H, Sonnenblick M. Misplacement of percutaneously inserted gastrostomy tube into the colon: report of 6 cases and review of the literature. *J Parenter Enteral Nutr.* 2007; **31**(6): 469-76. [PMID: 17947601]; [DOI: 10.1177/0148607107031006469]
- Larson DE, Burton DD, Schroeder KW, DiMugno EP. Percutaneous endoscopic gastrostomy. Indications, success, complications, and mortality in 314 consecutive patients. *Gastroenterol.* 1987; **93**(1): 48-52. [PMID: 3108063]
- Okutani D, Kotani K, Makihara S. A case of gastrocolocutaneous fistula as a complication of percutaneous endoscopic gastrostomy. *Acta Med Okayama.* 2008; **62**(2): 135-8. [PMID: 18464890]; [DOI: 10.18926/AMO/30958]
- Patwardhan N, McHugh K, Drake D, Spitz L. Gastroenteric fistula complicating percutaneous endoscopic gastrostomy. *J Pediatr Surg.* 2004; **39**(4): 561-4. [PMID: 15065028]; [DOI: 10.1016/j.jpedsurg.2003.12.018]
- Khattak IU, Kimber C, Kiely EM, Spitz L. Percutaneous endoscopic gastrostomy in paediatric practice: complications and outcome. *J Pediatr Surg.* 1998; **33**(1): 67-72. [PMID: 9473103]; [DOI: 10.1016/s0022-3468(98)90364-5]
- Kinoshita Y, Udagawa H, Kajiyama Y, Tsutsumi K, Ueno M, Nakamura T, Watanabe G, Akiyama H. Cologastric fistula and colonic perforation as a complication of percutaneous endoscopic gastrostomy. *Surg Laparosc Endosc Percutan Tech.* 1999; **9**(3): 220-2. [PMID: 10804006]
- Yamazaki T, Sakai Y, Hatakeyama K, Hoshiyama Y. Colocutaneous fistula after percutaneous endoscopic gastrostomy in a remnant stomach. *Surg Endosc.* 1999; **13**(3): 280-2. [PMID: 10064765]; [DOI: 10.1007/s004649900964]
- Lee J, Kim J, Kim HI, Oh CR, Choi S, Noh S, Na HK, Jung HY. Gastrocolocutaneous fistula: An unusual case of gastrostomy tube malfunction with diarrhea. *Clin Endosc.* 2018; **51**(2): 196-200. [PMID: 28854775]; [DOI: 10.5946/ce.2017.062]
- Lohiya GS, Tan-Figueroa L, Krishna V. Intermittent diarrhea as a delayed presentation of percutaneous endoscopic gastrostomy (PEG)-associated fistula. *J Am Board Fam Med.* 2010; **23**(5): 681-4. [PMID: 20823365]; [DOI: 10.3122/jabfm.2010.05.090268]
- Croaker GDH, Najmaldin AS. Laparoscopically assisted percutaneous endoscopic gastrostomy. *Pediatr Surg Int.* 1997; **12**(2/3): 130-1. [PMID: 9069213]
- Chung CC, Meng WC, Yu SC, Leung KL, Lau WY, Li AK. A prospective study on the use of water-soluble contrast follow-through radiology in the management of small bowel obstruction. *Aust N Z J Surg.* 1996; **66**(9): 598-601. [PMID: 8859158]; [DOI: 10.1111/j.1445-2197.1996.tb00827.x]
- Blackmon S, Lucius C, Wilson JP, Duncan T, Wilson R, Mason EM, Ramshaw B. The use of water-soluble contrast in evaluating clinically equivocal small bowel obstruction. *Am Surg.* 2000; **66**(3): 238-42. [PMID: 10759192]
- Gauderer MW. Percutaneous endoscopic gastrostomy-20 years later: a historical perspective. *J Pediatr Surg.* 2001; **36**(1): 217-9. [PMID: 11150469]; [DOI: 10.1053/jpsu.2001.20058]
- Chang WK, Hsieh TY. Safety of percutaneous endoscopic gastrostomy in high-risk patients. *J Gastroenterol Hepatol.* 2013; **28**(Suppl 4): 118-22. [PMID: 24251717]; [DOI: 10.1111/jgh.12300]
- Chang WK, McClave SA, Yu CY, Huang HH, Chao YC. Positioning a safe gastric puncture point before percutaneous endoscopic gastrostomy. *Int J Clin Pract.* 2007; **61**(7): 1121-5. [PMID: 17343669]; [DOI: 10.1111/j.1742-1241.2006.01106.x]
- Shukla PA, Kolber MK, Tapnio R, Zybulewski A, Kumar A, Patel RI. Safety and feasibility of ultrasound-guided gastric access for percutaneous transabdominal gastrostomy tube placement. *Gastroenterol Res.* 2019; **12**(3): 115-9. [PMID: 31236151]; [DOI: 10.14740/gr1136]
- Kawashima K, Adachi K, Onishi K, Fukuda K, Kazumori H, Ohno Y, Katoh T, Sonoyama H, Tada Y, Kusunoki R, Oka A, Fukuba N, Oshima N, Yuki T, Ishihara S, Kinoshita Y. Usefulness of computed tomography with air insufflation of the stomach prior to percutaneous endoscopic gastrostomy procedure. *J Clin Biochem Nutr.* 2016; **58**(3): 246-50. [PMID: 27257351]; [DOI: 10.3164/jcbn.15-145]
- Kato K, Iwasaki Y, Onodera K, Matsuda M, Higuchi M, Kato K, Kato Y, Taniguchi M, Furukawa H. Laparoscopic-assisted percutaneous endoscopic gastrostomy combined with CT-GC. *J Invest Surg.* 2017; **30**(3): 193-200. [PMID: 27700181]; [DOI: 10.1080/08941939.2016.1232451]
- Tyng CJ, Santos EFV, Guerra LFA, Bitencourt AGV, Barbosa PNVP, Chojniak R. Computed tomography-guided percutaneous gastrostomy: initial experience at a cancer center. *Radiol Bras.* 2017; **50**(2): 109-14. [PMID: 28428654]; [DOI: 10.1590/0100-3984.2015.0219]
- Foutch PG, Talbert GA, Waring JP, Sanowski RA. Percutaneous endoscopic gastrostomy in patients with prior abdominal surgery: virtues of the safe tract. *Am J Gastroenterol.* 1988; **83**(2): 147-50. [PMID: 3124605]