

A Case of Jejunal Lipomatosis Diagnosed with Double-balloon Enteroscopy

Hyung-Keun Kim, Young-Seok Cho, Sung-Soo Kim, Su-Yeon Lee, Seung-Kyoung Kim, Eun-Sun Kim, Yun-Ji Kim, Hiun-Suk Chae

Hyung-Keun Kim, Young-Seok Cho, Sung-Soo Kim, Su-Yeon Lee, Seung-Kyoung Kim, Eun-Sun Kim, Yun-Ji Kim, Hiun-Suk Chae, Division of Gastroenterology, Department of Internal Medicine, The Catholic University of Korea College of Medicine and Uijeongbu St. Mary's Hospital, 65-1, Guemo-dong, Uijeongbu, Kyunggi-do, 480-717, South Korea

Correspondence to: Hiun-Suk Chae, MD, PhD, Division of Gastroenterology, Department of Internal Medicine, The Catholic University of Korea College of Medicine and Uijeongbu St. Mary's Hospital, 65-1, Guemo-dong, Uijeongbu, Kyunggi-do, 480-717, South Korea. chs@catholic.ac.kr

Telephone: +082-31-820-3019 Fax: +082-31-847-2719

Received: June 8, 2012 Revised: November 2, 2012

Accepted: October 18, 2012

Published online: January 21, 2013

Key words: Jejunal lipomatosis; Double-balloon enteroscopy

Kim HK, Cho YS, Kim SS, Lee SY, Kim SK, Kim ES, Kim YJ, Chae HS. A Case of Jejunal Lipomatosis Diagnosed with Double-balloon Enteroscopy. *Journal of Gastroenterology and Hepatology Research* 2013; 2(1): 381-383 Available from: URL: <http://www.ghrnet.org/index./joghr/>

INTRODUCTION

Lipomas of the gastrointestinal tract are relatively rare benign tumors, one-third of which are located in the small intestine^[1]. The term "lipomatosis" has been used to describe the presence of numerous circumscribed lipomas in the intestine^[2]. However, most cases involve a solitary lipoma, and cases of multiple lipomatosis are very rare. To date, about 30 cases of intestinal or jejunal lipomatosis have been reported^[1-13], but as far as we know, only one recently reported case was diagnosed using double-balloon enteroscopy (DBE)^[3].

Here, we describe a case of jejunal lipomatosis, causing intermittent abdominal pain, that was diagnosed using DBE. This is the second report of jejunal lipomatosis diagnosed using DBE.

CASE REPORT

A 50-year-old man was referred with intermittent abdominal pain of three months' duration. The pain was mainly located in the left upper abdominal quadrant and was often aggravated by meals. He had no history of melena or intestinal obstructive symptom. He had no remarkable family history or past medical history.

Physical and laboratory examinations produced normal results. Abdominal computed tomography (CT) revealed large amounts of fatty infiltration involving the jejunum and mesentery (Figure 1). A barium study of the small bowel showed multiple, variably sized polypoid lesions, extending from the proximal jejunum to the distal jejunum (Figure 2).

We used DBE to diagnose these lesions endoscopically and pathologically, inserting the double-balloon enteroscope (EN-450P5/20, FUJIFILM Corporation, Tokyo, Japan) via the oral route. DBE revealed multiple, variably sized, submucosal tumors in the jejunum, with smooth yellowish surfaces (Figure 3). When compressed with biopsy forceps, these submucosal tumors had a soft consistency, with mucosal

ABSTRACT

A 50-year-old man was referred with intermittent abdominal pain of three months' duration. He had no remarkable family history or past medical history. Physical and laboratory examinations produced normal results. Abdominal computed tomography revealed large amounts of fatty infiltration involving the jejunum and mesentery. A barium study of the small bowel showed multiple, variably sized polypoid lesions, extending from the proximal jejunum to the distal jejunum. We used double-balloon enteroscopy to diagnose these lesions endoscopically and pathologically, via the oral route. Double-balloon enteroscopy revealed multiple, variably sized, submucosal tumors in the jejunum, with smooth yellowish surfaces. These submucosal tumors had a soft consistency, with mucosal indentation, which constitutes the so-called "cushion sign". Histopathology showed no definite adipose tissue in the submucosal layer. However, the patient was diagnosed clinically with jejunal lipomatosis according to the results of the examinations described above, particularly the endoscopic findings. His abdominal pain was improved with conservative treatment, and the patient is currently being followed regularly in our outpatient clinic. In conclusion, this case highlights the intraluminal endoscopic characteristics of jejunal lipomatosis when double-balloon enteroscopy is used. Here, we present a case of jejunal lipomatosis diagnosed with double-balloon enteroscopy.

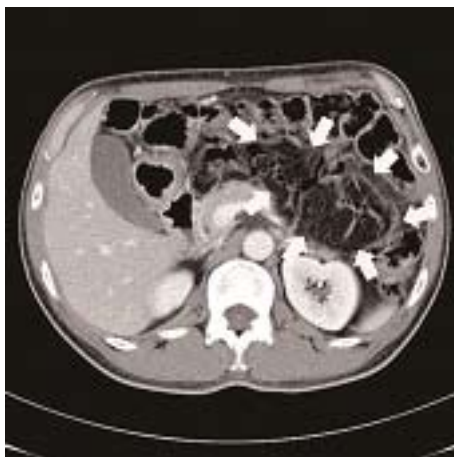

Figure 1 Abdominal computed tomography showed large amounts of fatty infiltration (white arrows) involving the jejunum and mesentery.

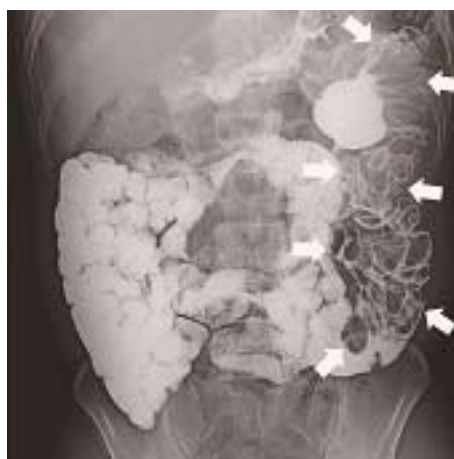

Figure 2 A barium study of the small bowel showed multiple, variably sized, polypoid lesions (white arrows) extending from the proximal jejunum to the distal jejunum.

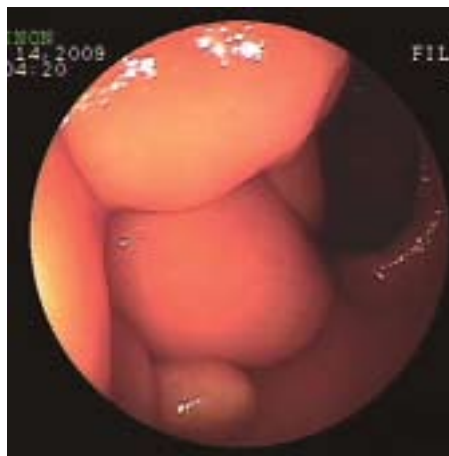


Figure 3 Double-balloon enteroscopic examination demonstrated multiple, variably sized, submucosal tumors with smooth, yellowish surfaces in the jejunum.

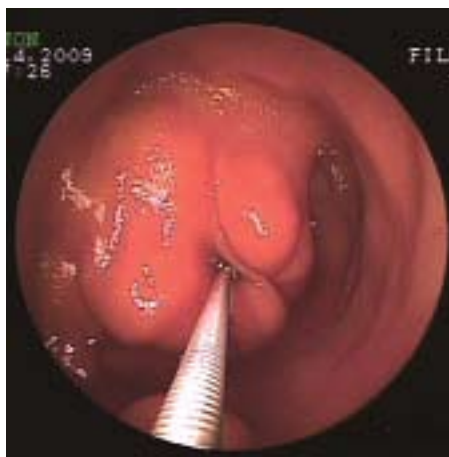

Figure 4 When compressed with biopsy forceps during the double-balloon enteroscopic examination, these submucosal tumors had a soft consistency, with mucosal indentation, the so-called “cushion sign.”

indentation, which constitutes the so-called “cushion sign” (Figure 4). The endoscopic diagnosis was multiple jejunal lipomatosis. Several biopsies of these lesions were taken for pathological diagnosis. The double-balloon enteroscope could be passed through the entire jejunum.

Histopathology showed some submucosal muscle bundles and vascular proliferation, but no definite adipose tissue in the submucosal layer. We recommended the surgery to this patient as a purpose of definite diagnosis and simultaneous therapy, but he refused it. Then, his abdominal pain was improved with conservative treatment. Therefore, the patient was diagnosed clinically with jejunal lipomatosis according to the results of the examinations described above, particularly the endoscopic findings and the patient is currently being followed regularly in our outpatient clinic.

DISCUSSION

We have reported a case of jejunal lipomatosis diagnosed using DBE. In this patient, DBE demonstrated multiple, variably sized, submucosal tumors in the jejunum, which had smooth, yellowish surfaces, a soft consistency, and the “cushion sign,” which are characteristic of lipoma. Therefore, although abdominal CT and a barium study suggested jejunal lipomatosis and a biopsy performed using DBE could not demonstrate a lipomatotic pathology, the diagnosis of jejunal lipomatosis was actually confirmed by the characteristic intraluminal endoscopic characteristics of lipomatosis, detected using DBE.

In a review of 23 cases, the mean age of patients with intestinal lipomatosis was about 50 years and no sex-based bias in its occurrence was observed^[4]. The site of lipomatosis usually included the ileum: the ileum alone in nine cases (39%), the jejunum and ileum in nine cases (39%), and the jejunum alone in three cases (13%)^[4]. However, a patient with lipomatosis involving the stomach, duodenum, jejunum, and ileum has recently been reported^[5].

Intestinal lipomatosis can remain asymptomatic^[6], but the most frequent presenting symptom is abdominal pain attributed to intestinal obstruction, such as intussusception^[3,7], or volvulus^[2]. The cause of the abdominal pain in our patient, who had no intestinal obstruction, might be attributable to functional obstruction after meals. Melena usually occurs as a result of the ulceration of the lipoma surface caused by either an intussusception, torsion, gangrene, or simple erosion^[4,8]. Chronic diarrhea and suspected malabsorption syndrome have been reported as presenting symptoms of intestinal lipomatosis^[9]. The most common comorbid disease of intestinal lipomatosis is diverticulosis, and eight of the previously reported 23 patients had concurrent diverticulosis^[4]. It is probable that intestinal lipomatosis plays a contributory role in the genesis of these diverticula^[10]. One patient has been reported with simultaneous osteomalacic myopathy attributed to malabsorption^[11], and another with macrodactylia fibrolipomatosis^[9]. Some patients with lipomatosis have a familial history suggesting autosomal dominant inheritance, and hypercholesterolemia is also often reported^[4]. However, our patient

displayed neither of these traits.

The diagnosis of intestinal lipomatosis can be made using a barium study, which is particularly useful in diagnosing an intussusception. MRI or CT can also effectively distinguish lipomatosis from intestinal polyps and other submucosal tumors because lipomatotic lesions appear as radiolucent fatty dense masses on CT, like normal abdominal fat^[6]. As in a recently reported case^[3] and our patient, DBE can identify the characteristic endoscopic signs of intestinal lipomatosis if there is no contraindication for DBE, such as bowel strangulation. In our patient, a biopsy performed using DBE provided no definitive pathological diagnostic clue. However, this problem might not be attributable to the technique of biopsy using DBE, but might have arisen from the characteristics of this lesion. Generally, biopsy tissues procured with normal biopsy forceps do not include enough submucosal tissue to diagnose a submucosal lesion. There are also limitations on the instruments used in a DBE examination. For example, certain instruments, such as jumbo biopsy forceps, are not yet available for DBE. In the first reported case of lipomatosis diagnosed using DBE, no biopsy was performed during the DBE examination and surgical resection was performed to prevent a recurrence of intussusception^[3]. Finally, the pathological diagnosis was confirmed with resection, by demonstrating multiple lipomas containing adipose tissue in the submucosa.

It has been suggested that lipomatosis might be hamartomatous because some neural bundles have been observed in lipomas^[1]. However, there is no satisfactory explanation for the etiology of intestinal lipomatosis. Histopathologically, intestinal lipomatosis is mainly located in the submucosa and serosa, with the preservation of the muscularis propria^[1,12,13], but a case that involved the muscularis propria as well as the submucosa has been reported^[4].

If intestinal lipomatosis is confined to a segment of the intestine, surgical resection of the involved segment is the most effective treatment. However, there is no consensus about the treatment of patients with multiple lipomatosis involving a large segment of the gut^[1]. Moreover, if the patient improves with conservative treatment, like our patient, or has no symptoms, regular follow-up should be considered^[5,6].

In conclusion, this case highlights the intraluminal endoscopic characteristics of jejunal lipomatosis when DBE is used. To improve the pathological diagnosis as well as the endoscopic diagnosis with a DBE examination, various instruments, such as biopsy forceps, for use in DBE examinations must be developed.

REFERENCES

- 1 Climie ARW, Wylin RF. Small intestinal lipomatosis. *Arch Pathol Lab Med* 1981; **105**: 40-42
- 2 Tani T, Abe H, Tsukada H, Kodama M. Lipomatosis of the ileum with volvulus: report of a case. *Surg Today* 1998; **28**: 640-642
- 3 Lee BJ, Park JJ, Joo MK, Kim JH, Yeon JE, Kim JS, Chun HJ, Byun KS, Choi JH, Kim CD, Bak YT, Jang YJ, Mok YJ. A case of small-bowel intussusception caused by intestinal lipomatosis: preoperative diagnosis and reduction of intussusception with double-balloon enteroscopy. *Gastrointest Endosc* 2010; **71**: 1329-1332
- 4 Yakabe S, Muranaka T, Sumii T, Takeshita M, Yamashita T, Tsuruta S, Saku M, Yoshida K. Jejunal lipomatosis with diverticulosis: report of a case. *Surg Today* 1998; **28**: 846-849
- 5 Suárez Moreno RM, Hernández Ramírez DA, Madrazo Navarro M, Salazar Lozano CR, Martínez Gen R. Multiple intestinal lipomatosis. Case report. *Cir Cir* 2010; **78**: 163-165
- 6 Omson MJ, Stephens DH, Carlson HC. CT recognition of intestinal lipomatosis. *AJR Am J Roentgenol* 1985; **144**: 313-314
- 7 Shenoy R, Rodrigues G, Gospashetty M, Kannaiyan L, Rao S. Segmental jejunal lipomatosis—a rare cause of intestinal obstruction. *Yonsei Med J* 2003; **44**: 59-61
- 8 Roberts JM, Kelley HD. Intraluminal jejunal and ileal hemorrhage and obstructing lesions. *Am Surg* 1967; **33**: 564-568
- 9 Mazziotti S, Salamone I, Vinci S, Pandolfo A. Macrodactylia fibrolipomatosis associated with multiple small-bowel lipomas. *AJR Am J Roentgenol* 2006; **186**: 1195-1196
- 10 Ranchod M, French TJ, Novis BH, Bank S, Marks IN. Diffuse nodular lipomatosis and diverticulosis of the small intestine. *Gastroenterology* 1972; **63**: 667-710
- 11 Palmucci L, Bertolotto A, Doriguzzi C, Mongini T, Coda R. Osteomalacic myopathy in a case of diffuse nodular lipomatosis of the small bowel. *Acta Neurol Belg* 1982; **82**: 65-71
- 12 Neilson D, Wilkinson N, Magell J. Case of simultaneous diverticulosis, lipomatosis and volvulus of the small intestine. *Br J Surg* 1990; **77**: 105
- 13 Duun S. Lipomatosis of the small intestine. *Eur J Surg* 1994; **160**: 311-312

Peer reviewers: Yosuke Tsuji, Department of Gastroenterology, NTT Medical Center Tokyo, 5-9-22, Shinagawa-ku, Tokyo, 141-8625, Japan; Robert Ehehalt, MD, Professor, Internal Medicine IV, University hospital Heidelberg, INF 410, Heidelberg, 69120, Germany; Eva Intagliata, MD, Department of Surgery, University of Catania, casella postale 226, Augusta, 96011, Italy.