

Journal of *Gastroenterology and Hepatology Research*

Online Submissions: <http://www.ghrnet.org/index./joghr/>
doi: 10.6051/j.issn.2224-3992.2012.02.016

Journal of GHR 2012 February 21 1(1): 5-10
ISSN 2224-3992 (print) ISSN 2224-6509 (online)

ORIGINAL ARTICLE

Comparison of the Imaging of Ultrathin Transnasal Endoscopy and Transoral Conventional Endoscopy in the Same Patient with Early Esophageal Cancer

Naondo Sohara, Satoru Kakizaki, Yasuhiro Onozato, Haruhisa Iizuka, Hiroshi Ishihara, Shinichi Okamura, Hideaki Itoh, Masatomo Mori

Naondo Sohara, Yasuhiro Onozato, Haruhisa Iizuka, Hiroshi Ishihara, Department of Endoscopy and Endoscopic Surgery, Shirakawa Clinic, Maebashi, Gunma 371-0051, Japan
Satoru Kakizaki, Shinichi Okamura, Masatomo Mori, Department of Medicine and Molecular Science, Gunma University Graduate School of Medicine, Maebashi, Gunma 371-8511, Japan

Hideaki Itoh, Department of Pathology, Maebashi Red Cross Hospital, Maebashi, Gunma 371-0014, Japan

Correspondence to: Satoru Kakizaki, MD, PhD, Department of Medicine and Molecular Science, Gunma University Graduate School of Medicine, 3-39-15 Showa-machi, Maebashi, Gunma 371-8511, Japan. kakizaki@showa.gunma-u.ac.jp

Telephone: +81-27-220-8127 Fax: +81-27-220-8136

Received: November 1, 2011 Revised: December 25, 2011

Accepted: January 19, 2012

Published online: February 21, 2012

© 2012 Thomson research. All rights reserved.

Keywords: Early esophageal cancer; Ultrathin transnasal endoscopy; Narrow-band imaging

Sohara N, Kakizaki S, Onozato Y, Iizuka H, Ishihara H, Okamura S, Itoh H, Mori M. Comparison of the Imaging of Ultrathin Transnasal Endoscopy and Transoral Conventional Endoscopy in the Same Patient with Early Esophageal Cancer. *Journal of Gastroenterology and Hepatology Research* 2012; 1(1): 5-10
Available from: URL: <http://www.ghrnet.org/index./joghr/>

INTRODUCTION

Since the report by Shaker^[1] in 1994, transnasal esophagogastroduodenoscopy has been reported worldwide as one technique that facilitates comfortable endoscopy without the requirement for sedative drugs. Recent technological advances have led to the further miniaturization of the charge-coupled device (CCD) allowing the production of thinner endoscopes^[1]. Ultrathin transnasal endoscopy (UT) has been increasingly performed in health check-up institutions in Japan, in patients that anticipate comfortable unsedated upper gastrointestinal endoscopy. Several studies have demonstrated that the tolerance and acceptance of UT are better than those for transoral conventional endoscopy (CO) in unsedated patients^[2-5]. Furthermore, several studies have demonstrated that UT is less stressful on the cardiovascular system than CO^[2, 5, 6]. However, UT has several drawbacks, such as low image resolution, low luminous intensity and lack of magnification^[7]. Using UT, several studies reported the detection rate of gastric cancer in Japan, which was comparable to the rate using standard scopes^[8, 9]. However, Hayashi *et al*^[10] reported that the diagnostic utility of UT may be lower than for CO for screening early gastric cancers, and that the disadvantages of UT should be carefully considered when physicians are evaluating patients.

Therefore, the diagnostic utility of UT for early gastric cancers remains controversial. UT for screening early esophageal cancers (EEC) can be more difficult than detecting early gastric cancers. A higher imaging quality may be required to detect EEC. Furthermore, the early diagnosis of esophageal cancers is an important determinant of outcome and quality of life. As a result, using UT is controversial in screening for EEC.

It is well known that CO is superior to UT in imaging quality^[7]. However, few studies have performed the comparative analyses between CO and UT using quantitative imaging tools. It is important to analyze the imaging methods for their subjectivity

ABSTRACT

AIM: The diagnostic value of ultrathin transnasal endoscopy (UT) for early esophageal cancers (EEC) remains controversial. To evaluate the diagnostic utility of UT in detecting EEC, we compared the imaging of UT and transoral conventional endoscopy (CO) in the same patient.

METHODS: Nineteen consecutive patients with 20 lesions were enrolled to this study. The endoscopic findings, sensitivity and accuracy in the detection of mucosal findings, and the sensitivity of diagnosis were compared between UT and CO in the same subjects. The image density from each procedure was quantified and compared with the ImageJ software program.

RESULTS: All 20 lesions could be detected using UT. Twelve of 20 lesions (60.0%) could be diagnosed as cancerous by UT. The sensitivities of the mucosal findings such as the fur white coat, the vessel irregularity and loss of glossy identified by CO were superior to those obtained by UT. A combined examination by narrow-band imaging (NBI) yielded the same detection rate of the brownish area. The quantitative analyses revealed that combination diagnosis with NBI was superior to optical imaging alone. There were no differences in the calculated densities between UT and CO, thus demonstrating that UT was not inferior to CO for detecting these lesions.

CONCLUSIONS: The inherent shortcomings of UT included its poor resolution, lower light source, and lack of magnification. The imaging qualities and diagnostic accuracy of UT in EEC were lower than those of CO. However, the combination of UT with NBI increased the sensitivity, and UT with NBI could detect EEC.

and their quantitative qualities. We herein evaluated the imaging differences between UT and CO in the calculated densities using the ImageJ software program. The present study evaluated the detecting utility of UT in comparison to CO in order to screen EEC.

PATIENTS AND METHODS

Patients and design

At our hospital, nineteen patients with twenty lesions of EEC were treated by endoscopic submucosal dissection (ESD) from November 2007 to October 2009. All 19 patients (17 male subjects, 2 female subjects) underwent UT and CO. Three gastrointestinal endoscopists who had 21 years, 20 years and 17 years of experience in gastrointestinal endoscopy respectively, compared the images. One of 3 endoscopists performed each procedure, but all 3 endoscopists attended each procedure and saw the images live. Furthermore, 3 endoscopists reviewed both the still images and video images. The detection ability, accuracy of diagnosis, and mucosal findings were decided by the consensus of the 3 gastrointestinal endoscopists. We classified the degrees of diagnostic utility of UT as distinct, indistinct and undetectable. Distinct; we were able to detect the lesion and accurately assess its malignancy. Indistinct; we could detect the lesion but were unable to accurately assess its malignancy. Undetectable; we could not detect the lesion by UT. The location of the lesion was classified into the upper, middle, and lower third of the esophagus. The location classification according to a clockwise definition was also assessed. Dimethicone (100 mg), pronase (20 000 units), and sodium bicarbonate (1g) dissolved in 30 ml of drinking water were orally administered 15 minutes before endoscopy to remove mucous obstacles. All patients provided written informed consent before receiving the examination. This study was approved by the institutional ethical committee (No., SC2007/002; date, 14 October, 2007).

Ultrathin transnasal endoscopy and narrow-band imaging (NBI)

UT was carried out with an Olympus GIF-XP260N and CO was performed using an Olympus GIF-H260Z (Olympus Medical Systems Corp., Tokyo, Japan). The outer diameter of the GIF-XP260N insertion tube was 5.0 mm and the width of vision was 120°. The tip flexion capability was 210° up, 90° down and 100° right/left. The outer diameter of the insertion tube of GIF-H260Z was 10.8 mm and the width of vision was 140°. The tip flexion capability was same as GIF-XP260N. We used the Evis Lucera Spectrum video imaging system (Olympus) for narrow-band imaging (NBI). The neoplastic lesion was defined as the area that appeared brownish under NBI and was equated to the area of microvascular proliferation in the lesion^[11-15]. We carried out UT with white light, which was followed by examination with UT with NBI, CO with white light, CO with NBI, and CO with lugol chromoendoscopy, prior to treatment with ESD. Lugol chromoendoscopy was as follows: through a washing pipe that was 2 mm in outer diameter (PW-6P-1; Olympus), 20 to 30 ml of 3% Lugol solution and sprayed uniformly over the esophageal mucosa. Mucosal findings were assessed by the following five categories: redness, fur white coat, mucosal irregularity, vessel irregularity and loss of glossy appearance. Representative endoscopic imaging of mucosal findings is shown in Figure 1.

Histology

Biopsy samples and resected specimens after ESD were obtained for histological evaluation by an experienced pathologist (H.I). The diagnosis and classifications were in accordance with the Japan Esophageal Society^[16].

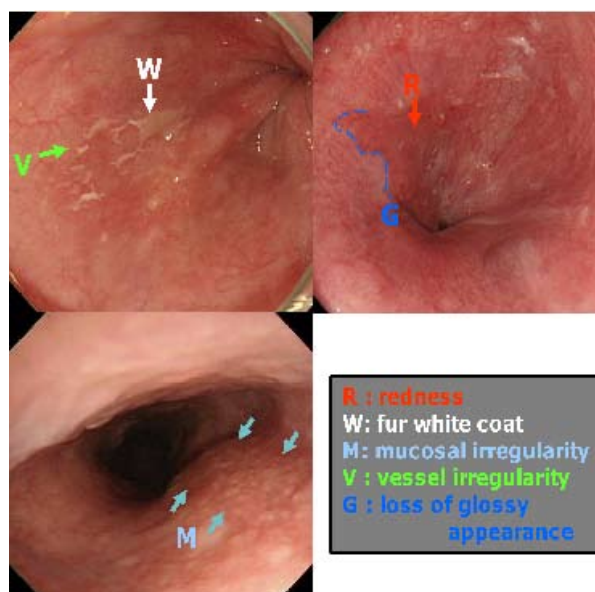


Figure 1 Representative endoscopic imaging of mucosal findings. Mucosal findings were assessed by the following five categories: redness (R), fur white coat (W), mucosal irregularity (M), vessel irregularity (V) and loss of glossy appearance (G).

Quantitative analyses of endoscopic findings

The densities were measured using the ImageJ software program (National Institutes of Health, MD, USA). ImageJ software recognizes black as 1 and white as 255. Other colors indicated a gradient numerical parameter between 1 and 255. Briefly, the colors resembling to black show a low score and colors that resemble white show a higher score. As shown in Figure 2, endoscopic films obtained during the UT and CO with white-light or NBI were scanned and measured using a computer graphics software program. The density ratios were calculated and indicated as percentile of: $-(1 - \text{density of the tumor lesion} / \text{density of surrounding normal mucosa}) \times 100\%$.

Statistical analysis

The results are presented as the mean \pm SD for continuous variables. Fisher's exact probability test for frequency tables was used for the statistical analyses. Distributions of continuous variables were analyzed using the Mann-Whitney *U* test. *P*-values of less than 0.05 were considered to be statistically significant.

RESULTS

Clinical characteristics

The clinical characteristics of the treated patients are shown in Table 1. Tobacco smoking (16/19, 84.2%), and alcohol consumption (16/19, 84.2%) were prevalent behaviors. According to the tumor location, 14 of 20 lesions (70.0%) were located at the middle third of the esophagus, and 6 lesions (30.0%) were located at the lower third of esophagus. According to the tumor size, the mean longitudinal diameter of the lesions was 23.7 ± 7.9 mm (range 8-38 mm). We divided the tumors into four categories on the basis of their size: ≤ 10 mm (1 lesions), 11-20 mm (3 lesions), 21-30 mm (10 lesions), and ≥ 31 mm (6 lesions). The macroscopic types of lesions included the elevated type (types I and 0-IIa; 3 lesions), the flat type (type 0-IIb; 13 lesions), and the superficial depressed type (type 0-IIc; 4 lesions). All lesions were squamous cell carcinoma according to the histological analyses. According to the tumor depth, eleven (55.0%) tumors were classified as T1a-epithelium (T1a-EP), five (25.0%) were classified as T1a-lamina propria mucosae (T1a-LPM), and four (20.0%) were

classified as T1a-mucularis mucosae (T1a-MM)^[16].

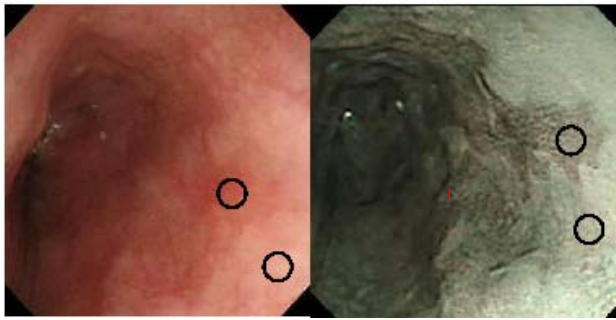


Figure 2 The quantitative analyses methods of endoscopic findings.

The densities of the images were measured using the ImageJ software program (National Institutes of Health, MD, USA). ImageJ software recognizes black as 1 and white as 255. Other colors lay along a numerical parameter gradient between 1 and 255. Endoscopic films obtained during the ultrathin transnasal endoscopy and conventional transoral endoscopy with white light or NBI were scanned and measured using a computer graphic software program. The density within the circle was calculated and was indicated as a number between 1 and 255.

Table 1 Clinical features of patients with early esophageal cancer.

Clinical characteristic		20 lesions with 19 patients
Age (years)	Mean ± SD (range)	67.9 ± 6.8 (55-81)
Sex	Male/Female	17/2
Smoking		16/19 (84.2 %)
Alcohol		16/19 (84.2 %)
Both smoking and alcohol		15/19 (78.9 %)
Location	lower/middle/upper	6/14/0
Longitudinal diameter of the lesions	Mean ± SD (range)	23.7 ± 7.9 (8-38)
	≤10 mm	1 lesion
	11-20 mm	3 lesions
	21-30 mm	10 lesions
	≥31 mm	6 lesions
Macroscopic findings	elevated type	3 lesions
	flat type	13 lesions
	superficial depressed type	4 lesions
Depth of the cancer	T1a-EP	11 lesions
	T1a-LPM	5 lesions
	T1a-MM	4 lesions

Screening performance of ultrathin transnasal endoscopy

All 20 lesions were detected using UT; therefore, no lesions were classified as undetectable. Twelve of 20 (60.0%) lesions were accurately assessed for malignancy by UT, and the diagnostic utility was defined as distinct. Eight of 20 (40.0%) lesions were detected but could not be accurately assessed for malignancy by UT, and the diagnostic utility was therefore defined as indistinct. Because CO can perform magnification endoscopy, all 20 lesions were accurately assessed for malignancy, and the diagnostic utility was defined as distinct. Using NBI observation, 1 of 8 lesions which were indistinct by UT with white light was diagnosed as a malignancy. As a result, 13 of 20 (65.0%) lesions were assessed as distinct by UT with NBI. Concerning the type of lesions, 3 of 3 (100.0%) cases with the elevated type, 5 of 13 (38.5%) cases had flat type, and 4 of 4 (100.0%) cases with the superficial depressed type were defined as distinct by UT. As a result, the flat type was difficult to diagnose according to the

type of lesions ($P < 0.05$). There was no obvious correlation between the diagnostic utility and the tumor location. Concerning the tumor size, 1 of 1 (100.0%) tumor with ≤10 mm, 2 of 3 (66.7%) tumors with 11-20 mm, 6 of 10 (60.0%) tumors with 21-30 mm, and 3 of 6 (50.0%) tumors with ≥31 mm in size were defined as distinct by UT. There was no obvious correlation between the diagnostic utility and the tumor size. Concerning the tumor depth, 5 of 11 (45.5%) T1a-EP tumors, 4 of 5 (80.0%) T1a-LPM tumors, 3 of 4 (75.0%) T1a-MM tumors were defined as distinct by UT. Although this trend did not reach statistical significance, T1a-EP tumors were difficult to diagnose in comparison with T1a-LPM and T1a-MM tumors.

Representative cases

Figure 3 shows the representative cases of endoscopic findings by UT and CO. In figure 3A, UT revealed the lesion to a similar extent as CO. UT revealed the redness, mucosal irregularity, vessel irregularity

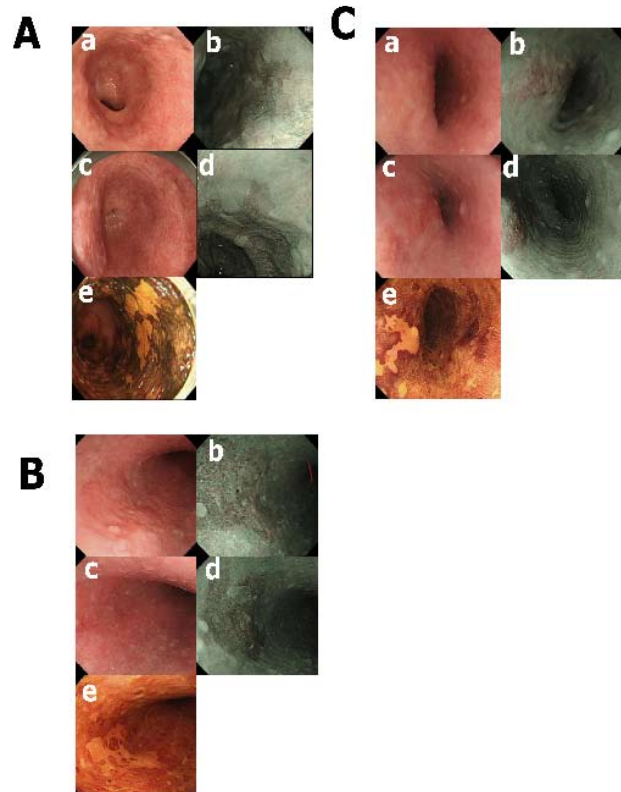


Figure 3 Representative endoscopic findings of early esophageal cancers from ultrathin transnasal endoscopy and conventional transoral endoscopy.

A: A 73-year-old male patient with a T1a-EP tumor. Ultrathin transnasal endoscopy revealed the lesion to a similar extent as conventional transoral endoscopy. Ultrathin transnasal endoscopy, redness, ○; fur white coat, ×; mucosal irregularity, ○; vessel irregularity, ○; loss of glossy, ○. Conventional transoral endoscopy, redness, ○; fur white coat, ×; mucosal irregularity, ○; vessel irregularity, ○; loss of glossy, ○. B: A 64-year-old male patient with a T1a-EP tumor. Ultrathin transnasal endoscopy was inferior to conventional transoral endoscopy in one category. Ultrathin transnasal endoscopy, redness, ○; fur white coat, ×; mucosal irregularity, ○; vessel irregularity, ○; loss of glossy, ○. Conventional transoral endoscopy, redness, ○; fur white coat, ○; mucosal irregularity, ○; vessel irregularity, ○; loss of glossy, ○. C: A 61-year-old male patient with a T1a-LPM tumor. Ultrathin transnasal endoscopy was inferior to conventional transoral endoscopy in 4 categories. Ultrathin transnasal endoscopy, redness, ○; fur white coat, ×; mucosal irregularity, ×; vessel irregularity, ×; loss of glossy, ×. Conventional transoral endoscopy, redness, ○; fur white coat, ○; mucosal irregularity, ○; vessel irregularity, ○; loss of glossy, ○. a: Ultrathin transnasal endoscopy with white light; b: Ultrathin transnasal endoscopy with NBI; c: conventional transoral endoscopy with white light, d: conventional transoral endoscopy with NBI; e: conventional transoral endoscopy with Lugol chromoendoscopy.

and loss of glossy appearance. However, the fur white coat was not revealed by UT. CO also revealed the same findings as UT. In Figure 3B, UT was inferior to CO in one category. Although CO could reveal all 5 characteristics, UT did not reveal the fur white coat. Figure 3C shows a representative patient in whom UT was inferior to CO. CO could reveal all 5 categories. In contrast, UT only revealed only the redness.

Comparison of mucosal findings between ultrathin transnasal endoscopy and conventional transoral endoscopy

The comparisons of the mucosal findings between UT and CO are shown as Figure 4. Redness was observed in 80% (16/20) of the tumors with UT and 90% (18/20) of the tumors with CO; fur white coat was observed in 60% (12/20) of the tumors with UT and 90% (18/20) of the tumors with CO; mucosal irregularity, 80% (16/20) by UT and 95% (19/20) by CO; vessel irregularity, 75% (15/20) by UT and 100% (20/20) by CO; loss of glossy, 55% (11/20) by UT and 100% (20/20) by CO. UT was significantly inferior for detecting the fur white coat ($P < 0.05$), vessel irregularity ($P < 0.05$) and loss of glossy ($P < 0.01$) in comparison with CO. There was no change in the brownish areas of NBI between UT and CO.

Quantitative analyses of endoscopic findings

To quantitatively compare the imaging findings, the densities of cancer lesions or surrounding non-tumor lesions were measured using the ImageJ software program (Figure 5). The densities of cancer lesions by UT with white light and CO with white light were 116.9 ± 18.9 and 120.8 ± 17.2 , respectively (not significantly difference). The densities of cancer lesions were significantly lower than those of the surrounding non-tumor lesions by UT and CO ($P < 0.05$). The densities of the cancer lesions were $-14.4 \pm 9.2\%$ in UT and $-14.3 \pm 9.6\%$ in CO compared with the normal lesions (not significantly difference). As a result, the imaging contrasts were not significantly different between UT and CO, confirming the results from the same detection rate. The densities of imaging with NBI by UT and CO revealed significantly better contrast between the tumor and the surrounding non-tumor lesion in comparison with those obtained using white light ($P < 0.05$). The densities of the

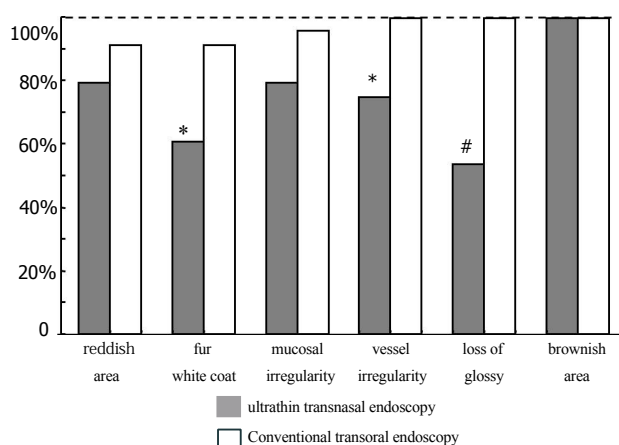


Figure 4 Comparison of mucosal findings between ultrathin transnasal endoscopy and conventional transoral endoscopy.

Conventional transoral endoscopy was superior to ultrathin transnasal endoscopy in the mucosal findings including reddish area, fur white coat, vessel irregularity, and loss of glossy appearance. However, there were no changes in mucosal irregularity or the brownish area of NBI between ultrathin transnasal endoscopy and conventional transoral endoscopy. *, $P < 0.05$ in comparison with conventional transoral endoscopy. #, $P < 0.01$ in comparison with conventional transoral endoscopy.

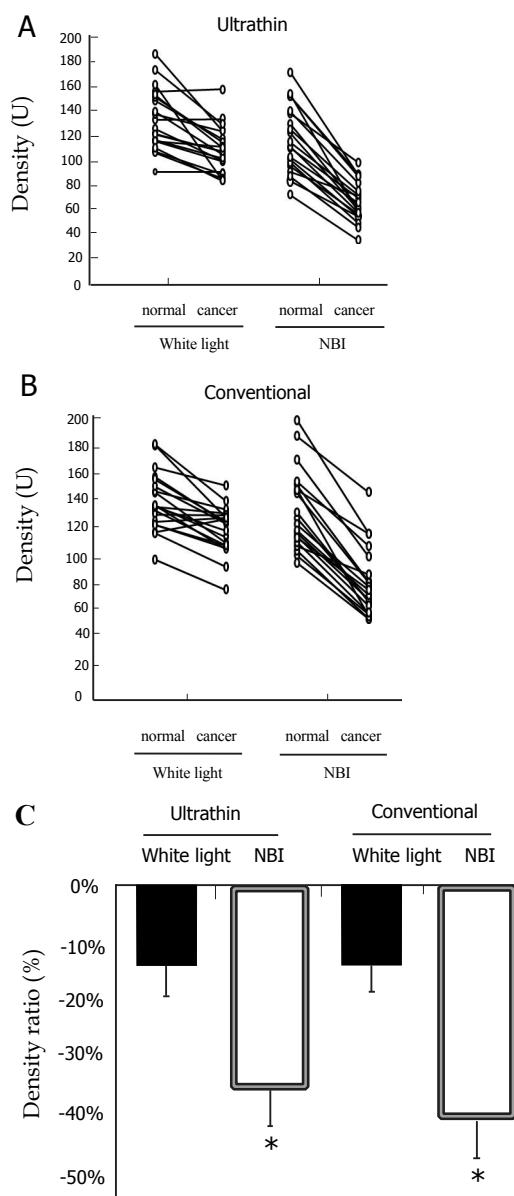


Figure 5 Quantitative analyses of endoscopic findings using the ImageJ software program.

A: Ultrathin transnasal endoscopy with white light and NBI; B: Conventional transoral endoscopy with white light and NBI; C: Density ratios. The density ratios were calculated and indicated as the percentile of $-(1 - \text{density of the tumor lesion} / \text{density of surrounding normal mucosa}) \times 100\%$. *, $P < 0.05$ in comparison with white light.

cancer lesions were $-36.5 \pm 7.6\%$ in UT with NBI and $-40.1 \pm 10.5\%$ in CO with NBI compared with the normal lesions. NBI significantly improve the lesion contrast using UT and CO ($P < 0.05$), and the utility of NBI imaging was confirmed by the analytical parameters.

DISCUSSION

We demonstrated that UT could be used in conjunction with NBI for the screening of EEC. The detection of the lesions was achieved for all lesions by UT in the present study. The quantitative imaging analyses revealed that UT had similar contrast densities with CO. Although the imaging quality of UT was inferior to CO, UT could screen for EEC. Furthermore, combined imaging with NBI yielded a higher detection rate. As a result, UT can be used for the screening of

EEC. However, it is important to consider the disadvantages of UT. It may therefore be useful for the endoscopist to change to CO with magnified endoscopy when EEC is suggested based on the findings of screening endoscopy with UT and NBI. A future goal is therefore to be able to make both an accurate diagnosis or differential diagnosis with UT.

UT has been increasingly carried out in health care institutions in Japan, particularly in patients anticipating comfortable unsedated upper gastrointestinal endoscopy. With the recent ultrathin videoscopes, several studies reported an improved detection rate of gastric cancer in Japan, suggesting that no differences were noted between UT and CO when it was carried out by experienced endoscopists^[9]. Several studies reported the diagnostic accuracy and optical quality of UT to be equivalent to those of CO^[17-21]. However, those studies targeted lesions other than early gastric cancers, such as esophagitis, Barrett's esophagus, hiatal hernia, esophageal varices, and gastric ulcers^[17-21]. Catanzaro *et al.*^[19] reported that the overall accuracy for esophageal findings was 98%; the sensitivity, 91%; and the specificity, 99%. Sorbi *et al.*^[20] reported that 97% of the lesions were correctly detected by UT compared with CO. However, the use of UT for screening for early gastric cancers still remains controversial. As a result, it also remains controversial to use UT to screen for EEC. Because the inherent shortcomings of UT include its poor resolution, lower light source, and lack of magnification^[7], it may be more difficult to detect EEC than early gastric cancers.

In the present series, all EEC lesions were accurately detected. Although there was data on the EEC before the procedure, which was carried out by experienced endoscopists, the brownish areas of NBI were all accurately detected by UT. Combined imaging with NBI improved the sensitivity of UT for the screening of EEC. Furthermore, the utility of NBI was revealed by the mathematical parameters in the present study. Our patient series showed that UT was inferior to CO in regarding the mucosal findings, including the fur white coat, vessel irregularity, and loss of glossy appearance. The explanation is that the lower resolution and lower luminous intensity of the UT render it difficult to detect these findings. However, mucosal irregularity was relatively well detected by UT. The light guide of UT was one, although the light guide of CO was two. The findings of the mucosal irregularity were easily detected because of only one light guide, which may have resulted in a clearer light/shadow contrast. The comparison of the mucosal findings in UT with CO is subjective because it may vary with the experience of the endoscopists. Therefore, using the ImageJ software program to compare image quality is a benefit of this study. This study showed that there was no significant difference in the imaging contrasts between UT and CO, confirming the results from the same detection rate. The density of imaging with NBI by UT and CO revealed significantly better contrast between the tumor and the surrounding non-tumor lesion in comparison to those obtained using white light. NBI significantly improve the lesion contrast using UT and CO, and the utility of NBI imaging was confirmed by the analytical parameters.

The time required for endoscopic examination to diagnose EEC is important. The examination time using UT was compared with the time using CO to evaluate the usefulness of UT as a screening test for EEC. The time required for endoscopic examination of the esophagus (excluding the observation of stomach and duodenum) was 152.0±43.1 sec in UT and 137.0±47.3 sec in CO ($P=0.10$). The time from insertion to detecting EEC was 55.5 ± 51.7 sec in UT and 40.0±25.4 sec in CO in observation time ($P=0.08$). There were no significant differences in examination times for EEC between UT and CO in this study.

Lee *et al.*^[11, 23] reported that interpretations based on endoscopy

with NBI are much more consistent than those based on standard endoscopy alone. Moreover, the reliability of interpretation based on Lugol chromoendoscopy can be improved with information derived from previous NBI endoscopy^[11, 22, 23]. UT might increase the patient tolerance for longer procedures. The achievement of a higher level of resolution and a brighter image compared to previous methods is clearly important. Further innovations, such as the use of high-resolution charge-coupled devices (CCD), strong-power light sources, and enhanced integration of the imaging system will improve the image quality of UT.

In conclusion, UT was found to be useful for the screening of EEC. The imaging qualities and diagnostic accuracy of UT were lower than those of CO. However, combination with NBI yielded a higher sensitivity, and UT with NBI could detect EEC.

REFERENCES

- Shaker R. Unsedated trans-nasal pharyngoesophagogastrroduodenoscopy (T-EGD): technique. *Gastrointest Endosc* 1994; **40**: 346-348
- Yagi J, Adachi K, Arima N, Tanaka S, Ose T, Azumi T, Sasaki H, Sato M, Kinoshita Y. A prospective randomized comparative study on the safety and tolerability of transnasal esophagogastrroduodenoscopy. *Endoscopy* 2005; **37**: 1226-1231
- Horiuchi A, Nakayama Y, Hidaka N, Ichise Y, Kajiyama M, Tanaka N. Prospective comparison between sedated high-definition oral and unsedated ultrathin transnasal esophagogastrroduodenoscopy in the same subjects: pilot study. *Dig Endosc* 2009; **21**: 24-28
- Mori A, Ohashi N, Yoshida A, Nozaki M, Tatebe H, Okuno M, Hoshihara Y, Hongo M. Unsedated transnasal ultrathin esophagogastrroduodenoscopy may provide better diagnostic performance in gastroesophageal reflux disease. *Dis Esophagus* 2011; **24**: 92-98
- Mori A, Fushimi N, Asano T, Maruyama T, Ohashi N, Okumura S, Inoue H, Takekoshi S, Friedman SL, Okuno M. Cardiovascular tolerance in unsedated upper gastrointestinal endoscopy: Prospective randomized comparison between transnasal and conventional oral procedures. *Dig Endosc* 2006; **18**: 282-287
- Mori A, Ohashi N, Tatebe H, Maruyama T, Inoue H, Takegoshi S, Kato T, Okuno M. Autonomic nervous function in upper gastrointestinal endoscopy: A prospective randomized comparison between transnasal and oral procedures. *J Gastroenterol* 2008; **43**: 38-44
- Tatsumi Y, Harada A, Matsumoto T, Tani T, Nishida H. Current status and evaluation of transnasal esophagogastrroduodenoscopy. *Dig Endosc* 2009; **21**: 141-146
- Miyawaki T, Nose M, Kouzu T, Hishikawa E, Watanabe Y, Inoue M, Satou T. Transnasal upper gastrointestinal endoscopy: Safe and painless examination. *Endoscopy Digestiva* 2007; **19**: 529-535 (in Japanese with English abstract)
- Yoshida Y, Hayami Y, Matsuoka M, Nakayama S. Comparison of endoscopic detection rate of early gastric cancer and gastric adenoma using transnasal EGD with that of transoral EGD. *Dig Endosc* 2008; **20**: 184-189
- Hayashi Y, Yamamoto Y, Suganuma T, Okada K, Nego M, Imada S, Imai M, Yoshimoto K, Ueki N, Hirasawa T, Uragami N, Tsuchida T, Fujisaki J, Hoshino E, Takahashi H, Igarashi M. Comparison of the diagnostic utility of the ultrathin endoscope and the conventional endoscope in early gastric cancer screening. *Dig Endosc* 2009; **21**: 116-121
- Lee YC, Lin JT, Chiu HM, Liao WC, Chen CC, Tu CH, Tai CM, Chiang TH, Chiu YH, Wu MS, Wang HP. Intraobserver and interobserver consistency for grading esophagitis with narrow-band imaging. *Gastrointest Endosc* 2007; **66**: 230-236

- 12 Gono K, Obi T, Yamaguchi M, Ohyama N, Machida H, Sano Y, Yoshida S, Hamamoto Y, Endo T. Appearance of enhanced tissue features in narrow-band endoscopic imaging. *J Biomed Opt* 2004; **9**: 568-577
- 13 Muto M, Nakane M, Katada C, Sano Y, Ohtsu A, Esumi H, Ebihara S, Yoshida S. Squamous cell carcinoma in situ at oropharyngeal and hypopharyngeal mucosal sites. *Cancer* 2004; **101**: 1375-1381
- 14 Yoshida T, Inoue H, Usui S, Satodate H, Fukami N, Kudo SE. Narrow-band imaging system with magnifying endoscopy for superficial esophageal lesions. *Gastrointest Endosc* 2004; **59**: 288-295
- 15 Muto M, Katada C, Sano Y, Yoshida S. Narrow band imaging: a new diagnostic approach to visualize angiogenesis in superficial neoplasia. *Clin Gastroenterol Hepatol* 2005; **3**: S16-S20
- 16 The Japan esophageal society. Guidelines for clinical and pathologic studies on carcinoma of the esophagus. 10th edn. Tokyo: Kanehara-Shuppan, 2008
- 17 Thota PN, Zuccaro G. Jr, Vargo JJ 2nd, Conwell DL, Dumot JA, Xu M. A randomized prospective trial comparing unsedated esophagoscopy via transnasal and transoral routes using a 4-mm video endoscope with conventional endoscopy with sedation. *Endoscopy* 2005; **37**: 559-565
- 18 Murata A, Akahoshi K, Sumida Y, Yamamoto H, Nakamura K, Nawata H. Prospective randomized trial of transnasal versus peroral endoscopy using an ultrathin videoendoscopes in unsedated patients. *J Gastroenterol Hepatol* 2007; **22**: 482-485
- 19 Catanzaro A, Faulx A, Isenberg GA, Wong RC, Cooper G, Sivak MV Jr, Chak A. Prospective evaluation of 4-mm diameter endoscopes for esophagoscopy in sedated and unsedated patients. *Gastrointest Endosc* 2003; **57**: 300-304
- 20 Sorbi D, Gostout CJ, Henry J, Lindor KD. Unsedated small-caliber esophagogastroduodenoscopy (EGD) versus conventional EGD: A comparative study. *Gastroenterology* 1999; **117**: 1301-1307
- 21 Jobe BA, Hunter JG, Chang EY, Kim CY, Eisen GM, Robinson JD, Diggs BS, O'Rourke RW, Rader AE, Schipper P, Sauer DA, Peters JH, Lieberman DA, Morris CD. Office-based unsedated small-caliber endoscopy is equivalent to conventional sedated endoscopy in screening and surveillance for Barrett's esophagus: A randomized and blinded comparison. *Am J Gastroenterol* 2006; **101**: 2693-2703
- 22 Sharma P, Wani S, Bansal A, Hall S, Puli S, Mathur S, Rastogi A. A feasibility trial of narrow band imaging endoscopy in patients with gastroesophageal reflux disease. *Gastroenterology* 2007; **133**: 454-464
- 23 Lee YC, Wang CP, Chen CC, Chiu HM, Ko JY, Lou PJ, Yang TL, Huang HY, Wu MS, Lin JT, Hsiu-Hsi Chen T, Wang HP. Transnasal endoscopy with narrow-band imaging and Lugol staining to screen patients with head and neck cancer whose condition limits oral intubation with standard endoscope (with video). *Gastrointest Endosc* 2009; **69**: 408-417

Peer reviewers: Chenghao Guo, MD, PhD, Professor, Department of Pathology, Institute of Pathology and Pathophysiology, School of Medicine, Shandong University, Wenhuxi R.d44, Jinan city, 250012, Shandong Province, China; Hoon Jai Chun, MD, PhD, Professor, Division of Gastroenterology and Hepatology, Department of Internal Medicine, Institute of Digestive Disease and Nutrition, Korea University College of Medicine, 126-1, 5-Ga, Anam-Dong, Seongbuk-Gu, Seoul, 136-705, Korea; Hee Man Kim, Assistant Professor, Department of Internal Medicine, Kwandong University College of Medicine, 697-24 Hwajung-dong, Deokyang-gu, Goyang city, 412-270, Republic of Korea.