

Aggravation of Pseudomyxoma Peritonei Recognized 31 Months Post Appendectomy

Hiromi Ono¹, MD; Hitoshi Yokoyama², MD, PhD; Haruyuki Yoshida², MD; Hiraku Fukushima², MD, PhD; Masato Kawakami², MD; Mikio Okamura³, MD; Takanori Aoki³, MD; Naoki Asakage³, MD; Yasushi Danjo⁴, MD, PhD; Kimimoto Nagashima⁵, MD; Hideyuki Hayashi⁶, MD, PhD; Hiroshi Nishihara⁶, MD, PhD; Yuichi Shimizu⁷, MD, PhD; Tsuyoshi Shimamura⁸, MD, PhD; Mitsuo Kusano⁹, MD, PhD

1 Department of Internal Medicine, Veritas Hospital, Kawanishi, Hyogo 666-0125, Japan;

2 Department of Internal Medicine, Seiwa Memorial Hospital, Kotoni, Nishi-ku, Sapporo, Hokkaido 063-0811, Japan;

3 Department of Surgery, Seiwa Memorial Hospital, Nishi-ku, Sapporo, Hokkaido 063-0811, Japan;

4 Department of Surgery, Heiwa Hospital, Nishi-ku, Sapporo, Hokkaido 063-0022, Japan;

5 Department of Anesthesiology, Shin-Sapporo Orthopedic Hospital, Atsubetsuminami, Atsubetsu-ku, Sapporo, Hokkaido, Japan;

6 Genomics Unit, Keio Cancer Center, Keio University School of Medicine, 35 Shinanomachi, Shinjuku-ku, Tokyo 160-8582, Japan;

7 Division of Endoscopy, Hokkaido University Hospital, Kita 14, Nishi 5, Kita-ku, Sapporo, Hokkaido 060-8648, Japan;

8 Division of Organ Transplantation, Central Clinical Facilities, Hokkaido University Hospital, Sapporo, Hokkaido Japan;

9 Division of Internal Medicine, Hokkaido Social Welfare Corporation Yoichi Hospital, Hokkaido, Japan.

Conflict-of-interest statement: The authors declare that there is no conflict of interest regarding the publication of this paper.

Open-Access: This article is an open-access article which was selected by an in-house editor and fully peer-reviewed by external reviewers. It is distributed in accordance with the Creative Commons Attribution Non Commercial (CC BY-NC 4.0) license, which permits others to distribute, remix, adapt, build upon this work non-commercially, and license their derivative works on different terms, provided the original work is properly cited and the use is non-commercial. See: <http://creativecommons.org/licenses/by-nc/4.0/>

Correspondence to: Hiromi Ono, Department of Internal Medicine, Veritas Hospital, Shinden, Kawanishi, Hyogo, Japan.

Email: kupz85728@zeus.eonet.ne.jp

Telephone: +81-72-793-7890

Received: November 15, 2020

Revised: November 21, 2020

Accepted: November 23, 2020

Published online: December 21, 2020

ABSTRACT

Pseudomyxoma peritonei (PMP) is a rare type of peritoneal secondary tumor. The incidence of PMP is approximately 1 per million population per year. A 63-year-old Japanese female was referred to our hospital with an acute appendicitis. Abdominal computed tomography (CT) scan revealed a peripheral liver ascites. Appendectomy was performed on the same day. A low-grade appendiceal mucinous neoplasm was diagnosed pathologically. She returned to our hospital with an abdominal distention and fullness 31 months post appendectomy. Abdominal CT scan could view an ascites in pelvic cavity. An aggravation of PMP was recognized clinically. PMP is an interesting syndrome with unique clinical and pathologic challenges. Although predictions reveal that, most cases will arise from low-grade appendiceal mucinous lesions, it remains challenging to classify as an entity. Standard treatment is peritoneotomy and hyperthermic intraperitoneal chemotherapy. Then, it needs continued monitoring post appendectomy since the recurrence of PMP is common.

Key words: Hyperthermic intraperitoneal chemotherapy; Low-grade appendiceal mucinous neoplasm; Peritoneotomy; Pseudomyxoma peritonei

© 2020 The Authors. Published by ACT Publishing Group Ltd. All rights reserved.

Ono H, Yokoyama H, Yoshida H, Fukushima H, Kawakami M, Okamura M, Aoki T, Asakage N, Danjo Y, Nagashima K, Hayashi H, Nishihara H, Shimizu Y, Shimamura T, Kusano M. Aggravation of Pseudomyxoma Peritonei Recognized 31 Months Post Appendectomy. *Journal of Gastroenterology and Hepatology Research* 2020; 9(6): 3393-3397 Available from: URL: <http://www.ghrnet.org/index.php/joghr/article/view/3034>

INTRODUCTION

Pseudomyxoma peritonei (PMP) is a rare clinical condition, characterised by mucinous ascites, and is generally associated with a perforated epithelial neoplasm of the appendix^[1,2]. Carl

Rokitansky was the first to describe an appendiceal mucocele in 1842^[3]. Subsequently, in 1884, Werth coined the term PMP to define an ovarian neoplasm^[4]. In 1937, Robert Michaelis Von Olshausen, a German gynaecologist, hypothesized that epithelial cells from the lining of a ruptured appendiceal cyst metastasize in the peritoneal cavity and continued to secrete gelatinous material, leading to PMP^[3]. While epithelial neoplasms of the appendix remains the most common cause of PMP, similar pathological features may originate from mucinous neoplasms of the colorectum, ovaries or any abdominal organ. PMP of nonappendiceal origin was thought to have a worse prognosis, as the underlying pathology was more likely to be a mucinous adenocarcinoma^[5]. Generally, PMP is considered as a benign process. However, the disease has a wide spectrum, ranging from slow growing benign lesions to rapidly progressive infiltrative disease. Therefore, PMP should always be considered as a borderline malignant process^[2]. Thus, we report a patient of PMP, who returned to our hospital 31 months post appendectomy.

CASE REPORT

A 63-year-old Japanese female was referred to our hospital on August 2016 with an acute appendicitis. She had right lower abdominal pain. She had a BMI of 23.5kg/m². Physical examination revealed a right lower abdominal tenderness on palpation. Her body temperature was at 36.9°C, white blood cell count at 6,300/μL, C-reactive protein at 0.09 mg/dL, carcinoembryonic antigen level at 3.5 ng/mL, and carbohydrate antigen 19-9 level at 39 U/mL. Abdominal ultrasound showed dilatation of an appendix, leading to the diagnosis of appendicitis in the previous hospital. Abdominal CT scan revealed an ascites around the liver, but not in the pelvic cavity (Figure 1). On the same day, a laparoscopic surgery was performed to relieve the pain after obtaining an informed consent. Since a mucinous ascites was noticed around the liver and appendix could not be removed due to adhesions, the original laparotomy was switched to an appendectomy. We then performed an appendectomy and drained and washed the abdominal cavity of the mucinous ascites. Macroscopically, we observed a dilated appendix measuring 72×28 mm filled with jelly, but no significant abnormal mucosa of the resected specimen (Figure 2). From pathology, we diagnosed a low-grade appendiceal mucinous neoplasm (Figure 3), and clinically, we diagnosed an appendiceal pseudomyxoma peritonei. We would plan to perform a chemotherapy, but we could not contact her. It was thought that she visited another hospital to request a second opinion. However, she returned to our hospital after 31 months post appendectomy. Furthermore, an abdominal CT scan revealed an ascites in the abdominopelvic cavity (Figure 4). Thus, we then recognized an aggravation of pseudomyxoma peritonei clinically and she was transferred to another hospital for better management.

DISCUSSION

Due to paucity of data, the incidence of PMP is unknown. Previous data from autopsy studies estimated the incidence of an appendiceal mucocele to be about 0.2%^[6]. The aforementioned incidence (1 per million population per year)^[7] was not based on good evidence^[2]. Estimates from recent data revealed that the incidence of mucinous epithelial neoplasm of the appendix is around 0.3% and progression to PMP is about 20% of these patients^[8].

In 2000, Esquivel and Sugarbaker described common features of PMP. Their study with 217 patients found the most common presentation to be an acute appendicitis (27%). The next most common presentation was an abdominal distension (23%), while

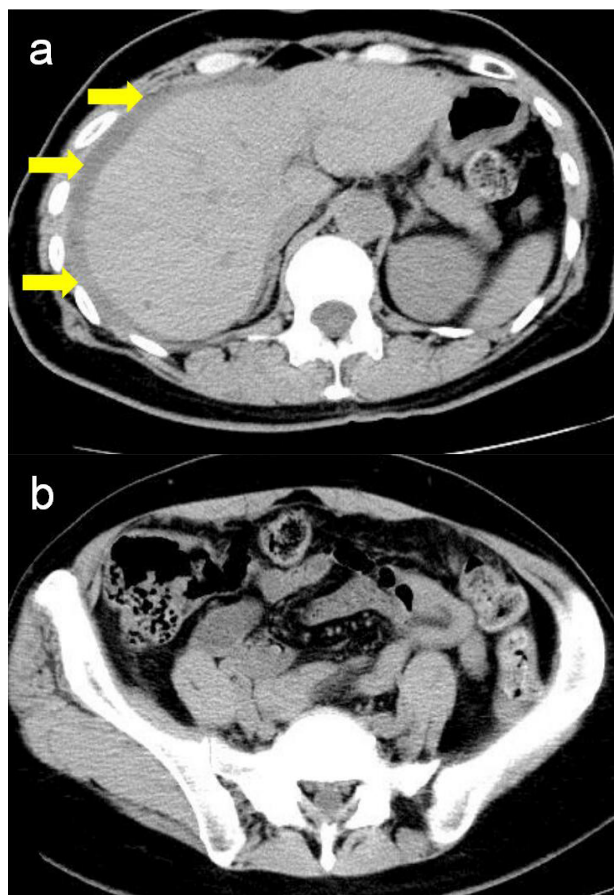


Figure 1 Abdominal computed tomography (CT) scan showed ascites around a liver (yellow arrows) (a) but no ascites in the pelvic cavity (b) at admission.

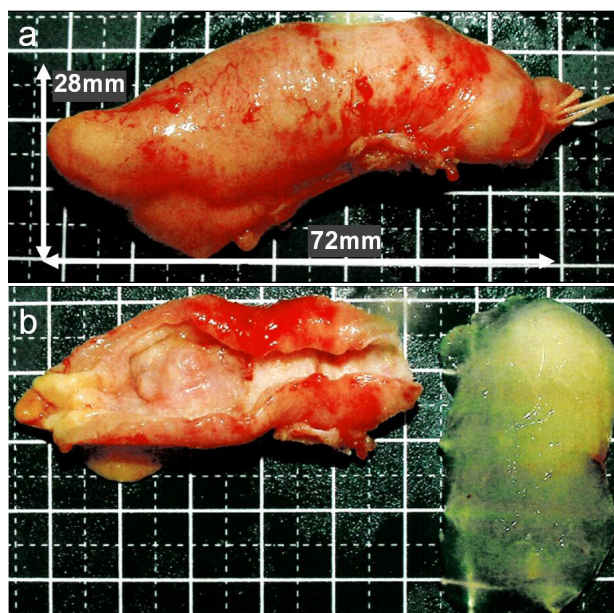


Figure 2 Macroscopy showed that the appendix measured 72×28 mm in size (a), and the mucosal level is almost intact, and a mucinous jelly was contained into an appendix (b).

14% were discovered under investigation for a new onset hernia, mostly inguinal. Other findings included ascites, abdominal pain, and vague abdominal symptoms accounting for 17% of cases^[9].

PMP is a clinico-pathological entity resulting from mucin-producing peritoneal and omental tumor metastases from a perforated

mucinous neoplasm. Rupture of the primary tumor results in free-floating mucin and epithelial cells, which metastasize in various parts of the peritoneal cavity. These then produce mucin and are responsible for the development of the typical jelly belly^[10]. Classical PMP originates from an appendiceal tumor, with similar clinical, radiological and even pathological features with adenocarcinoma of sources such as the appendix, colon or rectum^[2]. In women, PMP was usually considered to originate from the ovary but not more the case as recent findings reveal an underlying etiology in the appendix, with

secondary involvement of the ovaries^[2].

Histopathology and classification of PMP has always been confusing and challenging. There are many classification systems, often with confusing and overlapping terminologies. Ronnett *et al.* in 1995 divided PMP into three categories: disseminated peritoneal adenomucinosis (DPAM), peritoneal mucinous carcinomatosis (PMCA), and an intermediate category containing tumors with inconsistent or discordant features (PMCA-I/D)^[11]. Bradley *et al.* in 2006 classified PMP into two distinct categories: mucinous

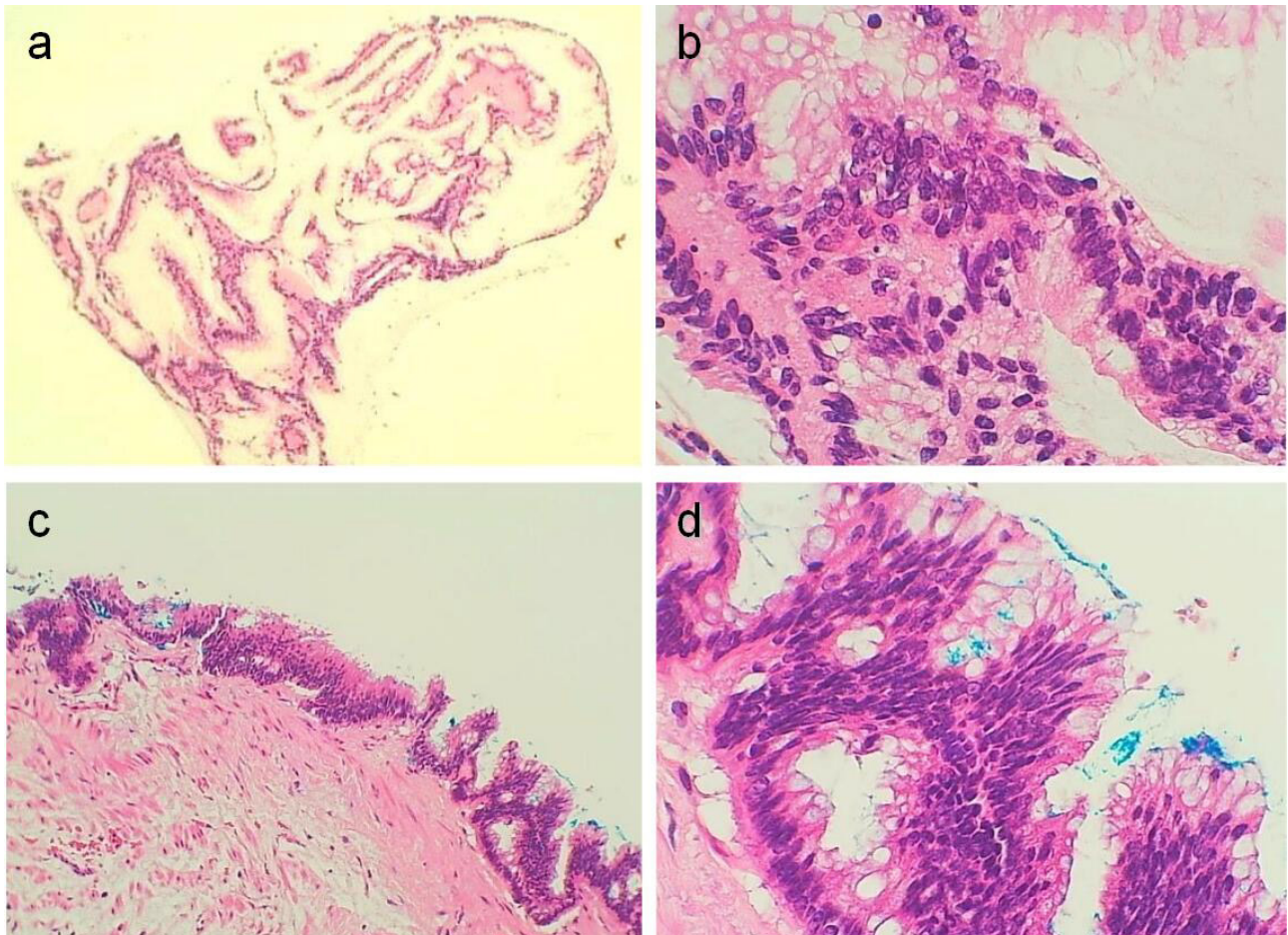


Figure 3 Postoperative histological pathologic diagnoses were low-grade appendiceal mucinous neoplasm. Small quantities of cavities containing mucin were observed in the fibrous tissues (a) (10×) and (b) (200×). Microscopy of the appendiceal mucosa revealed low-grade appendiceal mucinous neoplasm (c) (50×) and (d) (200×) hematoxylin and eosin (H.E) stained sections.

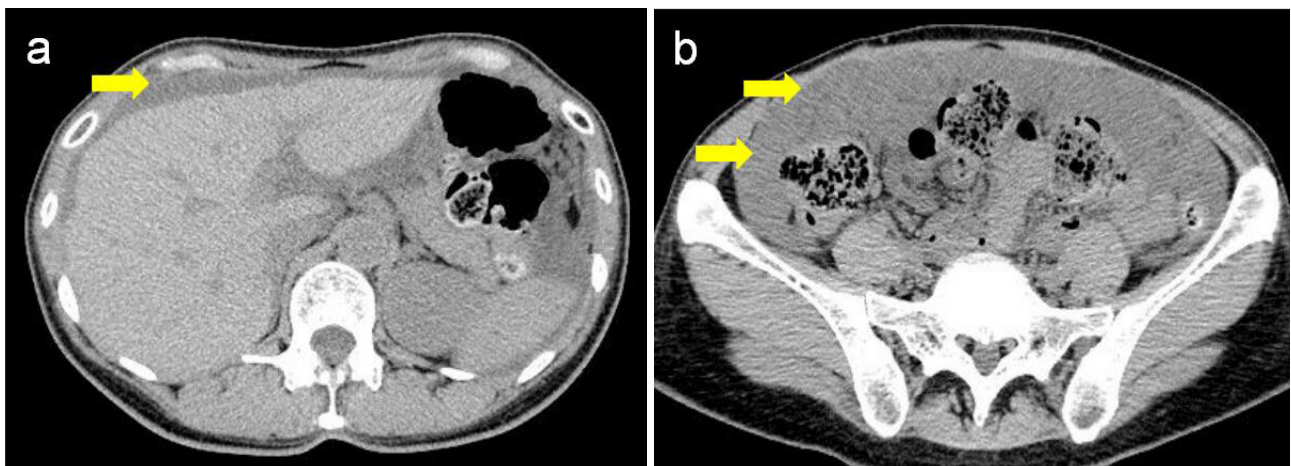


Figure 4 Abdominal CT scan showed ascites (yellow arrows) around the liver (a) and revealed ascites (yellow arrows) in the pelvic cavity (b) 31 months post appendectomy.

carcinoma peritonei low grade (MCP-L) and mucinous carcinoma peritonei high grade (MCP-H)^[12]. In 2010, WHO classified PMP into low-grade and high-grade lesions^[13].

Chest, abdomen, and pelvis CT with intravenous contrast is the imaging modality of choice for PMP. CT scan can often reveal the primary tumor in the appendix, which may be calcified or ruptured, in addition to omental thickening and mucinous ascites^[14,15]. Magnetic resonance imaging (MRI) of the abdomen and pelvis may be helpful in assessing the small bowel as well as the hepatoduodenal ligament^[16-18]. Serum tumor markers are helpful in predicting adverse nature of the disease. In secreting tumor types, elevated tumor markers help in follow-up and early identification of recurrence^[19]. The three markers commonly explored in PMP are the carcino-embryonic antigen (CEA), carbohydrate antigen 125 (CA 125), and carbohydrate antigen 19-9 (CA 19-9)^[20].

Appropriate treatment for PMP is a combined strategy of complete macroscopic tumor removal (complete cytoreductive surgery; CCRS) with HIPEC (hyperthermic intraperitoneal chemotherapy)^[21-23]. CCRS with HIPEC is a major undertaking with an average operating time of nine hours (range: 2-24 hours) with significant associated morbidity but little postoperative mortality^[24]. Moreover, CCRS+HIPEC presumes to be a better treatment option of patients with suspected PMP though little is known about prognosis and outcome. By introducing this method, the survival of PMP patients has improved dramatically^[25,26]. Disease-free survival at 1,5, and 10 years are reported at 75%, 56-70%, and 67%, with an overall 5-year survival rate of 69-75% and 10-year survival rates of 57%^[21,24,27-29]. That was not performed in our case. Conversely, we performed an appendectomy with suction of ascites and abdominal washing. Additionally, we would plan to perform a chemotherapy, but we could not contact her. It was thought that she visited another hospital to request a second opinion. However, she returned to our hospital after 31 months post appendectomy. Furthermore, an abdominal CT scan revealed an ascites in the abdominopelvic cavity. Thus, we then recognized an aggravation of pseudomyxoma peritonei clinically and she was transferred to another hospital for better management.

A definitive follow-up strategy is important for early detection and management of recurrences. By this, a follow-up CT scan and serum tumor markers are done one year after surgery and then annually for 10 years. If recurrence is detected, further management has to be patient-specific, with no definitive guidelines available. The nature of the primary tumor and primary surgery, location of the recurrence, disease burden, fitness for surgery as well as symptoms and patient wishes, all play a part in choosing further management^[5].

CONCLUSION

PMP is a rare, borderline malignant, clinico-pathological entity originating from a perforated mucinous neoplasm of the appendix, and is an interesting syndrome with unique clinical and pathologic challenges. PMP poses unique management issues in that it does not metastasize systemically but causes recurrent obstructions requiring proper monitoring and aggressive management, because the recurrence of PMP is common.

REFERENCES

1. Sugarbaker PH. Pseudomyxoma peritonei. *Cancer Treat Res.* 1996; **81**: 105-19. [DOI: 10.1007/978-1-4613-1245-1_10]
2. Moran BJ, Cecil TD. The etiology, clinical presentation, and management of pseudomyxoma peritonei. *Surg Oncol Clin N Am.* 2003; **12**(3): 585-603. [PMID: 14567019]; [DOI: 10.1016/s1055-3207(03)00026-7]
3. Weaver CH. Mucocoele of appendix with pseudomucinous degeneration. *Am J Surg.* 1937; **36**:523-6. [DOI: 10.1016/S0002-9610(37)90763-3]
4. Werth R. Klinische und anatomische untersuchungen zur lehre von den bauchgeschwülsten und der laparatomie. *Arch Für Gynäkol.* 1884; **24**:100-18.
5. Mittal R, Chandramohan A, Moran B. Pseudomyxoma peritonei: natural history and treatment. *Int J Hyperthermia.* 2017; **33**: 511-9. [PMID: 28540829]; [DOI: 10.1080/02656736.2017.1310938]
6. Castle OL. Cystic dilation of the vermiform appendix. *Ann Surg.* 1915; **61**(5): 582-8. [PMID: 17863360]; [DOI: 10.1097/00000658-191505000-00007]
7. Sugarbaker PH. Complete cytoreduction for pseudomyxoma peritonei (Sugarbaker technique). 2011. Guidance and guidelines. NICE [Internet] <https://www.nice.org.uk/guidance/ippg56>. Accessed 24 Nov 2011.
8. Smeenk RM, van Velthuysen ML, Verwaal VJ, Zoetmulder FAN. Appendiceal neoplasms and pseudomyxoma peritonei: a population based study. *Eur J Surg Oncol.* 2008; **34**(2): 196-201. [PMID: 17524597]; [DOI: 10.1016/j.ejso.2007.04.002]
9. Esquivel J, Sugarbaker PH. Clinical presentation of the pseudomyxoma peritonei syndrome. *Br J Surg.* 2000; **87**(10): 1414-8. [PMID: 11044169]; [DOI: 10.1046/j.1365-2168.2000.01553.x]
10. Behling H. Mucocoele of the appendix and jelly-belly. *Minn Med.* 1967; **50**(7): 1109-12. [PMID: 6046250]
11. Ronnett BM, Zahn CM, Kurman RJ, Kass ME, Sugarbaker PH, Shmookler BM. Disseminated peritoneal adenomucinosis and peritoneal mucinous carcinomatosis. A clinicopathologic analysis of 109 cases with emphasis on distinguishing pathologic features, site of origin, prognosis, and relationship to "pseudomyxoma peritonei". *Am J Surg Pathol.* 1995; **19**(12): 1390-408. [PMID: 7503361]; [DOI: 10.1097/00000478-199512000-00006]
12. Bradley RF, Stewart JH, Russell GB, Levine EA, Geisinger KR. Pseudomyxoma peritonei of appendiceal origin: a clinicopathologic analysis of 101 patients uniformly treated at a single institution, with literature review. *Am J Surg Pathol.* 2006; **30**(5): 551-9. [PMID: 16699309]; [DOI: 10.1097/01.pas.0000202039.74837.7d]
13. Carr NJ, Sobin LH. Adenocarcinoma of the appendix. In: Bosman FT, Carneiro F, Hruban RH, et al., editors. WHO classification of tumors of the digestive system. Lyon: IARC; 2010:12212-5.
14. Sulkin TVC, O'Neill H, Amin AL, Moran B. CT in pseudomyxoma peritonei: a review of 17 cases. *Clin Radiol.* 2002; **57**(7): 608-13. [PMID: 12096860]; [DOI: 10.1053/crad.2002.0942]
15. Jacquet P, Jelinek JS, Chang D, Koslowe P, Sugarbaker PH. Abdominal computed tomographic scan in the selection of patients with mucinous peritoneal carcinomatosis for cytoreductive surgery. *J Am Coll Surg.* 1995; **181**(6): 530-8. [PMID: 7582228]
16. Cotton F, Pellet O, Gilly F-N, Granier A, Sournac L, Glehen O. MRI evaluation of bulky tumor masses in the mesentery and bladder involvement in peritoneal carcinomatosis. *Eur J Surg Oncol.* 2006; **32**(10): 1212-6. [PMID: 16762527]; [DOI: 10.1016/j.ejso.2006.04.013]
17. Tirumani SH, Fraser-Hill M, Auer R, Shabana W, Walsh C, Lee F, Ryan JG. Mucinous neoplasms of the appendix: a current comprehensive clinicopathologic and imaging review. *Cancer Imaging.* 2013; **13**(1): 14-25. [PMID: 23439060]; [DOI: 10.1102/1470-7330.2013.0003]
18. Low RN, Barone RM, Gurney JM, Muller WD. Mucinous appendiceal neoplasms: preoperative MR staging and classification compared with surgical and histopathologic findings. *Am J Roentgenol.* 2008; **190**(3): 656-65. [PMID: 18287436]; [DOI: 10.2214/AJR.07.2018]
19. Wagner PL, Austin F, Sathaiah M, Magge D, Maduekwe U,

- Ramalingam L, Jones HL, Holtzman MP, Ahrendt SA, Zureikat AH, Pingpank JF, Zeh III HJ, Bartlett DL, Choudry HA. Significance of serum tumor marker levels in peritoneal carcinomatosis of appendiceal origin. *Ann Surg Oncol.* 2013; **20(2)**: 506-14. [PMID: 22941175]; [DOI: 10.1245/s10434-012-2627-5]
20. Taflampas P, Dayal S, Chandrakumaran K, Mohamed F, Cecil TD, Moran BJ. Pre-operative tumour marker status predicts recurrence and survival after complete cytoreduction and hyperthermic intraperitoneal chemotherapy for appendiceal pseudomyxoma peritonei: analysis of 519 patients. *Eur J Surg Oncol.* 2014; **40(5)**: 515-20. [PMID: 24462284]; [DOI: 10.1016/j.ejso.2013.12.021]
 21. Youssef H, Newman C, Chandrakumaran K, Mohamed F, Cecil TD, Moran BJ. Operative findings, early complications, and long-term survival in 456 patients with pseudomyxoma peritonei syndrome of appendiceal origin. *Dis Colon Rectum.* 2011; **54(3)**: 293-9. [PMID: 21304299]; [DOI: 10.1007/DCR.0b013e318202f026]
 22. Moran B, Baratti D, Yan TD, Kusamura S, Deraco M. Consensus statement on the loco-regional treatment of appendiceal mucinous neoplasms with peritoneal dissemination (pseudomyxoma peritonei). *J Surg Oncol.* 2008; **98(4)**:277-82. [PMID: 18726894]; [DOI: 10.1002/jso.21054]
 23. Sugarbaker PH, Chang D. Results of treatment of 385 patients with peritoneal surface spread of appendiceal malignancy. *Ann Surg Oncol.* 1999; **6(8)**: 727-31. [PMID: 10622499]; [DOI: 10.1007/s10434-999-0727-7]
 24. Chua TC, Moran BJ, Sugarbaker PH, Levine EA, Glehen O, GillyDario Baratti FN, Deraco M, Elias D, Sardi A, Liauw W, Yan TD, Barrios P, Portilla AG, de Hingh I H.J.T, Ceelen WP, Pelz JO, Piso P, González-Moreno S, Speeten KVD, Morris DL. Early- and long-term outcome data of patients with pseudomyxoma peritonei from appendiceal origin treated by a strategy of cytoreductive surgery and hyperthermic intraperitoneal chemotherapy. *J Clin Oncol.* 2012; **30(20)**: 2449-56. [PMID: 22614976]; [DOI: 10.1200/JCO.2011.39.7166]
 25. Sugarbaker PH. Surgical treatment of peritoneal carcinomatosis: 1988 Du Pont lecture. *Can J Surg.* 1989; **32(3)**: 164-70. [PMID: 2713770]
 26. Sugarbaker PH. Peritonectomy procedures. *Ann Surg.* 1995; **221(1)**: 29-42. [PMID: 7826158]; [DOI: 10.1097/0000658-199501000-00004]
 27. Yan TD, Bijelic L, Sugarbaker PH. Critical analysis of treatment failure after complete cytoreductive surgery and perioperative intraperitoneal chemotherapy for peritoneal dissemination from appendiceal mucinous neoplasms. *Ann Surg Oncol.* 2007; **14(8)**: 2289-99. [PMID: 17541772]; [DOI: 10.1245/s10434-007-9462-0]
 28. Omohwo C, Nieroda CA, Studeman KD, Thieme H, Kostuik P, Ross AS, Holter DR, Gushchin V, Merriman B, Sardi A. Complete cytoreduction offers longterm survival in patients with peritoneal carcinomatosis from appendiceal tumors of unfavorable histology. *J Am Coll Surg.* 2009; **209(3)**: 308-12. [PMID: 19717034]; [DOI: 10.1016/j.jamcollsurg.2009.04.019]
 29. Elias D, Gilly F, Quenet F, Bereder JM, Sidéris L, Mansvelt B, Lorimier G, Glehen O. Pseudomyxoma peritonei: a French multicentric study of 301 patients treated with cytoreductive surgery and intraperitoneal chemotherapy. *Eur J Surg Oncol.* 2010; **36(5)**: 456-62. [PMID: 20227231]; [DOI: 10.1016/j.ejso.2010.01.006]