

## Decrease in APRI Score in Compensated Liver Cirrhosis Patients Due to Hepatitis C After a Combination Therapy of Sofosbuvir and Daclatasvir

Dolvy Girawan<sup>1</sup>, Ony Wiraswati<sup>2</sup>, Aditya Herbiyantoro<sup>1</sup>, Yovita Hartantri<sup>3</sup>

1 Gastroenterohepatology Division, Department of Internal Medicine, Faculty of Medicine, Padjadjaran University / Dr. Hasan Sadikin General Hospital Bandung.

2 Department of Internal Medicine, Faculty of Medicine, Padjadjaran University / Dr. Hasan Sadikin General Hospital Bandung.

3 Infectious Disease and Tropical Medicine Division, Department of Internal Medicine, Faculty of Medicine, Padjadjaran University / Dr. Hasan Sadikin General Hospital Bandung.

**Conflict-of-interest statement:** The authors declare that there is no conflict of interest regarding the publication of this paper.

**Open-Access:** This article is an open-access article which was selected by an in-house editor and fully peer-reviewed by external reviewers. It is distributed in accordance with the Creative Commons Attribution Non Commercial (CC BY-NC 4.0) license, which permits others to distribute, remix, adapt, build upon this work non-commercially, and license their derivative works on different terms, provided the original work is properly cited and the use is non-commercial. See: <http://creativecommons.org/licenses/by-nc/4.0/>

**Correspondence to:** Dolvy Girawan, Consultant of Gastroenterohepatology, Division of Gastroenterohepatology, Department of Internal Medicine Dr. Hasan Sadikin General Hospital / Faculty of Medicine University of Padjadjaran, Jl. Pasteur 38, Bandung 40161, Indonesia.

Email: [imeldg2@gmail.com](mailto:imeldg2@gmail.com)

Telephone: + (022) 82021011

Fax: + (022) 82021011

Received: December 29, 2020

Revised: January 15, 2021

Accepted: January 19, 2021

Published online: February 21, 2021

### ABSTRACT

**AIM:** Hepatitis C is a hepatitis C virus (HCV) infection that targets the liver and can cause fibrosis, cirrhosis, and eventually death. The treatment of hepatitis C has progressed considerably, the combination of sofosbuvir and daclatasvir with 92-100% SVR (Sustained

Virologic Response) can increase reversibility of compensated liver cirrhosis after sofosbuvir and daclatasvir therapy.

**MATERIALS AND METHODS:** This study used observational analytic study design. The subjects were hepatitis C compensated liver cirrhosis patients who received combination therapy sofosbuvir and daclatasvir in the Gastroentero-hepatology clinic of Dr. Hasan Sadikin Hospital Bandung from October 2017 until October 2018. In this study, measurement of liver fibrosis was carried out by using AST to Platelet Ratio Index (APRI) before therapy and SVR-12.

**RESULTS:** The study involved 23 patients. Most of the subjects were women, with an average age of 59.43 years (SD 11.31). All patients in this study have achieved SVR-24. According to the results, 91% of patients experienced a decrease in APRI scores after being treated with sofosbuvir/daclatasvir. There was a decrease in APRI score before therapy and after SVR 12 from 1.51 to 0.79, the change was 0.878 (95% CI: 0.536 - 1.480). There is a reversal in liver cirrhosis to be non-cirrhosis after being treated with sofosbuvir/daclatasvir which is characterized by a decrease in the APRI score < 1 by 80%.

**CONCLUSION:** The study concluded that the combination of sofosbuvir and daclatasvir in patients with compensated liver cirrhosis with hepatitis C had particularly good effectiveness and could reduce APRI scores.

**Key words:** APRI score; Compensated liver cirrhosis; Sofosbuvir; Daclatasvir

© 2021 The Authors. Published by ACT Publishing Group Ltd. All rights reserved.

Girawan D, Wiraswati O, Herbiyantoro A, Hartantri Y. Decrease in APRI Score in Compensated Liver Cirrhosis Patients Due to Hepatitis C After a Combination Therapy of Sofosbuvir and Daclatasvir. *Journal of Gastroenterology and Hepatology Research* 2021; **10(1)**: 3435-3440 Available from: URL: <http://www.ghrnet.org/index.php/joghr/article/view/3062>

### INTRODUCTION

Hepatitis C is an infection of the hepatitis C virus (HCV) which targets the liver and can cause fibrosis, most hepatic fibrosis that oc-

curs are asymptomatic unless hepatic cirrhosis has developed<sup>[1,2]</sup>. In Indonesia it is estimated 25 million people suffering from hepatitis B and C, as many as 50% of them develop into a chronic form of the disease and 10% develop into hepatic cancer<sup>[1]</sup>. According to the 2013 Riset Kesehatan Dasar, the Indonesian basic health survey, hepatitis C prevalence increased from 2.1% to 2.5%<sup>[3]</sup>. Hepatitis C mortality rates are also relatively high, those due to hepatocellular carcinoma is estimated as high as 12-16% in Caucasians<sup>[2]</sup>.

Aims of therapy in chronic hepatitis C is the eradication of the virus and prevention of complications such as fibrosis, cirrhosis, hepatocellular carcinoma, and eventually death. Antiviral therapy target is sustained serologic response, specifically Sustained Virologic Response (SVR) that is measured through HCV RNA examination. Therapy is administered to naïve patients and failed treatment patients with both compensated and decompensated liver disease<sup>[3]</sup>. Antiviral therapy is given in patients with decompensated hepatic cirrhosis and at the risk for hepatocellular carcinoma<sup>[1,4]</sup>. Therapy for hepatitis C has had advantages especially after the distribution of Direct Acting Anti Virus (DAA) medications<sup>[3,5]</sup>. In Indonesia, there are 2 types of DAAs included in the hepatitis C eradication program which are sofosbuvir and simeprevir and a combination of sofosbuvir and daclatasvir.

Measurement of hepatic fibrosis grading is important in determining the length of therapy, prognosis, and risk factors that may occur throughout the disease progress. Liver biopsy is still the gold standard in determining hepatic fibrosis grading, but this method has several disadvantages as it is invasive, subjective, reasonably expensive, and there are often errors in sample collection<sup>[5-11]</sup>. Thus, a non-invasive method was developed to grade hepatic fibrosis<sup>[3,6,9]</sup>.

There are other non-invasive markers, such as biomarkers from the blood that may replace liver biopsy, the AST (Aspartate Amino Transferase) score/platelet ratio (APRI). These examinations are easy to conduct as it only utilizes 2 indicators, AST and thrombocyte without complicated equations<sup>[3,12]</sup>.

DAA therapy development with considerably high SVR values provides hope for hepatitis C patients with fibrosis<sup>[13]</sup>. Several studies stated that necroinflammation and hepatic fibrosis were decreased by SVR<sup>[7,10,14,15]</sup>. Numerous studies mentioned a significant decrease in fibrosis in hepatitis C patients undergoing DAA therapy, which measured through liver biopsy, transient elastography, or biomarkers, however, there were very little studies on a population with hepatic cirrhosis measured using their APRI score. There are differences in the fibrotic changes in compensated and decompensated cirrhosis, SVR values are also lower than decompensated patients<sup>[16]</sup>.

This study aimed to assess the decrease in APRI score in the compensated hepatic cirrhosis population due to HCV who receiving a combination of sofosbuvir and daclatasvir. Henceforth, the result of this study is expected to be utilized as evaluation material for government intervention in managing hepatitis C infection.

## METHODS

### Study population

This was an observational analytic study. Subjects were HCV compensated liver cirrhosis patients receiving a combination of Sofosbuvir and daclatasvir in the Outpatient Gastroentero-hepatology clinic of Dr. Hasan Sadikin General Hospital Bandung from October 2017 to October 2018, with an inclusion criteria of 18 years old. Patients with eGFR < 60mL/minute, HIV and Hepatitis B coinfection, and incomplete laboratory data such as SGOT level data, thrombocyte, and HCV RNA before therapy and during SVR-12 examination were

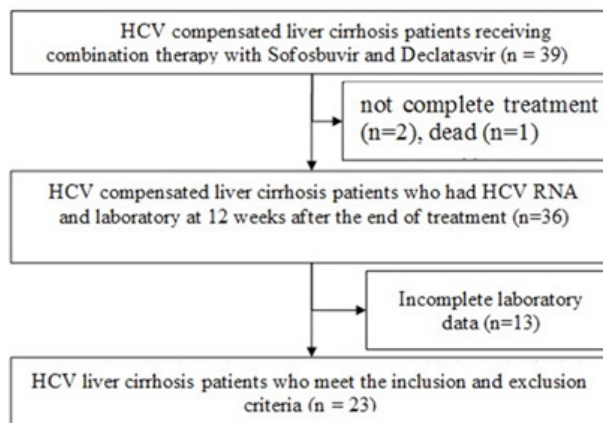


Figure 1 Research Chart.

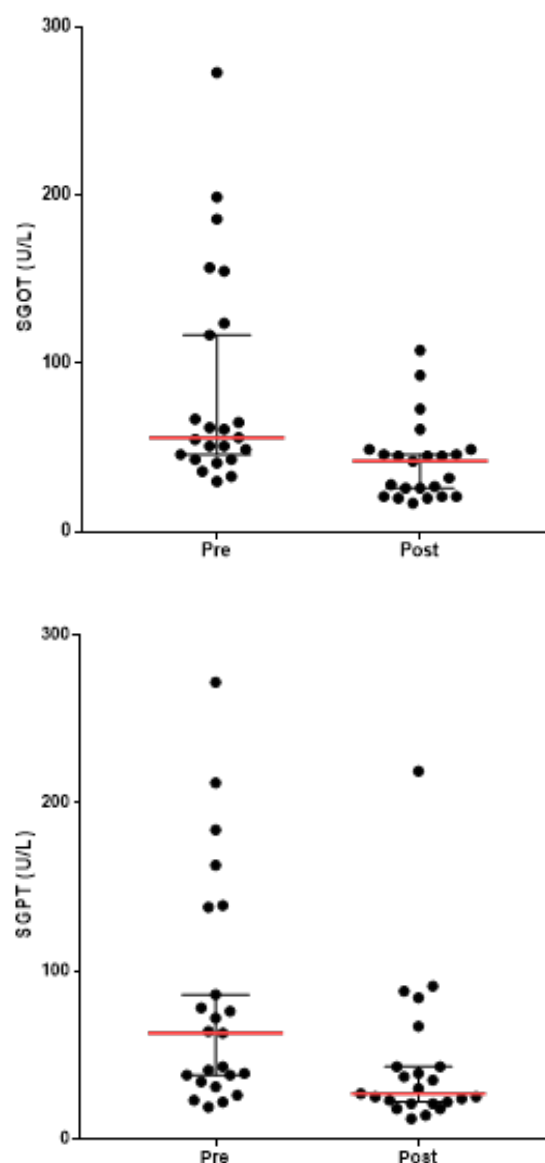
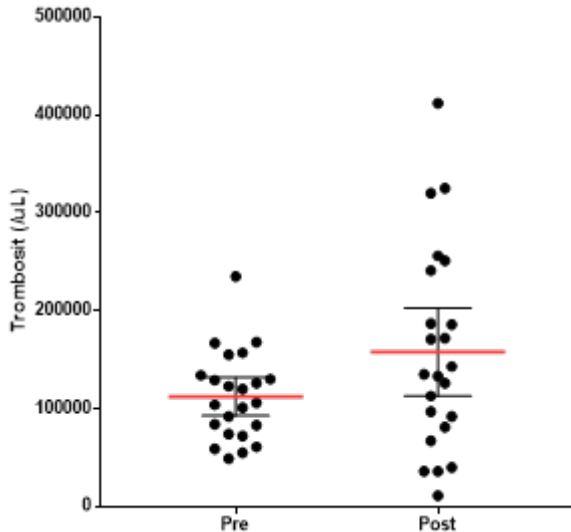
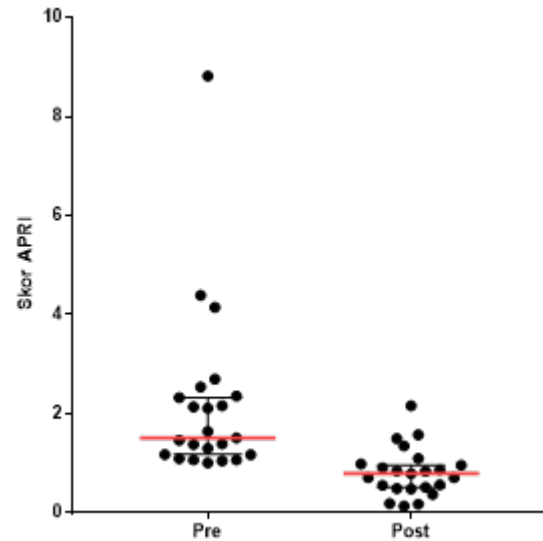


Figure 2 Scatter plot Differences in SGOT before and after sofosbuvir/daclatasvir administration.

excluded from the study. HCV infection was diagnosed both through anti-HCV antibody examination using electrochemiluminescence assay, ECLIA (Elecsys 2010, Roche), and HCV RNA examination,



**Figure 3** Scatter plot of Platelet Differences before and after sofosbuvir/daclatasvir administration.



**Figure 4** Scatter plot APRI Score Differences before and after sofosbuvir/daclatasvir administration.

**Table 1** Characteristics of research subjects based on Demographic and Laboratory Data of hepatitis c compensated liver cirrhosis patients administered a combination of sofosbuvir and daclatasvir.

Variable	n	%
Demographic data		
Sex		
Male	11	47.8
Female	12	52.2
Age		
Average (SD) :59,43 (11.31)		
Median (Minimum-Maximum) : 63 (36-77)		
36-45 years old	3	13
46-55 years old	5	21.7
56-65 years old	7	30.4
> 65 years old	8	34.8
Laboratory Data		
Pre-treatment SGOT		
Within normal limit (< 37)	4	17.3
Above normal (> 37)	19	82.7
Pre-treatment SGPT		
Within normal limit (<63)	11	47,8
Above normal (> 63)	12	52.2
Pre-treatment Thrombocyte		
Within normal limit (> 150000)	5	22
Below normal (< 150000)	18	78
Total	23	100

then APRI score was determined afterward. The study was designed as a retrospective cohort from medical record data. The subjects were graded using the AST Score to Platelet Ratio Index (APRI) before therapy and on SVR-12. In this study, from October 2017 to October 2018, as many as 23 patients fulfilling the inclusion criteria were included.

**Operational definition and data collection**

The operational definition of compensated liver cirrhosis are patients marked with APRI examination > 1 but from history taking there were no previous history of decreased consciousness, history of melena and hematemesis, and edema. In addition, during physical exami-

**Table 2** Normality test data before and after combination therapy of sofosbuvir and daclatasvir in hepatitis c compensated liver cirrhosis patients.

Variable		P-value	Description
APRI	Pre	< 0.001	Abnormal
	Post	0.122	Normal
SGOT	Pre	< 0.001	Abnormal
	Post	0.002	Abnormal
SGPT	Pre	0.001	Abnormal
	Post	< 0.001	Abnormal
Thrombocyte	Pre	0.239	Normal
	Post	0.234	Normal

Analysis using the Shapiro-Wilk Test

**Table 3** Overview of research subjects based on the values of SGOT, SGPT, Thrombocytes and APRI before and after combination therapy of sofosbuvir and daclatasvir.

Variable	Before Median (Min-Max)	After Median (Min-Max)	Difference (95% CI)	P value
SGOT	56 (30 - 273)	42 (17 - 108)	25 (12 - 47)	<0.001 <sup>b</sup>
SGPT	63 (19 - 272)	27 (12 - 219)	25 (4 - 43)	<0.001 <sup>b</sup>
Thrombocytes*	112.348 ± 45.004	157.870 ± 103.966	45.522 (8.714 - 82.330)	0.007 <sup>a</sup>
APRI	1,512 (1.011 - 8.817)	0,793 (0.138 - 2.162)	0,878 (0.536 - 1.480)	<0.001 <sup>b</sup>

\*mean ± standard deviation, analysis using <sup>a</sup> Paired t-test, <sup>b</sup> Wilcoxon test.

nation, there were no hepatic encephalopathy, ascites, icteric, flapping tremor, and edema found. A combination intervention of sofosbuvir and daclatasvir were administration of 400 mg sofosbuvir under the myHep trade name under the license of Gilead science Ireland UC to Gilead science India and myDekla 60mg under the license of Gilead science Ireland UC to Gilead science India in a period of 6 months. Thrombocyte levels were examined through a method of flow cytometry using Sysmex SN HE-038. AST levels were examined through a method of enzymatic calorimetric using Siemens Dimension EXL.

**Statistical Analysis**

Analysis to test the hypothesis in seeing the difference in APRI score before and after combination therapy of sofosbuvir and daclatasvir using the paired t-test if the data is distributed normally, and the Wil-

coxon test if the data is not distributed normally. Normality test using the Shapiro-wilk test, if  $p > 0.005$  is considered normal distribution.

## RESULTS

This research was conducted in the Outpatient Gastroentero-hepatology clinic of Dr. Hasan Sadikin General Hospital Bandung in 2017-2018. Subjects of this study were HCV compensated liver cirrhosis patients administered a combination of sofosbuvir and daclatasvir in the outpatient Gastroentero-hepatology polyclinic of Dr. Hasan Sadikin General Hospital Bandung fulfilling the inclusion and exclusion criteria. The total number of hepatic cirrhosis HCV patients administered a combination treatment of sofosbuvir and daclatasvir was 41 patients, 2 of which with decompensated cirrhosis and 39 of which with compensated cirrhosis. From a total of 39 patients, 1 patient died, 2 patients did not complete full treatment and 13 patients did not have complete data sets at 12 weeks after the end of treatment so only 23 patients were included in the study (Figure 1).

The normality test using the Shapiro-Wilk One sample test shows that only the thrombocytes had normal distribution while the other variables are not normally distributed ( $p < 0.05$ ), hence the statistical analysis for thrombocytes was done differently using the t-test, while the other variables were analyzed using the Wilcoxon test (Table 2).

The median value of pre-treatment SGOT and SGPT were 56 U/L and 63 U/L then declined after treatment of sofosbuvir and daclatasvir to 42 U/L and 27 U/L respectively (Figure 2). The increased of mean thrombocyte before and after treatment were observed, from  $112,348 \pm 45,004$  /uL to  $157,870 \pm 13,966$  / uL (Figure 3). Figure 4 revealed that APRI score had decreased from 1.51 to 0.79 between before and after treatment.

Table 3 shows results of the statistical test using the Wilcoxon test on the 95% confidence level indicate that there are significant differences in the values of SGOT, SGPT and APRI after combination therapy of sofosbuvir and daclatasvir with a value of  $p < 0.001$  ( $p$ -value  $< 0.05$ ). The statistical test using a t-test that there is an improvement in the median platelet value before combination therapy of sofosbuvir and daclatasvir in hepatitis c compensated liver cirrhosis patients at a 95% confidence level indicating that there are significant differences in thrombocyte value after combination therapy of sofosbuvir and daclatasvir in hepatitis c compensated liver cirrhosis patients with a value of  $p = 0.007$  (value  $p \leq 0.05$ ).

## DISCUSSION

This was an observational analytic, retrospective cohort study conducted through obtaining secondary data from medical records. Patients fulfilling the criteria for compensated cirrhosis in this study were judged based on their history of symptoms and physical examination performed at the Outpatient Gastroentero-hepatology Polyclinic in Dr. Hasan Sadikin General Hospital Bandung. Not all included patients had supporting examinations conducted such as ultrasound or transient elastography, while the gold standard in distinguishing compensated from decompensated cirrhosis is through liver biopsy<sup>[17,18]</sup>.

The results showed that from the total samples used in this study, all 23 patients achieved 100% SVR-12. This was consistent with several studies which state that SVR rates in monoinfected hepatitis C patients administered a combination therapy of sofosbuvir and daclatasvir reach 100%. The combination of these two drugs has a potent antiviral ability, capable of handling all viral genotypes, and can achieve 92-100% SVR in hepatitis C monoinfected patients<sup>[4,5,19-21]</sup>.

This study found that sex-wise there were more females (58.8%) than males (42.2%). This is inconsistent with research conducted by Barden, which stated that males were more exposed to hepatitis C virus infection compared to females. Productive-age women are said to have protection for their liver cells due to the hormones estrogen and estradiol, protecting their livers from fibrosis through a protective mechanism against oxidative stress, liver inflammation, and cell death<sup>[22]</sup>.

The hormones are also said to help spontaneous healing of hepatitis C infection, but this protection mechanism is not present in menopausal females. The same was stated in a research conducted in Europe, hepatitis C infection is more prevalent in males than females with a ratio of 2.1% and 1.1%<sup>[22-24]</sup>. A study conducted by Poynard et al stated that being male is one of the risk factors of hepatitis C progression<sup>[25]</sup>. However, several studies suggest that there is an increase in the incidence of liver fibrosis in menopausal females, hence the incidence of cirrhosis isn't significantly different between the two sexes<sup>[25]</sup>.

A study by Hayashi mentioned more specifics about the relationship of age with hepatitis C treatment outcomes in females, where they stated that females under the age of 40 years old with interferon alfa treatment have a higher SVR rate than females over 40 years old, this is consistent with the results of this study where the females are aged is 55 years old, with the eldest being 77 years old, although this study did not further examine the number of menopausal subjects in the study sample<sup>[23,26,27]</sup>.

The average age in this study was 59.43 with a standard deviation of 11.31, while the median age is 63 years old with the youngest age being 36 years old and the oldest being 77 years old (Table 1), consistent with the results of a study conducted by Gordon et al in 2015 which stated the average age of patients suffering from liver cirrhosis due to hepatitis C is  $58.5 \pm 8.9$ , with the incidence increasing along with age<sup>[28]</sup>.

In the results of this study, there was a significant change in response to liver function enzymes before and after treatment. As many as 20 of the total 23 patients or as much as 86% experienced a decrease in SGOT value. The median SGOT before treatment amounted to 56, decreased after treatment to 42 or decreased by 25%, and the average value of SGPT, 63 became 27 or decreased by 57%, this is consistent with the results of a study conducted by Deterding et al where they stated that the liver enzymes have a near-normal improvement in 77% of the overall study sample, as well as the SGPT results, which declined in value as much as 82%. This is associated with the cessation of the inflammatory processes that occur in the liver, which is characterized by a decrease in inflammatory cytokines in line with reduced damage to liver cells<sup>[29-32]</sup>. Patients who did not experience a decrease in liver function enzymes, both SGOT and SGPT, around 14-18%, experienced an increase in function, but the increase was no more than 2 times the upper limit of the normal values<sup>[29]</sup>.

Thrombocytopenia in hepatitis C is a problem caused by various factors, an autoimmune reaction with antiplatelet antibody production, enlargement of the spleen, and hepatitis C virus can also cause suppression of the bone marrow, causing thrombocytopenia. In this study, as many as 73% of the patients experienced an increase in thrombocyte value, thrombocyte average before the combination therapy of sofosbuvir and daclatasvir of  $112,348$  / uL with a standard deviation of  $45,004$  / uL<sup>[30,33]</sup>.

Thrombocytes after combination therapy of sofosbuvir and daclatasvir increased to  $157,870$  / uL with a standard deviation of  $103,966$  / uL. The average increase in thrombocytes is  $45,522$  / uL with 95% CI  $8,714 - 82,330$  / uL, using the Paired t-test statistical test with  $p$  values  $< 0.05$  (0.007). These results are in line with

studies conducted by Deterding where thrombocytes improved both during treatment and at the end of treatment to SVR 12. Research conducted by Dahal also revealed the same thing, that DAA treatment and achievement of SVR in hepatitis C patients could include thrombocyte repair. A study by Vandermeer involving 646 patients with 76% being cirrhotic patients, after achieving an SVR, experienced a platelet increase of 35,000 with  $p < 0.001$ <sup>[29-31,33,34]</sup>.

In this study, 91% or 21 out of 23 patients experienced a decrease in APRI score, and from the decreasing number, as much as 80% experienced a change from APRI score of cirrhosis ( $> 1$ ) to non-cirrhosis ( $< 1$ ), as a whole. There was a significant decrease in APRI scores from the median APRI score of 1.51 before treatment to 0.79 at 12 weeks after the end of treatment, with  $p < 0.001$ . This is consistent with the research conducted by Domazahvii et al in 2017 which stated that SVR can reduce the rate of liver fibrosis. The study involved 304 patients, comparing liver fibrosis before and 24 weeks after SVR using Transient Elastography (TE), which found a decrease in Liver Stiffness Measurement (LSM) from 16.9 (range 11.8-27.7) to 11.9 (range 8.2-20.9). 198 study participants (65.1%) experienced a decrease in liver fibrosis of at least 20%. Research in Switzerland by Bachofner et al. Also stated the same thing that SVR can reduce liver fibrosis, involving 549 patients, in which all patients received DAA. The median TE before DAA treatment was 12.65 kPa (IQR 9.45-19.2 kPa), while 18 months after treatment decreased to 8.55 kPa (IQR 5.93-15.25), with  $p < 0.001$ . The median FIB-4 index and APRI score also decreased significantly from 2.54 (IQR 1.65-4.43) and 1.10 (IQR 0.65-2.43) to 1.80 (IQR 1.23-2.84,  $p < 0.001$ ) and 0.43 (IQR 0.3-0.79),  $p < 0.001$ <sup>[7,32,35,36]</sup>.

The concept of liver fibrosis reversal as reflected in a decrease in APRI score may be associated with a decrease in active hepatic stellate cells both experiencing apoptosis and re-becoming quiescent. This can be due to the loss of inflammatory signals, one of which originates from chronic viral inflammation. Therefore, it is very important for the target of hepatitis C therapy for virus eradication which is characterized by SVR. The mechanism of sofosbuvir and daclatasvir is to prevent viral replication by inhibiting the formation of protein viruses and inhibiting the replication of new RNA viruses. Hepatic stellate cells that turn into myofibroblasts during fibrogenesis will become inactive and can eliminate all pathways that cause fibrogenesis, such as lipopolysaccharide, inflammatory cytokines (TNF- $\alpha$  and interferon  $\gamma$ ), and production of ROS (Reactive Oxygen Species) in kuppfer cells. All of these pathways will impact the degradation of the extracellular matrix which was previously induced by myofibroblast and is also a component that forms fibrosis. This concept of reversal fibrosis indirectly improves liver function marked by a decrease in APRI score<sup>[37]</sup>.

## CONCLUSION

There is a significant decrease in the APRI score after combination therapy of sofosbuvir and daclatasvir in compensated hepatic cirrhosis patients in the Outpatient Gastroentero-hepatology Polyclinic in Hasan Sadikin General Hospital Bandung. There was a decrease in the median APRI value as much as 0,878 with 95% CI 0.536 - 1.480. There was a decrease in the median SGOT value as much as 25 U/L with 95% CI 12 - 47 U/L, statistically tested using the Wilcoxon test with a  $p$ -value  $< 0.001$ . There was a decrease in the median SGPT value as much as 25 U/L with 95% CI 4 - 43 U/L, statistically tested using the Wilcoxon test with a  $p$ -value of 0.001. There was a significant increase in the thrombocyte mean increase as much as 45.522 /uL with 95% CI 8.714 - 82.330 /uL, statistically

tested using the Paired t-test with a  $p$ -value of  $p = 0.007$ .

## ACKNOWLEDGMENT

DG, OW, AH and YH conceived and designed the study. OW acquired the data. All authors contributed to the writing of the manuscript.

## REFERENCES

- Gani RA, Setiati S, Sudoyo A, Simadibrata M, Setiyohadi B, Syam A. Hepatitis C. In Textbook of Internal Medicine. 5<sup>th</sup> ed. Jakarta: Interna Publishing, 2014: 1972-7.
- Petruzzello A, Marigliano S, Loquercio G, Cozzolino A, Cacciapuoti C. Global epidemiology of hepatitis C virus infection: An up-date of the distribution and circulation of hepatitis C virus genotypes. *World J Gastroenterol.* 2016; **22(34)**: 7824-40. [PMID: 27678366]; [DOI: 10.3748/wjg.v22.i34.7824]
- Indonesia PPH. National consensus on Hepatitis C treatment. Jakarta: Indonesia PPH, 2017.
- Abdel-Aziz AM, Ibrahim MA, El-Sheikh AA, Kamel MY, Zenhom NM, Abdel-Raheim S, Abdelhaleem H. Effect of Sofosbuvir Plus Daclatasvir in Hepatitis C Virus Genotype-4 Patients: Promising Effect on Liver Fibrosis. *Journal of clinical and experimental hepatology.* 2018; **8(1)**: 15-22. [PMID: 29743792]; [DOI: 10.1016/j.jceh.2017.06.006]
- Gao M, Nettles RE, Belema M, Snyder LB, Nguyen VN, Fridell RA, Serrano-Wu MH, Langley DR, Sun JH, O'Boyle DR 2nd, Lemm JA, Wang C, Knipe JO, Chien C, Colonno RJ, Grasela DM, Meanwell NA, Hamann LG. Chemical genetics strategy identifies an HCV NS5A inhibitor with a potent clinical effect. *Nature.* 2010; **465(7294)**: 96-100. [PMID: 20410884]; [DOI: 10.1038/nature08960]
- AASLD/IDSA HCV Guidance Panel. Hepatitis C guidance: AASLD-IDSA recommendations for testing, managing, and treating adults infected with hepatitis C virus. *Hepatology.* 2015; **62(3)**: 932-54. [PMID: 26111063]; [DOI: 10.1002/hep.27950].
- Dolmazashvili E, Abutidze A, Chkhartishvili N, Karchava M, Sharvadze L, Tsertsvadze T. Regression of liver fibrosis over a 24-week period after completing direct-acting antiviral therapy in patients with chronic hepatitis C receiving care within the national hepatitis C elimination program in Georgia: results of hepatology clinic HEPA experience. *Eur J Gastroenterol Hepatol.* 2017; **29(11)**: 1223-1230. [PMID: 28857900]; [DOI: 10.1097/MEG.0000000000000964]
- Patch D, Luong TV. Biopsy of the liver. In Sherlock's Diseases of the Liver and Biliary System. 13<sup>th</sup> ed. UK: John Wiley & Sons Ltd, 2018.
- Carrara R, Ferrarese A, Franceschet E, Zanetto A, Gambato M, Floreani A, Farinati F, Burra P, Russo FP. Non-invasive evaluation of change in liver fibrosis after viral eradication in patients with HCV related cirrhosis. *Digestive and Liver Disease.* 2018; **50(1)**: 61. [DOI: 10.1016/j.dld.2018.01.077]
- Shiffman ML, Sterling RK, Contos M, Hubbard S, Long A, Luketic VA, Stravitz RT, Fuchs M, Sanyal AJ. Long term changes in liver histology following treatment of chronic hepatitis C virus. *Ann Hepatol.* 2014; **13(4)**: 340-349. [Available from: URL: <https://www.medigraphic.com/cgi-bin/new/resumenI.cgi?IDARTICULO=57966>]
- Tada T, Kumada T, Toyoda H, Mizuno K, Sone Y, Kataoka S, Hashinokuchi S. Improvement of liver stiffness in patients with hepatitis C virus infection who received direct-acting antiviral therapy and achieved sustained virological response. *J Gastroenterol Hepatol.* 2017; **32(12)**: 1982-1988. [PMID: 28299813]; [DOI: 10.1111/jgh.13788]
- Trivedi HD, Lin SC, T Y Lau D. Noninvasive Assessment of Fibrosis Regression in Hepatitis C Virus Sustained Virologic

- Responders. *Gastroenterol Hepatol (N Y)*. 2017; **13(10)**: 587-595. [PMID: 29391861]
13. Grgurevic I, Bozin T, Madir A. Hepatitis C is now curable, but what happens with cirrhosis and portal hypertension afterwards?. *Clinical and experimental hepatology*. 2017; **3(4)**: 181-6. [PMID: 29255805]; [DOI: 10.5114/ceh.2017.71491]
  14. Afdhal N, Zeuzem S, Kwo P, Chojkier M, Gitlin N, Puoti M, Romero-Gomez M, Zarski JP, Agarwal K, Buggisch P, Foster GR, Brau N. Ledipasvir and sofosbuvir for untreated HCV genotype 1 infection. *N Engl J Med*. 2014; **370(20)**: 1889-98. [DOI: 10.1056/NEJMoa1402454]
  15. European Association for the Study of the Liver. Electronic address: easloffice@easloffice.eu. EASL Recommendations on Treatment of Hepatitis C 2016. *J Hepatol*. 2017; **66(1)**: 153-194. [PMID: 27667367]; [DOI: 10.1016/j.jhep.2016.09.001]
  16. Garg G, Dixit VK, Shukla SK, Singh SK, Sachan S, Tiwari A, Yadav VK, Yadav DP. Impact of Direct Acting Antiviral Drugs in Treatment Naïve HCV Cirrhosis on Fibrosis and Severity of Liver Disease: A Real Life Experience from a Tertiary Care Center of North India. *J Clin Exp Hepatol*. 2018; **8(3)**: 241-249. [PMID: 30302040]; [DOI: 10.1016/j.jceh.2017.11.011]
  17. Muir AJ. Understanding the Complexities of Cirrhosis. *Clin Ther*. 2015; **37(8)**: 1822-36. [PMID: 26188836]; [DOI: 10.1016/j.clinthera.2015.05.507]
  18. D'Amico G, Pasta L, Morabito A, D'Amico M, Caltagirone M, Malizia G, Tinè F, Giannuoli G, Traina M, Vizzini G, Politi F, Luca A, Virdone R, Licata A, Pagliaro L. Competing risks and prognostic stages of cirrhosis: a 25-year inception cohort study of 494 patients. *Aliment Pharmacol Ther*. 2014; **39(10)**: 1180-93. [PMID: 24654740]; [DOI: 10.1111/apt.12721].
  19. Sulkowski MS, Gardiner DF, Rodriguez-Torres M, Reddy KR, Hassanein T, Jacobson I, Lawitz E, Lok AS, Hinestrosa F, Thuluvath PJ, Schwartz H, Nelson DR, Everson GT, Eley T, Wind-Rotolo M, Huang SP, Gao M, Hernandez D, McPhee F, Sherman D, Hindes R, Symonds W, Pasquinelli C, Grasela DM; A1444040 Study Group. Daclatasvir plus sofosbuvir for previously treated or untreated chronic HCV infection. *N Engl J Med*. 2014 Jan 16; **370(3)**: 211-21. [PMID: 24428467]; [DOI: 10.1056/NEJMoa1306218]
  20. Sulkowski MS, Jacobson IM, Nelson DR. Daclatasvir plus sofosbuvir for HCV infection. *N Engl J Med*. 2014; **370(16)**: 1560-1. [DOI: 10.1056/NEJMc1401726]
  21. Iacob S, Cerban R, Pietrareanu C, Ester C, Iacob R, Gheorghe C, Popescu I, Gheorghe L. 100% sustained virological response and fibrosis improvement in real-life use of direct acting antivirals in genotype-1b recurrent hepatitis C following liver transplantation. *J Gastrointest Liver Dis*. 2018; **27(2)**: 139-144. [PMID: 29922758]; [DOI: 10.15403/jgld.2014.1121.272.100]
  22. Baden R, Rockstroh JK, Buti M. Natural history and management of hepatitis C: does sex play a role?. *J Infect Dis*. 2014; **209(Suppl 3)**: S81-5. [PMID: 24966194]; [DOI: 10.1093/infdis/jiu057]
  23. Rantala M, van de Laar MJ. Surveillance and epidemiology of hepatitis B and C in Europe - a review. *Euro Surveill*. 2008; **13(21)**: 18880. [PMID: 18761967]; [DOI: 10.2807/ese.13.21.18880-en]
  24. Wiese M, Fischer J, Löbermann M, Göbel U, Grüngreif K, Günthoff W, Küllig U, Richter F, Schiefke I, Tenckhoff H, Zipprich A, Berg T, Müller T; East German HCV Study Group. Evaluation of liver disease progression in the German hepatitis C virus (1b)-contaminated anti-D cohort at 35 years after infection. *Hepatology*. 2014; **59(1)**: 49-57. [PMID: 23929603]; [DOI: 10.1002/hep.26644]
  25. Poynard T, Bedossa P, Opolon P. Natural history of liver fibrosis progression in patients with chronic hepatitis C. The OBSVIRC, METAVIR, CLINIVIR, and DOSVIRC groups. *Lancet*. 1997; **349(9055)**: 825-32. [PMID: 9121257]; [DOI: 10.1016/s0140-6736(96)07642-8]
  26. Villa E, Vukotic R, Cammà C, Petta S, Di Leo A, Gitto S, Turolo E, Karampatou A, Losi L, Bernabucci V, Cenci A, Tagliavini S, Baraldi E, De Maria N, Gelmini R, Bertolini E, Rendina M, Francavilla A. Reproductive status is associated with the severity of fibrosis in women with hepatitis C. *PLoS One*. 2012; **7(9)**: e44624. [PMID: 22970270]; [DOI: 10.1371/journal.pone.0044624]
  27. Hayashi J, Kishihara Y, Ueno K, Yamaji K, Kawakami Y, Furusyo N, Sawayama Y, Kashiwagi S. Age-related response to interferon alfa treatment in women vs men with chronic hepatitis C virus infection. *Arch Intern Med*. 1998; **158(2)**: 177-81. [PMID: 9448556]; [DOI: 10.1001/archinte.158.2.177]
  28. Gordon SC, Lamerato LE, Rupp LB, Holmberg SD, Moorman AC, Spradling PR, Teshale E, Xu F, Boscarino JA, Vijayadeva V, Schmidt MA, Oja-Tebbe N, Lu M. Prevalence of cirrhosis in hepatitis C patients in the Chronic Hepatitis Cohort Study (CHeCS): a retrospective and prospective observational study. *Am J Gastroenterol*. 2015; **110(8)**: 1169-77; quiz 1178. [PMID: 26215529]; [DOI: 10.1038/ajg.2015.203]
  29. Deterding K, Höner zu Siederdisen C, Port K, Solbach P, Sollik L, Kirschner J, Mix C, Cornberg J, Worzala D, Mix H, Manns MP, Cornberg M, Wedemeyer H. Improvement of liver function parameters in advanced HCV-associated liver cirrhosis by IFN-free antiviral therapies. *Aliment Pharmacol Ther*. 2015; **42**: 889-901. [DOI: 10.1111/apt.13343]
  30. Ji F, Wang W, Dang S, Wang S, Li B, Bai D, Zhao W, Deng H, Tian C, Li Z. Outcomes after sofosbuvir-containing regimens for hepatitis C virus in patients with decompensated cirrhosis: a real-world study. *Infect Agent Cancer*. 2017; **12**: 48. [PMID: 28924449]; [DOI: 10.1186/s13027-017-0158-1]
  31. Mohamed MS, Hanafy AS, Bassiony MAA, Hussein S. Sofosbuvir and daclatasvir plus ribavirin treatment improve liver function parameters and clinical outcomes in Egyptian chronic hepatitis C patients. *Eur J Gastroenterol Hepatol*. 2017; **29(12)**: 1368-72. [PMID: 28953002]; [DOI: 10.1097/meg.0000000000000963]
  32. Khan ST, McGuinty M, Corsi DJ, Cooper CL. Liver enzyme normalization predicts success of Hepatitis C oral direct-acting antiviral treatment. *Clinical and investigative medicine Medecine clinique et experimentale*. 2017; **40(2)**: E73-E80. [DOI: 10.25011/cim.v40i2.28198]
  33. van der Meer AJ, Maan R, Veldt BJ, Feld JJ, Wedemeyer H, Dufour JF, Lammert F, Duarte-Rojo A, Manns MP, Zeuzem S, Hofmann WP, de Knegt RJ, Hansen BE, Janssen HL. Improvement of platelets after SVR among patients with chronic HCV infection and advanced hepatic fibrosis. *J Gastroenterol Hepatol*. 2016; **31(6)**: 1168-76. [PMID: 26647353]; [DOI: 10.1111/jgh.13252]
  34. Dahal S, Upadhyay S, Banjade R, Dhakal P, Khanal N, Bhatt VR. Thrombocytopenia in Patients with Chronic Hepatitis C Virus Infection. *Mediterr J Hematol Infect Dis*. 2017; **9(1)**: e2017019. [PMID: 28293407]; [DOI: 10.4084/MJHID.2017.019]
  35. Bachofner JA, Valli PV, Kröger A, Bergamin I, Künzler P, Baserga A, Braun D, Seifert B, Moncsek A, Fehr J, Semela D, Magenta L, Müllhaupt B, Terziroli Beretta-Piccoli B, Mertens JC. Direct antiviral agent treatment of chronic hepatitis C results in rapid regression of transient elastography and fibrosis markers fibrosis-4 score and aspartate aminotransferase-platelet ratio index. *Liver Int*. 2017; **37(3)**: 369-376. [PMID: 27678216]; [DOI: 10.1111/liv.13256]
  36. Tao YC, Deng R, Wang ML, Lv DD, Yuan M, Wang YH, Chen EQ, Tang H. Satisfactory virological response and fibrosis improvement of sofosbuvir-based regimens for Chinese patients with hepatitis C virus genotype 3 infection: results of a real-world cohort study. *Viral J*. 2018; **15(1)**: 150. [PMID: 30285800]; [DOI: 10.1186/s12985-018-1066-8]
  37. Jung YK, Yim HJ. Reversal of liver cirrhosis: current evidence and expectations. *Korean J Intern Med*. 2017; **32(2)**: 213-228. [PMID: 28171717]; [DOI: 10.3904/kjim.2016.268]