

# Journal of Gastroenterology and Hepatology Research

Online Submissions: <http://www.ghrnet.org/index./joghr/>  
doi: 10.6051/j.issn.2224-3992.2012.02.029

Journal of GHR 2012 February 21; 1(1): 11-15  
ISSN 2224-3992 (print) ISSN 2224-6509 (online)

## CASE REPORT

### A Prospective Study Comparing Real Time Video Capsule Endoscopy to Standard Endoscopy in Patients with Suspected Upper Gastrointestinal Bleeding

Arkady Broder, Timothy C Johnson, David P Hudesman, Jonathan Mazurek, Frank Chateau, Brett B Bernstein

Arkady Broder, Timothy C Johnson, David P Hudesman, Jonathan Mazurek, Frank Chateau, Brett B Bernstein, Division of Digestive Disease, Beth Israel Medical Center 350 East 17th Street, 17th Floor, New York, NY, 10003, United States  
Jonathan Mazurek, Department of Medicine, Beth Israel Medical Center 350 East 17th Street, 20th Floor, New York, NY, 10003, United States

Correspondence to: Arkady Broder, MD, Division of Digestive Disease, Beth Israel Medical Center 350 East 17th Street, 17th Floor, New York, NY, 10003, United States. [abroder@chpnet.org](mailto:abroder@chpnet.org)

Telephone: +1-212-844-1832 Fax: +1-212-420-4373

Received: December 11, 2011 Revised: January 23, 2012

Accepted: January 31, 2012

Published online: February 21, 2012

**Keywords:** Upper gastrointestinal bleeding (UGIB); Video capsule endoscopy (VCE); Real time video capsule endoscopy (RT-VCE); Official video capsule endoscopy (O-VCE)

Broder A, Johnson TC, Hudesman DP, Mazurek J, Chateau F, Bernstein BB. A Prospective Study Comparing Real Time Video Capsule Endoscopy to Standard Endoscopy in Patients with Suspected Upper Gastrointestinal Bleeding. *Journal of Gastroenterology and Hepatology Research* 2012; 1(1): 11-15 Available from: URL: <http://www.ghrnet.org/index./joghr/>

## ABSTRACT

To determine the diagnostic yield, quality of risk stratification, and patient tolerability of real time video capsule endoscopy (RT-VCE) as compared to standard upper endoscopy and official video capsule endoscopy (O-VCE) in patients presenting with UGIB. A total of 20 patients were evaluated during our trial period. An official interpretation of the VCE (O-VCE) was performed by an experienced endoscopist and documented before the end of the day. Overall cumulative findings and their clinical significance were evaluated using the RT-VCE and O-VCE interpretations as compared to gold standard EGD. The level of agreement in individual re-bleeding risk was compared using EGD versus VCE obtained Rockall scores. A questionnaire on patient tolerability and satisfaction was administered after both procedures were completed. Prospective analysis revealed that EGD and RT-VCE identified both low acuity and high acuity lesion at statistically similar rates (79% vs. 68%,  $p=0.157$ , and 21% vs. 32%,  $p=0.157$  respectively). There was high level of agreement between the post endoscopy Rockall scores obtained for RT-VCE, O-VCE and EGD (Spearman correlation coefficient of 0.97 and 0.86 respectively,  $p<0.0001$ ). Real time capsule endoscopy was the self reported preferable diagnostic test of choice. RT-VCE has similar lesion detection rates when compared to both standard EGD and O-VCE, and may serve as a risk stratification tool in patients who present with suspected UGIB, and are at high risk for cardiopulmonary complications from EGD.

## INTRODUCTION

Upper gastrointestinal hemorrhage accounts for more than 400 000 hospital admissions per year. The majority of upper gastrointestinal bleeds (80 to 90%) are classified as non-variceal, with gastroduodenal peptic ulcer being most common<sup>[1]</sup>.

Mortality associated with peptic ulcer bleeding remains as high as 5-10%, despite advances in endoscopic diagnostic and therapeutic options<sup>[1]</sup>. In the United States estimated direct medical costs for the in-patient care of peptic ulcer related bleeding total more than \$2 billion annually<sup>[2]</sup>.

In an emergent setting, immediate endoscopic support carries with it the risk of sedation induced cardiopulmonary complications which account for a majority of the potential EGD related complications<sup>[3]</sup> thereby at times limiting the therapeutic and diagnostic utility of EGD. Additionally, early endoscopy in low to moderate risk patients is likely to be of little long-term clinical benefit<sup>[4]</sup>. This dilemma often leaves clinicians with a greater need to accurately, safely, and rapidly risk-stratify patients presenting with upper gastrointestinal bleeding (UGIB). Several risk stratification tools have been established to help triage patients presenting with UGIB. The 11 point Rockall score is probably the most widely known risk-stratification scale and has been validated in numerous health care settings<sup>[5]</sup>. Furthermore, the Rockall score has been shown to best identify patients at low risk for re-bleeding and mortality<sup>[6]</sup>.

## BACKGROUND

Video capsule endoscopy (VCE) is a technology that has been FDA approved for the detection of bleeding in the gastrointestinal tract. Since it was introduced in 2000 video capsule endoscopy has become a gold standard for the investigation of patients with obscure gastrointestinal bleeding<sup>[7]</sup>, as well as other intestinal diseases,

including inflammatory bowel disease and celiac disease. There is little evidence, however, for the application of VCE technology in the risk stratification of patients with suspected acute upper gastrointestinal bleeding.

CE has high positive (95%) and negative predictive values (83–100%), demonstrating the best clinical accuracy in patients in whom ongoing gastrointestinal bleeding is suspected<sup>[8]</sup>. Recent clinical investigations have suggested that even if the culprit lesion is not directly visualized, CE during an acute bleeding episode may determine the location of the bleeding with subsequent impact on therapy and clinical outcomes<sup>[9,10]</sup>. In recent years a real-time viewer compatible with VCE has become available for the immediate evaluation of gastrointestinal pathology. After the patient swallows the standard video capsule, a portable tablet computer allows for live viewing, image backup and even remote transmission of obtained images.

There is only one other study evaluating this novel technology for its use in acute UGIB<sup>[11]</sup>. We aimed to prospectively determine the diagnostic yield, quality of risk assessment, and patient tolerability of the real-time video capsule as compared to the gold standard upper endoscopy in patients presenting with acute upper gastrointestinal hemorrhage.

## METHODS

A total of 20 patients that presented to the emergency department or were admitted to our medical facility with a presumed diagnosis of UGIB from October 2007 to May 2008 were consecutively enrolled in the pilot study. Inclusion criteria included all patients who were able to tolerate an endoscopic procedure, and able to provide consent for the endoscopic studies. Additionally, patients included were those with presumed non-emergent UGIB, defined as those who had a history of melena and/or coffee ground emesis, but did not exhibit signs and symptoms of hemodynamic instability. Exclusion criteria included the need for urgent endoscopy in those patients who had evidence of ongoing bleeding, such as persistent hematemesis, hematochezia, or hemodynamic instability. Patients who were unable to give informed consent, had a GI tract related procedure within the previous 30 days, or had known contraindications to capsule endoscopy (such as intestinal obstruction, implantable electronic devices, and difficulty swallowing) were also excluded.

The identity of patients and their medical records were kept confidential and the study protocol was approved by the institutional review board (IRB) of Beth Israel Medical Center. After completing an IRB approved informed consent, each subject first underwent real-time video capsule endoscopy (RT-VCE) using the M2A Pillcam (Given Imaging Ltd, Yoqneam, Israel). The studies were conducted in the emergency department or the endoscopy suite within 24 h of presentation. The RT-VCE is similar to standard capsule endoscopy; a set of electrodes were placed on the skin of the abdominal wall with real-time viewing made possible by linking a hard disk worn by the patient to a portable tablet computer at the patient's bedside. The size of the resulting image is 640-480 pixels, allowing for an adequate analysis of the study<sup>[12]</sup>. The real-time images were viewed until the M2A Pillcam reached the second portion of the duodenum. To aid in transit time, patients in whom the duodenum was not visualized after 30 min were given 10mg IV metoclopramide. Patients were subsequently taken to the endoscopy suite for a complete EGD performed by an experienced endoscopist. An official interpretation of the VCE (O-VCE) was performed by an experienced endoscopist and documented before the end of the day. The endoscopist who performed the EGD was blinded to the results of the VCE and vice versa.

Patient data regarding age, gender, procedure indications, baseline hemoglobin levels, comorbid conditions, need for prokinetics

administration, complication rates, and study results were collected. RT-VCE is a relatively new advance in capsule endoscopy, and as such there is likely a variable learning curve in interpreting video imaging. In an attempt to elucidate the precision of diagnostic interpretation of RT-VCE pathology, we compared endoscopist observations during real time viewing (RT-VCE) versus the standard video capsule endoscopy interpretation methodology (O-VCE). Overall cumulative findings and their clinical significance were evaluated using the RT-VCE and O-VCE interpretations as compared to gold standard EGD. To allow for statistical sub analysis and a more accurate comparison of pathology, study findings were grouped into two major categories, low acuity and high acuity lesions. Low acuity lesions included findings of gastritis, duodenitis, gastrointestinal polyps, red spots, and gastropathy that would not typically require emergent endoscopy and/or invasive therapy (Figure 1a and 1b). The second group of findings included gastro-duodenal ulcers, fresh blood, and arteriovenous malformation, which typically would require invasive therapies, such as endoscopic hemostasis, interventional angiography with possible embolization, and surgical intervention (Figure 2a and 2b).

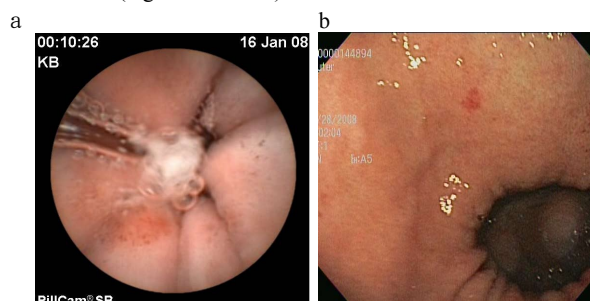


Figure 1 a:VCE Low Acuity; b: EGD Low Acuity.

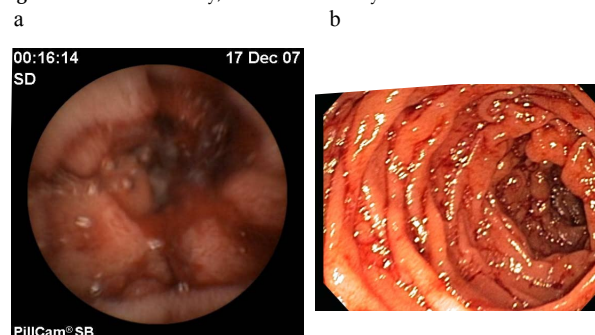


Figure 1 a: VCE High Acuity; b: EGD High Acuity.

The previously validated Rockall post-endoscopy scores were obtained for both VCE and EGD separately, by an operator blinded to either study. The level of agreement in individual re-bleeding risk was compared using EGD versus VCE obtained Rockall scores.

A questionnaire on patient tolerability and satisfaction was administered after both procedures were completed. The questionnaire consisted of a total of 4 questions. The patients were asked to rank on a scale of 0-9 the level of discomfort experienced during VCE versus EGD, they were also asked to report the preferred procedure and should a repeat study be necessary their preference in procedure type.

## Statistical Analysis

Spearman comparison coefficients<sup>[13]</sup> were measured to detect the level of correlation between Rockall scores obtained from patients who underwent RT-VCE versus EGD. In those patients whose Rockall

scores did not correlate 100% of the time (Spearman coefficient=1), we conducted a subanalysis to determine the number of units the RT-VCE obtained score differed from the EGD obtained score. Descriptive statistical analyses were performed to evaluate any related trends in patient demographics and procedure findings. A two tailed Fisher exact test was performed to calculate *p* values for the comparison of findings between VCE findings and gold standard EGD. A *p* value <0.05 was considered statistically significant.

## RESULTS

A total of 20 patients who met enrollment criteria for the prospective portion of our pilot study were analyzed (Table 1). The average age was 65, with mostly males (65%) comprising the study population. The vast majority of the cohort (85%) presented with a recent history of melena, with the remaining presenting with coffee ground emesis. The average hemoglobin concentration at the time of presentation was 7.5 g/dL. A previous history of UGIB was reported in 30% of the study population. Seventy percent of the patients had a history of clinically significant cardiac disease and would normally be considered at moderate-high risk to undergo conscious sedation for the purpose of EGD. All of the patients were given a PPI pre-endoscopy. After 30 min of study time the duodenum was not visualized in 35% of the cohort, requiring 10mg IV metoclopramide to aid in gastric transit. The mean gastric transit time was 25 min. In total the real time capsule reached the duodenum in 85% (17/20) of subjects, while in 15% (3/20) of subjects the VCE did not reach the duodenum due to a hiatal hernia, equipment malfunction, and a case of gastroparesis refractory to metoclopramide. Among the 3 patients in whom the duodenum was not reached only 1 patient had a non-diagnostic study and was excluded from final analysis.

**Table 1 Prospective Pilot Study Patient Characteristics.**

Parameter	Value
Average Age	65 years
<b>Gender</b>	
Male	65% (13/20)
<b>Indication</b>	
Melena	85% (17/20)
Coffee Ground Emesis	15% (3/20)
<b>Comorbidities</b>	
Previous History of UGIB	30% (6/20)
<sup>a</sup> Cardiac Disease	70% (14/20)
<b>Average Hgb</b>	7.5 g/dL
<sup>b</sup> High Risk Medication	70% (14/20)
<sup>c</sup> Pre-Endoscopy PPI	
Intravenous	30% (14/20)
Oral	70% (14/20)
<sup>d</sup> Prokinetic Therapy for RT-VCE	35% (7/20)
<b>Duodenum Reached</b>	85% (17/20)
<b>Mean Gastric Transit</b>	25 min
<b>Complications</b>	
RT-VCE	None
EGD	None
<b>Treatment</b>	
Medical Management	80% (16/20)
Surgical Intervention	20% (4/20)

<sup>a</sup> Cardiac disease: defined as clinically apparent CAD and CHF; <sup>b</sup> High risk medication: includes NSAIDS, aspirin, clopidogrel and warfarin;

<sup>c</sup> PPI: proton pump inhibitors; Hgb: Hemoglobin concentration on admission; <sup>d</sup> Pro-Kinetic therapy: patients in whom the duodenum was not visualized after 30 minutes were given 10mg IV metoclopramide; UGIB: Upper gastrointestinal bleeding.

After diagnosis of the source of bleeding, the majority (80%; 16/20) of the study population did not require invasive endoscopic intervention and were treated with PPI's alone. The other 4 patients (20%) received invasive endoscopic therapy. Of the 4 patients who needed endoscopic therapy, 2 patients had bleeding gastric polyps and were successfully treated with hemostatic clips. One patient had an actively bleeding gastric lipoma successfully treated with two hemostatic clips and bipolar cautery. One patient with an actively bleeding gastric adenocarcinoma required surgical intervention, despite two endoscopic attempts at hemostasis.

Overall, clinically significant pathologic findings (total N=40) were identified at fairly similar rates during both O-VCE and corresponding EGD examinations (Table 2a). Video capsule endoscopy was relatively better at identifying pathologic vascular lesions as a cause of UGIB.

The mean Rockall scores (0-11) for RT-VCE and O-VCE versus gold standard EGD were 3, 2.95, and 2.9 respectively. The level of agreement between the Rockall scores obtained for O-VCE versus EGD were highly in concurrence, with a Spearman correlation coefficient of 0.86 (*p*<0.0001). When compared within one Rockall unit the RT-VCE findings exhibited an ever higher level of agreement with EGD pathology, reflected by an almost perfect Spearman correlation of 0.97 (*p*<0.0001, Table 2b).

**Table 2a Prospective Comparison of Lesion Type Detected on EGD vs. O-VCE.**

Catego	EGD	O-VCE
Gastroduodenitis	35% (14/40)	26% (10/38)
Esophagitis	0% (0/40)	2.6% (1/38)
Gastroduodenal Polyps	5% (2/40)	2.6% (1/38)
Portal Gastropathy	2.5% (1/40)	8% (3/38)
Unremarkable Exam	5% (2/40)	5% (2/38)
Vascular Lesions	2.5% (1/40)	13% (5/38)

O-VCE: official video capsule reading done by an experienced endoscopist.

**Table 2b Comparison of Prospective Study Findings.**

Category	EGD	RT-VCE	O-VCE
Mean Rockall Score	2.9	3	2.95
Spearman Coefficient Rockall Score (O-VCE vs. EGD)		0.86 ( <i>p</i> <0.0001)	
Spearman Coefficient Rockall Score (RT-VCE vs. O-VCE)		0.97 ( <i>p</i> <0.0001)	

RT-VCE: denotes real time video capsule, which is the diagnostic reading obtained by an experienced endoscopist during live viewing; O-VCE: denotes an official video capsule reading done by an experienced endoscopist using the Rockall score was based on the standard complete score 0-11

Rockall scores for EGD and O-VCE were also found to be clinically equivalent, exhibiting perfect agreement 70% of the time and within one Rockall unit 90% of the time.

For further analysis the endoscopic findings were grouped into low acuity and high acuity lesions. Both EGD and RT-VCE identified low acuity lesions at a statistically similar rate (79% vs. 68% respectively,

$p=0.157$ ). Furthermore, the rate of identification of fresh blood, gastroduodenal ulcers, and AVMs during RT-VCE versus EGD were also similar (21% vs. 32% respectively,  $p=0.157$ ) (Table 3). A comparison of EGD versus O-VCE identified both low acuity and high acuity lesions at statistically similar rates (Table 3). Notably both RT-VCE and O-VCE identified all of the lesions which would normally require invasive therapy, such as gastroduodenal ulcers, fresh blood or AVMs seen during EGD.

**Table 3 Lesions requiring invasive therapy found during real-time capsule endoscopy.**

Finding	EGD	RT-VCE	P-value
<sup>1</sup> Low acuity lesions	79% (15/19)	68% (13/19)	$p=0.157$
<sup>2</sup> High Acuity Lesions	21% (4/19)	32%(6/19)	$p=0.157$
Finding	EGD	O-VCE	P-value
Low acuity lesions	79% (15/19)	74% (14/19)	$p=0.317$
High Acuity Lesions	21% (4/19)	26%(5/19)	$p=0.317$

<sup>1</sup>Low acuity lesions; considered to be lesions which normally would not require emergent endoscopy and/or invasive therapy. These included gastritis, duodentitis, gastrointestinal polyps, red spots, and gastropathy;

<sup>2</sup>High acuity lesions; included fresh blood, ulcer, bleeding AVM and considered to necessitate invasive therapy including endoscopic hemostasis, interventional radiology therapy and surgical intervention.

The 4 point questionnaire on patient tolerability and satisfaction had a 90% completion rate, with one patient unable to complete. Discomfort levels were graded from 0-9 with a score of 9 being most severe. Although pain levels were very low for both procedures (Table 4), slightly more patients reported a higher level of discomfort during RT-VCE (0.8 [ $\pm 1.8$  SD] vs. 0.4 [ $\pm 1.8$  SD] respectively). Strikingly a greater proportion of patients preferred RT-VCE (32% vs. 5% respectively), although the majority (63%) cited no difference in preference. Similarly more patients cited RT-VCE as the preferable procedure for potential repeat investigation (42% vs. 10% respectively).

**Table 4 Patient Tolerability Questionnaire**

Parameter	Value
Avg Discomfort Level EGD (0-9)	0.4 ( $\pm 1.8$ SD)
Avg Discomfort Level RT-VCE (0-9)	0.8 ( $\pm 1.8$ SD)
<b>Preferred Procedure</b>	
EGD	5% (1/19)
RT-VCE	32% (6/19)
No Difference	63% (12/19)
<b>Preferred Repeat Procedure</b>	
EGD	10% (2/19)
RT-VCE	42% (8/19)
No Difference	48% (9/18)

RT-VCE: real time video capsule endoscopy.

## DISCUSSION

Capsule endoscopy remains the preferred modality for mucosal imaging of the entire small intestine, as well as the recommended diagnostic tool of choice in the setting of obscure gastrointestinal bleeding<sup>[14]</sup>. The International Conference for Capsule Endoscopy (ICCE) guidelines for the evaluation of obscure GI hemorrhage in patients with active,

ongoing, mild-to-moderate, overt UGIB recommended capsule endoscopy as a viable and early utilized diagnostic option<sup>[15]</sup>. Furthermore, capsule endoscopy has clearly been demonstrated to have high positive and negative predictive values, while providing the best clinical accuracy for patients in whom ongoing gastrointestinal bleeding is suspected<sup>[8, 16]</sup>.

Clinicians are often faced with the additional challenge of accurately and safely risk stratifying patients based on the presumed severity of the gastrointestinal hemorrhage. To date there remains a small body of literature supporting the feasibility and accuracy of real-time capsule endoscopy in triaging patients who present to the emergency department with a history of UGIB<sup>[17]</sup>. Our study investigates the diagnostic accuracy and utility of RT-VCE in the setting of suspected acute UGIB as compared to standard EGD.

This prospective study revealed very similar results for capsule endoscopy and EGD in the detection of UGIB sources. EGD, when compared to both RT-VCE and O-VCE, did not show any statistically significant difference in its ability to diagnose low acuity lesions and high risk lesions, such as fresh blood, ulcers, and AVMs. Most notably all lesions requiring invasive endoscopic or surgical therapy were identified by both RT-VCE and O-VCE.

The Rockall scores (0-11) obtained during initial presentation to the emergency room for RT-VCE and O-VCE versus gold standard EGD were almost identical. Patient discomfort was self reported as very similar and overall minimal during both EGD and RT-VCE. On the other hand, RT-VCE was overwhelmingly preferred as both a first line test as well as a repeat investigative tool for the diagnosis of gastrointestinal bleeding in the appropriate setting. Other techniques have been investigated to allow for adequate assessment of the upper gastrointestinal tract in the setting of suspected UGIB, while minimizing the risk of sedation related cardiopulmonary complications. The performance of unsedated upper endoscopy using ultrathin videoendoscopes passed both perorally and transnasally, have been studied as alternatives to standard EGD<sup>[18, 19, 20]</sup>. Studies have demonstrated that these techniques preserve diagnostic accuracy, while potentially mitigating the cardiopulmonary complications associated with sedation. Nevertheless, the use of ultrathin videoendoscopes may be problematic as it is associated with gagging, trauma and significant patient discomfort. Given its low level of discomfort, patient preference, and comparable performance to standard EGD, it would appear that RT-VCE may prove to be superior to ultrathin endoscopy for the assessment of the high-risk patient with suspected UGIB. Further studies can be performed to compare both the diagnostic accuracy and patient tolerability of RT-VCE to that of ultrathin endoscopy.

We acknowledge that VCE has some technical limitations. It can not be used to obtain biopsy specimens or for endoscopic treatment, and it can not at this time be controlled remotely. As such, the lack of ability to control the path of the video capsule coupled with its relatively rapid transit time, prevents it from examining all parts of the stomach and duodenum, thereby potentially limiting its diagnostic yield. It is conceivable therefore, that certain anatomical areas of the stomach are visualized more frequently than others. Additional studies would be needed to determine whether this is indeed the case.

Furthermore, although complication rates for VCE are relatively low, capsule retention is a real concern as was observed in one of our patients. While these findings have exciting implications for the future role of VCE in the risk stratification of patients with acute upper gastrointestinal bleeding, our conclusions are limited by the need for further investigation in a larger and statistically powered prospective randomized trial would be necessary before firm conclusions can be

reached.

In our patient population real time capsule endoscopy is the self reported preferable diagnostic test of choice and appears to be a safe and viable option for the initial management of acute GI bleeding in non-critically ill patients. In combination with the Rockall risk assessment score, this technology was prospectively able to accurately identify those patients at risk for potentially adverse outcomes. Real-time endoscopy may improve the timing of necessary treatment, and may help to avoid the unnecessary risk of sedation and endoscopic examination in high risk patients. The impact of real-time capsule examination on mortality and risk of re-bleeding certainly warrants further investigation.

## REFERENCES

- 1 Barkun A, Sabbah S, Enns R, Armstrong D. The Canadian Registry on Nonvariceal Upper Gastrointestinal Bleeding and Endoscopy (RUGBE): Endoscopic hemostasis and proton pump inhibition are associated with improved outcomes in a real-life setting. *Am J Gastroenterol* 2004; **99**(7):1238-1246
- 2 Viviane A, Alan BN. Estimates of costs of hospital stay for variceal and nonvariceal upper gastrointestinal bleeding in the United States. *Value Health* 2008; **11**(1):1-3
- 3 Eisen GM, Baron TH, Dominitz JA, et al. Complications of upper GI endoscopy. *Gastrointest. Endosc* 2002; **55** (7):784-793
- 4 Spiegel BM, Vakil NB, Ofman JJ. Endoscopy for acute nonvariceal upper gastrointestinal tract hemorrhage: is sooner better? A systematic review. *Arch Intern Med* 2001; **161**(11):1393-1404
- 5 Rockall TA, Logan RF, Devlin HB, Northfield TC. Risk assessment after acute upper gastrointestinal haemorrhage. *Gut* 1996; **38**: 316-321
- 6 Camellini L, Merighi A, Pagnini C, et al. Comparison of three different risk scoring systems in non-variceal upper gastrointestinal bleeding. *Dig Liver Dis* 2004; **36**:271-277
- 7 Triester SL, Leighton JA, Leontiadis GI, et al. A meta-analysis of the yield of capsule endoscopy compared to other diagnostic modalities in patients with obscure gastrointestinal bleeding. *Am J Gastroenterol* 2005; **100**:2407-2418
- 8 Pennazio M, Santucci R, Rondonotti E, et al. Outcome of patients with obscure gastrointestinal bleeding after capsule endoscopy: Report of 100 consecutive cases. *Gastroenterology* 2004; **126**: 643-653
- 9 Almeida N, Figueiredo P, Lopes S, et al. Urgent Capsule Endoscopy is Useful in Severe Obscure-Overt Gastrointestinal Bleeding. *Digestive Endoscopy* 2009; **21**(2): 87-92
- 10 Apostolopoulos P, Liatsos C, Granlek IM, et al. Evaluation of capsule endoscopy in active, mild-to-moderate, overt, obscure GI bleeding. *Gastrointest. Endosc* 2007; **66**: 1174-1181
- 11 Rubin M, Hussain S, Shalomov A, Cortes R, Smith M, Kim S. Risk Stratification of Upper GI Bleeding Patients in the Emergency Room with LiveView Video Capsule Endoscopy - A Pilot study. *Dig Dis Sci* 2010 Jul 15
- 12 Ginsberg G, Barkun A, Bosco J, et al. ASGE Technology Status Evaluation Report: wireless capsule endoscopy. *Gastrointest. Endosc* 2002; **56**: 621-624
- 13 Spearman, Ch (1904) Proof and measurement of association between two things, *American Journal of Psychology* 15, 72-101
- 14 Mishkin DS, Chuttani R, Croffi e J, et al. ASGE Technology Status Evaluation Report: wireless capsule endoscopy. *Gastrointest Endosc* 2006; **63**: 539-545
- 15 Pennazio M, Eisen G, Goldfarb N. ICCE consensus for obscure gastrointestinal bleeding. *Endoscopy* 2005; **37**(10):1046-1450
- 16 Carey EJ, Leighton JA, Heigh RI, et al. A single-center experience of 260 consecutive patients undergoing capsule endoscopy for obscure gastrointestinal bleeding. *Am J Gastroenterol* 2007; **102**:89-95

**Peer reviewers:** Dr. Seng-Kee Chuah, Division of Hepatogastroenterology, Kaohsiung Chang Gung Memorial Hospital, 123, Ta-Pei Road, Niao-sung Hsiang, Kaohsiung County, 833 Taiwan; Denise Kalmaz, MD, Assistant Clinical Professor, Department of Gastroenterology, University of California, San Diego, 9500 Gilman Drive (ECOB/ 2nd Fl/ 2-062H), 0956 La Jolla, CA 92093-0063, USA.