

A Case of Bleeding Gastric Lesion: A Diagnosis to Keep in Mind

Daniela Marra, Grazia Travaglini, Aroldo Fianchini, Cristina Marmorale

Daniela Marra, Grazia Travaglini, Aroldo Fianchini, Cristina Marmorale, Department of Surgical and Medical Science, Polytechnic University of Marche, Ancona, Italy

Correspondence to: Daniela Marra, Department of Surgical and Medical Science, Polytechnic University of Marche, Ancona, Italy. daniela_ma@live.it

Received: September 23, 2012 Revised: November 6, 2012

Accepted: November 10, 2012

Published online: February 21, 2013

ABSTRACT

The gastric Anisakidosis is a rare parasitic disease caused by the ingestion of larvae of marine nematodes in raw or undercooked fish. The most common symptoms include nausea, diarrhea, abdominal pain and allergic reactions such as urticaria or anaphylaxis. Rare cases of chronic form may manifest as Anisakidosis gastric submucosal eosinophilic granuloma. These paintings raise considerable problems of differential diagnosis with other diseases such as gastric peptic ulcer, gastric cancer, GIST, and gastric lymphoma. We report a case of acute bleeding of the upper gastrointestinal tract with severe anemia and radiographic findings highly suspicious for GIST of the gastric fundus, which had been treated with emergency gastric resection. The lesion was histologically proven to be an eosinophilic granuloma containing fragments of helminths. The definitive diagnosis was supported by the finding of high levels of anti-Anisakis Antibodies (>100 kUA/L) and subsequently confirmed by history positive for ingestion of raw fish. In view of the increased habit to eat raw fish due to the spread of Eastern cultures in our country, the Anisakidosis should always taken into consideration in the differential diagnosis of gastric lesions especially in cases of reported ingestion of undercooked or raw fish before the onset of symptoms.

© 2013 ACT. All rights reserved.

Key words: Gastrointestinal bleeding; Anisakiasis; GIST

Marra D, Travaglini G, Fianchini A, Marmorale C. A Case of Bleeding Gastric Lesion: A Diagnosis to Keep in Mind. *Journal of Gastroenterology and Hepatology Research* 2013; 2(2): 423-425 Available from: URL: <http://www.ghrnet.org/index./joghr/>

INTRODUCTION

The gastric Anisakiasis is a rare parasitic disease of the human gastrointestinal tract caused by the ingestion of marine nematode larvae present in raw or undercooked fish. The stomach can become involved. Symptoms include nausea, diarrhea, severe abdominal pain, allergic response such as urticaria or anaphylaxis. In rare cases of chronic gastric Anisakiasis, other manifestations may be ileus perforation or peritonitis and intestinal bleeding. In such cases, problems of differential diagnosis with other gastric diseases like peptic ulcer, gastric tumor, GIST and gastric lymphoma may occur.

We report a rare case of bleeding gastric lesion with radiological features similar to a GIST, but subsequently identified as parasitic illness at the histological exam.

CASE REPORT

A 36-year-old white man was admitted in a nearby hospital for melena and the laboratory tests highlighted anaemia. After some transfusions, a gastroscopy was performed. A 6-mm bleeding ulcerated lesion was found in the gastric fundus which was treated with local adrenalin injection. After two days of stable clinic conditions, melena reappeared and the patient was transferred to our hospital. At admission he was symptomless: his abdomen was not distended and he did not report any pain. The laboratory tests showed anaemia (Hb 7.6 gr/dL) and eosinophilia (910/mm³, v.n. 10-500). After some blood transfusions, he was submitted to another gastroscopy which showed a lesion in the gastric fundus apparently similar to an ulcerated submucosal tumour.

On the basis of that finding, an endoscopic ultrasonography was performed, which showed a heterogenic ipoecogenic lesion measuring 34×15 mm, derived from the fourth layer (muscular layer), placed in the gastric fundus.

The abdominal magnetic resonance imaging (RMI) confirmed the ipoecogenic-disomogenic area measuring 348×15 mm. These features were compatible with a GIST.

After a further episode of bleeding associated to fainting, the patient was moved to our department and underwent surgery. The exploration of the stomach enabled us to identify a lesion measuring 1.5 cm placed in the gastric fundus, which did not involve the full thickness. We therefore performed a gastric wedge resection.

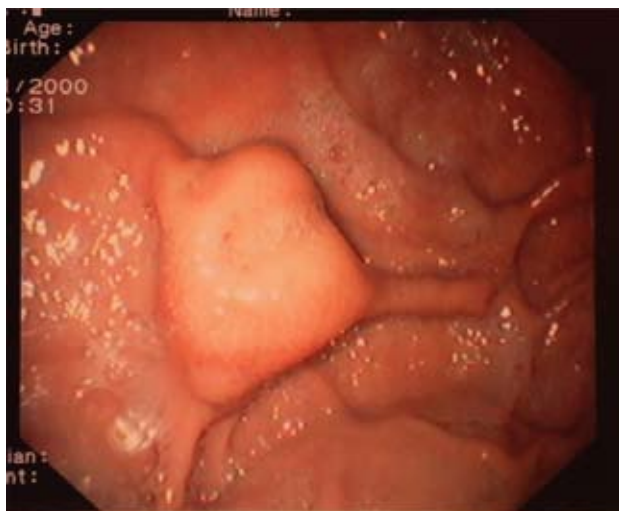


Figure 1 A 6 mm bleeding ulcerated lesion in the gastric fundus which appeared to be similar to an ulcerated submucosal tumour.

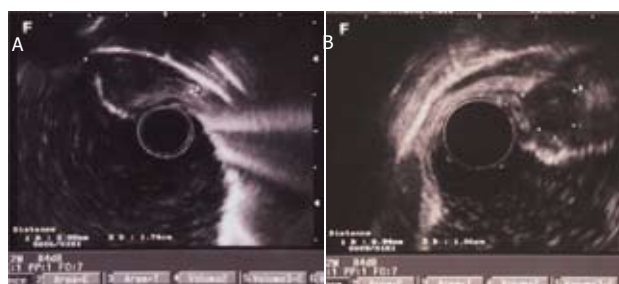


Figure 2 The heterogenic ipoecogenic lesion measuring 34×15 mm, derived by the fourth layer (muscular layer), placed in the gastric fundus.

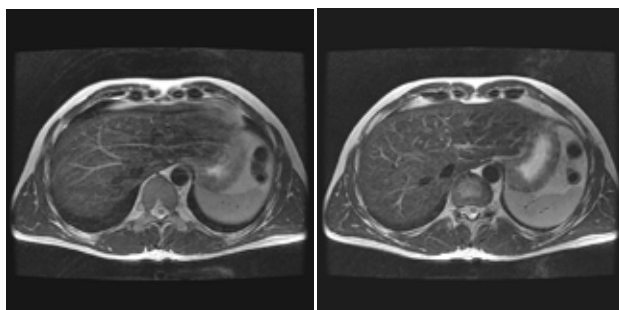


Figure 3 Confirmation of an ipoecogenic-disomogenic area measuring 34×15 mm, features compatible with a GIST.

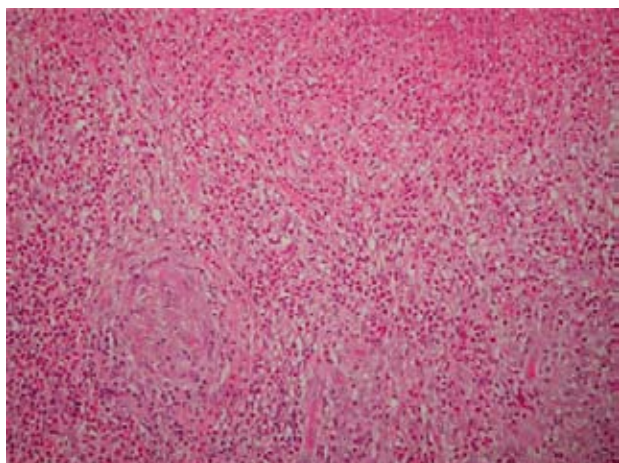


Figure 4 Wall infiltrated by chronic granulomatous inflammation and eosinophilic exuberant agranulocytosis.

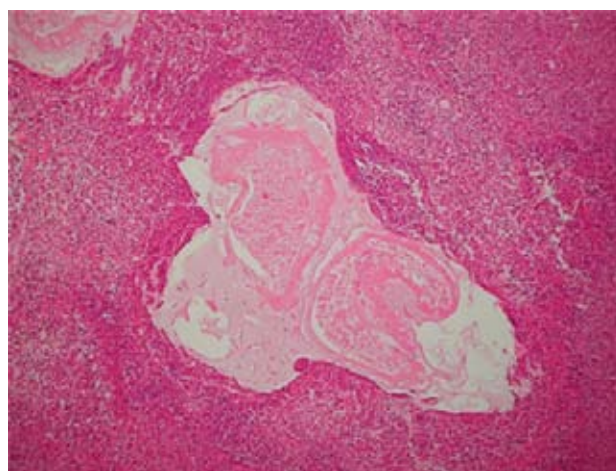


Figure 5 Within the abscess a pseudocyst containing fragments of the parasitic structure was identified.

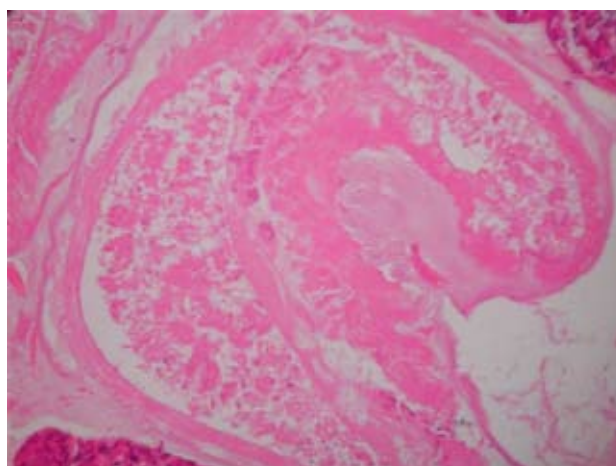


Figure 6 In detail, a fragment of the parasite with structural features related to the parasite Anisakis type.

The histological examination showed active chronic inflammation located in the muscular layer of the gastric wall, with extensive and confluent areas of abscess. The granulocytes were in prevalence eosinophil. Fragments of parasites could be identified within the abscess. The set of findings was consistent with the diagnosis of helminth granuloma, probably Anisakis type.

The diagnosis was confirmed by the high values of IgE anti-Anisakis (>100 KUA/L, nv<0.1) detected through ImmunoCAP.

DISCUSSION

As the gastric Anisakiasis is due to the ingestion of raw fish, it is relatively common in Japan. However, it has recently increasingly appeared in Western Countries because of the growing popularity of Eastern food habits^[1].

The most common symptoms are severe epigastric pain, nausea and diarrhea, which may occur one hour after the ingestion of the parasite. If the infection is not treated, the pain continues for several days until the larvae die within the mucosa. In acute, larvae can be seen in some areas of the mucosal surface during endoscopy. Other endoscopic signs are edema, erosion and a transient edematous swelling of the mucosa defined “vanishing tumor”^[2]. In such a case, the best therapy is the endoscopic removal of the larvae. In rare cases of chronic gastric Anisakiasis, a submucosal eosinophilic granuloma may appear. Its pathogenesis is considered as a form of allergic reaction. After the

larva dies within the mucosa, it activates the eosinophil infiltration and a proliferation of connective tissue around the body of the larva resulting in the formation of a granuloma. As it happened in our case, this lesion appears like a submucosal tumor, but it usually decreases in size and gradually disappears. However, in our case, instead of disappearing, the granuloma had infiltrated the mucosa until it ulcerated and bled. Literature reports that the morphology of the lesion may resemble a type II advanced gastric cancer or an early type IIa or type III gastric cancer, or an inflammatory fibrous polyp^[3-4]. The EUS features, such as the hypoechoic, well-defined margins and the origin from the fourth layer, matched the characteristics of gastric GIST. For this reason, instead of performing the CT examination, which is considered optimal for the detection of lesions from Anisakis, we decided to perform a MRI^[5]. Considering the clinical-instrumental suspicion and the general conditions of the patient, we decided to operate on him. The final diagnosis was obtained through the histological analysis of the surgical specimen which revealed a gastric wall completely damaged by the inflammatory reaction induced by Anisakis, which is irreversible in such cases^[6].

A positive result in a serological test can be helpful in diagnosing. However, in patients without symptoms, positive values of IgE anti-Anisakis can't be considered a reliable indicator of disease. This antibody has been detected in 25% of healthy controls and lacks specificity as a result of its cross-reactivity with other parasite antigens. It isn't generally available and therefore of limited benefit in early diagnosis.

Increased eosinophil levels have been observed in less than half of the patients with Anisakiasis. Therefore the eosinophil count is not likely to be a useful tool in the early diagnosing of the enteric Anisakiasis^[7-8].

The differential diagnosis of gastric lesions by Anisakis is difficult; the disease often remains undiagnosed and it is consequently underestimated as a cause of gastrointestinal symptoms. Therefore, considering the increasing diffusion of the parasite in Western Europe, the Anisakiasis should be kept in mind as a differential

diagnosis of bleeding gastric lesions in patients with positive anamnesis for ingestion of raw food.

REFERENCES

- 1 Arizono N, Yamada M, Tegoshi T, Yoshikawa M. Anisakis simplex sensu stricto and Anisakis pegreffii: biological characteristics and pathogenetic potential in human anisakiasis. *Foodborne Pathog Dis* 2012; **9**: 517-521
- 2 Nakanishi Y, Yazumi S, Ikeuchi D, Matsumoto A, Yamamura H, Yoshizaki S, Mise S, Fukuyama N, Shimamoto C, Katsu K. Vanishing gastric tumor caused by anisakiasis. *Gastrointest Endosc* 2005; **61**: 102
- 3 Kang DB, Oh JT, Park WC, Lee JK. Small bowel obstruction caused by acute invasive enteric anisakiasis. *Korean J Gastroenterol* 2010; **56**: 192-195
- 4 Lee EJ, Kim YC, Jeong HG, Lee OJ. The mucosal changes and influencing factors in upper gastrointestinal anisakiasis: analysis of 141 cases. *Korean J Gastroenterol* 2009; **53**: 90-97
- 5 Nakajo M, Setoguchi Y, Onohara S, Nakajo M. Computed tomographic features of two cases of acute gastric anisakiasis. *Abdom Imaging* 2011; **36**: 509-513
- 6 Ito Y, Ikematsu Y, Yuzawa H, Nishiwaki Y, Kida H, Waki S, Uchimura M, Ozawa T, Iwaoka T, Kanematsu T. Chronic gastric anisakiasis presenting as pneumoperitoneum. *Asian J Surg* 2007; **30**: 67-71
- 7 Caramello P, Vitali A, Canta F, Caldana A, Santi F, Caputo A, Lipani F, Balbiano R. Intestinal localization of anisakiasis manifested as acute abdomen. *Clin Microbiol Infect* 2003; **9**: 734-737
- 8 Perteguer MJ, Chivato T, Montoro A, Cuéllar C, Mateos JM, Laguna R. Specific and total IgE in patients with recurrent, acute urticaria caused by Anisakis simplex. *Ann Trop Med Parasitol* 2000; **94**: 259-268

Peer reviewer: Denise Kalmaz, MD, Assistant Clinical Professor, Department of Gastroenterology, University of California, San Diego, 9500 Gilman Drive (ECOB/ 2nd Fl/ 2-062H), Mail Code 0956, La Jolla, CA 92093-0063, the United States.