

Journal of Gastroenterology and Hepatology Research

Online Submissions: <http://www.ghrnet.org/index./joghr/>
doi: 10.17554/j.issn.2224-3992.2021.10.1001

Journal of GHR 2021 April 21; **10(2)**: 3488-3491
ISSN 2224-3992 (print) ISSN 2224-6509 (online)

CASE REPORT

Actinomyces of an Appendix with a Cecal Abscess

Hiromi Ono¹, MD; Hitoshi Yokoyama², MD, PhD; Haruyuki Yoshida², MD; Hiraku Fukushima², MD, PhD; Masato Kawakami², MD; Mikio Okamura³, MD; Takanori Aoki³, MD; Naoki Asakage³, MD; Yasushi Danjo⁴, MD, PhD; Kimimoto Nagashima⁵, MD; Hideyuki Hayashi⁶, MD, PhD; Hiroshi Nishihara⁶, MD, PhD; Yuichi Shimizu⁷, MD, PhD; Tsuyoshi Shimamura⁸, MD, PhD; Mitsuo Kusano⁹, MD, PhD

1 Department of Internal Medicine, Veritas Hospital, 2-23, 1-Chome, Shinden, Kawanishi, Hyogo 666-0125, Japan;

2 Department of Internal Medicine, Seiwa Memorial Hospital, 1-1, 1-Jo, 5-Chome, Kotoni, Nishi-ku, Sapporo, Hokkaido 063-0811, Japan;

3 Department of Surgery, Seiwa Memorial Hospital, 1-1, 1-Jo, 5-Chome, Kotoni, Nishi-ku, Sapporo, Hokkaido 063-0811, Japan;

4 Department of Surgery, Heiwa Hospital, 2-1, 2-Jo, 11-Chome, Heiwa, Nishi-ku, Sapporo, Hokkaido 063-0022, Japan;

5 Department of Anesthesiology, Shin-Sapporo Orthopedic Hospital, 2-32, 2-Chome, Atsubetsuminami, Atsubetsu-ku, Sapporo, Hokkaido 004-0022, Japan;

6 Genomics Unit, Keio Cancer Center, Keio University School of Medicine, 35 Shinanomachi, Shinjuku-ku, Tokyo 160-8582, Japan;

7 Division of Endoscopy, Hokkaido University Hospital, Kita 14, Nishi 5, Kita-ku, Sapporo, Hokkaido 060-8648, Japan;

8 Division of Organ Transplantation, Central Clinical Facilities, Hokkaido University Hospital, Kita 14, Nishi 5, Kita-ku, Sapporo, Hokkaido 060-8648, Japan;

9 Division of Internal Medicine, Hokkaido Social Welfare Corporation Yoichi Hospital, 19-1-1, Kurokawa-cho, Yoichi, Hokkaido 046-0003, Japan.

Conflict-of-interest statement: The authors declare that there is no conflict of interest regarding the publication of this paper.

Open-Access: This article is an open-access article which was selected by an in-house editor and fully peer-reviewed by external reviewers. It is distributed in accordance with the Creative Commons Attribution Non Commercial (CC BY-NC 4.0) license, which permits others to distribute, remix, adapt, build upon this work non-commercially, and license their derivative works on different terms, provided the original work is properly cited and the use is non-commercial. See: <http://creativecommons.org/licenses/by-nc/4.0/>

Correspondence to: Hiromi Ono, Department of Internal Medicine, Veritas Hospital, 2-23, 1-Chome, Shinden, Kawanishi, Hyogo 666-0125, Japan.

Email: kupz85728@zeus.eonet.ne.jp

Telephone: +81-72-793-7890

Received: February 27, 2021

Revised: March 15, 2021

Accepted: March 18, 2021

Published online: April 21, 2021

ABSTRACT

Appendicitis has an etiology of appendiceal actinomyces and chronic inflammation in only 0.01-0.06% of the cases, and less than 10% of these cases are diagnosed before surgery. Here we report the case of a 27-year-old Chinese female who was referred to our hospital with right lower abdominal pain and a high fever. Abdominal computed tomography (CT) scan revealed an abscess around the cecum. Appendectomy was performed on the same day, and a tumor-like edematous appendix was observed. Appendiceal actinomyces was diagnosed pathologically. A combination of antibiotic therapy and operative treatment resolves actinomyces in 90% of cases.

Key words: Actinomyces; Appendiceal actinomyces; Cecal abscess; Perforated appendicitis

© 2021 The Authors. Published by ACT Publishing Group Ltd. All rights reserved.

Ono H, Yokoyama H, Yoshida H, Fukushima H, Kawakami M, Okamura M, Aoki T, Asakage N, Danjo Y, Nagashima K, Hayashi H, Nishihara H, Shimizu Y, Shimamura T, Kusano M. Non-Invasive Predictors of Moderate-Large Esophageal Varices in Compensated Cirrhotic Patients. *Journal of Gastroenterology and Hepatology Research* 2021; **10(2)**: 3488-3491 Available from: URL: <http://www.ghrnet.org/index.php/joghr/article/view/3110>

INTRODUCTION

Acute appendicitis is the most common indication for emergency abdominal surgery, and has a lifetime incidence of around 10%^[1,2]. The etiology of acute appendicitis is secondary to appendiceal obstruction, and the most common causes of this obstruction are lymphoid hyperplasia, and fecal stasis with fecaliths^[3,4]. Other rare causes have also been described, including carcinoid tumor, pinworm, eosinophilic appendicitis, granulomas, and actinomyces, among others^[3,5,6].

Actinomycosis species are gram-positive anaerobic bacteria, which are normal commensals of the oral cavity, gastrointestinal, and urogenital tract, but become pathogenic in the presence of necrotic tissue^[7-9]. Actinomycetes are responsible for appendicitis in only 0.01-0.06% of cases^[3,5,6], less than 10% of which are diagnosed before surgery^[8-10].

Several studies have attempted to diagnose this condition by the presence of specific radiologic or endoscopic features^[8,9,11,12]. However, these radiologic, endoscopic, and clinical features are not diagnostic, and the final diagnosis of actinomycosis usually requires pathologic confirmation after surgery^[13]. Unfortunately, pathologic diagnosis is often difficult, even in resected specimens, because this disease can mimic Crohn's disease or inflammatory pseudotumors and the causative organisms can be very difficult to determine. Here, we report a case of appendiceal actinomycosis that was diagnosed after surgery.

CASE REPORT

A 27-year-old Chinese female was referred to the Seiwa Memorial Hospital on April 2014 with right lower abdominal pain and high fever. She had a body mass index (BMI) of 18.4 kg/m². Physical examination revealed right lower abdominal tenderness on palpation. Her body temperature was 36.9°C, with a white blood cell count of 7,400/μL, and a c-reactive protein level of 2.87 mg/dL. Abdominal ultrasound showed dilatation of the appendix, which led to the diagnosis of appendicitis in the previous hospital. Abdominal computed tomography (CT) scan revealed an abscess around the cecum that measured 50×30 mm² in size, but the appendix was unknown (Figure 1). The clinical diagnosis was an acute perforated appendicitis with an abscess around the cecum pre-surgery. On the same day, laparoscopic surgery was performed to relieve pain after obtaining informed consent. Since an abscess was noticed around the cecum and the appendix could not be removed owing to adhesion, the original laparotomy was switched to an appendectomy. We then performed an appendectomy, washed the abdominal cavity of the abscess around the cecum, and drained. Macroscopically, we observed a tumor-like edematous appendix measuring approximately 63×23 mm² in size (Figure 2). Acute gangrenous appendicitis due to actinomycosis was diagnosed pathologically (Figure 3). The patient had a high fever of 40.0°C 1 day after appendectomy, and one more antibiotic was used. The fever reduced gradually and her condition improved such that she was discharged 13 days after appendectomy (Figure 4).

DISCUSSION

Actinomycosis is distributed worldwide and is found with equal frequency in urban and rural dwellers. In humans, *Actinomyces israelii* is the most common cause of the disease; these organisms are indigenous to the oral cavity, gastrointestinal tract, and genital tract.

Actinomyces israelii is an opportunistic pathogen, and infection can occur when the mucosal barrier is broken, which leads to multiple abscess formation, fistula, or mass lesions^[14,15].

Appendiceal actinomycosis is very rare. Alemayehu *et al.* studied 3,602 appendicular cases and found that only one had actinomycosis (0.02%)^[3]. Akbulut *et al.* found that eight patients in their series of 80,698 cases had actinomycosis (0.01%)^[5]. Furthermore, Limaïem *et al.* reported that in a retrospective study of 1,627 appendectomy specimens only one sample had actinomycosis (0.06%)^[6]. The overall incidence of actinomycosis is virtually unknown; however, the estimated population prevalence is one case per 119,000^[8].

Actinomycosis commonly occurs in three distinct forms that may

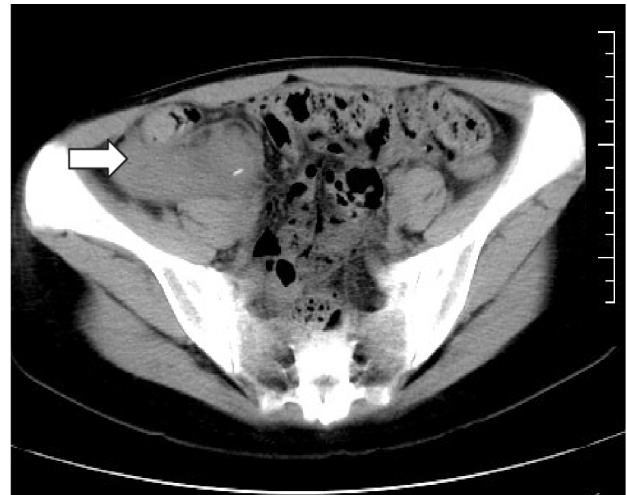

Figure 1 Abdominal computed tomography (CT) scan showing an abscess around the cecum (white arrow), which measured 50×30 mm² in size, but the appendix could not be detected.

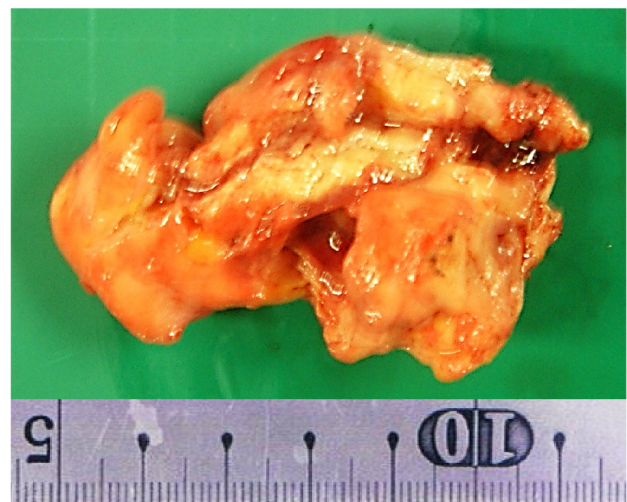


Figure 2 Macroscopically, we observed a tumor-like edematous appendix measuring approximately 63×23 mm² in size.

occasionally overlap, with cervicofacial presentation in 50%, abdominopelvic in 20%, and the intrathoracic form in 15% of the cases^[7-9]. Abdominal actinomycosis involves the appendix and cecum in 66% of cases^[16,17], of these, perforated appendicitis is the stimulus in 75% of cases^[17].

The clinical presentation has an indolent course, with an initial nonspecific presentation, usually with lower abdominal pain and fever, with less than 10% of the cases diagnosed before surgery^[8-10]. Radiologic techniques are not helpful in the diagnosis of abdominal actinomycosis: the abdominal CT scan may show an infiltrative mass adjacent to the other involved organs, like the bowel wall thickening is the main sign of gastrointestinal disease^[11]. The final diagnosis of actinomycosis requires microscopic proof of either the pathogen itself, the presence of specific sulfur granules, or culture of actinomycetes obtained by needle aspiration or from a surgical specimen^[9,18].

The choice of treatment of abdominal actinomycosis depends on whether the diagnosis is made pre- or postoperatively. The recommended nonsurgical treatment for abdominal actinomycosis is intravenous penicillin G for 2-6 weeks followed by oral penicillin or amoxicillin for 6-12 months^[19]. For those allergic to penicillin, alternatives include tetracycline, erythromycin, or clindamycin^[20]. Surgery is reserved for patients who do not respond to initial antibiotic therapy or for those with severe disease, as noted by fistulas,

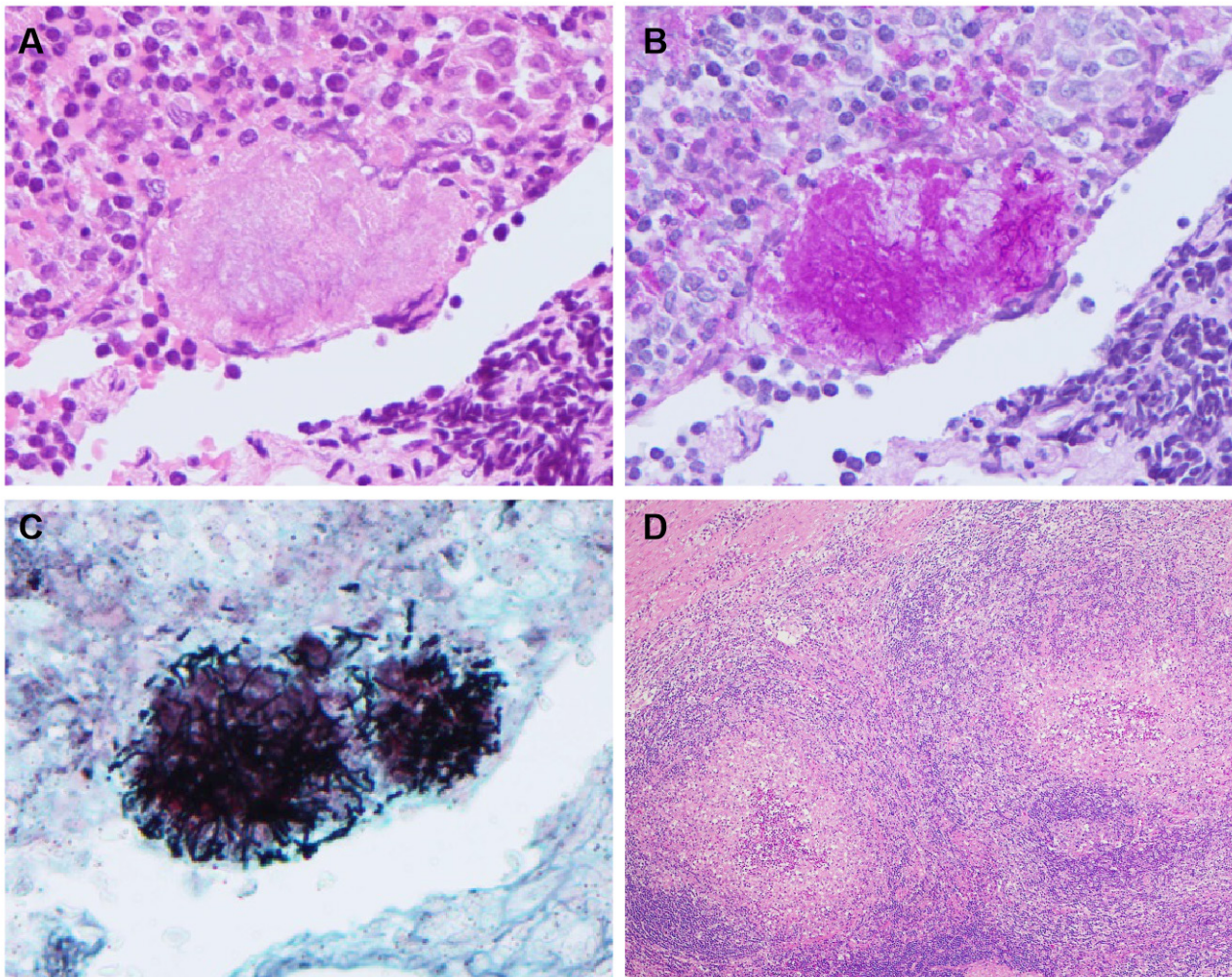


Figure 3 The postoperative histopathologic diagnosis was appendiceal actinomycosis. An actinomycotic colony surrounded by inflammatory infiltrates, hematoxylin and eosin (H&E) stained sections (A) ($\times 200$), and periodic acid-schiff (PAS) stained sections (B) ($\times 200$). Filamentous bacilli are shown by grocott staining (C) ($\times 200$). The fibroinflammatory foci shows marked lymphoplasmacytic infiltration with fibrosis that is reminiscent of pseudotumor (D) ($\times 40$).

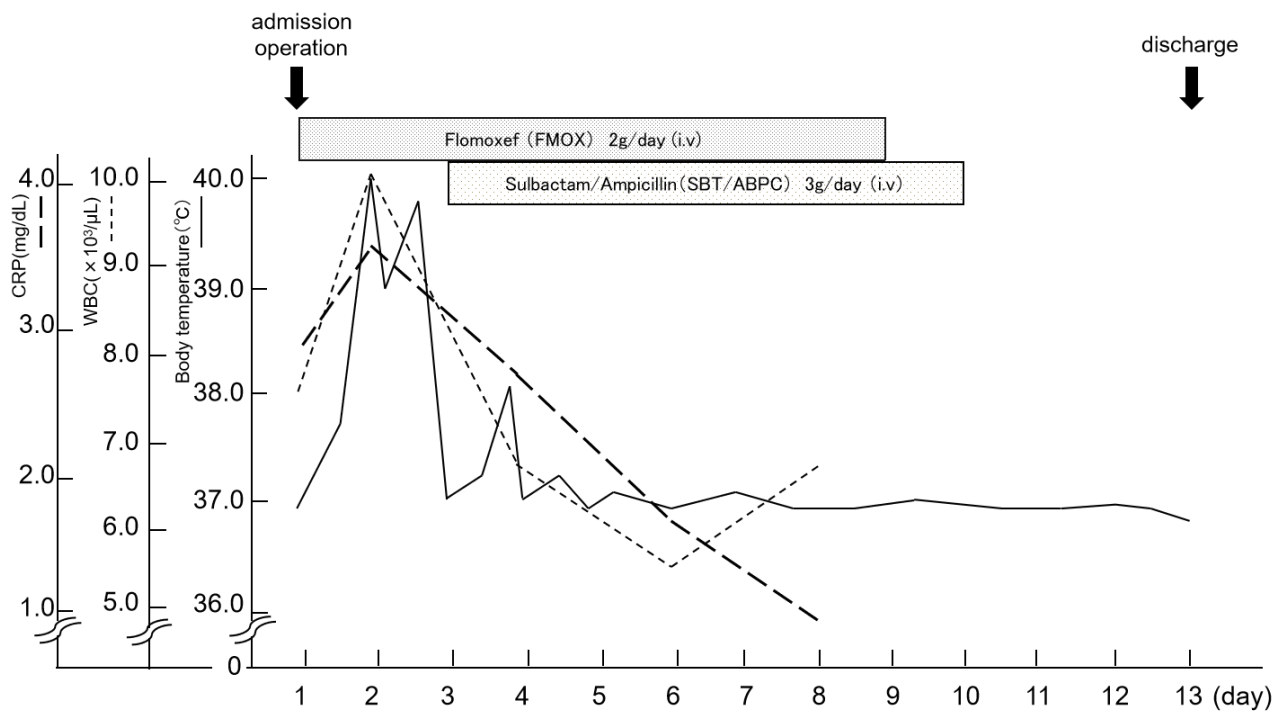


Figure 4 Figure of the patient's clinical course. The white blood cell count, c-reactive protein level, and body temperature are shown. The patient had a high fever of 40.0°C 1 day after appendectomy. One more antibiotic was used, and she was discharged 13 days after appendectomy.

necrosis, or abscesses. Surgery is also indicated if malignancy cannot be ruled out. Postsurgical treatment includes long-term penicillin therapy. Mortality is extremely rare, and favorable outcomes are seen in 90% of cases treated with combined medical and surgical therapy^[16].

CONCLUSION

Appendiceal actinomycosis is rare and a pathological report after surgery is required for definitive diagnosis. Appendiceal actinomycosis should be considered in patients with an indolent course and non-specific abdominal symptoms. Treatment with prolonged antibiotic therapy either alone or in combination with surgery is effective.

REFERENCES

- Sotelo-Anaya E, Sánchez-Muñoz MP, Ploneda-Valencia CF, de la Cerda-Trujillo LF, Varela-Muñoz O, Gutiérrez-Chávez C, CarlosLópez-Lizarraga CR. Acute appendicitis in an overweight and obese Mexican population: A retrospective cohort study. *Int J Surg.* 2016; **32**: 6-9. [PMID: 27321379]; [DOI: 10.1016/j.ijsu.2016.06.004]
- Alvarez-Alvarez FA, Maciel-Gutierrez VM, Rocha-Muñoz AD, Lujan JH, Ploneda-Valencia CF. Diagnostic value of serum fibrinogen as a predictive factor for complicated appendicitis. A cross-sectional study. *Int J Surg.* 2016; **25**: 109-113. [PMID: 26644291]; [DOI: 10.1016/j.ijsu.2015.11.046]
- Alemayehu H, Snyder CL, St. Peter SD, Ostlie DJ. Incidence and outcomes of unexpected pathology findings after appendectomy. *J Pediatr Surg.* 2014; **49**(9): 1390-1393. [PMID: 25148744]; [DOI: 10.1016/j.jpedsurg.2014.01.005]
- Kuri Osorio JA, De Luna Díaz R, Marín D, Espinosa Aguilar L, Martínez Berlanga P. Chronic appendicitis of 3 years progression secondary to actinomycosis infection. *Cir Esp.* 2012; **90**(2): 131-134. [PMID: 21414609]; [DOI: 10.1016/j.ciresp.2010.09.018]
- Akbulut S, Tas M, Sogutcu N, Arikanoğlu Z, Basbug M, Ulku A, Semur H, Yagmur Y. Unusual histopathological findings in appendectomy specimens: a retrospective analysis and literature review. *World J Gastroenterol.* 2011; **17**(15): 1961-1970. [PMID: 21528073]; [DOI: 10.3748/wjg.v17.i15.1961]
- Limaïem F, Arfa N, Marsaoul L, Bouraoui S, Lahmar A, Mzabi S. Unexpected histopathological findings in appendectomy specimens: a retrospective study of 1627 cases. *Indian J Surg.* 2015; **77**(Suppl 3): 1285-1290. [PMID: 27011552]; [DOI: 10.1007/s12262-015-1278-8]
- Conrad RJ, Riela S, Patel R, Misra S. Abdominal actinomycosis mimicking acute appendicitis. *BMJ Case Rep.* 2015; **26**: 1-3. [PMID: 26611488]; [DOI: 10.1136/bcr-2015-212888]
- Garner JP, Macdonald M, Kumar PK. Abdominal actinomycosis. *Int J Surg.* 2007; **5**(6): 441-448. [PMID: 18078685]; [DOI: 10.1016/j.ijsu.2006.06.009]
- Liu K, Joseph D, Lai K, Kench J, Ngu MC. Abdominal actinomycosis presenting as appendicitis: two case reports and review. *J Surg Case Rep.* 2016; **3**(5): 1-3. [PMID: 27147718]; [DOI: 10.1093/jscr/rjw068]
- Choi MM, Baek JH, Lee JN, Park S, Lee WS. Clinical features of abdominopelvic actinomycosis: report of twenty cases and literature review. *Yonsei Med J.* 2009; **50**(4): 555-559. [PMID: 19718405]; [DOI: 10.3349/ymj.2009.50.4.555]
- Lee SY, Kwon HJ, Cho JH, Oh JY, Nam KJ, Lee JH, Yoon SK, Kang MJ, Jeong JS. Actinomycosis of the appendix mimicking appendiceal tumor: a case report. *World J Gastroenterol.* 2010; **16**(3): 395-397. [PMID: 20082489]; [DOI: 10.3748/wjg.v16.i3.395]
- Lee IJ, Ha HK, Park CM, Kim JH, Kim TK, Kim JC, Cho KS, Auh YH. Abdominopelvic actinomycosis involving the gastrointestinal tract: CT features. *Radiology.* 2001; **220**(1): 76-80. [PMID: 11425976]; [DOI: 10.1148/radiology.220.1.r01j11376]
- Gomez-Torres GA, Ortega-García OS, Gutierrez-López EG, Carballido-Murguía CA, Flores-Ríos JA, López-Lizarraga CR, Bautista López CA, Ploneda-Valencia CF. A rare case of subacute appendicitis, actinomycosis as the final pathology reports: A case report and literature review. *Int J Surg Case Rep.* 2017; **36**: 46-49. [PMID: 28531869]; [DOI: 10.1016/j.ijscr.2017.04.033]
- Berardi RS. Abdominal actinomycosis. *Surg Gynecol Obstet.* 1979; **149**(2): 257-266. [PMID: 380028]
- Brown JR. Human actinomycosis. A study of 181 subjects. *Hum Pathol.* 1973; **4**(3): 319-330. [PMID: 4756858]; [DOI: 10.1016/s0046-8177(73)80097-8]
- Liu V, Val S, Kang K, Velcek F. Case report: actinomycosis of the appendix—an unusual cause of acute appendicitis in children. *J Pediatr Surg.* 2010; **45**(10): 2050-2052. [PMID: 20920728]; [DOI: 10.1016/j.jpedsurg.2010.06.015]
- Deshmukh N, Heaney SJ. Actinomycosis at multiple colonic sites. *Am J Gastroenterol.* 1986; **81**(12): 1212-1214. [PMID: 3788934]
- Yiğiter M, Kiyici H, Arda IS, Hiçsönmez A. Actinomycosis: a differential diagnosis for appendicitis. A case report and review of the literature. *J Pediatr Surg.* 2007; **42**(6): e23-26. [PMID: 17560191]; [DOI: 10.1016/j.jpedsurg.2007.03.057]
- Russo TA. Agents of actinomycosis: principles and practice of infectious diseases. Eds, Mandell L, Bennett JE, Dolin R. 7th ed. London: Elsevier Churchill Livingstone, 2010: 3209-3219.
- Smith AJ, Hall V, Thakker B, Gemmell CG. Antimicrobial susceptibility testing of actinomyces species with 12 antimicrobial agents. *J Antimicrob Chemoth.* 2005; **56**(2): 407-409. [PMID: 15972310]; [DOI: 10.1093/jac/dki206]