

Surgical Treatment of Pancreatic Pseudocysts

Nefis Abdelnacer, Kouira Mouna, Ben Mabrouk Mohamed, Bel Hadj Hmida Mehdi, Mazhoud Jaafar, Derbel Fethi, Ben Ali Ali, Ajmi Salem, Arifa Nadia, Kadri Khaled, Moulahi Hassan, Najja Walid, Bel Hadj Hmida Ridha

Nefis Abdelnacer, Kouira Mouna, Ben Mabrouk Mohamed, Bel Hadj Hmida Mehdi, Mazhoud Jaafar, Derbel Fethi, Ben Ali Ali, Ajmi Salem, Arifa Nadia, Kadri Khaled, Moulahi Hassan, Najja Walid, Bel Hadj Hmida Ridha, Digestive and visceral surgery department at Sahloul university hospital Sousse, Tunisia

Correspondence to: Fethi Derbel, Digestive and visceral surgery department at Sahloul university hospital Sousse, Tunisia. fethi.derbel@gmail.com

Received: July 30, 2012 Revised: September 30, 2012

Accepted: October 2, 2012

Published online: February 21, 2013

Journal of Gastroenterology and Hepatology Research 2013; 2(2): 426-428 Available from: URL: <http://www.ghrnet.org/index./joghr/>

INTRODUCTION

The pseudocyst of the pancreas (PKP) is an intra or a peripancreatic collection whose capsule has no epithelial lining, and occurring after acute or chronic pancreatitis or is subsequent to a trauma of the pancreas^[1].

The PKP is a complication to up to 10 to 30% of all cases of pancreatitis^[2]. In case of acute necrotizing pancreatitis, about 85% of PKP resolve spontaneously within six weeks after the acute episode and specific treatment is seldom necessary^[3,4]. Beyond this period, the PKP whose size is over 6 cm are unlikely to regress and often cause pain or digestive discomfort by compression, or complications such as bleeding and infection^[1,5]. In chronic pancreatitis, it is assumed that the origin of PKP is ductal obstruction due to lithiasis or stenosis, causing distension and rupture of a pancreatic canaliculus^[1,6]. Internal drainage is the treatment of choice for symptomatic and uncomplicated PKP. Despite the emergence of new techniques for endoscopic or percutaneous drainage, which are often preferred, conventional surgery is still as important. The purpose of this study is to evaluate the clinical results of surgical treatment of PKP and clarify the benefits of this treatment method.

METHODS

Patients

This is a retrospective study that examined a series of seven patients with symptomatic PKP that were treated in digestive and visceral surgery department at Sahloul university hospital of Sousse between January 2009 and December 2011. There were five women and two men with a median age of 49 years (range 27-78). Half the patients had a history of hypertension, diabetes mellitus and dyslipidemia. Six patients had a history of gallstone acute pancreatitis, a case of acute pancreatitis on chronic pancreatitis was noted. The mean time to diagnosis of pseudocyst was 5 months (range 2-12). Topography was: caudal (4 cases), corporeo caudal (3 cases). The average size was 8 cm (range 6-13) (Figure 1). All cysts were symptomatic with abdominal pain without signs of gastrointestinal compression (Table 1).

Surgical Technique

The surgical approach was a median supraumbilical in all cases.

ABSTRACT

To evaluate the clinical results of surgical treatment of pancreatic pseudocysts and specify the benefits of this treatment method. This is a retrospective study which collected seven cases of patients treated for pancreatic pseudocysts in Sahloul university hospital in Sousse between January 2009 and December 2011. There were five women and two men with a mean age of 49 years (range 27-78). Six patients had a history of acute pancreatitis and one case of acute pancreatitis on chronic pancreatitis. The average time of appearance of pseudocysts was 5 months (range 2-12). Five of our patients underwent a conventional intervention which consisted of a transgastric cystogastrostomy and they had a favourable outcome. One patient had a percutaneous drainage for infection of the pseudocyst, which recurred two months later, the patient was operated in the same way with a favourable outcome. Postoperative morbidity is zero. The last patient died preoperatively due to cardiac decompensation. Surgical treatment of pancreatic pseudocysts is an effective technique with low morbidity. This technique has two major advantages: excellent control of hemostasis and the possibility of creating a large communication thus minimizing the risk of recurrence and infection.

© 2013 ACT. All rights reserved.

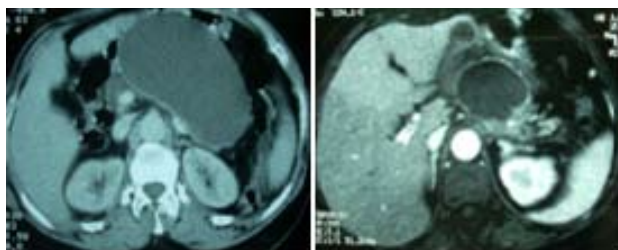
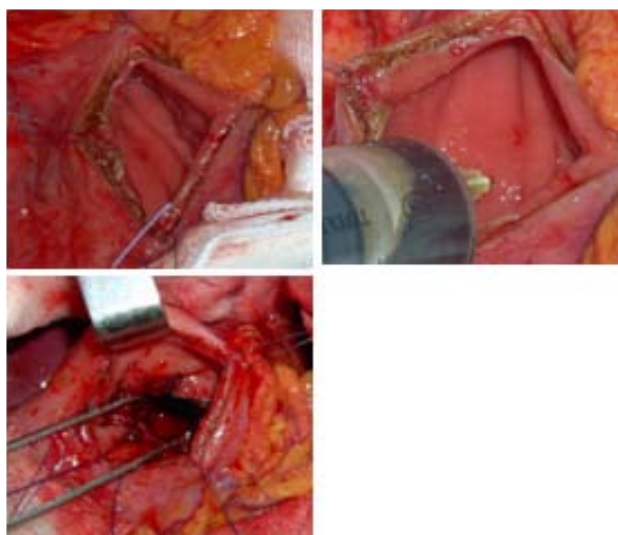
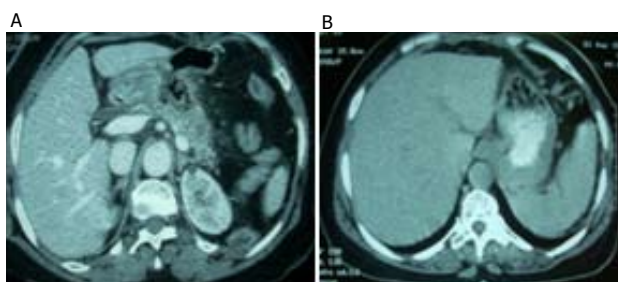
Key words: Pseudo-pancreatic cyst; Cystogastrostomy; Internal Drainage; Pancreatitis

Nefis A, Kouira M, Ben Mabrouk M, Bel Hadj Hmida M, Mazhoud J, Derbel F, Ben Ali A, Ajmi Salem, Arifa N, Kadri K, Moulahi H, Najja W, Bel Haj Hmida R. Surgical Treatment of Pancreatic Pseudocysts.

Table 1 summary of the different data concerning the 7 patients.

CASE	age	gender	Past medical history	Delay of onset of the pseudocyst (month)	Localisation and size of the pseudocyst (cm)	symptoms	treatment	Follow-up (month)
1	39	F	*	3	caudal 9	Abdominal pain	Cysto-gastrostomy	24
2	32	M	Blood hypertension	3	Corporeo-caudal 8	Abdominal pain	Cysto-gastrostomy	12
3	43	M	Blood hypertension, Diabetes Arythmia	12	Caudal 9	Abdominal pain	Non operated	died
4	68	F	Blood hypertension, diabetes	5	Corporeo-caudal 7	Abdominal pain	Cysto-gastrostomy	18
5	27	F	*	2	Corporeo-caudal 13	Abdominal pain + and vomiting	Cysto-gastrostomy	3
6	56	F	*	3	Caudal 6	Abdominal pain	Percutaneous drainage then Cysto-gastrostomy	8
7	78	F	*	12	Corporeal 8	Abdominal pain	Cysto-gastrostomy	15

A horizontal anterior gastrotomy is performed on a length of 5 cm, the hemostasis of the submucosal vessels is performed before the incision of the gastric mucosa. First, the cystic content is punctured then it is completed it by an incision of 3 to 5 cm at the posterior gastric wall and then the wall of the pseudocyst is hemmed to the gastric wall with interrupted sutures made of a slowly absorbable wire alongside the entire circumference of the orifice. The procedure is completed by an anterior gastrotomy closure in a extra mucosal plan with a slowly absorbable wire (Figure 2).

**Figure 1** CT-scan graphs illustrating the Pseudocyst preoperatively.**Figure 2** Intraoperative view showing the operative technique.**Figure 3** Postoperative CT-scan graphs showing the gradual disappearance of Pseudocyst in one week (A) and one month (B).

RESULTS

Five of our patients had a trans-gastric cyst-gastrostomy using the open laparotomy approach. The postoperative course was smooth in all cases. The symptoms related to pseudocysts disappeared within two weeks after surgery in all patients. CT scan control shows a partial pseudocyst sterilization after one month and a complete one within an average of 45 days after surgery (Figure 3). One patient had a percutaneous drainage for infection of the pseudocyst, the subsequent monitoring within two months has showed a relapse, despite the octreotid treatment, the was a persistence of the fistulae. The opacification through the drain did not show any communication with the pancreatic ducts. A panerteato-MRI was programmed but could not be performed (technical reson in our unit). An internal drainage was indicated. The endoscopic procedure was not possible in our department. The patient was operated, he underwent a cysto-gastrostomy with favorable outcome.

No postoperative complications were noted in the six operated patients. The last patient with a heavy past medical history with diabetes mellitus decompensation, blood hypertension, renal failure. The percutaneous drainage was programmed but not performed because the patient died before due to his sickness.

The follow-up of the operated patients after surgery was 13 months (3-24).

DISCUSSION

The evolution of PKP depends on their etiology. If they are associated with acute pancreatitis, it is conventionally assumed that cysts larger than 6 cm and persisting longer than six weeks after the acute episode require treatment to prevent complications^[3,5]. At this stage of evolution, the cyst wall is sufficiently strong and adherent to allow a cysto-digestive diversion. If PKP associated with chronic pancreatitis, it is often considered that a treatment should be offered more regularly because of the higher risk of complications and the low probability of spontaneous regression^[4] and that no treatment is justified in asymptomatic patients when the cyst does not exceed 4 cm^[6]. Internal drainage is the treatment of choice for PKP. Resection is proposed only in cases of complicated cyst, especially if it is located on the tail of the pancreas. External drainage is only indicated in case of infected cyst because of the high risk of pancreatic fistula and recurrence after such treatment^[3,7,8]. Whatever its location, it is always possible to surgically drain the PKP in a hollow organ (stomach, duodenum or jejunum)^[3,9,10].

The new therapeutic options are currently multiple (endoscopic or percutaneous internal drainage), however, conventional surgery still has its place. In a literature review in 1997, Beckingham concluded that endoscopic drainage of PKP was a minimally invasive treatment that, compared to conventional surgery, was accompanied by an equivalent recurrence rate but a lower morbidity and mortalityrate^[11].

Still, this treatment option is only possible if the PKP is attached to the stomach or the duodenum or if it communicates with the pancreatic duct, and only 27% of PKP associated with acute pancreatitis and 55% associated with PKP chronic pancreatitis meet these criteria^[11]. Moreover, drainage is technically feasible by endoscopy in 82% to 89% of patients and failure often requires a laparotomy. The two most common complications of endoscopic cystogastrostomy are hemorrhage (8%) and infection (8%)^[7,12,13], in such cases, conventional surgery has its indication to control the haemostasis especially for big sized PKP and to create a wide anastomosis thus minimizing the risk of early closure and secondary infection. The systematic use of prostheses in case of endoscopic drainage has been advocated, but specific complications were observed such as migration, plication, perforation and obstruction by necrotic material^[2,11,12,14].

Despite the indications of conventional surgery were reduced in favor of endoscopic procedures and interventional radiology, it still has the so called first-line indications represented by the impossibility of endoscopic treatment or a limited likely effectiveness. The other so-called second-line indications are represented by failures or complications of endoscopic or radiological interventions^[15]. The benefits of surgical treatment are represented by the radical nature of the treatment but still weighted with a failure rate of 10% and a recurrence rate of 20%. The main drawback of surgery is its invasiveness. Elements against relative contraindication to surgery can be considered as the patient's general condition, comorbidities or the presence of segmental portal hypertension^[15]. The advent of laparoscopy, with acceptable rates of morbidity (6%) and recurrence or failure (15%), allows to consider a lesser induced surgical morbidity, while preserving the indication of the act itself^[16,17].

Currently, laparoscopy bridges the gap that may exist between open surgery and laparoscopic surgery and it is a new and interesting therapeutic option. Ideally, the choice of the drainage technique should result from a collaboration between surgeons, gastroenterologists and radiologists depending on the location of the PKP, its content, the expertise of various mediators and the clinical context^[18].

The surgical management of PKP remains an important component especially if the pseudocyst is part of a more complex pathology. The indications are multidisciplinary with the goal of detecting patients who will be operated in any way by avoiding an excess of interventional actions, whether radiology or endoscopy.

REFERENCES

- 1 Poisson J, Nantais M, Echavé V. Pseudokyste du pancréas : évolution des concepts thérapeutiques. *Can J Surg* 1994; **37**: 450-456
- 2 Sharma SS, Bhargawa N, Govil A. Endoscopic management of pancreatic pseudocyst: a long term follow-up. *Endoscopy*

- 2002; **34**: 203-207
- 3 Eeftinck Schattenkerk M, De Vries JE, Bruining HA, Eggink WF, Obertop H. Surgical treatment of pancreatic pseudocysts. *Br J Surg* 1982; **69**: 593-594
- 4 Warshaw AL, Rattner DW. Timing of surgical drainage for pancreatic pseudocyst - Clinical and chemical criteria. *Ann Surg* 1985; **202**: 720-724
- 5 Bradley EL, Clements JL, Gonzalez AC. The natural history of pancreatic pseudocysts: a unified concept of management. *Am J Surg* 1979; **137**: 135-141
- 6 Yeo CJ, Bastidas JA, Lynch-nyhan A. The natural history of pancreatic pseudocysts documented by computed tomography. *Surg Gynecol Obstet* 1990; **170**: 411-417
- 7 Cremer M, Deviere J, Engelholm L. Endoscopic management of cysts and pseudocysts in chronic pancreatitis: long-term follow-up after 7 years of experience. *Gastrointest endosc* 1989; **35**: 1-9
- 8 Lo SK, Rowe A. Endoscopic management of pancreatic pseudocysts. *The Gastroenterologist* 1997; **5**: 10-25
- 9 Kohler H, Schafmayer A, Ludtke FE, Lepsien G, Peiper H-J. Surgical treatment of pancreatic pseudocysts. *Br J Surg* 1987; **74**: 813-815
- 10 Newell KA, Liu T, Aranha GV, Prinz RA. Are cystogastrostomy and cystojejunostomy equivalent operations for pancreatic pseudocysts. *Surgery* 1990; **108**: 635-640
- 11 Beckingham IJ, Krige JEJ, Bornman PC, Terblanche J. Endoscopic management of pancreatic pseudocyst. *Br J Surg* 1997; **84**: 1638-1645
- 12 Bejanin H, Liguory C, Ink O, Fritsch J, Choury AD, Lefebvre JF, et al. Drainage endoscopique des pseudo-kystes du pancréas. *Gastroenterol Clin Biol* 1993; **17**: 804-810
- 13 De Guzman KP, Holdermen WH, Abu-Hamour A. Endoscopic drainage of pancreatic pseudocyst: patient selection and evaluation of the outcome by endoscopic ultrasonography. *Endoscopy* 1995; **27**: 329-333
- 14 Henriksen FW, Hancke S. Percutaneous cystogastrostomy for chronic pancreatic pseudocyst. *Br J Surg* 1994; **81**: 1525-8.
- 15 Hamy A, Mucci S, Prise en charge des pseudo-kystes pancréatiques. *Place de la chirurgie*
- 16 Hauters P, Weerts J, Peillon C et al. Treatment of pancreatic pseudocysts by laparoscopic cystogastrostomy. *Ann Chir* 2004; **129**: 347-352
- 17 Park AE, Heniford BT. Therapeutic laparoscopy of the pancreas. *Ann Surg* 2002; **236**: 149-158
- 18 Kozarek RA. Endoscopic treatment of pancreatic pseudocysts. *Gastrointest Endosc Clin North Am* 1997; **7**: 271-283

Peer reviewers: Toshiyuki Ishiwata, MD, PhD, Associate Professor, Departments of Pathology and Integrative Oncological Pathology, Nippon Medical School, 1-1-5 Sendagi, Bunkyo-ku, Tokyo 113-8602, Japan; Premashish Halder, Professor, Head Of Department Of Gastrointestinal Surgery, Jagjivanram Hospital, Maratha Mandir Lane, Mumbai Central, Mumbai - 400 008. India.