

Percutaneous-Endoscopic Rendezvous Technique for Treatment of Malignant Biliary Obstruction in a Gastric Cancer Patient after Billroth II Gastrectomy

Lianda Siregar^{1,2(*)}, Imelda Maria Loho^{1,2}, Agus Sudiro Waspodo¹, Hendro Saulata¹, Viharsyah Aulia Akbar¹, Rahmanandhika Swadari¹

1 Department of Gastroenterology and Hepatology, "Dharmais" Hospital, Indonesian National Cancer Center, Jakarta, Indonesia;

2 Hepatobiliary Division, Department of Internal Medicine, Faculty of Medicine, Universitas Indonesia, Jakarta, Indonesia.

Conflict-of-interest statement: The authors declare that there is no conflict of interest regarding the publication of this paper.

Open-Access: This article is an open-access article which was selected by an in-house editor and fully peer-reviewed by external reviewers. It is distributed in accordance with the Creative Commons Attribution Non Commercial (CC BY-NC 4.0) license, which permits others to distribute, remix, adapt, build upon this work non-commercially, and license their derivative works on different terms, provided the original work is properly cited and the use is non-commercial. See: <http://creativecommons.org/licenses/by-nc/4.0/>

Correspondence to: Lianda Siregar, Department of Gastroenterology and Hepatology, "Dharmais" Hospital, Indonesian National Cancer Center, Jakarta, Indonesia.

Telephone: +62-21-5681570, ext. 2335

Email: liandadr_siregar@yahoo.com

Received: April 6, 2021

Revised: May 15, 2021

Accepted: May 17, 2021

Published online: October 21, 2021

ABSTRACT

Gastric cancer is the fifth most commonly diagnosed cancer in the world, with a peak incidence rate at 60 years of age and men affected more than women. Obstructive jaundice is a rare symptom associated with gastric cancer, with a prevalence rate of 2.3%. Management of obstructive jaundice through endoscopic retrograde cholangiopancreatography (ERCP) may be challenging in patients with an altered anatomy, such as a previous history of having undergone a Billroth II. As such, rendezvous techniques of ERCP and percutaneous transhepatic biliary drainage (PTBD) that enter one location through two access points can be used to alleviate the complexities of altered anatomy due to previous abdominal surgery of which ERCP alone

was technically difficult and often unsuccessful in problematic conditions. In this case report we present a case of a male with a previous history of a rendezvous technique with ERCP and PTBD, following a Billroth II gastrectomy, and successful stent implantation without any complication.

Key words: Percutaneous-endoscopic rendezvous technique; Endoscopic retrograde cholangiopancreatography; Billroth II procedure; Bile duct obstruction; Gastric cancer

© 2021 The Authors. Published by ACT Publishing Group Ltd. All rights reserved.

Siregar L, Loho IM, Waspodo AS, Saulata H, Akbar VA, Swadari R. Percutaneous-Endoscopic Rendezvous Technique for Treatment of Malignant Biliary Obstruction in a Gastric Cancer Patient after Billroth II Gastrectomy. *Journal of Gastroenterology and Hepatology Research* 2021; **10(5)**: 3596-3598 Available from: URL: <http://www.ghrnet.org/index.php/joghr/article/view/3127>

INTRODUCTION

Gastric cancer is the fifth most commonly diagnosed cancer in the world with a peak incidence rate at 60 years of age and men affected more often than women. Gastric cancer causes 783,000 deaths each year, making it the third most fatal cancer among males^[1]. Patients with gastric cancer would have symptoms and signs such as epigastric pain, hematemesis, melena, weight loss, anorexia, and nausea. Vomiting may occur if there is an obstruction, while dysphagia may occur if the tumor is located in the cardia. Symptoms of obstructive jaundice in gastric cancer were not commonly found and thus was a rare complication^[2].

Endoscopic retrograde cholangiopancreatography (ERCP) is the treatment of choice for the management of obstructive jaundice in gastrointestinal tumor due to its minimally invasive nature^[3]. However, performing ERCP in patients with surgically altered anatomy, such as post Billroth-II gastrectomy, is more challenging, particularly as it relates to the insertion to the afferent loop and the cannulation procedure. In order to address these difficulties, the rendezvous technique, which combines the endoscopic and percutaneous techniques to reach one location through two access

points, was used^[4].

Here we present a case where we used the rendezvous technique with ERCP and percutaneous transhepatic biliary drainage (PTBD) to implant a stent in a patient with altered anatomy due to a previous history of Billroth-II gastrectomy.

CASE SUMMARY

A 73-year-old male presented to the outpatient clinic of our department with a primary complaint of yellowish eyes for two weeks, accompanied by additional symptoms of nausea and vomiting. He had a history of gastric adenocarcinoma with poor differentiation, three years prior to admission and underwent a Billroth-II gastrectomy, followed by six cycles of chemotherapy with docetaxel and carboplatin. The patient did not present for follow-up during the last year and finally came to our clinic with yellowish eyes and skin. Other past medical history was unremarkable.

On physical examination, the patient had obvious jaundice with scleral icterus. Other physical findings were unremarkable. On blood test, his total bilirubin level was 22.88 mg/dL with direct bilirubin 22.12 mg/dL. Other laboratory findings were as follows: hemoglobin 12.5 g/dL, white blood cells $9.44 \times 10^3/\mu\text{L}$, ALT 46 U/L, AST 79 U/L ALP 359 U/L, GGT 269 U/L, albumin 3.4 g/dL, CA 72-4: 30.24 U/mL. Abdominal CT revealed multiple peripancreatic and periduodenal mesenteric lymph nodes enlargement attached to the head of the pancreas and the common bile duct, (CBD) causing dilation of common bile duct (CBD), as well as right and left hepatic ducts (Figure 1). No residual mass in the perianastomotic region was detected.

ERCP was attempted but the afferent limb and the ampulla could not be reached with the conventional side-viewing duodenoscope. Therefore, the percutaneous-endoscopic rendezvous technique was performed. An 80cm long 0.035-inch hydrophilic guidewire (Cook Medical) was inserted into the jejunum using a left-lobe approach under fluoroscopic guidance with the patient supine (Figure 2A). The endoscope was then inserted orally by the operator to reach the biliary orifice. However, endoscope insertion was difficult due to looping, therefore abdominal pressure placed by the hand of an assistant was applied. The distal tip of the guidewire was grasped with a snare and passed through the working channel of the duodenoscope (Figure 2B). Retrograde cannulation was achieved over the guidewire and a 10 Fr, 11-cm plastic stent was successfully implanted (Figure 2C and 2D). The patient was discharged without any complication.

DISCUSSION

Obstructive jaundice in gastric cancer is a rare complication, with the incidence of jaundice associated with gastric cancer reported to be only 2.3%^[5]. In some cases, ERCP may be challenging as sometimes, the endoscope cannot reach the ampulla of Vater due to gastric outlet obstruction by the tumor, or due to surgically altered anatomy^[6], such as Billroth I, Billroth II, and Roux-en-Y^[7]. The difficulties to guide the endoscope into the loop is caused by the presence of anastomosis angulations, adhesions, excessive length, Braun entero-entero-anastomosis, and distorted anatomy at the duodeno-jejunal angle^[8,9]. Patients with surgically altered anatomy have lower ERCP success rates compared with patients having normal anatomy^[10]. Altered anatomy is found in patients with congenital anomalies, duodenal stenosis, large periampullary diverticula, and also diversionary surgery, of which Billroth II partial gastrectomy is the most common^[8]. In a study by Cheng et al it was shown that the success rate of ERCP in patients with a prior history of Billroth II

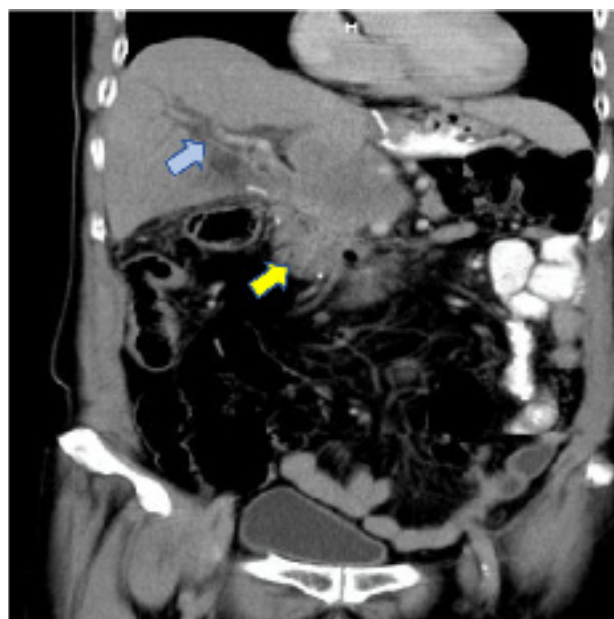

Figure 1 Abdominal CT showed dilated right intrahepatic duct (blue arrow), as well as enlarged lymph nodes (yellow arrow) which obstructed the CBD.

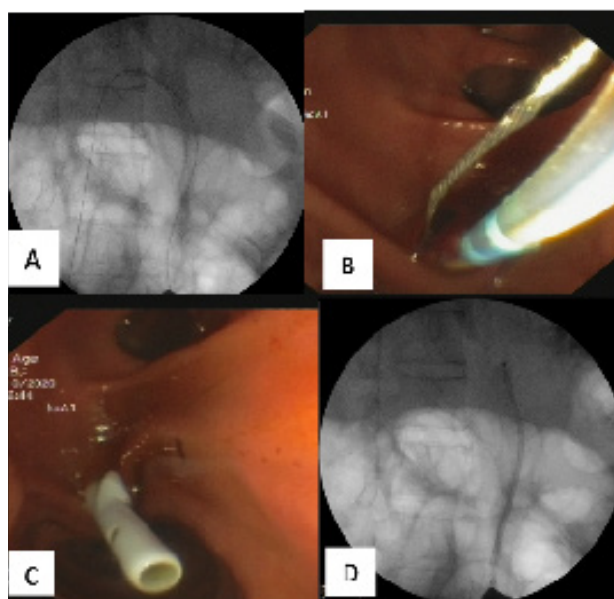


Figure 2 A guidewire was introduced from the left hepatic bile duct to jejunum B. The distal tip of the guidewire was grasped with a snare. C and D. Successful stent implantation in CBD.

gastrectomy varies from 68% to 92%^[11].

Stent implantation through the rendezvous technique of PTBD and ERCP is a minimally invasive treatment procedure for obstructive jaundice. The indications for this procedure must meet the indications for both PTBD and ERCP^[3]. Ying et al study showed that the indication for both PTBD and ERCP was obstructive jaundice, high serum bilirubin level, dilated bile duct above the stricture, no ascites around the puncture site, normal coagulation function, inability to enter the common bile duct due to distortion of the ampulla, or an inability to pass a guide wire across the lesion during the initial ERCP^[3].

The key to a successful rendezvous technique lies at advancing the PTBD guidewire across the ampulla of Vater to guide the endoscope^[3]. A rendezvous technique after percutaneous transhepatic biliary drainage (PTBD), which requires a dilated intrahepatic duct,

can facilitate the cannulation^[12]. If the intrahepatic duct is not dilated, the safety performance of the percutaneous transhepatic rendezvous technique can be challenging. A double-balloon enteroscopy (DBE), single-balloon enteroscopy (SBE), and rotational or spiral enteroscopy (SE) is the device - assisted endoscope that can increase ERCP success rate in patients with surgically altered anatomy. Krutsri et al study reported a DBE insertion success rate of 90%-100% in Billroth II gastrectomy.^[12]

An understanding of the different types of postoperative reconstruction anatomy is important to determine the easiest way to access the afferent limb and also to select the most appropriate endoscopic technique^[3]. By understanding postoperative reconstruction anatomy and the correct procedure, we can minimize postoperative complications. However, ERCP failure can increase the risk of acute pancreatitis due to the procedure. The occurrence rate of post-ERCP pancreatitis has been reported to be 7.3-17%, even when methods for difficult bile duct cases were used. Therefore, further caution is needed to minimize ERCP failure and to avoid further complication^[13].

CONCLUSION

In this case, we succeeded in performing a rendezvous technique with both ERCP and PTBD guided by guidewire into the ampulla of Vater and implanting the stent in a patient that underwent previous Billroth II gastrectomy. In conclusion, the rendezvous technique can be used for unsuccessful ERCP and management of biliary obstruction.

REFERENCE

1. Rawla P, Barsouk A. Epidemiology of gastric cancer: global trends, risk factors and prevention. *Gastroenterol Rev.* 2019; **14(1)**: 26-38. [DOI: 10.5114/pg.2018.80001]
2. Bowles MJ, Benjamin IS. ABC of the upper gastrointestinal tract: Cancer of the stomach and pancreas. *BMJ.* 2001 Dec 15; **323(7326)**: 1413-1416. [PMID: 11744568]; [DOI: 10.1136/bmj.323.7326.1413]
3. LIU Y Di, WANG ZQ, WANG XD, YANG YS, LINGHU EQ, WANG WF, LI W, CAI FC. Stent implantation through rendezvous technique of PTBD and ERCP: The treatment of obstructive jaundice. *J Dig Dis.* 2007 Nov; **8(4)**: 198-202. [PMID: 17970876]; [DOI: 10.1111/j.1751-2980.2007.00305.x]
4. Meek J, Fletcher S, Crumley K, Culp WC, Meek M. Percutaneous rendezvous technique for the management of a bile duct injury. *Radiol Case Reports.* 2018 Feb; **13(1)**: 175-178. [PMID: 29487652]; [DOI: 10.1016/j.radcr.2017.11.004]
5. Shiraishi N, Yasuda K, Kakisako K, Inoue T, Kitano S, Adachi Y. Gastric cancer presenting with obstructive jaundice. *Gastric Cancer.* 1999 May 31; **2(1)**: 76-78. [PMID: 11957075]; [DOI: 10.1007/s101200050025]
6. Ogura T, Okuda A, Miyano A, Imanishi M, Nishioka N, Yamada M, Yamada T, Kamiyama R, Masuda D, Higuchi K. EUS-guided versus percutaneous biliary access in patients with obstructive jaundice due to gastric cancer. *Dig Liver Dis.* 2019 Feb; **51(2)**: 247-252. [DOI: 10.1016/j.dld.2018.09.015]
7. Forbes A, Cotton PB. ERCP and sphincterotomy after Billroth II gastrectomy. *Gut.* 1984 Sep 1; **25(9)**: 971-974. [PMID: 6469083]; [DOI: 10.1136/gut.25.9.971]
8. Bove V, Tringali A, Familiari P, Gigante G, Boškoski I, Perri V, Mutignani M, Costamagna G. ERCP in patients with prior Billroth II gastrectomy: report of 30 years' experience. *Endoscopy.* 2015 Mar 2; **47(07)**: 611-616. [PMID: 25730282]; [DOI: 10.1055/s-0034-1391567]
9. Lin L-F, Siau C-P, Ho K-S, Tung J-C. ERCP in Post-Billroth II Gastrectomy Patients: Emphasis on Technique. *Am J Gastroenterol.* 1999 Jan; **94(1)**: 144-148. [PMID: 9934745]; [DOI: 10.1111/j.1572-0241.1999.00785.x]
10. Shao X-D, Qi X-S, Guo X-Z. Endoscopic retrograde cholangiopancreatography with double balloon enteroscope in patients with altered gastrointestinal anatomy: A meta-analysis. *Saudi J Gastroenterol.* **23(3)**: 150-160. [PMID: 28611338]; [DOI: 10.4103/1319-3767.207713]
11. Cheng C-L, Liu N-J, Tang J-H, Yu M-C, Tsui Y-N, Hsu F-Y, Lee C-S, Lin C-H. Double-balloon enteroscopy for ERCP in patients with Billroth II anatomy: results of a large series of papillary large-balloon dilation for biliary stone removal. *Endosc Int Open.* 2015 May 6; **3(03)**: E216-E222. [PMID: 26171434]; [DOI: 10.1055/s-0034-1391480]
12. Krutsri C, Kida M, Yamauchi H, Iwai T, Imaizumi H, Koizumi W. Current status of endoscopic retrograde cholangiopancreatography in patients with surgically altered anatomy. *World J Gastroenterol.* 2019 Jul 14; **25(26)**: 3313-3333. [PMID: 31341358]; [DOI: 10.3748/wjg.v25.i26.3313]
13. Sunada F, Morimoto N, Tsukui M, Kurata H. The rendezvous technique involving insertion of a guidewire in a percutaneous transhepatic gallbladder drainage tube for biliary access in a case of difficult biliary cannulation. *J Rural Med.* 2017; **12(1)**: 46-49. [PMID: 28593017]; [DOI: 10.2185/jrm.2918]