

Journal of Gastroenterology and Hepatology Research

Online Submissions: <http://www.ghrnet.org/index./joghr/>
doi: 10.17554/j.issn.2224-3992.2021.10.1002

Journal of GHR 2021 April 21; **10(2)**: 3492-3496
ISSN 2224-3992 (print) ISSN 2224-6509 (online)

CASE REPORT

Portal Venous Gas of Uncertain Etiology with Delayed Portal Vein Thrombosis: A Case Report and Review of the Literature

Francisco A. Durazo^{1,2,3}, MD, FACP, FAASLD, FASGE; Kelly Kristbaum^{1,2}, NP; Igor Shusterman⁴, MD; Joohyun Kim^{1,2}, MD, PhD; Kaitlin Kirkpatrick⁵; Michael A. Zimmerman^{1,2}, MD, FACS; Johnny C. Hong^{1,2}, MD, FACS

1 Division of Transplant Surgery, Department of Surgery, Medical College of Wisconsin, Milwaukee, Wisconsin, the United States;

2 The Transplant Center, Froedtert and The Medical College of Wisconsin, Milwaukee, Wisconsin, the United States;

3 Division of Gastroenterology and Hepatology, Department of Medicine, Medical College of Wisconsin, Milwaukee WI, the United States;

4 Department of Emergency Medicine, Froedtert and The Medical College of Wisconsin, Milwaukee, Wisconsin, the United States;

5 Department of Internal Medicine, Froedtert and The Medical College of Wisconsin, Milwaukee, Wisconsin, the United States.

Conflict-of-interest statement: The authors declare that there is no conflict of interest regarding the publication of this paper.

Open-Access: This article is an open-access article which was selected by an in-house editor and fully peer-reviewed by external reviewers. It is distributed in accordance with the Creative Commons Attribution Non Commercial (CC BY-NC 4.0) license, which permits others to distribute, remix, adapt, build upon this work non-commercially, and license their derivative works on different terms, provided the original work is properly cited and the use is non-commercial. See: <http://creativecommons.org/licenses/by-nc/4.0/>

Correspondence to: Francisco A. Durazo, MD, FACP, FAASLD, FASGE, Division of Transplant Surgery, Department of Surgery, Medical College of Wisconsin, Transplant Center, 9200 W. Wisconsin Avenue, CFAC 2nd Floor, Suite H2200, Milwaukee, Wisconsin 53226, the United States.

Email: fdurazo@mcw.edu

Telephone: +1-414-805-6400

Fax: +1-414-805-4343

Received: March 14, 2021

Revised: March 26, 2021

Accepted: March 29, 2021

Published online: April 21, 2021

ABSTRACT

Historically, the presence of portal venous gas (PVG) on plain abdominal films was an indication for exploratory laparotomy and seen

as an ominous finding with a mortality of almost 100%. Over the last decades, the introduction of CT scan has facilitated the diagnosis of PVG with a subsequent decrease in the mortality. PVG has been associated with ischemic bowel but also with other more benign conditions. We describe a case of a young patient with PVG of uncertain etiology with delayed portal vein thrombosis, with a discussion on the different conditions associated with PVG and the approach to the patient with PVG.

Key words: Portal venous gas; Ischemic bowel; Portal vein thrombosis

© 2021 The Authors. Published by ACT Publishing Group Ltd. All rights reserved.

Durazo FA, Kristbaum K, Shusterman I, Kim J, Kirkpatrick K; Zimmerman MA, Hong JC. Portal Venous Gas of Uncertain Etiology with Delayed Portal Vein Thrombosis: A Case Report and Review of the Literature. *Journal of Gastroenterology and Hepatology Research* 2021; **10(2)**: 3492-3496 Available from: URL: <http://www.ghrnet.org/index.php/joghr/article/view/3133>

INTRODUCTION

The presence of portal venous gas (PVG) is a rare radiologic finding seen in different clinical conditions. The most common cause is intestinal ischemia, which is associated with high mortality^[1]. PVG has also been reported in patients with a great variety of conditions, including inflammatory bowel disease, obstructive airway disease, connective tissue disease, post-chemotherapy, after organ transplantation, after diving, among others^[2-12]. Most of the cases have been documented by individual case reports or small case series. PVG of uncertain etiology is extremely rare. A case series of 47 patients with portal venous gas had 5 patients in which no etiology could be found clinically and on imaging studies^[13]. The delayed appearance of portal vein thrombosis after portal venous gas is also very rare. To date, there are only 4 cases reported in the literature^[14-17]. We report a young patient with portal venous gas of uncertain etiology accompanied by delayed portal vein thrombosis.

CASE REPORT

A 29-year-old female presented to the emergency department (ED)

complaining of intermittent nausea and watery diarrhea over three days with one episode of vomiting. Symptoms progressed to include right upper quadrant pain on the day of presentation. The pain worsened with movement, palpation, and eating. She denied any fever, melena or hematochezia. Review of symptoms was also positive for decreased oral intake, dizziness, malaise and chills. She is a third-year medical resident caring for ill patients but denied any ill contacts at home. The remainder of the review of systems was negative. Her past medical history included history of ADHD controlled with Vyvanse, asthma on Singulair and Albuterol prn, migraines and history of past eating disorder. Surgical history was positive for medial ligament repair of the knee. She denied cigarette use or alcohol use. She is married with one child. She was nine months post-partum with a healthy male born at 35 weeks 5 days and was breastfeeding. She denied any recent travel, allergies or new medications. Her vital signs in the ED revealed a blood pressure of 83/51, pulse of 57, afebrile and oxygen saturation of 100% on room air. Abnormal physical examination findings revealed an ill-appearing, pale and diaphoretic female with guarding to the abdomen and positive McBurney's sign. There were no peritoneal signs. The rest of her examination was normal.

An abdominal ultrasound revealed normal size liver with heterogeneous echogenic foci throughout the liver, particularly around the portal tract, most concerning for portal venous gas, no biliary dilation. Hepatic function panel significant for an AST of 130 U/L, ALT of 78 U/L, alkaline phosphatase of 128 U/L with a total bilirubin of 1.3 mg/dl. White blood cell count was 8.3/mm³, hemoglobin 11.3 g/L with a lactic acid of 1.1 mmol/L. Urine pregnancy test was negative. A wet mount for vaginal pathogens was negative for *Trichomonas*, yeast, or clue cells. She was immediately sent for computed tomography (CT) of the abdomen and pelvis which confirmed the extensive portal venous gas and identified periportal edema. There was no evidence of bowel wall thickening or bowel hypo enhancement seen, no pneumatosis, no appendicitis or other abnormalities noted. She was given intravenous fluids and started on ciprofloxacin and metronidazole for presumed intra-abdominal source of infection and urgently transferred to our facility for surgical consultation. She was admitted to the Transplant Intensive Care Unit under care of the Liver Transplant Surgery team.

Upon admission, antibiotics were broadened to include aztreonam, metronidazole, and vancomycin as well as micafungin for antifungal coverage. Laboratory studies resulted negative for hepatitis, human immunodeficiency virus (HIV), and influenza. Urine drug, alcohol, acetaminophen, and salicylate tests were all negative. Alpha-fetoprotein was 1.8 ng/mL and PT/INR remained normal during her hospitalization. Her liver function tests down trended daily and she clinically improved without evidence of infection. Three days after initial presentation, a follow up CT of the abdomen and pelvis revealed near resolution of portal venous gas however a new thrombus within the portal venous branches. No bowel or intra-abdominal abnormalities. Hypercoagulable state work up was negative for JAK2, Factor V Leiden, antithrombin III, Protein S/C deficiency, lupus anticoagulant, cardiolipin antibodies, and homocysteine. She was anticoagulated with Lovenox 1 mg/kg twice daily. On hospital day four, she was discharged home to complete a fourteen-day empiric course of antibiotics. She was advised to avoid breastfeeding until antibiotic therapy was complete.

Follow up with Hepatology occurred at one week and five weeks post discharge. Laboratory tests revealed normalization of her liver tests and normal PT/INR. She denied any complaints beside one loose bowel movement per day which was attributed to her antibiotics. She followed with Hematology as an outpatient and completed a three-month course of anti-coagulation. Repeat abdominal CT scan

8 months later revealed thrombosis of an anterior segmental branch of the right portal vein into segment 8 showing a residual area of geographic low attenuation either representing persistent perfusion anomaly, segmental infarct or fatty replacement.

DISCUSSION

PVG is a rare radiologic finding. First described by Wolfe in 1955 in infants with necrotizing enterocolitis seen on plain abdominal X-rays with postmortem anatomical correlation^[18]. Early reports associated PVG with bowel gangrene with a high mortality and was an indication for exploratory laparotomy^[19]. Since the advent of CT scan of the abdomen, the presence of PVG has been described accompanying other more benign conditions besides bowel gangrene with a mortality of 25-35%^[2-12]. CT has allowed visualization of small amounts of intra-abdominal air that could not be seen at conventional abdominal radiography^[20].

CT scan or magnetic resonance imaging (MRI) have become the gold standard for the diagnosis of PVG. PVG can be differentiated from pneumobilia in that pneumobilia is associated with air within the central portion of the liver, which does not extend toward the liver capsule. In PVG air extends to 2 cm or less from the liver capsule. Air within the portal venous system is likely to be transported to the small peripheral branches in the liver by the centrifugal flow of portal venous blood, whereas air in the biliary tree is prevented from migrating peripherally by the centripetal flow of the bile^[21].

The exact mechanism of why air reaches the portal vein is still unknown. The factors that have been involved in the development of PVG are intestinal wall alteration or disruption, bowel distention, ischemia and sepsis. Mucosal barrier disruption of any kind can theoretically result in PVG, but it appears to be more common with intestinal ischemia, necrotizing enterocolitis, inflammatory bowel and peptic ulcer disease^[22]. Pneumatosis intestinalis (PI) not infrequently occurs in combination with PVG^[4,6]. Iatrogenic mucosal breaks from endoscopic biopsies can also result in PVG. Gastric and bowel distention can produce mucosal disruption that theoretically allows intraluminal gas to become intravascular. Iatrogenic gastric and bowel distention from endoscopic procedures is a well described cause of PVG^[23-26].

Several infections have been associated with PVG, including diverticulitis, cholangitis, abdominal tuberculosis and abdominal abscess^[27]. The pathogenesis of PVG associated with infectious gastrointestinal diseases is not fully understood. One theory states that PVG results from septicemia due to pylephlebitis^[28]. Another theory states that PVG results from increased intraluminal fermentation of carbohydrates due to bacteria^[27]. A third theory states that, in the case of diverticulitis, there is a perforation that dissects and creates access to the mesocolic veins^[29]. PVG has been associated with intra-abdominal abscess without mucosal damage in some cases^[30]. The pathophysiology is probably different in each case, depending on the underlying pathology.

There are several conditions that have been associated with the presence of PVG such as obstructive airway disease, connective tissue disease, post-chemotherapy, after organ transplantation, pelvic inflammatory disease, graft versus host disease, after diving, among others. The clinical outcome of these patients was determined by their underlying disease and not negatively influenced by the presence of PVG. Although the presence of PVG usually raises the suspicion of bowel ischemia, PVG on CT scan may be related to a variety of non-ischemic etiologies and pathophysiologic mechanisms as well^[31-33,34,5,10,11].

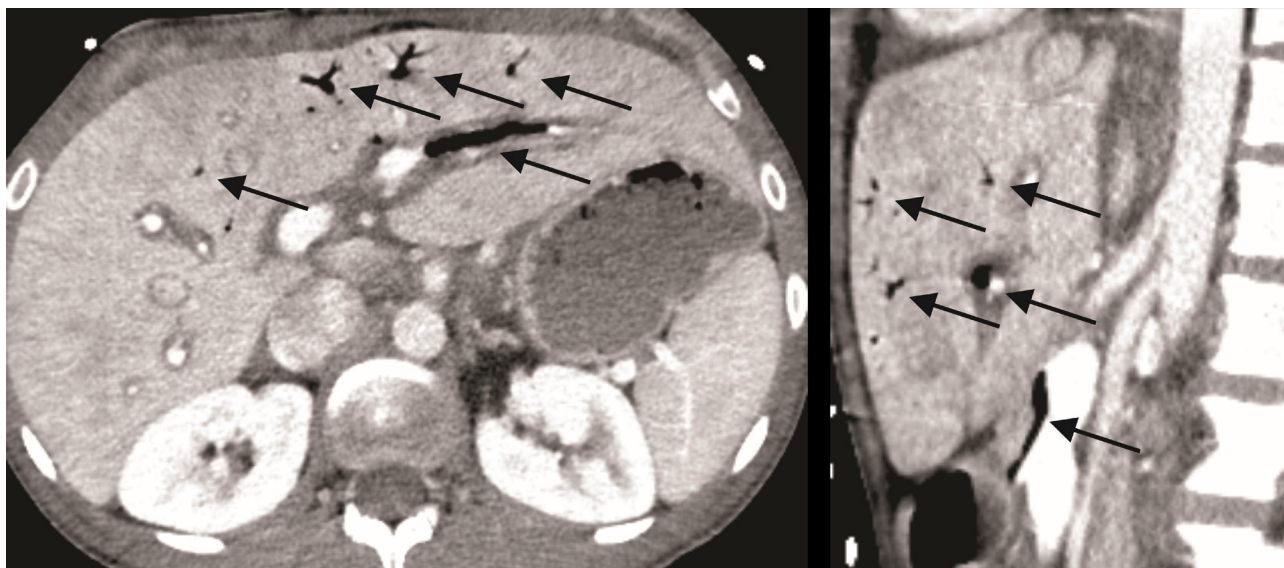


Figure 1 Extensive portal venous gas without definitive source. No bowel wall thickening or bowel hypoenhancement is seen. Diffuse periportal edema and heterogeneity of the liver parenchyma which is nonspecific.

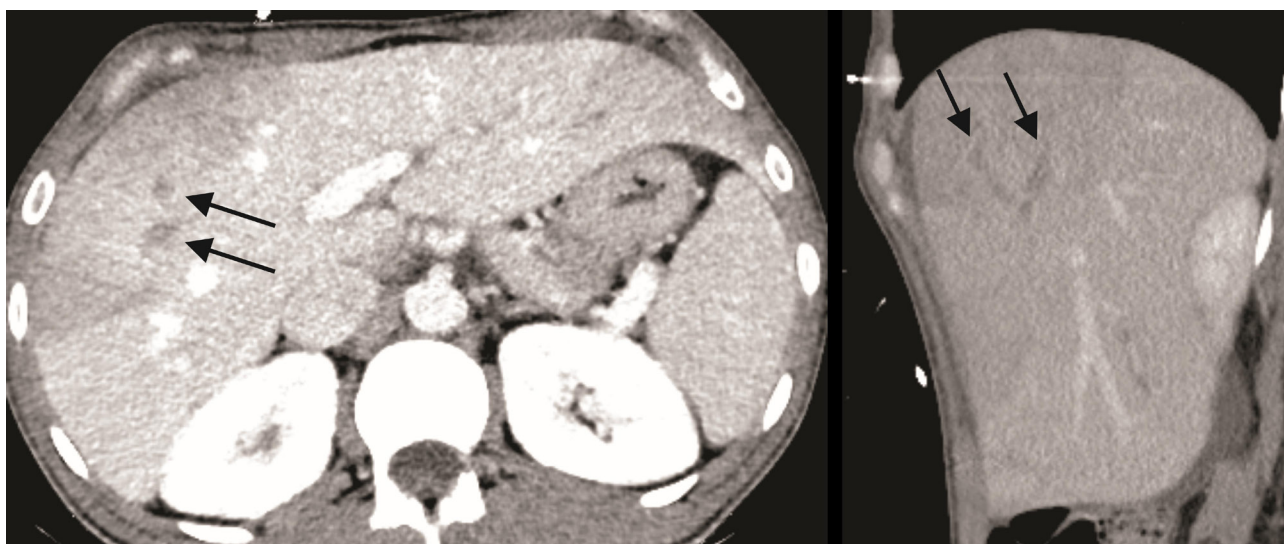


Figure 2 Interval development of thrombus within the right portal vein. Associated geographic hypoattenuation is favored perfusional in nature.

There are rare cases in which the etiology of PVG cannot be determined, like in the case of the patient we describe. A retrospective study of 47 patients with PVG found that in 5 of the cases the underlying etiology was uncertain. Three of the 5 patients with PVG of uncertain etiology did not survive and the cause of death was not mentioned^[13]. In another retrospective study by Hussain *et al* on 275 patients, PVG was idiopathic in only 1.8%, no outcomes were mentioned^[35]. In our young patient, the presence of PVG could not be explained by underlying medical conditions or by other radiological findings on CT scan.

Since PVG has been associated with both, fatal conditions (i.e. ischemic bowel) and benign conditions (i.e. Crohn's disease), it is imperative to diagnose the underlying condition causing PVG to establish a treatment plan and assess prognosis. Not all the causes of PVG produce the same outcomes. A detailed clinical and radiological evaluation should be done in all the patients that are found to have PVG before making decisions regarding diagnosis and therapy. Early reports indicated that PVG was diagnostic of bowel gangrene and that the presence of PVG required exploratory laparotomy^[18]:

^{19]}. However, over the last two decades, there has been a major shift from early surgical intervention with exploratory laparotomy to less aggressive therapy with observation and antimicrobial therapy. In most of the cases, the prognosis is favorable and surgery is not required. However, when the CT scan demonstrates PVG and the clinical findings suggest the presence of mesenteric ischemia, surgery is mandatory^[21].

A prospective study in 117 patients with pneumatosis intestinalis showed that the presence of PVG and pneumatosis intestinalis simultaneously in any given patient with elevated lactate levels and peritonitis, or decreased hemoglobin with an elevated INR and elevated lactate raises a strong suspicion of bowel necrosis requiring surgical exploration^[36]. A retrospective study by Heye *et al.* showed that the presence of gas at specific anatomical locations in the portomesenteric venous system, namely the arcade and segmental vessels, may serve as a strong indicator for ischemic etiology and poor prognosis in the assessment of individual cases of PVG^[13].

Our patient presented with abdominal pain, nausea and diarrhea. She did not have any significant underlying medical conditions.

Her medical history was significant for having a normal delivery 9 months prior. Her work up was non-contributory and there was no other abnormality on CT scan of the abdomen and pelvis that would suggest an intra-abdominal infection, PI or bowel necrosis. Because of the clinical and CT scan findings, we decided to treat her conservatively with antibiotics and observation. She improved clinically and a follow up CT scan of the abdomen showed near resolution of the PVG but new onset of portal vein thrombosis. No underlying cause for the portal vein thrombosis could be noted.

The etiology of delayed development of acute portal vein thrombosis in our patient with PVG is unclear and an unusual occurrence. Her evaluation for an underlying hypercoagulable state was non-contributory and there was no obvious pylephlebitis on her CT scan. To our knowledge, there are only 4 cases reported in the literature with delayed portal vein thrombosis after PVG [14-17]. She completed a course of antibiotics and was placed on anticoagulation with resolution of her symptoms. A follow up CT scan showed no significant abnormalities except for a residual thrombus in the anterior segmental branch of the right portal vein into segment 8.

CONCLUSION

We present a case of a young patient with PVG of uncertain etiology with delayed portal vein thrombosis treated conservatively with good outcome. PVG is frequently caused by mesenteric ischemia but may have a variety of other causes, and does not necessarily require surgical treatment. Findings of PVG on CT scan should be carefully evaluated in the context of clinical findings. In most of the cases, the prognosis is favorable and surgery is not required. The occurrence of acute portal vein thrombosis after PVG is not common and, if present, should be treated with anticoagulation.

REFERENCES

- Kinoshita H, Shinozaki M, Tanimura H, Umemoto Y, Sakaguchi S, Takifuji K, Kawasaki S, Hayashi H, Yamaue H. Clinical features and management of hepatic portal venous gas: four case reports and cumulative review of the literature. *Arch Surg.* 2001; **136**(12): 1410-4. [PMID: 11735870]; [DOI: 10.1001/archsurg.136.12.1410]
- Iannitti DA, Gregg SC, Mayo-Smith WW, Tomolonis RJ, Cioffi WG, Pricolo VE. Portal venous gas detected by computed tomography: is surgery imperative? *Dig Surg.* 2003; **20**(4): 306-15. [PMID: 12806196]; [DOI: 10.1159/000071756]
- Monneuse O, Pilleul F, Barth X, Gruner L, Allaouchiche B, Valette PJ, Tissot E. Portal venous gas detected on computed tomography in emergency situations: surgery is still necessary. *World J Surg.* 2007; **31**(5): 1065-71. [PMID: 17429565]; [DOI: 10.1007/s00268-006-0589-0]
- Morris MS, Gee AC, Cho SD, Limbaugh K, Underwood S, Ham B, Schreiber MA. Management and outcome of pneumatosis intestinalis. *Am J Surg.* 2008; **195**(5): 679-82; discussion 82-3. [PMID: 18424288]; [DOI: 10.1016/j.amjsurg.2008.01.011]
- Chezmar JL, Nelson RC, Bernardino ME. Portal venous gas after hepatic transplantation: sonographic detection and clinical significance. *AJR Am J Roentgenol.* 1989; **153**(6): 1203-5. [PMID: 2683676]; [DOI: 10.2214/ajr.153.6.1203]
- St Peter SD, Abbas MA, Kelly KA. The spectrum of pneumatosis intestinalis. *Arch Surg.* 2003; **138**(1): 68-75. [PMID: 12511155]; [DOI: 10.1001/archsurg.138.1.68]
- Wiesner W, Morteale KJ, Glickman JN, Ji H, Ros PR. Pneumatosis intestinalis and portomesenteric venous gas in intestinal ischemia: correlation of CT findings with severity of ischemia and clinical outcome. *AJR Am J Roentgenol.* 2001; **177**(6): 1319-23. [PMID: 11717075]; [DOI: 10.2214/ajr.177.6.1171319]
- Wayne E, Ough M, Wu A, Liao J, Andresen KJ, Kuehn D, Wilkinson N. Management algorithm for pneumatosis intestinalis and portal venous gas: treatment and outcome of 88 consecutive cases. *J Gastrointest Surg.* 2010; **14**(3): 437-48. [PMID: 20077158]; [DOI: 10.1007/s11605-009-1143-9]
- Ochiai T, Igri K, Kumagai Y, Iida M, Yamazaki S. Education and imaging. Gastrointestinal: massive portal venous gas and pneumatosis intestinalis. *J Gastroenterol Hepatol.* 2010; **25**(6): 1178. [PMID: 20594238]; [DOI: 10.1111/j.1440-1746.2010.06361.x]
- Lee CH, Chang YC. Mesenteric and hepatic portal venous gas in a woman with pelvic inflammatory disease. *J Emerg Med.* 2012; **43**(1): e57-8. [PMID: 20888165]; [DOI: 10.1016/j.jemermed.2010.07.022]
- Wiesner W, Morteale KJ, Glickman JN, Ji H, Ros PR. Portal-venous gas unrelated to mesenteric ischemia. *Eur Radiol.* 2002; **12**(6): 1432-7. [PMID: 12042950]; [DOI: 10.1007/s00330-001-1159-3]
- Jinno A, Hirotsawa T, Shimizu T. Hepatic portal venous gas after diving. *BMJ Case Rep.* 2018; **2018**. [PMID: 29330281]; [DOI: 10.1136/bcr-2017-223844]
- Heye T, Bernhard M, Mehrabi A, Kauczor HU, Hosch W. Portomesenteric venous gas: is gas distribution linked to etiology and outcome? *Eur J Radiol.* 2012; **81**(12): 3862-9. [PMID: 22901713]; [DOI: 10.1016/j.ejrad.2012.07.017]
- Wakisaka M, Mori H, Kiyosue H, Kamegawa T, Uragami S. Septic thrombosis of the portal vein due to peripancreatic ligamental abscess. *Eur Radiol.* 1999; **9**(1): 90-2. [PMID: 9933387]; [DOI: 10.1007/s003300050634]
- Al-Jundi W, Shebl A. Emphysematous gastritis: case report and literature review. *Int J Surg.* 2008; **6**(6): e63-6. [PMID: 17446149]; [DOI: 10.1016/j.ijssu.2007.02.007]
- Ma AS, Ewing I, Murray CD, Hamilton MI. Hepatic portal venous gas and portal venous thrombosis following colonoscopy in a patient with terminal ileal Crohn's disease. *BMJ Case Rep.* 2015; **2015**. [PMID: 25939971]; [DOI: 10.1136/bcr-2014-206854]
- Arai M, Kim S, Ishii H, Hagiwara J, Takiguchi T, Ishiki Y, Yokota H. Delayed development of portal vein thrombosis in a patient initially detected with portal venous gas and pneumatosis intestinalis: a case report. *Acute Med Surg.* 2019; **6**(4): 419-22. [PMID: 31592325]; [DOI: 10.1002/ams2.448]
- Wolfe JN, Evans WA. Gas in the portal veins of the liver in infants; a roentgenographic demonstration with postmortem anatomical correlation. *Am J Roentgenol Radium Ther Nucl Med.* 1955; **74**(3): 486-8. [PMID: 13249015]
- Susman N, Senturia HR. Gas embolization of the portal venous system. *Am J Roentgenol Radium Ther Nucl Med.* 1960; **83**: 847-50. [PMID: 13835795]
- Earls JP, Dachman AH, Colon E, Garrett MG, Molloy M. Prevalence and duration of postoperative pneumoperitoneum: sensitivity of CT vs left lateral decubitus radiography. *AJR Am J Roentgenol.* 1993; **161**(4): 781-5. [PMID: 8372757]; [DOI: 10.2214/ajr.161.4.8372757]
- Sebastià C, Quiroga S, Espin E, Boye R, Alvarez-Castells A, Armengol M. Portomesenteric vein gas: pathologic mechanisms, CT findings, and prognosis. *Radiographics.* 2000; **20**(5): 1213-24; discussion 24-6. [PMID: 10992012]; [DOI: 10.1148/radiographics.20.5.g00se011213]
- Kirsch M, Bozdech J, Gardner DA. Hepatic portal venous gas: an unusual presentation of Crohn's disease. *Am J Gastroenterol.* 1990; **85**(11): 1521-3. [PMID: 2239883]
- Bani-Hani KE, Heis HA. Iatrogenic gastric dilatation: a rare and transient cause of hepatic-portal venous gas. *Yonsei Med J.* 2008; **49**(4): 669-71. [PMID: 18729313]; [DOI: 10.3349/ymj.2008.49.4.669]
- Barthet M, Membriani P, Bernard JP, Sahel J. Hepatic portal venous gas after endoscopic biliary sphincterotomy. *Gastrointest Endosc.* 1994; **40**(2 Pt 1): 261-3. [PMID: 8013847]; [DOI: 10.1016/s0016-

- 5107(94)70193-8]
25. Huycke A, Moeller DD. Hepatic portal venous gas after colonoscopy in granulomatous colitis. *Am J Gastroenterol.* 1985; **80(8)**: 637-8. [PMID: 2862790]
 26. Simmons TC. Hepatic portal venous gas due to endoscopic sphincterotomy. *Am J Gastroenterol.* 1988; **83(3)**: 326-8. [PMID: 3344739]
 27. Zielke A, Hasse C, Nies C, Rothmund M. Hepatic-portal venous gas in acute colonic diverticulitis. *Surg Endosc.* 1998; **12(3)**: 278-80. [PMID: 9502713]; [DOI: 10.1007/s004649900652]
 28. Yoshida M, Mitsuo M, Kutsumi H, Fujita T, Soga T, Nishimura K, Kawabata K, Kadotani Y, Kinoshita Y, Chiba T, Kuroiwa N, Fujimoto S. A successfully treated case of multiple liver abscesses accompanied by portal venous gas. *Am J Gastroenterol.* 1996; **91(11)**: 2423-5. [PMID: 8931431]
 29. Draghetti MJ, Salvo AF. Gas in the mesenteric veins as a nonfatal complication of diverticulitis: report of a case. *Dis Colon Rectum.* 1999; **42(11)**: 1497-8. [PMID: 10566541]; [DOI: 10.1007/bf02235054]
 30. Li Z, Su Y, Wang X, Yan H, Sun M, Shu Z. Hepatic portal venous gas associated with colon cancer: A case report and literature review. *Medicine (Baltimore).* 2017; **96(50)**: e9352. [PMID: 29390409]; [DOI: 10.1097/MD.00000000000009352]
 31. Alqahtani S, Coffin CS, Burak K, Chen F, MacGregor J, Beck P. Hepatic portal venous gas: a report of two cases and a review of the epidemiology, pathogenesis, diagnosis and approach to management. *Can J Gastroenterol.* 2007; **21(5)**: 309-13. [PMID: 17505567]; [DOI: 10.1155/2007/934908]
 32. Mehta S, Desai GS, Shah S, Mehta H, Phadke A. Hepatic Portal Venous Gas: An Ill Omen or a Misleading Sign. *Surg J (N Y).* 2020; **6(1)**: e37-e41. [PMID: 32133413]; [DOI: 10.1055/s-0040-1702919]
 33. Jinno A, Hirose T, Shimizu T. Hepatic venous gas after diving. *BMJ Case Rep.* 2018; **2018**: bcr2017223844. [PMID: 29330281]; [DOI: 10.1136/bcr-2017-223844]
 34. Schindera ST, Triller J, Vock P, Hoppe H. Detection of hepatic portal venous gas: its clinical impact and outcome. *Emerg Radiol.* 2006; **12(4)**: 164-70. [PMID: 16547739]; [DOI: 10.1007/s10140-006-0467-y]
 35. Hussain A, Mahmood H, El-Hasani S. Portal vein gas in emergency surgery. *World J Emerg Surg.* 2008; **3**: 21. [PMID: 18637169]; [DOI: 10.1186/1749-7922-3-21]
 36. Ferrada P, Callcut R, Bauza G, O'Bosky KR, Luo-Owen X, Mansfield NJ, Inaba K, Pasley J, Bugaev N, Pereira B, Moore FO, Han J, Pasley A, DuBose J, Committee AM-iT. Pneumatosis Intestinalis Predictive Evaluation Study: A multicenter epidemiologic study of the American Association for the Surgery of Trauma. *J Trauma Acute Care Surg.* 2017; **82(3)**: 451-60. [PMID: 28225738]; [DOI: 10.1097/TA.0000000000001360]