

Journal of Gastroenterology and Hepatology Research

Online Submissions: <http://www.ghrnet.org/index./joghr/>
doi: 10.17554/j.issn.2224-3992.2021.10.1019

Journal of GHR 2021 August 21; **10(4)**: 3568-3570
ISSN 2224-3992 (print) ISSN 2224-6509 (online)

CASE REPORT

Pleuroperitoneal Shunt in a Patient With Hepatic Hydrothorax

Tomoki Nishida¹, Yuto Igarashi², Yuma Suno², Takaaki Murata², Katsunori Miyake², Naoko Isogai², Rai Shimoyama², Ryuta Fukai¹, Hiroyuki Kashiwagi², Jun Kawachi²

1 Department of General Thoracic Surgery, Shonan Kamakura General Hospital, Japan;

2 Department of General Surgery, Shonan Kamakura General Hospital, Japan.

Conflict-of-interest statement: The authors declare that there is no conflict of interest regarding the publication of this paper.

Open-Access: This article is an open-access article which was selected by an in-house editor and fully peer-reviewed by external reviewers. It is distributed in accordance with the Creative Commons Attribution Non Commercial (CC BY-NC 4.0) license, which permits others to distribute, remix, adapt, build upon this work non-commercially, and license their derivative works on different terms, provided the original work is properly cited and the use is non-commercial. See: <http://creativecommons.org/licenses/by-nc/4.0/>

Correspondence to: Tomoki Nishida, 1370-1 Okamoto, Kamakura, Kanagawa Prefecture, Japan.

Email: tmk-n.322@nifty.com

Telephone: +81-467-46-1717

Fax: +81-467-45-0190

Received: June 11, 2021

Revised: July 12, 2021

Accepted: July 15, 2021

Published online: August 21, 2021

ABSTRACT

Hepatic hydrothorax is a term that describes a pleural effusion induced by cirrhosis; these effusions are often resistant to standard medical therapy. The usefulness of pleuroperitoneal shunts for intractable pleural effusions has been reported, but there are few reports describing the use of this shunt for hepatic hydrothorax. We report our successful experience with a pleuroperitoneal shunt for palliative treatment of hepatic hydrothorax in a patient with cirrhosis. Our patient had class B liver cirrhosis per the Child-Pugh classification system. Two months prior to the procedure, she had undergone percutaneous coronary intervention for unstable angina. We selected a pleuroperitoneal shunt for noninvasive, palliative treatment of an intractable pleural effusion in this high-risk patient.

After surgery, the pleural effusion was well controlled and our patient was able to live her daily life at home for 6 months before she died of complications related to shunt occlusion. The pleuroperitoneal shunt should be considered a useful treatment option for hepatic hydrothorax, especially in high-risk patients.

Key words: Peritoneal absorption; Hydrothorax; Liver cirrhosis

© 2021 The Authors. Published by ACT Publishing Group Ltd. All rights reserved.

Nishida T, Igarashi Y, Suno Y, Murata T, Miyake K, Isogai N, Shimoyama R, Fukai R, Kashiwagi H, Kawachi J. Pleuroperitoneal Shunt in a Patient With Hepatic Hydrothorax. *Journal of Gastroenterology and Hepatology Research* 2021; **10(4)**: 3568-3570 Available from: URL: <http://www.ghrnet.org/index.php/joghr/article/view/3167>

INTRODUCTION

Hepatic hydrothorax sometimes occurs in patients with liver cirrhosis. This specific type of pleural effusion reduces respiratory function, decreases quality of life, and often leads to hospitalization. Some authors describe pleuroperitoneal shunts as useful for intractable pleural effusions, but these reports are mainly describing noninvasive, palliative treatment for malignant effusions^[1-3]. Currently, pleuroperitoneal shunting is not a standard therapy for hepatic hydrothorax, and there are few reports describing this procedure for this indication.

We report herein our successful experience with a high-risk patient who had an intractable hepatic hydrothorax that was controlled by implanting a pleuroperitoneal shunt.

CASE REPORT

A 71-year-old woman came to our hospital with the chief complaint of dyspnea. Chest radiography revealed a right-sided pleural effusion that was not present on an x-ray performed 5 months prior (Figure 1A, 1B). Her medical history included hepatitis B virus infection, liver cirrhosis, and insulin-dependent diabetes mellitus. Her surgical history was significant for a laparotomy performed for esophageal varices. Her liver cirrhosis was class B under the Child-Pugh classification system, based on her physical findings and laboratory

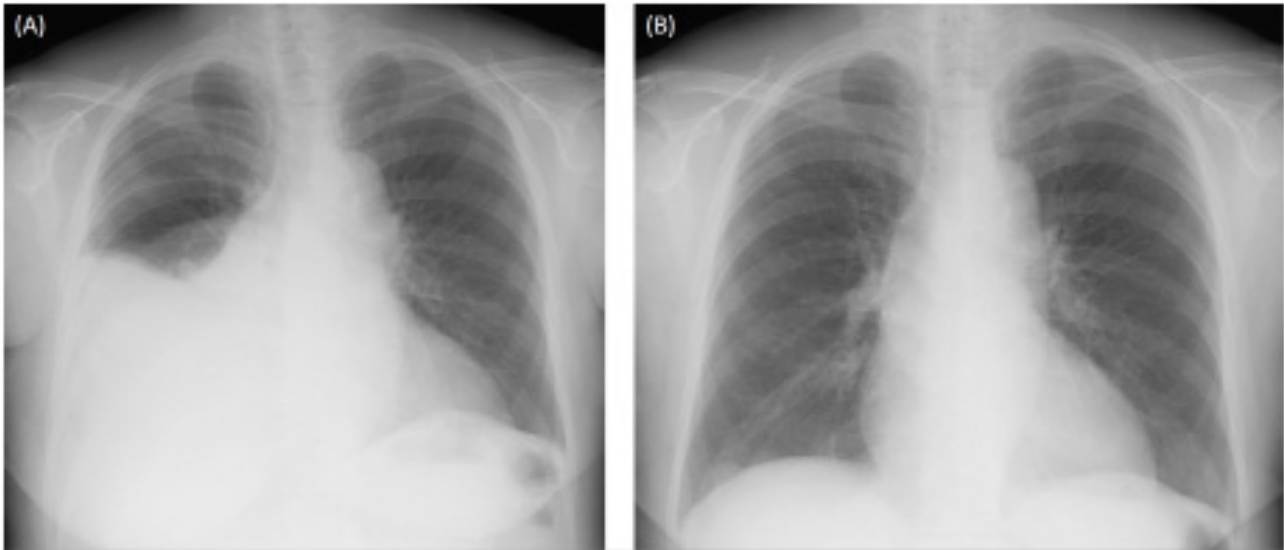


Figure 1 A: Chest radiography showing a right-sided pleural effusion. B: Chest radiography showing no evidence of a pleural effusion 5 months before admission.

results. The pleural effusion was diagnosed as a hepatic hydrothorax, and we started diuretic therapy. On the 15th hospital day, the patient experienced unstable angina and underwent percutaneous coronary intervention; dual antiplatelet therapy was added to her regimen. After that procedure, her pleural effusion began to gradually increase in size (Figure 2), and she became bedridden. Twice-weekly thoracentesis was needed to improve her dyspnea, so we decided to place a pleuroperitoneal shunt (Denver®; Mihama Medical, Inc; Tokyo, Japan).

Shunt placement was performed under general anesthesia on the 66th hospital day. We selected general anesthesia because of the possibility of intraperitoneal adhesions from her recent laparotomy. A small incision was made over the sixth intercostal space at the anterior axillary line. A guidewire was passed into the pleural space using Seldinger technique under fluoroscopy. An adjacent subcutaneous pocket was created over the anterolateral costal margin to accept the pumping chamber and provide a stable base for shunt compression. Next, a small skin incision was made over an area of her abdomen that was not involved in her prior surgery; there were no adhesions encountered. We created a pursestring suture in the peritoneum and inserted the catheter into the peritoneal free space under fluoroscopic guidance. The operative time was 40 minutes, and there was minimal blood loss.

After surgery, the shunt was compressed for about 5 minutes, 3 times per day. Follow-up chest radiography on the third postoperative day showed an expanded right upper lung (Figure 3). Her respiratory symptoms improved, and she was able to walk around the hospital. She was discharged on the 23rd postoperative day without a requirement for supplemental oxygen.

We followed her closely as an outpatient and were pleased that she was able to live her daily life at home for 6 months. At that point, she experienced a shunt occlusion and fluid control became difficult. She died of this complication on the 222nd postoperative day.

DISCUSSION

A pleuroperitoneal shunt is a silicone medical device consisting of a pump chamber, which can be manually compressed, and 2 catheters; the device transfers fluid from the pleural cavity to the peritoneal cavity. The pump is able to overcome the pressure gradient between

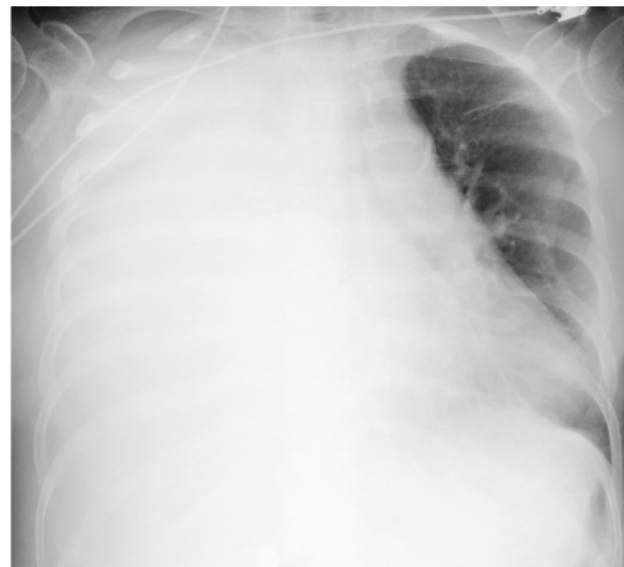

Figure 2 Chest radiography showing a massive right-sided pleural effusion.

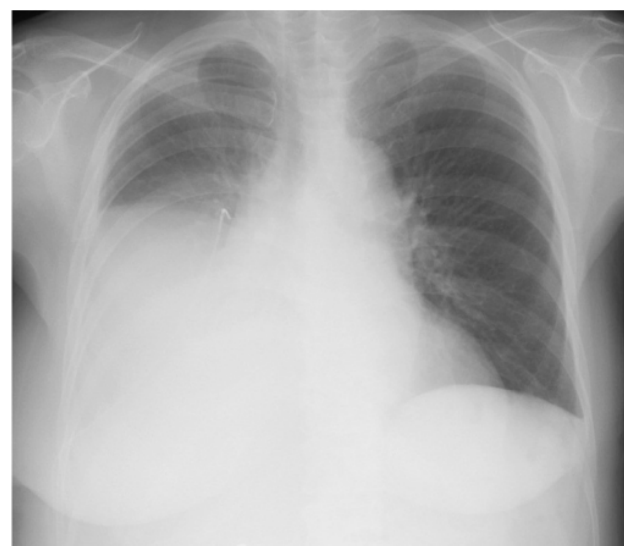


Figure 3 Chest radiography showing an improved right-sided pleural effusion after surgery.

the pleural and peritoneal cavities by compressing a bulb that houses a one-way valve, forcing flow from the chest to the abdomen. These shunts are reportedly useful for controlling malignant pleural effusions^[1-3]. In many cases, the procedure is performed in the operating room using local anesthesia with intravenous sedation. These shunts allow patients to improve their mobility and respiration status, and there are few complications associated with their placement. Alex *et al* report the use of shunts in 36 patients, for both malignant and benign pleural effusions. They reported perioperative complications including wound seroma and minor liver lacerations; however, they improved their technique and were subsequently able to avoid minor complications^[4].

Long-term use of shunts can sometimes result in shunt occlusion or infection, and the use of shunts for malignant effusions has the potential for causing tumor seeding in the peritoneal cavity^[5]. Contraindications to shunting include an inability to compress the pump, pleural infection, multiloculated effusions, an obliterated peritoneal space, and severe limitations unrelated to the pleural effusion^[6].

Habuka *et al* report the usefulness of this shunt for patients with benign pleural effusions undergoing maintenance hemodialysis^[7]. Because hepatic hydrothorax is an intractable benign pleural effusion, pleuroperitoneal shunting may be an effective treatment. Hepatic hydrothorax is defined as a pleural effusion that develops in a patient with cirrhosis; it is an infrequent complication of portal hypertension, with an estimated prevalence of 5% to 10%. In about 85% of cases, the pleural effusion associated with cirrhosis develops on the right side^[8-10]. The most plausible explanation is that the effusion is a result of direct passage of ascitic fluid into the pleural cavity through a defect in the diaphragm, due to the increased abdominal pressure in patients with cirrhosis and the negative pressure within the pleural space. Another hypothesis postulates that hypoalbuminemia and the subsequent decreased colloid osmotic pressure increase the pressure in the azygos venous system, leading to leakage of plasma into the pleural cavity and transdiaphragmatic migration of peritoneal fluid into the pleural space via lymphatic channels^[11-12]. Hepatic hydrothorax causes respiratory symptoms such as shortness of breath, and it results in hypoxemia and sometimes causes empyema due to bacterial infection. Patients with this condition can require prolonged hospitalization.

The therapy most commonly used for patients with hepatic hydrothorax is sodium restriction and administration of diuretics. When medical therapy fails, the only definitive treatment is liver transplantation. There are alternative therapies, such as therapeutic thoracentesis, tube thoracostomy with pleurodesis, transjugular intrahepatic portosystemic shunt (TIPS) placement, and thoracoscopic repair of diaphragmatic defects. Frequent thoracentesis or tube thoracostomy is associated with protein loss and infection, and pleurodesis has a reported failure rate of at least 20% to 30%^[8]. Although TIPS is a nonsurgical procedure that decompress the portal system, it cannot directly treat diaphragmatic defects. Surgical repair of diaphragmatic defects may be effective^[13], but it is often difficult to detect these defects and the procedure requires general anesthesia. Because the morbidity and mortality is high in these extremely ill patients, one must be careful with invasive techniques such as surgical repair. In addition, recurrent pleural effusions have been observed in patients who undergo surgical repair^[14]. We therefore do not consider surgical repair to be first-line therapy for patients with hepatic hydrothorax. Pleuroperitoneal shunting is a noninvasive option for palliative therapy.

CONCLUSION

In this report, we describe successful palliative treatment of hepatic hydrothorax using a pleuroperitoneal shunt in a patient with liver cirrhosis. Although the patient was considered to be high-risk for surgery, there were no postoperative complications. The pleuroperitoneal shunt improved the patient's quality of life for 6 months, until she ultimately experienced shunt occlusion. This procedure should be considered a useful treatment option for patients with hepatic hydrothorax.

REFERENCES

- 1 Lee KA, Harvey JC, Reich H, Beattie EJ. Management of malignant pleural effusions with pleuroperitoneal shunting. *J Am Coll Surg* 1994; **178**: 586-588. [PMID: 7514936]
- 2 Weese JL, Schouten JT. Pleural peritoneal shunts for the treatment of malignant pleural effusions. *Surg Gynecol Obstet* 1982; **154**: 391-392. [PMID: 7064076]
- 3 Genc O, Petrou M, Ladas G, Goldstraw P. The long-term morbidity of pleuroperitoneal shunts in the management of recurrent malignant effusions. *Eur J Cardiothorac Surg* 2000; **18**: 143-146. [PMID: 10925221]; [DOI: 10.1016/s1010-7940(00)00422-x]
- 4 Little AG, Kadowaki MH, Ferguson MK, Staszek VM, Skinner DB. Pleuro-peritoneal shunting: alternative therapy for pleural effusions. *Ann Surg* 1988; **208**: 443-450. [PMID: 317832]; [DOI: 10.1097/00000658-198810000-00006]
- 5 Baeyens I, Berrisford RG. Pleuroperitoneal shunts and tumor seeding. *J Thorac Cardiovasc Surg* 2001; **121**: 813. [PMID: 11279426]; [DOI: 10.1067/mtc.2001.111377]
- 6 Ponn RB, Blancaflor J, D'Agostino RS, Kiernan ME, Toole AL, Stern H. Pleuroperitoneal shunting for intractable pleural effusions. *Ann Thorac Surg* 1991; **51**: 605-609. [PMID: 1707256]; [DOI: 10.1016/0003-4975(91)90319-1]
- 7 Habuka M, Ito T, Yoshizawa Y, Matsuo K, Murakami S, Kondo D, Kanazawa H, Narita I. Usefulness of a pleuroperitoneal shunt for treatment of refractory pleural effusion in a patient receiving maintenance hemodialysis. *CEN Case Rep* 2018; **7**: 189-194. [PMID: 29572611]; [DOI: 10.1007/s13730-018-0323-4]
- 8 Lv Y, Han G, Fan D. Hepatic hydrothorax. *Ann Hepatol* 2018; **17**: 33-46. [PMID: 29311408]; [DOI: 10.5604/01.3001.0010.7533]
- 9 Lazaridis KN, Frank JW, Krowka MJ, Kamath PS. Hepatic hydrothorax: pathogenesis, diagnosis, and management. *Am J Med* 1999; **107**: 262-267. [PMID: 10492320]; [DOI: 10.1016/s0002-9343(99)00217-x]
- 10 Lieberman FL, Hidemura R, Peters RL, Reynolds TB. Pathogenesis and treatment of hydrothorax complicating cirrhosis with ascites. *Ann Intern Med* 1966; **64**: 341-351. [PMID: 5902279]; [DOI: 10.7326/0003-4819-64-2-341]
- 11 Norvell JP, Spivey JR. Hepatic hydrothorax. *Clin Liver Dis* 2014; **18**: 439-449. [PMID: 24679505]; [DOI: 10.1016/j.cld.2014.01.005]
- 12 Kiafar C, Gilani N. Hepatic hydrothorax: current concepts of pathophysiology and treatment options. *Ann Hepatol* 2008; **7**: 313-320. [PMID: 19034230]
- 13 Omura A, Kanzaki R, Ike A, Kanazawa G, Kanou T, Ose N, Funaki S, Minami M, Shintani Y. Thoracoscopic diaphragm repair using abdominal insufflation in a patient with hepatic hydrothorax. *Gen Thorac Cardiovasc Surg* 2020; **68**: 302-305. [PMID: 30927226]; [DOI: 10.1007/s11748-019-01117-3]
- 14 Nakamura Y, Iwazaki M, Yasui N, Seki H, Matsumoto H, Masuda R, Nishiumi N, Shimada A. Diaphragmatic repair of hepatic hydrothorax with VATS after abdominal insufflation with CO₂. *Asian J Endosc Surg* 2012; **5**: 141-144. [PMID: 22823172]; [DOI: 10.1111/j.1758-5910.2012.00133.x]