

Safety and Efficacy of Endobiliary Radio Frequency Ablation in Hilar Cholangiocarcinoma

Priya Nair¹, Harshavardhan B Rao¹, Anoop K Koshy¹, Krishnapriya S¹, Rama P Venu¹

¹ Department of Gastroenterology, Amrita Institute of Medical Sciences, Ponekkara, Kochi 682041, Kerala, India.

Conflict-of-interest statement: The authors declare that there is no conflict of interest regarding the publication of this paper.

Open-Access: This article is an open-access article which was selected by an in-house editor and fully peer-reviewed by external reviewers. It is distributed in accordance with the Creative Commons Attribution Non Commercial (CC BY-NC 4.0) license, which permits others to distribute, remix, adapt, build upon this work non-commercially, and license their derivative works on different terms, provided the original work is properly cited and the use is non-commercial. See: <http://creativecommons.org/licenses/by-nc/4.0/>

Correspondence to: Rama P Venu, Department of Gastroenterology, Amrita Institute of Medical Sciences, Ponekkara, Kochi 682041, Kerala, India.
Email: ramapvenu@yahoo.com

Received: October 26, 2021

Revised: December 10, 2021

Accepted: December 19, 2021

Published online: February 21, 2022

ABSTRACT

INTRODUCTION: Hilar Cholangiocarcinoma (hCCA) is often incurable at diagnosis and palliative treatment is the only option for most patients. Endoscopic placement of biliary stents to facilitate bile flow forms the cornerstone of palliative therapy. Tumour ingrowth with blockage of stent continues to be a major problem. Endo- Biliary Radio Frequency Ablation (EBRA) has emerged as an adjunct to existing treatment options by potentially prolonging stent patency and survival. However the safety and efficacy of EBRA is still an area that merits further study.

METHODS: The study was conducted at a high volume tertiary care centre from January 2017 to December 2019 where consecutive patients of hCCA requiring endoscopic palliation were included. EBRA was performed using the ELRA™ (Endo Luminal Radiofrequency Ablation) electrode from Taewoong Medical (South Korea) during the ERC, followed by the placement of a Self-expanding metallic stent (SEMS) as per protocol (Group 1). Patients who did not

consent to the EBRA were treated with SEMS alone and served as controls (Group 2). The primary outcome was overall survival; while secondary outcomes studied were need for repeat interventions and procedure related adverse events.

RESULTS: A total of 49 patients were included (mean age 66.65 ± 12.96 years, M:F = 0.8). 22 patients underwent EBRA (Group 1); and 27 patients underwent SEMS placement alone (Group 2). The baseline characteristics (age, gender, bismuth staging of hCCA and post drainage palliative chemotherapy) were similar in both groups. The median survival for group 1 was 282 days and for group 2 was 180 days ($p = 0.008$). Post procedure cholangitis was noted in 7/22 patients (31.8%) of patients in Group 1 and 8/27 patients (30.7%) of patients in group 2. Four patients (17.3%) in group 1 required re-stenting within 6 months while 8 patients (30.7%) required re-stenting in group 2.

CONCLUSIONS: Patients who underwent EBRA were found to have a significant survival advantage as compared to standard treatment options. EBRA was found to be technically feasible, safe and can be a useful adjunct to endoscopic palliation in patients with hCCA.

Key words: Radio frequency ablation; cholangiocarcinoma; Palliation; Biliary stricture; Endoscopy

Core tip: Palliative endoscopic biliary drainage is the mainstay of treatment in advanced hilar cholangiocarcinoma. Endoscopic biliary RFA is a useful adjunct in therapy by potentially increasing period of stent patency and overall survival. This was a single centre retrospective cohort study involving 49 patients, of which 22 patients were treated with EBRA followed by biliary stenting and their outcomes were compared with 27 patients who underwent biliary stenting alone. EBRA was found to be technically feasible, safe and provided a significant survival benefit as compared to biliary stent placement alone.

© 2022 The Authors. Published by ACT Publishing Group Ltd. All rights reserved.

Priya N, Harshavardhan BR, Anoop KK, Krishnapriya S, Rama PV. Safety and Efficacy of Endobiliary Radio Frequency Ablation in Hilar Cholangiocarcinoma. *Journal of Gastroenterology and Hepatology Research* 2022; **11**(1): 3658-3664 Available from: URL: <http://www.ghrnet.org/index.php/joghr/article/view/3195>

INTRODUCTION

Cholangiocarcinoma (CCA) is an epithelial cell malignancy that can arise from any part of the biliary tract. It represents the second most frequent type of primary liver cancer and approximately 3% of all gastro-intestinal neoplasias^[1]. The tumour is further classified into three subgroups according to its anatomical location: intrahepatic (iCCA), hilar (hCCA) and distal CCA (dCCA). Although these subgroups have a common ontology, their behaviour, natural history and treatment options are vastly different. This has been shown to have a significant impact on overall outcome^[2]. The most common subtype is hCCA, which accounts for 60-70% of all cases of CCA^[3]. Within Southeast Asia itself, its annual incidence varies from 0.1/100,000 to 71.3/100,000^[4]. Compared to the dCCA, hCCA usually presents at an advanced clinical stage and carries a very poor prognosis with a reported 5-year survival rate of less than 10%^[5,6]. Moreover, most patients present at an advanced stage and/or have significant comorbidities that make them poor surgical candidates. Palliative treatment remains the only option for a majority of patients and survival of these patients is poor even with chemotherapy.

Biliary drainage procedures - endoscopic or percutaneous drains, form the cornerstone of palliative treatment options in these patients. In addition to improving the quality of life in these patients, several studies have demonstrated that biliary drainage may improve immune function and nutritional status, at the same time reduce risk of cholangitis^[7,8]. Endoscopic biliary drainage is accomplished by Endoscopic retrograde cholangiography (ERC) with the placement of an endobiliary prosthesis. Most commonly, in the setting of malignant biliary strictures, a self-expanding metal stent (SEMS) is preferred owing to superior safety and longer duration of patency necessitating fewer interventions^[9,10]. However, delayed stent occlusion is common with SEMS and can be seen in 34.4% of patients at 1 year^[11]. Stent occlusion can be due to sludge deposition, tumour ingrowth, epithelial hyperplasia or biofilm formation^[6,12]. Among these, tumour ingrowth is particularly concerning as this may result in stent occlusion leading to recurrent cholangitis, re-intervention with the placement of additional stents, prolonged hospital stay and poor outcomes.

A variety of modalities have been explored to ablate tumour ingrowth and improve stent patency including, intraluminal brachytherapy (ILBT), radiofrequency ablation (RFA) and photodynamic therapy (PDT). With the introduction of RFA probes that can be passed through the scope, endoluminal biliary RFA (EBRA) has taken precedence and has shown good results in limited studies thus far. RFA is a technique by which thermal energy is applied directly to the tumour causing coagulative necrosis of tumour tissue thereby reducing tumour burden. EBRA prior to SEMS placement could potentially decrease the viability of the tumour tissue and thereby reduce tumour ingrowth of the stent. The original probe employed was the Habib EndoHBP probe (EMcision UK, London, United Kingdom). Since then, other types of probes have been developed including ELRA™ (Endo Luminal Radiofrequency Ablation) electrode from Taewoong Medical (South Korea). The safety and efficacy of this technique to prolong stent patency has been established in various reports in the past^[13]. As to whether EBRA provided a survival benefit in these patients is a matter of debate and needs further clarity.

MATERIALS AND METHODS

Study population and design

This was a retrospective cohort study where all patients with an established diagnosis of inoperable hCCA between January 2016 to

October 2017 were included in the study. Patients who had consented for EBRA were included into Group 1, while the remaining were included into group 2. Biliary drainage with the placement of an endobiliary prosthesis was performed in all the patients. Details of all the patients including demographics, bismuth staging of hCCA, clinical presentation, presence of lymph nodal involvement, portal vein thrombosis, metastasis, nature and site of stent placement, improvement in biliary obstruction post procedure, technical success of RFA and procedure related complications like cholangitis, pancreatitis and cholecystitis, need for repeat intervention and survival were recorded in pre-designed proformas.

Technical specifications of the procedure

All endoscopic procedures were performed under general anaesthesia by an experienced endoscopist. Choice of anaesthetic was left to the discretion of a dedicated anaesthetist present for all procedures. A standard adult ERC scope (Olympus TJF Q180V) with an outer diameter of 13.7 mm and channel diameter of 4.2 mm was used. All procedures were performed in a dedicated endoscopy suite under fluoroscopic guidance (Flexavision, Shimadzu). A satisfactory cholangiogram was done delineating the exact site and extent of the stricture.

In patients of Group 1, following an adequate sphincterotomy, an EBRA probe was passed over the wire, across the stricture. EBRA probe used was the ELRA™ electrode from Taewoong Medical in all the patients (Figure 1). The length of the probe is 18mm, diameter is 7 Fr, ablation depth is 4mm and it has multiple bipolar electrodes which provide linear ablation therefore no ground pad is needed. A VIVA combo™-generator was used with the probe and it was set to 2 minutes with a maximum temperature of 80°C and a power of 10 watts. All patients received a minimum of one session of RFA (2 minutes). If the entire length of the stricture was not covered by the 18mm probe, the probe was repositioned and multiple sessions of RFA (2 minutes each) were performed to ensure adequate ablation. As a part of protocol, a complete balloon sweeping of the ducts were performed after every RFA session to remove necrotic debris. This was followed by the placement of a self-expanding metal stent as per usual protocol. Technical success was defined as successful passage of the EBRA probe across the stricture, followed by the placement of a stent into the intended ductal system.

Patients of group 2 were treated only with the placement of stent following sphincterotomy. In all patients, bilateral stent placement was preferred over unilateral stent. However, in the patients where technical limitations like unfavourable anatomy of the proximal ducts and tight high grade strictures precluded bilateral stenting, a single stent was placed in the ductal system of choice as assessed prior to procedure based on ductal diameters and lack of lobar atrophy on cross-sectional imaging.

Follow-up protocol

All patients were followed up for complications, 30-day mortality and outcome. The primary outcome of the study was overall survival of the study population, while secondary outcomes studied were need for repeat interventions and post procedure complications.

Statistical Analysis

Statistical analysis was carried out using IBM SPSS software version 20.0. Comparison between two groups was done using independent 2-sample T test/Mann Whitney U test and three group comparison was done using ANOVA/Kruskal Wallis for parametric and non-parametric variables respectively. Categorical variables were analysed

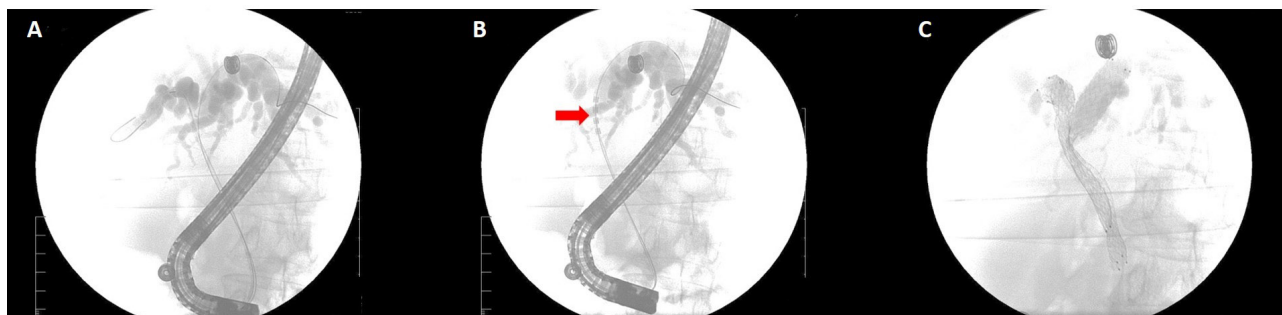


Figure 1 Cholangiogram showing A) Hilar stricture with Intrahepatic Bilateral radial dilatation B) RFA probe seen within the hilar stricture C) Fluoroscopic image showing Bilateral Self expanding metal stents.

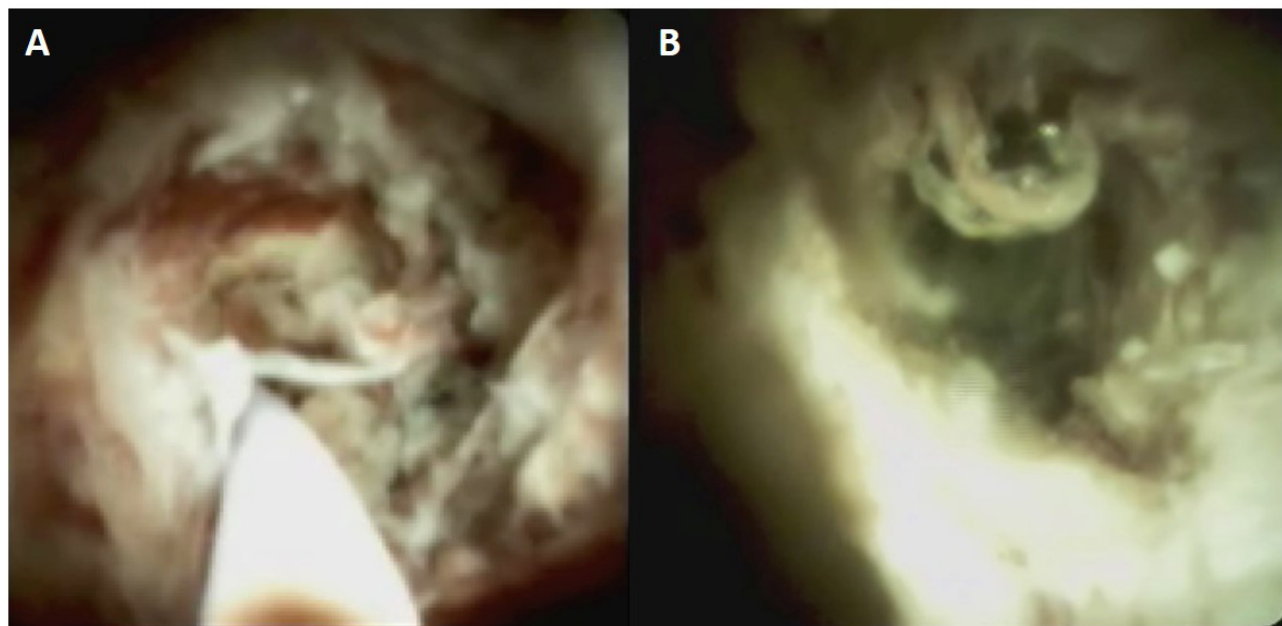


Figure 2 Cholangioscopic image of hCCA : Panel A - Prior to RFA, lumen occlusion, increased vascularity and tissue friability are seen; Panel B - Post RFA the lumen is widened and there is reduced vascularity and tissue friability.

using Chi-square test/Fisher's exact test for univariate analysis and multivariate analysis was then carried out using multiple logistic regression analysis. Kaplan Meir curves with log rank estimation for overall survival at 3 months and 6 months and for efficacy of RFA was carried out as a part of outcome analysis. A p value of less than 0.05 was considered significant.

RESULTS

Patient demographics

A total of 49 patients were included in the study. The baseline demographics of the patient population have been provided in Table 1. The mean age was 66.65 ± 12.96 years with a male to female ratio of 0.8. Bismuth type I/II CCA was noted in 6/49 patients (12.2%), type III a/b CCA in 13/49 patients (26.5%), and type IV in 30/49 patients (61.2%). The most common presentation was jaundice (46/49, 93.9%), followed by pruritus (42/49, 85.7%). Fever at presentation was noted in 7/49 patients (14.3%). Disease was predominantly left sided (21/49, 43.8%) with metastasis noted in 22.4%(11/49) and portal vein thrombosis (PVT) noted in 42.9% (21/49). Palliative chemotherapy was administered in 6/49 patients (12.2%).

A total of 22 patients underwent EBRA and were included into Group 1 (mean age 68.45 ± 11.71 years, M:F = 0.91); and 27 patients underwent biliary stent placement alone and were included into Group 2 (mean age 65.18 ± 13.95 years, M:F = 0.73). Bismuth I/II disease

were noted in 4/22 patients(18.1%) in group 1 and 2/27 patients(7.4%) in group 2; while Bismuth III/IV disease were noted in 18/22 patients (81.8) in group 1 and 25/27 patients (92.5%) in group 2 (p value - 0.549). The baseline laboratory values were similar in both groups. Metastasis was noted in 8/22 patients (36.4%) patients in group 1 and 3/27 patients(11.1%) in group 2 (p value - 0.035). Metastasis was noted in the liver, lungs and peritoneum. Lymph node involvement was noted in 9/22 patients (40.9%) patients in group 1 as compared to 3/27 patients (11.1%) patients in group 2 (p value - 0.018). The presence of PVT thrombosis was similar in both groups (10/22 patients(45.5%) in group 1 and 11/27 patients (40.7%) in group 2). Three patients (3/22, 13.6%) in group 1 and three patients in group 2 (3/27, 11.1%) were given palliative chemotherapy ($p = 0.789$).

Safety of EBRA in the management of hCCA

Biliary drainage was achieved by ERC in all patients in group one and 21 (77%) patients in group 2 with the remaining 6(33%) patients undergoing Percutaneous Transhepatic Biliary Drainage (PTBD) with stent placement. All patients who underwent ERCP underwent papillotomy following which EBRA was performed prior to stenting. The cholangiograms done immediately after EBRA did not show any significant difference. Change in ductal diameters post stenting were also found to be similar between the two groups. In the total patient cohort, 40.8% (20/49) patients had unilateral stent placement while 29/49 patients (59.2%) had bilateral stent placement.

Table 1 Total and group demographics.

Variables	Overall (n=49)	Group 1 (n=22)	Group 2 (n=27)	P value
Age	66.65±12.96	68.45±11.71	65.18±13.95	0.38
Gender				
Male	22(44.89)	11(50)	12(44.4)	0.698
Female	27(55.10)	11(50)	15(55.6)	
Clinical presentation				
Jaundice	46(93.9)	20(90.9)	26(96.3)	0.581
Fever	7(14.3)	3(13.6)	4(14.8)	1
Pruritus	42(85.7)	19(86.4)	23(85.2)	1
Bismuth/Stage				
I	2(4.1)	2(9.1)	0(0)	
II	4(8.2)	2(9.1)	2(7.4)	0.549
IIIa	4(8.2)	2(9.1)	2(7.4)	
IIIb	9(18.4)	3(13.6)	6(22.2)	
IV	30(61.2)	13(59.1)	17(63)	
Metastasis	11(22.4)	8(36.4)	3(11.1)	0.035
Lymph nodes	12(24.5)	9(40.9)	3(11.1)	0.016
PVT	21(42.9)	10(45.5)	11(40.7)	0.74
ERCP				
Ductal involvement				
Right duct	15(31.3)	9(42.9)	6(22.2)	0.07
Left duct	21(43.8)	10(47.6)	11(40.7)	
Stent therapy				
Unilateral	20(40.8)	9(40.9)	11(40.7)	0.99
Bilateral	29(59.2)	13(59.1)	16(59.3)	
Chemotherapy	6(12.2)	3(13.6)	3(11.1)	0.789
Post procedure Cholangitis	15(30.6)	7(31.8)	8(29.6)	0.869
30 day Mortality	7(14.2)	3(42.8)	4(57.1)	0.9
Median Survival (days)	236	282	180	0.008

Overall, 15/49 patients (30.6%) had post procedure complications. The only complication noted in this study was cholangitis. Rate of cholangitis was 7/22 patients(31.8%) in Group 1 as compared to 8/27 patients (29.6%) in group 2 ($p = 0.869$) None of our patients had post procedure pancreatitis, bleeding or perforation. There was no procedure related mortality. Causes of 30 day mortality in this study include cardiac event ($n = 1$), sepsis with multiorgan dysfunction ($n = 3$) and pulmonary metastasis related complications ($n = 1$).

Need for Re-intervention

Re-intervention was required due to cholangitis secondary to stent blockage. Overall, 15/49 patients (30.6%) required re-intervention with repeated placement of biliary stents. A total of 4/22 patients(18.2%) required re-intervention within 6 months in group 1 as compared to 6/27 patients (22.2%) in group 2 (p value 0.577). The mean delta bilirubin levels post procedure was 48.4% in group 1 as compared to 28.6% in group 2 (p value 1.32). The median intervention free days was 58 days in group 1 as compared to 60 days in group 2.

Efficacy of EBRA in the management of hCCA

The overall survival of the patient cohort during the study period was 236 days. The 30-day mortality was 13% (3/22) in group 1 and 7.7% (2/27) in group 2 (p value 0.133). More importantly, patients in group 1 had a significantly longer median survival (282 days) as compared to patients in group 2 (180 days) (p value 0.008). The only other factor that showed an independent association with survival was

bilateral biliary stenting as compared to unilateral stent placement with a median survival of 492 days and 124 days respectively ($p = 0.025$). The median survival in patients with metastasis was 178 days compared to 414 days in patients without metastasis ($p = 0.535$) and median survival of patients who underwent palliative chemotherapy was 244 days as compared to 378 days in patients who did not get chemotherapy ($p = 0.710$).

DISCUSSION

CCA is classified as a rare cancer, but its incidence (0.3-6 per 100,000 inhabitants per year^[2]) and mortality (1-6 per 100,000 inhabitants per year, globally^[14], not taking into account specific regions with incidence > 6 per 100,000 habitants such as South Korea, China and Thailand) have been increasing in the past few decades worldwide, representing a global health problem^[15]. Moreover, CCA has a dismal prognosis owing to its insidious onset and late stage at presentation (Seer 18 registry data shows the 5 year survival rate for intrahepatic biliary malignancies is as low as 17.5%).

Treatment options for CCA include surgical resection with a curative intent or biliary drainage with or without palliative chemotherapy^[15]. A majority of patients require biliary drainage which can be done endoscopically or percutaneously^[2]. Endoscopic drainage involves ERCP with placement of biliary endoprosthesis, which can be plastic or metal (SEMS). The major long term complication of this procedure is stent occlusion leading to jaundice and cholangitis^[16]. The mechanisms for stent blockage include sludge deposition, tu-

mour ingrowth, epithelial hyperplasia, biofilm formation and formation of granulation tissue^[12,17,18].

EBRA is a modality that has been shown to improve stent patency in patients with malignant biliary strictures^[18]. There are two EBRA probes commercially available - The Habib™ endoprobe and the ELRA™ electrode from Taewoong Medical. A recent comprehensive review of EBRA^[18] studied 330 patients from 12 studies, of which all studies except one were treated with the Habib™ endoprobe. The prospective study by Laleman *et al*^[19], evaluated the feasibility, safety and stent patency of the ELRA™ probe in 18 patients with dCCA (9), hCCA (11) and pancreatic carcinoma (7). Overall, the procedure was feasible in all patients, with complications being pancreatitis in two patients and cholangitis in 4 patients. The median stent patency was 110 days (16-374 days).

In our study, all patients in the intervention group were treated using the ELRA™ probe.

The only complication noted in our study was cholangitis (31.8%) with no significant difference between the two study groups. This finding was in line with other studies^[20,21]. The cause of cholangitis is multifactorial - procedural introduction of enteric bacteria, incomplete drainage of obstructed ducts, stent blockage and poor nutritional and immune status. In addition, thermal energy generated during RFA is known to cause sloughing of tumour tissue in the biliary tract which might lead to early stent plugging and cholangitis^[18] (Figure 2). We tried to reduce this risk by sweeping the duct with a biliary balloon after application of RFA. In our study, RFA of the duct did not increase the risk of cholangitis. Other reported complications of EBRA such as acute pancreatitis, cholecystitis, cholangitis, gall bladder empyema and hemobilia were absent in our patients^[18,22]. Though the median intervention free days were similar in both groups (58 days versus 60 days), the need for re-stenting was less in patients who underwent RFA (17.3% versus 30.7%).

Our study population with advanced hCCA treated with palliative biliary drainage, had an overall median survival of 220 days. The patients in the intervention group had a significantly higher median survival of 282 days as compared to 180 days in the control group ($p = 0.008$). There was no difference in the number of patients who underwent palliative chemotherapy in both groups (13.6% in the intervention group and 11.1% in the controls, $p = 0.789$).

Earlier reports exploring the efficacy of EBRA with SEMS placement have shown mixed results with a trend towards a marginal survival benefit. A retrospective study by Sharaiha *et al.*, evaluated EBRA and SEMSs vs. SEMSs alone in 66 patients with malignant biliary obstruction (cholangiocarcinoma in 37 and pancreatic cancer in 29). Twenty-six were treated with RFA plus SEMS, while 40 patients matched by age and diagnosis underwent direct SEMS placement and were used as controls. No differences in AEs, increase in bile duct diameter and survival were observed between the two groups^[23].

However, in a systematic review and meta-analysis, Sofi *et al* studied 505 patients from 9 publications, with malignant biliary strictures in whom SEMS placement with or without prior RFA application via the endoscopic or the percutaneous routes was done. The analysis showed that patients who received RFA had a significantly longer stent patency (50 versus 37 days, $p < 0.002$) and survival (285 vs. 248 days, $p < 0.001$)^[24]. Yang J *et al* published a randomized control trial where type I and II Klatskin tumor (19) or distal cholangiocarcinoma (46) were randomly assigned to RFA plus plastic stent (32) versus plastic stent alone (33)^[25]. The main outcome was mean survival time and the secondary outcomes were adverse events and stent patency. Similar AEs occurred in both groups, while stent patency was signifi-

cantly longer in the RFA group (6.8 months versus 3.4 months, $p = 0.02$). The mean overall survival time was significantly longer in the RFA plus stent group than the stent only group (13.2 ± 0.6 versus 8.3 ± 0.5 months, $p < 0.001$)^[25].

Despite a significantly higher number of patients with metastatic disease and lymph node involvement (36.4% versus 11.1% in the control group), the median survival was significantly better in the intervention group. This can be attributed to an immunologic response directed towards the tumour triggered by RFA induced tissue necrosis^[18]. In a study by Schueller G *et al*, following RF ablation, cellular expression of heat-shock proteins (known to be of crucial importance in host-tumour interactions) HSP 70 and HSP 90 increased significantly in patients of hepatocellular carcinoma treated with RFA^[26].

Another interesting finding of this study was that patients with bilateral stent placement had a significant survival benefit ($p = 0.025$) with a median survival of 492 days compared with 124 days in patients who had unilateral stenting. Previous studies have shown conflicting results^[27-29]. But, a study by Lee *et al* showed that bilateral SEMS placement resulted in fewer reinterventions and a more durable stent patency (median 252 vs. 139 days)^[30]. This finding indicates an important role played by the number and location of biliary stents in the overall prognosis of these patients. The application of RFA can potentially facilitate bilateral stenting and optimal placement of stents, a finding which requires further validation.

CONCLUSION

This study is one of the few studies that evaluated the safety and efficacy of the ELRA™ endobiliary RFA probe in palliative biliary drainage for hCCA. Our study comparing thermal ablation of hCCA prior to the deployment of SEMS demonstrated a significant survival advantage in addition to what appears to be prolonged stent patency with less frequent therapeutic interventions. Compared to most other studies, our cohort of patients were uniform since we did not include distal cholangiocarcinoma and pancreatic cancer. Important technical aspects of EBRA were also highlighted in this study, including meticulous positioning of the RFA endo probe at the cephalic end of the stricture with incremental thermal ablation in a caudal fashion to achieve more complete ablation of the tumour mass; and balloon sweeping of the duct of necrotic debris prior to deploying the stent in order to reduce the risk of post procedural cholangitis. Thus, EBRA can be a useful adjunct to endoscopic palliation in patients with hCCA and needs further evaluation in larger studies.

Author Contributions

Krishnapriya S and Priya Nair were involved in patient recruitment and data entry. Priya Nair, Anoop Koshy and Harshavardhan Rao were involved in patient follow up. Priya Nair drafted the manuscript and Harshavardhan Rao and Rama P Venu revised the manuscript with critical insights.

REFERENCES

1. Global Burden of Disease Cancer Collaboration, Fitzmaurice C, Dicker D, Pain A, Hamavid H, Moradi-Lakeh M, MacIntyre MF, Allen C, Hansen G, Woodbrook R, Wolfe C, Hamadeh RR, Moore A, Werdecker A, Gessner BD, Te Ao B, McMahon B, Karimkhani C, Yu C, Cooke GS, Schwebel DC, Carpenter DO, Pereira DM, Nash D, Kazi DS, De Leo D, Plass D, Ukwaja KN, Thurston GD, Yun Jin K, Simard EP, Mills E, Park EK, Catalá-López F, deVeber G, Gotay C, Khan G, Hosgood HD 3rd, Santos IS, Leasher JL, Singh J, Leigh J, Jonas JB, Sanabria J, Beardsley J, Jacobsen KH, Takahashi K, Franklin RC, Ronfani L, Montico

- M, Naldi L, Tonelli M, Geleijnse J, Petzold M, Shrimel MG, Younis M, Yonemoto N, Breitborde N, Yip P, Pourmalek F, Lotufo PA, Esteghamati A, Hankey GJ, Ali R, Lunevicius R, Malekzadeh R, Dellavalle R, Weintraub R, Lucas R, Hay R, Rojas-Rueda D, Westerman R, Sepanlou SG, Nolte S, Patten S, Weichenthal S, Abera SF, Fereshtehnejad SM, Shiue I, Driscoll T, Vasankari T, Alsharif U, Rahimi-Movaghar V, Vlassov VV, Marcenés WS, Mekonnen W, Melaku YA, Yano Y, Artaman A, Campos I, MacLachlan J, Mueller U, Kim D, Trillini M, Eshtrati B, Williams HC, Shibuya K, Dandona R, Murthy K, Cowie B, Amare AT, Antonio CA, Castañeda-Orjuela C, van Gool CH, Violante F, Oh IH, Deribe K, Soreide K, Knibbs L, Kereselidze M, Green M, Cardenas R, Roy N, Tillmann T, Li Y, Krueger H, Monasta L, Dey S, Sheikhbahaei S, Hafezi-Nejad N, Kumar GA, Sreeramareddy CT, Dandona L, Wang H, Vollset SE, Mokdad A, Salomon JA, Lozano R, Vos T, Forouzanfar M, Lopez A, Murray C, Naghavi M. The Global Burden of Cancer 2013. *JAMA Oncol*. 2015 Jul; **1**(4): 505-27. [PMID: 26181261]; [DOI: 10.1001/jamaoncol.2015.0735]. Erratum in: *JAMA Oncol*. 2015 Aug; **1**(5):690. Jonas, Jost [corrected to Jonas, Jost B]; Tillman, Taavi [corrected to Tillmann, Taavi].
2. Banales JM, Cardinale V, Carpino G, Marzioni M, Andersen JB, Invernizzi P, Lind GE, Folseraas T, Forbes SJ, Fouassier L, Geier A, Calvisi DF, Mertens JC, Trauner M, Benedetti A, Maroni L, Vaquero J, Macias RIR, Raggi C, Perugorria MJ, Gaudio E, Boberg KM, Marin JGG, Alvaro D. Expert consensus document: Cholangiocarcinoma: current knowledge and future perspectives consensus statement from the European Network for the Study of Cholangiocarcinoma (ENS-CCA). *Nat Rev Gastroenterol Hepatol* 2016; **13**: 261-280. [PMID: 27095655]; [DOI: 10.1038/nrgastro.2016.51]
3. Razumilava N, Gores GJ. Cholangiocarcinoma. *Lancet Lond Engl* 2014; **383**: 2168-2179. [PMID: 24581682]; [DOI: 10.1016/S0140-6736(13)61903-0]
4. Khan SA, Emadossadat S, Ladep NG, Thomas HC, Elliott P, Taylor-Robinson SD, Toledano MB. Rising trends in cholangiocarcinoma: is the ICD classification system misleading us? *J Hepatol* 2012; **56**: 848-854. [PMID: 22173164]; [DOI: 10.1016/j.jhep.2011.11.015]
5. Gerges C, Schumacher B, Terheggen G, Neuhaus H. Expandable metal stents for malignant hilar biliary obstruction. *Gastrointest Endosc Clin N Am* 2011; **21**: 481-497, ix. [PMID: 21684466]; [DOI: 10.1016/j.giec.2011.04.004]
6. Larghi A, Tringali A, Lecca PG, Giordano M, Costamagna G. Management of hilar biliary strictures. *Am J Gastroenterol* 2008; **103**: 458-473. [PMID: 18028506]; [DOI: 10.1111/j.1572-0241.2007.01645.x]
7. Roughneen PT, Gouma DJ, Kulkarni AD, Fanslow WF, Rowlands BJ. Impaired specific cell-mediated immunity in experimental biliary obstruction and its reversibility by internal biliary drainage. *J Surg Res* 1986; **41**: 113-125. [PMID: 3762122]; [DOI: 10.1016/0022-4804(86)90016-8]
8. Gouma DJ, Roughneen PT, Kumar S, Moody FG, Rowlands BJ. Changes in nutritional status associated with obstructive jaundice and biliary drainage in rats. *Am J Clin Nutr* 1986; **44**: 362-369. [PMID: 3751957]; [DOI: 10.1093/ajcn/44.3.362]
9. Isayama H, Komatsu Y, Tsujino T, Sasahira N, Hirano K, Toda N, Nakai Y, Yamamoto N, Tada M, Yoshida H, Shiratori Y, Kawabe T, Omata M. A prospective randomised study of "covered" versus "uncovered" diamond stents for the management of distal malignant biliary obstruction. *Gut* 2004; **53**: 729-734. [PMID: 15082593]; [DOI: 10.1136/gut.2003.018945]
10. Kaassis M, Boyer J, Dumas R, Ponchon T, Coumaros D, Delcenserie R, Canard J-M, Fritsch J, Rey J-F, Burtin P. Plastic or metal stents for malignant stricture of the common bile duct? Results of a randomized prospective study. *Gastrointest Endosc* 2003; **57**: 178-182. [PMID: 12556780]; [DOI: 10.1067/mge.2003.66]
11. Almadi MA, Barkun A, Martel M. Plastic vs. Self-Expandable Metal Stents for Palliation in Malignant Biliary Obstruction: A Series of Meta-Analyses. *Am J Gastroenterol* 2017; **112**: 260-273. [PMID: 27845340]; [DOI: 10.1038/ajg.2016.512]
12. Faigel DO. Preventing biliary stent occlusion. *Gastrointest Endosc* 2000; **51**: 104-107. [PMID: 10625815]; [DOI: 10.1016/s0016-5107(00)70403-2]
13. Steel AW, Postgate AJ, Khorsandi S, Nicholls J, Jiao L, Vlavianos P, Habib N, Westaby D. Endoscopically applied radiofrequency ablation appears to be safe in the treatment of malignant biliary obstruction. *Gastrointest Endosc* 2011; **73**: 149-153. [PMID: 21184881]; [DOI: 10.1016/j.gie.2010.09.031]
14. Bertuccio P, Malvezzi M, Carioli G, Hashim D, Boffetta P, El-Serag HB, La Vecchia C, Negri E. Global trends in mortality from intrahepatic and extrahepatic cholangiocarcinoma. *J Hepatol* 2019; **71**: 104-114. [PMID: 30910538]; [DOI: 10.1016/j.jhep.2019.03.013]
15. Banales JM, Marin JGG, Lamarca A, Rodrigues PM, Khan SA, Roberts LR, Cardinale V, Carpino G, Andersen JB, Braconi C, Calvisi DF, Perugorria MJ, Fabris L, Boulter L, Macias RIR, Gaudio E, Alvaro D, Grailone SA, Strazzabosco M, Marzioni M, Coulouarn C, Fouassier L, Raggi C, Invernizzi P, Mertens JC, Moncsek A, Rizvi S, Heimbach J, Koerkamp BG, Bruix J, Forner A, Bridgewater J, Valle JW, Gores GJ. Cholangiocarcinoma 2020: the next horizon in mechanisms and management. *Nat Rev Gastroenterol Hepatol*. 2020 Sep; **17**(9): 557-588. [PMID: 32606456]; [DOI: 10.1038/s41575-020-0310-z. Epub 2020 Jun 30.]
16. Tringali A, Boškoski I, Costamagna G. Endoscopic Stenting in Hilar Cholangiocarcinoma: When, How, and How Much to Drain? *Gastroenterol Res Pract* 2019; **2019**: 5161350. [PMID: 31781190]; [DOI: 10.1155/2019/5161350]
17. Rajman I. Biliary and pancreatic stents. *Gastrointest Endosc Clin N Am* 2003; **13**: 561-592, vii-viii. [PMID: 14986787]; [DOI: 10.1016/s1052-5157(03)00069-2]
18. Larghi A, Rimbaş M, Tringali A, Boškoski I, Rizzatti G, Costamagna G. Endoscopic radiofrequency biliary ablation treatment: A comprehensive review. *Dig Endosc Off J Jpn Gastroenterol Endosc Soc* 2019; **31**: 245-255. [PMID: 30444547]; [DOI: 10.1111/den.13298]
19. Laleman W, van der Merwe S, Verbeke L, Vanbeckevoort D, Aerts R, Prenen H, Van Cutsem E, Verslype C. A new intraductal radiofrequency ablation device for inoperable biliopancreatic tumors complicated by obstructive jaundice: the IGNITE-1 study. *Endoscopy* 2017; **49**: 977-982. [PMID: 28732391]; [DOI: 10.1055/s-0043-113559]
20. Tang Z, Yang Y, Meng W, Li X. Best option for preoperative biliary drainage in Klatskin tumor: A systematic review and meta-analysis. *Medicine (Baltimore)*. 2017 Oct; **96**(43):e8372. [PMID: 29069029]; [DOI: 10.1097/MD.00000000000008372.]
21. Coelen RJS, Roos E, Wiggers JK, Besselink MG, Buis CI, Busch ORC, Dejong CHC, Delden OM van, Eijck CHJ van, Fockens P, Gouma DJ, Koerkamp BG, Haan MW de, Hooft JE van, IJzermans JNM, Kater GM, Koornstra JJ, Lienden KP van, Moelker A, Damink SWMO, Poley J-W, Porte RJ, Ridder RJ de, Verheij J, Woerden V van, Rauws EAJ, Dijkgraaf MGW, Gulik TM van. Endoscopic versus percutaneous biliary drainage in patients with resectable perihilar cholangiocarcinoma: a multicentre, randomised controlled trial. *Lancet Gastroenterol Hepatol* 2018; **3**: 681-690. [PMID: 30122355]; [DOI: 10.1016/S2468-1253(18)30234-6]
22. Tal AO, Vermehren J, Friedrich-Rust M, Bojunga J, Sarrazin C, Zeuzem S, Trojan J, Albert JG. Intraductal endoscopic radiofrequency ablation for the treatment of hilar non-resectable malignant bile duct obstruction. *World J Gastrointest Endosc* 2014; **6**: 13-19. [PMID: 24527176]; [DOI: 10.4253/wjge.v6.i1.13]
23. Sharaiha RZ, Natov N, Glockenberg KS, Widmer J, Gaidhane M, Kahaleh M. Comparison of metal stenting with radiofrequency ablation versus stenting alone for treating malignant biliary strictures: is there an added benefit? *Dig Dis Sci* 2014; **59**: 3099-3102.

- [PMID: 25033929]; [DOI: 10.1007/s10620-014-3264-6]
24. Sofi AA, Khan MA, Das A, Sachdev M, Khuder S, Nawras A, Lee W. Radiofrequency ablation combined with biliary stent placement versus stent placement alone for malignant biliary strictures: a systematic review and meta-analysis. *Gastrointest Endosc* 2018; **87**: 944-951.e1. [PMID: 29108980]; [DOI: 10.1016/j.gie.2017.10.029]
25. Yang J, Wang J, Zhou H, Zhou Y, Wang Y, Jin H, Lou Q, Zhang X. Efficacy and safety of endoscopic radiofrequency ablation for unresectable extrahepatic cholangiocarcinoma: a randomized trial. *Endoscopy* 2018; **50**: 751-760. [PMID: 29342492]; [DOI: 10.1055/s-0043-124870]
26. Schueller G, Kettenbach J, Sedivy R, Stift A, Friedl J, Gnant M, Lammer J. Heat shock protein expression induced by percutaneous radiofrequency ablation of hepatocellular carcinoma in vivo. *Int J Oncol*. 2004 Mar;24(3):609-13. [PMID: 14767545.DOI: <https://doi.org/10.3892/ijo.24.3.609>]
27. Sawas T, Al Halabi S, Parsi MA, Vargo JJ. Self-expandable metal stents versus plastic stents for malignant biliary obstruction: a meta-analysis. *Gastrointest Endosc* 2015; **82**: 256-267.e7. [PMID: 25982849]; [DOI: 10.1016/j.gie.2015.03.1980]
28. Puli SR, Kalva N, Pamulaparthi SR, Bechtold ML, Cashman MD, Volmar F-H, Dhillon S, Shekleton MF, Estes NC, Carr-Locke D. Bilateral and unilateral stenting for malignant hilar obstruction: a systematic review and meta-analysis. *Indian J Gastroenterol Off J Indian Soc Gastroenterol* 2013; **32**: 355-362. [PMID: 24214663]; [DOI: 10.1007/s12664-013-0413-3]
29. Hong W, Sun X, Zhu Q. Endoscopic stenting for malignant hilar biliary obstruction: should it be metal or plastic and unilateral or bilateral? *Eur J Gastroenterol Hepatol* 2013; **25**: 1105-1112. [PMID: 23542449]; [DOI: 10.1097/MEG.0b013e328360b9ec]
30. Lee TH, Kim TH, Moon JH, Lee SH, Choi HJ, Hwangbo Y, Hyun JJ, Choi J-H, Jeong S, Kim JH, Park DH, Han J-H, Park S-H. Bilateral versus unilateral placement of metal stents for inoperable high-grade malignant hilar biliary strictures: a multicenter, prospective, randomized study (with video). *Gastrointest Endosc* 2017; **86**: 817-827. [PMID: 28479493]; [DOI: 10.1016/j.gie.2017.04.037]