

Journal of Gastroenterology and Hepatology Research

Online Submissions: <http://www.ghrnet.org/index./joghr/>
doi: 10.17554/j.issn.2224-3992.2021.10.1028

Journal of GHR 2021 October 21; **10(5)**: 3577-3586
ISSN 2224-3992 (print) ISSN 2224-6509 (online)

ORIGINAL ARTICLE

Clinical, Radiographical and Antibacterial Evaluation of Acemannan Sponge and Tri-Mix Used in Treatment of Non Vital Primary Molars

Sara Gonna¹, Rehab Foad Ghouraba², Radwa Eissa³, Amal Kabbash⁴, Akira Yagi⁵, Nancy Mohamed Metwally⁶

1 Lecturer at Pediatric Dentistry Department, Tanta University, Egypt;

2 Lecturer of Oral medicine, periodontology, oral diagnosis and radiology department, faculty of dentistry, Tanta University, Egypt;

3 Lecturer of Medical Microbiology and Immunology, Faculty of medicine, Tanta university;

4 Professor of Pharmacognosy Department, Faculty of Pharmacy, Tanta University;

5 Special advisor of Japan Aloe Science Association, Editor in-Chief of Journal of Gastroenterology and Hepatology Research; Emeritus Professor, Fukuyama University, Hiroshima, Japan;

6 Lecturer of Pediatric Dentistry, Tanta University, Egypt.

Conflict-of-interest statement: The authors declare that there is no conflict of interest regarding the publication of this paper.

Open-Access: This article is an open-access article which was selected by an in-house editor and fully peer-reviewed by external reviewers. It is distributed in accordance with the Creative Commons Attribution Non Commercial (CC BY-NC 4.0) license, which permits others to distribute, remix, adapt, build upon this work non-commercially, and license their derivative works on different terms, provided the original work is properly cited and the use is non-commercial. See: <http://creativecommons.org/licenses/by-nc/4.0/>

Correspondence to: Akira Yagi, 2-10-1 Hanagaura-ku, Kasuyamachi, Kasuya-gun, Fukuoka-ken, Japan 811-2310.

Email: 0131akirayagi@gmail.com

Telephone: +81-92-938-2717

Received: August 16, 2021

Revised: September 15, 2021

Accepted: September 17, 2021

Published online: October 21, 2021

ABSTRACT

AIM: The present study was conducted to compare effects of acemannan and 3 Mix antibiotic (ciprofloxacin, amoxicillin and metronidazole) as pulpotomy in non-vital primary molars. And assess the antibacterial effect of acemannan and 3 Mix.

MATERIALS AND METHODS: Aloe vera gel high molecular weight fractions (AHM) containing native ingredients of polysaccharide (acemannan) and glycoprotein (verectin) were obtained by using the patented hyper dry system after washing out coloured materials with running water from Aloe vera gel slurry. Twenty healthy children aged from four to eight years, they were selected from patients attending outpatient clinic of Pediatric Dentistry department. Each child had at least bilateral non vital lower primary molar indicated for non-vital pulpotomy. Non vital pulpotomy was done in both groups; where group I treated by 3Mix antibiotics, while AHM, acemannan used in group II. The study cases were recalled after three, nine and twelve months for clinical and radiographic evaluation.

RESULTS: The overall clinical and radiographical success rate of acemannan group was 82%, while 3mix antibiotic group was 18%. Frurther more, group 2 AHM showed better improvement in intra-radicular bone density with treatment than group I 3trimix which was statistically significant $p > 0.05$.

CONCLUSION: The acemannan showed higher clinical and radiographic success rate compared to 3mix antibiotic as a pulpotomy agent in non-vital primary molars. It can be considered as an acceptable biomaterial for non-vital pulp therapy of deep caries in primary teeth.

Key words: Acemannan; 3mix antibiotic; Primary teeth; Non-vital pulpotomy

© 2021 The Authors. Published by ACT Publishing Group Ltd. All rights reserved.

Gonna S, Ghouraba RF, Eissa R, Kabbash A, Yagi A, Metwally NM. Clinical, Radiographical and Antibacterial Evaluation of Acemannan Sponge and Tri-Mix Used in Treatment of Non Vital Primary Molars. *Journal of Gastroenterology and Hepatology Research* 2021; **10(5)**: 3577-3586 Available from: URL: <http://www.ghrnet.org/index.php/joghr/article/view/3214>

INTRODUCTION

Teeth with infected root canals, particularly when reached the periradicular tissues, are a common problem in primary dentition. The

premature loss of primary molars will not only limit the child's diet choices, but it will also increase the crowding tendency. So, a successfully treated tooth is the best space maintainer^[1].

The root canal system of the primary molars is very complex; examination of numerous primary molars revealed thin, tortuous and branching network. This morphology makes it difficult to achieve proper cleansing by mechanical instrumentation and irrigation of the canals^[2].

To overcome this, the technique of mortal pulpotomy was suggested by Velling and Captain^[3] as a treatment of necrotic primary molar pulps with no attempt to ream the canals and it was showed high success rate.

Different medicaments have been used to alleviate pain and treat pulp pathology; formocresol, camphorated parachlorophenol and beechwood creosote were recommended because of their clinical success. Formocresol was the agent of choice for vital and non-vital pulp therapy. Although camphorated parachlorophenol were found to be less irritating to the bifurcation tissue, it showed a cytotoxic effect. Beechwood creosote caused no pain and rapidly eliminates most of the infecting organisms. However, there is an obvious desire to move away from the use of potentially toxic compounds and to use medicaments that promote repair of tissues^[4,5].

An alternative approach in the treatment of non-vital primary molars with or without periapical involvement is Lesion Sterilization and Tissue Repair (LSTR); it is non-instrumental endodontic treatment in which there is no mechanical instrumentation, no enlargement of root canal and no unnecessary irritation of periapical tissue. It reduces the chair time as it requires only one treatment visit^[6].

Due to polymicrobial nature of the infected root canals, the concept of LSTR includes the use of triantibiotic paste to suppress the pathogen and allow healing in the periapical lesions. The triantibiotic paste is composed of metronidazole, ciprofloxacin and minocycline; the volume applied is small and there is no report of side-effects on children^[7].

Although minocycline exhibits broad spectrum activity against gram positive and gram negative microorganisms, it has a disadvantage of causing discoloration. Amoxicillin was substituted for minocycline of the triantibiotic paste to avoid discoloration^[8].

The triantibiotic paste can be used in the treatment of non-vital primary teeth as it is shown to be effective in disinfection and successful in healing of large periradicular lesions^[9].

Recently, there has been a growing trend to seek natural remedies as part of medical and dental therapeutics, which has been termed as "phytotherapeutics" or "ethnopharmacology"^[10]. *Aloe vera* is embracing the concept of phytotherapy; it is a tropical or sub-tropical plant of the genus and belongs to family *Liliaceae*. It is succulent, perennial, evergreen having lance shaped leaves, containing a viscous essentially clear gel^[11,12]. The potentially active components of *Aloe vera* are amino acids, sugars, enzymes, vitamins, minerals, powerful nutritional supplement and antioxidant^[13].

Aloe vera has important properties such as tissue penetration, anti-inflammatory effect, immunoregulatory function, in addition to antimicrobial, healing and regenerative properties^[14,15]. Also it has anti-fungal, antiviral, and anti-tumor properties which make it useful in broad range of ailments including: arthritis, asthma, gastrointestinal diseases, skin burning, protects and promotes wound healing^[16,17].

In dentistry, *Aloe vera* is used in periodontal therapy, acute mouth lesions are improved by direct application of it on herpetic viral lesions, aphthous ulcers, canker sores, and cracks occurring at the corners of the lips^[18]. It can also be used around dental implants

and in ill-fitting denture base to control any bacterial and fungal infection^[19,20]. Also, *Aloe vera* added to toothpaste due to its bleaching properties^[21].

Acemannan is a sponge acetylated polymannose extracted from *Aloe vera* gel, it promotes dentin formation by stimulating primary dental pulp cell proliferation, differentiation, extracellular matrix formation, and mineralization^[20].

In endodontic treatment of primary teeth, Khairwa *et al*^[22] evaluate using of mixture of zinc oxide and *Aloe vera* gel instead of eugenol as an obturating material in primary teeth. It was observed that 73.34% of cases demonstrated arrest or decrease of radiolucency and has shown good clinical and radiographic success.

MATERIALS AND METHODS

This study was conducted as a clinical trial, it was carried out at Pediatric Dentistry Department, Faculty of Dentistry, Tanta University. This study was carried out on thirty healthy children aged from four to eight years, they were selected from patients attending outpatient clinic of Pediatric department. The microbiological study was carried out at the laboratory of Microbiology, Faculty of Medicine, Tanta University. Each child had at least two non-vital primary mandibular (first or second) molars indicated for non-vital pulpotomy (Figure 1).

Approval for this research was obtained from Faculty of Dentistry, Tanta University Research Ethics Committee. The purpose of the present study was explained to the patients and informed consents were obtained according to the guidelines on human research adopted by the Research Ethics Committee Faculty of Dentistry, Tanta University

Criteria for teeth selection

Criteria for teeth selection

A Clinical criteria: (1) Necrotic pulp tissue upon entrance the pulp chamber. (2) Presence of gingival swelling or fistula. (3) Pain on percussion.

Exclusion criteria: (1) Non restorable tooth. (2) Patients with medical condition as heart disease or leukemia because pulp therapy is contraindicated. (3) Patients with history of drug allergy to metronidazole, ciprofloxacin or amoxicillin. (4) Extensive root resorption exceeding one third of the root. (5) Severe mobility.

B-Radiographic criteria: (1) Evidence of furcation or periapical radiolucency. (2) Discontinuity of lamina dura. (3) Physiological root resorption not exceeding one third of the root.

Preparation of acemannan sponge

***Aloe vera* polysaccharide fraction:** Fresh *Aloe vera* gel (100 g) was homogenized and centrifuges at 9×10^3 g for 10 min. The supernatant was dialyzed with molecular weight 8000 cut-off membrane against distilled water for 36 hours and the non-dialysate (1 g) was obtained as polysaccharides fraction after lyophilization, 0.4% acemannan solutions (w/v) were frozen at -80 C degree for 16 h and lyophilized overnight. Then the sponges are sterilized by gamma irradiation and tested for endotoxin contamination. The endotoxin level of the acemannan sponges are assessed using the Traditional Kinetic Limulus Amebocyte Lysate (LAL) assay kit (Lonza, Inc., Allendale, NJ, USA) following the manufacturer's instructions. The endotoxin level is measured using ELISA after mixing the sample with LAL reagent and comparing it to a standard curve. Endotoxin levels are 4.30 EU/mg sponge^[23]. Acemannan sponge, provided by Prof. Yagi A., Emeritus, Fukuyama University, Hiroshima, Japan (Figure 2).

Preparation of triantibiotic paste (3 Mix)

The capsule shell and the enteric coating of the three antibiotics were removed and they were pulverized using mortar and pestle. The powdered antibiotics were stored and sealed in air tight containers separately from light and moisture. The same amount of each drug was mixed together; one part of each powdered drug was taken in the ratio 1:1:1. After that the mixed drugs were combined with macrogol (M) and propylene glycol (P) in ratio of 1:1 by volume to form 3 Mix-MP paste just before use. The unused paste was discarded at the end of the day^[24]. One part of barium sulfate was added as radioopacifier^[25].

Antibacterial activity assay

Agar diffusion method: Antimicrobial effect of Aloe vera, and 3Mix-MP against *Staphylococcus aureus* and *Escherichia coli* was determined by agar diffusion method (modified Kirby- Bauer) on Muller-Hinton agar^[26] and this was done in microbiology laboratory at Microbiology Department, Faculty of Medicine, Tanta University.

Bacterial suspensions were prepared equivalent to 0.5 McFarland^[27]. The tested organism was spread on the surface of Muller Hinton agar plate by sterile swab. The 3mix was dispersed in polyethylene glycol. While the Aloe vera extracts were mixed in distilled water. Sterile circular paper discs each 6 mm in diameter were immersed into these dispersions before mounting on the surface of seeded agar. The plates were then incubated at 37°C for 24 hours and the plates were examined for the inhibition zones^[28]. The relative susceptibility was determined by measuring the diameter of the inhibition zones using caliper. The diameter of each zone was recorded as the average of three determinations to minimize the errors.

Technique

Clinical procedures: Under local anesthesia and rubber dam isolation clinical procedure was performed, caries was removed using a sterile high speed rose head bur with continuous water spray. Access opening was gained; roof of the pulp chamber was removed and all overhanging edges were eliminated. The pulp chamber was then irrigated with normal saline and dried. In case of teeth presented with abscess, drainage and irrigation with normal saline was done.

Group assignment: The forty selected primary molars out of twenty children were randomly divided into two groups of twenty teeth for each, according to the material used as follow: **Group I (study group):** Treated using 3 Mix-MP. **Group II (control group):** Treated using Acemannan sponge was mixed with distilled water to form a viscous solution and mixed with zinc oxide powder.

The treatment was done in a single visit; the paste of the material used in the study according to each group was placed in the pulp chamber and the cavity was sealed with glass ionomer cement and post-operative x-ray was taken (baseline). All cases were recalled after 7-10 days for placement of the final restoration. The cases which show persistent abscess were excluded from the study. The children were recalled after 3, 9, 12 months for clinical and radiographic evaluation. The collected data were recorded in pedodontic examination chart (Figures 3, 4).

The parallel periapical technique was gained through using the Rinn (XCP, Eign,IL) which was mounted to the x-ray tube with its arm was attached to the film holder which hold covered PSP (photo stimulated phosphorous plate). Condensation rubber base impression material was prepared and put on outer surface of film holder and the child was ordered to bite on it during setting of the

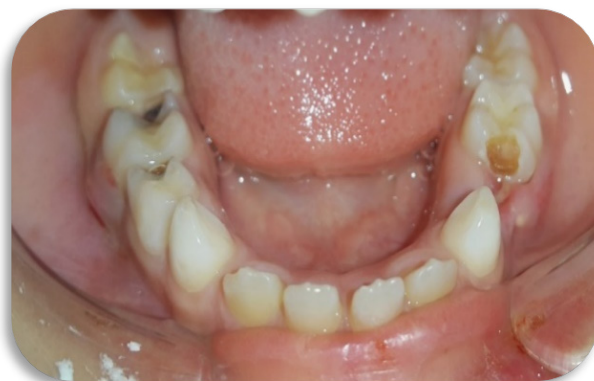

Figure 1 A photograph showing bilateral carious mandibular second molars with abscess formation.




Figure 2 Acemannan sponges.

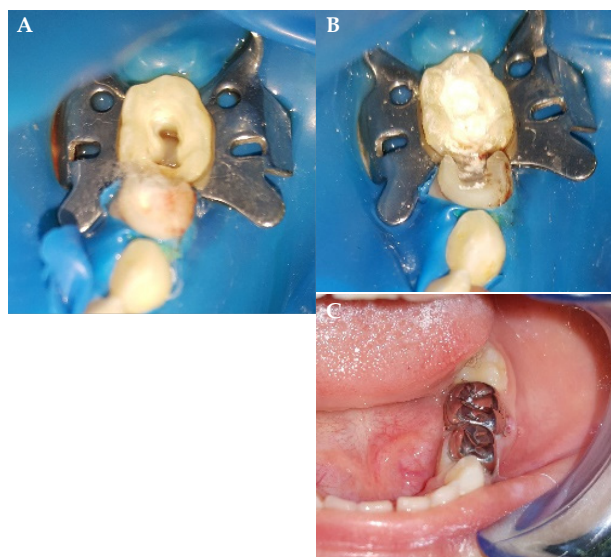


Figure 3 Clinical procedure using Acemannan sponge. (A) Access opening after removal of dead pulp tissue; (B) Applying Acemannan sponge mixed with ZOE in the pulp chamber (C) Final stainless steel crown insertion

material to ensure standardization during retakes of radiographical images. The sensor was exposed to X-ray device (Planmeca ProX, Helsinki, Finland) with 70 kVp, 6 mA, 0.8 s exposure time. The central ray was directed perpendicular to the sensor.

All data was collected, tabulated, and statistically analyzed. Chi-square test and Fisher exact were used to test significance of

association between nominal variables. In order to compare mean difference between groups, unpaired and paired-t test were used. The significance level was set as P value ≤ 0.05 is significant. Statistical analysis was performed using SPSS version 16.

RESULTS

Non vital pulpotomy was performed on forty mandibular primary molars out of 20 children selected from Outpatient clinics of Pediatric Dentistry Department, Faculty of Dentistry and Tanta University however three cases were lost leaving 17 patients. All patients were evaluated clinically and radiographically prior treatment, immediately after restoration, at three and at twelve months after restoration.

Clinical evaluation

The following criteria were used to evaluate the efficacy of treatment clinically^[29]: (1) Absence of pain; (2) No tooth mobility; (3) Presence of healthy soft tissue; no swelling, redness or sinus tract.

Prior treatment, all twenty deciduous molars of both groups showing pain with pain to vertical percussion with ten deciduous molars (50%) from group 1 (G1), regarding group 2 (G2) nine deciduous molars (45%) showing mobility. Immediately after restoration two deciduous molars (10%) showed pain regarding G1 and one deciduous molar (5%) regarding G2 with 3 deciduous molars (15%) regarding G1 and two deciduous molars (10%) regarding G2 showed pain to vertical percussion while regarding tooth mobility there were two deciduous molars (10%) in G1 and one deciduous molar (5%) in G2 showing mobility. At 3 months post restoration 4 deciduous molar (20%) regarding G1 and two deciduous molars (10%) regarding G2 showed pain with 4 deciduous molars (20%) regarding G1 and two deciduous molars cases (10%) regarding G2 showed pain to vertical percussion while regarding tooth mobility there was two deciduous molars (10%) in G1 and one deciduous molar (5%) in G2 showing mobility. At 9 months post restoration there were three cases dropped out with ten deciduous molars (59%) regarding G1 and two deciduous molars (12%) regarding G2 showed pain with twelve deciduous molars (71%) regarding G1 and two deciduous molars (12%) regarding G2 showed pain to vertical

percussion while regarding tooth mobility there was seven deciduous molars (41%) in G1 and two deciduous molars (12%) in G2 showing mobility. At 12 months post restoration fourteen deciduous molars (82%) regarding G1 and two deciduous molars (12%) regarding G2 showing pain and pain to vertical percussion while regarding tooth mobility there were twelve deciduous molars (41%) in G1 and two deciduous molars (12%) in G2 showed mobility. Upon using Chi-square test, there were statistically significant difference (P value ≤ 0.05) in favor of G2 regarding pain presence, pain to vertical and tooth mobility as shown in Table 1, 2 and 3 respectively.

Furthermore, at 12 months post restoration fourteen deciduous molars (82%) regarding G1 revealed signs of failure with ten cases with recurrent intra-radicular abscess among three of them showed also fistulas tract and four deciduous molars showed mobility, G2 showed three deciduous molars (18%) with mobility by using Fisher exact test, there was statistically significant difference (P value ≤ 0.05) in favor of G2 as shown in table 4.

Table 1 Intergroup comparison according to pain presence.

	At pa		At B ∞		At 3 m PR δ		At 9 m PR δ		At 12 m PR δ	
	N	%	N	%	N	%	N	%	N	%
G1	20/20	100%	2/20	0.1	4/20	0.2	10/17	0.59	14/17	82%
G2	20/20	100%	1/20	0.05	2/20	0.1	2/17	0.12	2/17	12%
χ^2	51.03									
P	0.0001***									

Chi-square test Significance: $p^* < 0.05$, $p^{**} < 0.01$, $p^{***} < 0.001$; ns=not significance; α prior treatment, ∞ immediately after treatment, δ post restoration

Table 2 Intergroup comparison according to pain presence to percussion.

	At pa		At B ∞		At 3m PR δ		At 9 m PR δ		At 12 m PR δ	
	N	%	N	%	N	%	N	%	N	%
G1	20/20	100%	3/20	0.15	4/20	0.2	12/17	0.71	14/17	82%
G2	20/20	100%	2/20	0.1	2/20	0.1	2/17	0.12	2/17	12%
χ^2	56.7									
P	0.0001***									

Chi-square test Significance: $p^* < 0.05$, $p^{**} < 0.01$, $p^{***} < 0.001$; ns=not significance; α prior treatment, ∞ immediately after treatment, δ post restoration

Table 3 Intergroup comparison according to presence of mobility.

	At pa		At B ∞		At 3 m PR δ		At 9 m PR δ		At 12 m PR δ	
	N	%	N	%	N	%	N	%	N	%
G1	10/20	50%	2/20	10%	2/20	10%	7/17	41%	12/17	71%
G2	9/20	45%	1/20	5%	2/20	10%	2/17	12%	2/18	12%
χ^2	27.34									
P	0.0001***									

Chi-square test Significance: $p^* < 0.05$, $p^{**} < 0.01$, $p^{***} < 0.001$; ns=not significance; α prior treatment, ∞ immediately after treatment, δ post restoration

Table 4 Intergroup comparison according to success and failure rate.

	Failure		Success	
	N	%	N	%
G1(3MDX)	14	82%	3	18%
G2 (AC)	3	18%	14	82%
P~	0.0001***			

~ Fisher exact test Significance: $p^* < 0.05$, $p^{**} < 0.01$, $p^{***} < 0.001$; ns=not significance.

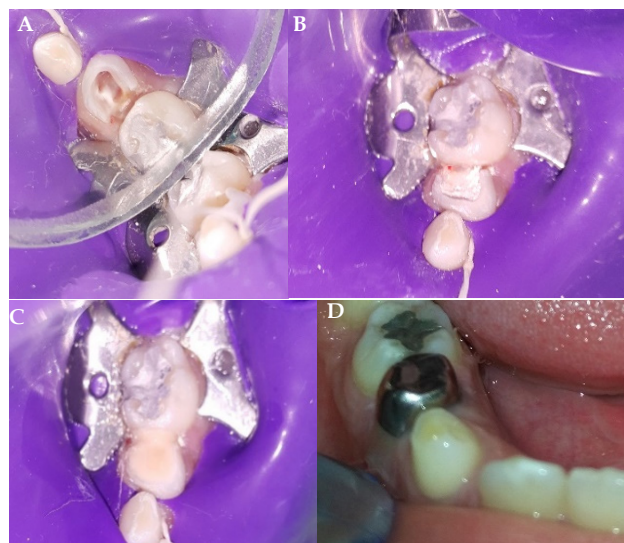

Figure 4 Clinical procedure using 3Mix. (A) Access opening of mandibular second molar after removal of dead pulp tissue; (B) Application of 3Mix; (C) Application of glass ionomer; (D) Stainless-steel crowns in place at the second visit.

Radiographic evaluation

The radiographic evaluation was recorded according to success criteria as follow^[30]: (1) Continuity of lamina Dura. (2) Static or reduction in the size of existing pathologic intraradicular or periapical radiolucency. (3) No newly formed radiographic lesion. (4) Absence of pathological root resorption. (5) Evidence of bone regeneration.

Radiographic evaluation was performed prior starting treatment, immediately after tooth restoration (base line), after 3 months, 9 months and twelve months post restoration (Figures 5, 6) for

group treated with 3trimix(G1) and grouped with Acemannan (G2) respectively, these direct radiographical images were achieved using intraoral digital PSP (photo simulated phosphorus plate) sensor (Planmeca ProSensor HD, Helsinki, Finland).

Radiographical evaluation regarding density was achieved through using the histogram feature of a software application (Adobe Photoshop CS6; Adobe System, Inc., San Jose, CA). Also, presence of external or internal root resorption was assessed in periapical radiographs. The region of interest (ROIs) was picked in middle of furcation region to measure mean value of gray level (Figure 7).

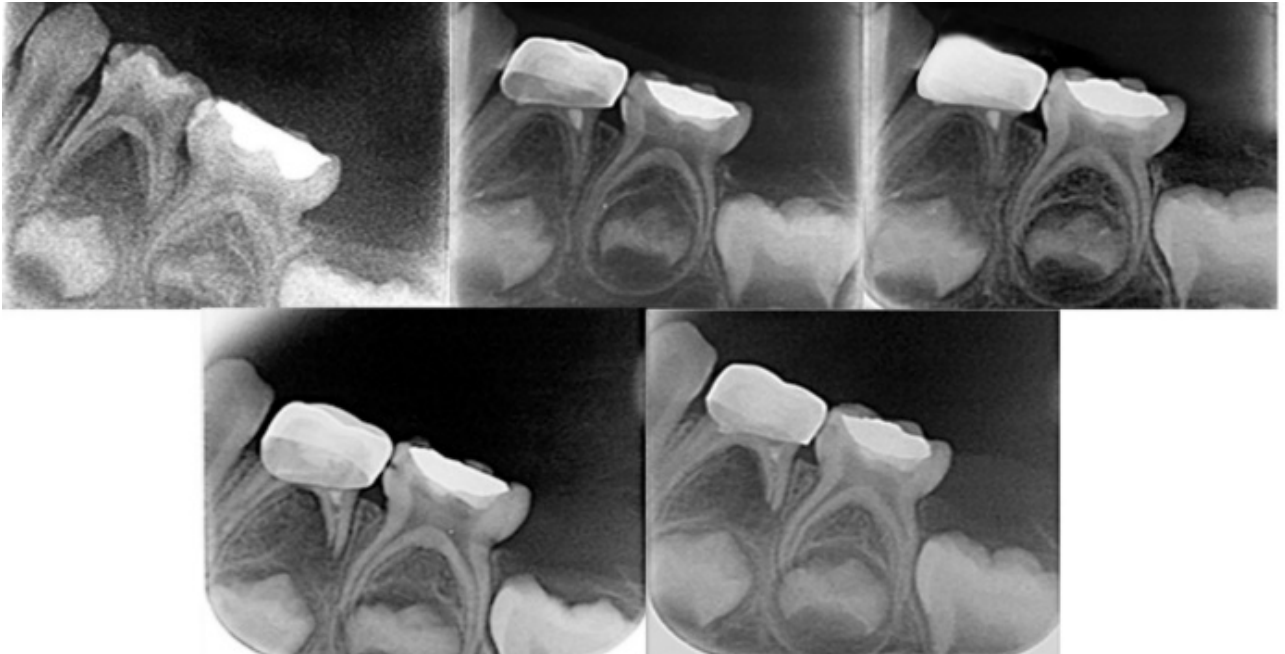


Figure 5 A: pre-operative radiograph showing proximal mesial caries to lower right D, B: base line image immediately after restoration with 3trimix and (C-D): follow up periods at 3, 9 and 12 months post restoration respectively.

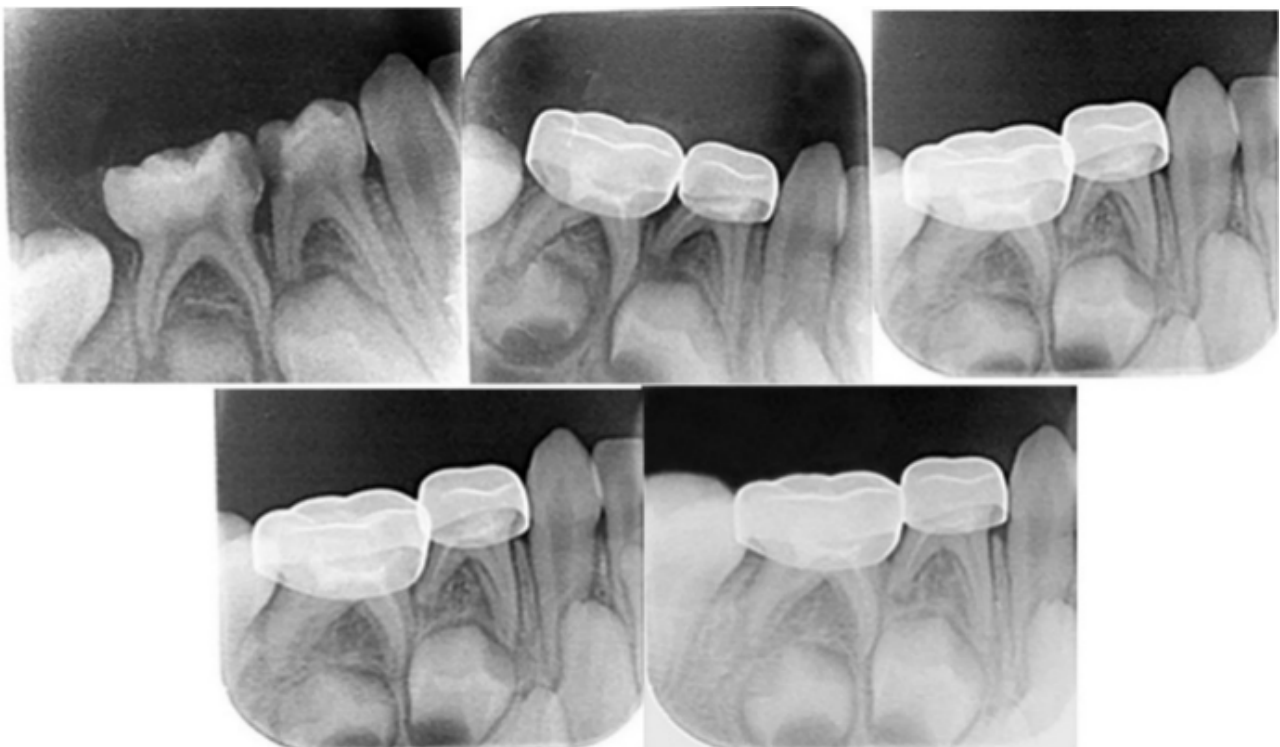

Figure 6 A: pre-operative radiograph showing proximal caries between lower left D and E, B: base line image immediately after restoration with Acemannan and (C-D): follow up periods at 3, 9 and 12 months post restoration respectively.

Radiographic evaluation

Regarding bone density in furcation region, intra-group comparison of G1 showed (Table 5) G1 mean value of bone density prior treatment was 146 ± 4.899 , immediately after restoration was 118.8 ± 8.89 , three months after restoration was 98.75 ± 2.99 , nine months after restoration was 51.25 ± 2.99 and twelve months post restoration was 31.50 ± 2.65 . Upon using paired t test, there was statistically significant decrease in bone density when compared to baseline (immediately after restoration) value as ($p < 0.05$) as shown in Table 5.

Regarding bone density in furcation region, intra-group comparison of G2 showed mean value of bone density prior treatment was 150.0 ± 4.08 , immediately after restoration was 121.8 ± 8.261 , three months after restoration was 137.3 ± 6.076 , nine months after restoration was 151.8 ± 4.992 and twelve months post restoration was 160.0 ± 4.082 . Upon using paired t test, there was statistically significant increase in bone density when compared to baseline (immediately after restoration) value as ($p < 0.05$) as shown in Table 6.

Inter-group comparison of mean values of bone density between G1&G2 prior treatment and immediately after restoration were (146 ± 4.899 , 150.0 ± 4.08 , 118.8 ± 8.89 , 121.8 ± 8.261), respectively with no statistical significant difference ($p > 0.05$) by using paired test. However, Inter-group comparison of mean values of bone density between G1 & G2 at 3,9 & 12 months were (98.75 ± 2.99 , 137.3 ± 6.076), (51.25 ± 2.99 , 151.8 ± 4.992) and (31.50 ± 2.646 , 160.0 ± 4.082) respectively with statically significant difference ($p < 0.05$) in favor of G2 upon using paired t test as shown in Table 6.

In addition, at 12 months post restoration fourteen deciduous molars (82%) regarding G1 revealed signs of failure with ten deciduous molar showed decrease in intra-radicular bone density, three with internal root resorption and one deciduous molar with external root resorption whereas, G2 showed three deciduous molars (18%) with failure two of them showed internal root resorption and one deciduous molar showed external root desorption with using Fisher exact test, there was statistically significant difference (p value ≤ 0.05) in favor of G2 as shown in Table 4.

Table 5 Intra-group comparison of bone density at furcation region regarding group1.

G1	GP α v GB	GP ∞ vG3	GP vG9	GP v G12	GB v G3	GB v G9	GB v G12	G3v G9	G3 vG12	G9 vG12
M \pm SD	146 ± 4.899 ; 118.8 ± 8.89	146 ± 4.899 ; 98.75 ± 2.99	146 ± 4.899 ; 51.25 ± 2.99	146 ± 4.899 ; 31.50 ± 2.646	118.8 ± 8.89 ; 98.75 ± 2.99	118.8 ± 8.89 ; 51.25 ± 2.99	118.8 ± 8.89 ; 31.50 ± 2.65	98.75 ± 2.99 ; 51.25 ± 2.99	98.75 ± 2.99 ; 31.50 ± 2.65	51.25 ± 2.99 ; 31.50 ± 2.65
t	10.1	42.62	24.28	34.39	5.43	12.13	17.46	15.91	27.7	13.75
p	0.00210**	0.0001***	0.0001***	0.0001***	0.012*	0.0012**	0.0004***	0.0005***	0.0001***	0.0005***

Paired t test Significance: $p^* < 0.05$, $p^{**} < 0.01$, $p^{***} < 0.001$; ns=not significance; α prior treatment, ∞ immediately after treatment

Table 6 Intra-group comparison of bone density at furcation region regarding group2.

S	GP α v GB	GP ∞ vG3	GP vG9	GP v G12	GB v G3	GB v G9	GB v G12	G3v G9	G3 vG12	G9 vG12
M \pm SD	150.0 ± 4.08 ; 121.8 ± 8.261	150.0 ± 4.08 ; 137.3 ± 6.076	150.0 ± 4.08 ; 151.8 ± 4.992	150.0 ± 4.08 ; 160.0 ± 4.082	121.8 ± 8.261 ; 137.3 ± 6.076	121.8 ± 8.261 ; 151.8 ± 4.992	121.8 ± 8.261 ; 160.0 ± 4.082	137.3 ± 6.076 ; 151.8 ± 4.992	137.3 ± 6.076 ; 160.0 ± 4.082	151.8 ± 4.992 ; 160.0 ± 4.082
T	7.012	5.251	1.578	41	7.671	8.485	9.495	6.047	9.369	7.441
P	0.0060**	0.0135*	0.2126ns	0.0001***	0.0046**	0.0034**	0.0025**	0.0091**	0.0026**	0.0050**

Paired t test Significance: $p^* < 0.05$, $p^{**} < 0.01$, $p^{***} < 0.001$; ns=not significance; α prior treatment, ∞ immediately after treatment

Table 7 Inter-group comparison of bone density at furcation region between G1and G2.

Stage	G1vG2 at Pa	G1vG2 at B ∞	G1vG2 at3	G1vG2 at9	G1vG2 at12
M \pm SD	146 ± 4.899 ; 150.0 ± 4.08	118.8 ± 8.89 ; 121.8 ± 8.261	98.75 ± 2.99 ; 137.3 ± 6.076	51.25 ± 2.99 ; 151.8 ± 4.992	31.50 ± 2.646 ; 160.0 ± 4.082
T	2.954	0.504	10.71	28.15	40.47
P	0.0598ns	0.6489ns	0.0017**	0.0001***	0.0001***

Paired t test Significance: $p^* < 0.05$, $p^{**} < 0.01$, $p^{***} < 0.001$; ns=not significance; α prior treatment, ∞ immediately after treatment

This study carried out on the Aloe vera extract to evaluate its antimicrobial activities against pathogenic bacteria (Staphylococcus aureus, and E.coli.). The standard drugs used for comparison were metronidazole, ciprofloxacin and minocycline but discoloration of teeth being a disadvantage, so amoxicillin was used^[31] Macroglol and propylene glycol are specifically used to increase penetration into the dentinal tubules even in the presence of anatomical aberrations and blocked canals^[32].

Inter-group comparison of mean values of anti-microbial effects of 3trimi versus Aloe vera against E.coli were 24.25 ± 0.6455 & 5.00 ± 1.080 respectively and against *S.aureus* were 40.63 ± 1.109 & 21.75 ± 1.041 respectively. Upon using unpaired t test there was statistically significant difference $p < 0.05$ in favor of G1 regarding both bacteria tested Table 8.

The Aloe vera extract showed antibacterial effect against both gram positive and gram negative bacteria. (Staphylococcus aureus,

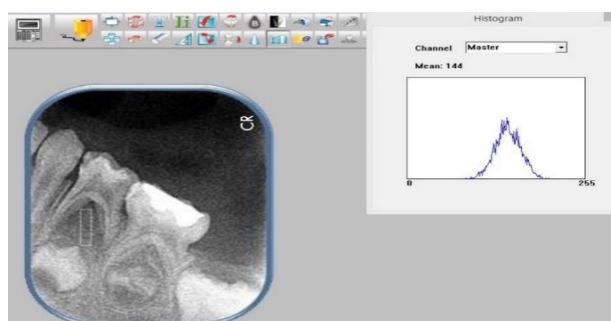


Figure 7 Radiograph imaging is showed measuring of bone density in middle of furcation region showing image software.

Table 8 Inter-group comparison between the effect of the tested materials on Escherichia coli and Staphylococcus aureus growth.

Group test microorganism	G1 M \pm SD	G2 M \pm SD	t-test	P value
E.Coli	24.25 ± 0.6455	15.00 ± 1.080	14.7	0.0001***
S.aureus	40.63 ± 1.109	21.75 ± 1.041	24.82	0.0001***

Unpaired t test Significance: $p^* < 0.05$, $p^{**} < 0.01$, $p^{***} < 0.001$; ns=not significance

and *E.coli*). Our results were comparable to the study by Bashir A *et al.*, in which Aloe vera extract was found to be 100% active against all gram negative isolates and 75.3% active against gram positive pathogens^[33]. Irshad S *et al.*, found that Aloe vera extract is effective against *Escherichia coli*, *Bacillus subtilis*, *Salmonella typhi*, *Pseudomonas*, *Klebsiella epidermidis*^[34].

The clinical success rate 3Mix was high, these findings agreed with Trairatvorakul and Detsomboonrat^[35], they reported that the clinical success rate was (75%). However this study was disagreed with the study conducted by Prabhakar *et al*^[36], Takushige *et al*^[37] and Nakornchai *et al*^[38] who reported higher clinical success rate that were (93%), (100%) and (100%) respectively; this may be related to the difference in sample size and follow up periods.

Hence, it can be concluded that the leaf extracts of Aloe Vera can effectively act as an antimicrobial agent which have ability to replace most of medium medicines of this era (Figures 8 and 9).

DISCUSSION

Root canal treatment of primary teeth remains a debated issue in Pediatric Dentistry. Success of endodontic treatment depends on mainly aseptic conditions; but residual microorganisms can cause reinfection and failure of endodontic treatment. This causes waste of time, money, energy and annoying condition for the patient and dentist. A successfully restored primary tooth is a superior space maintainer than an appliance^[39].

The successful management of chronically infected primary teeth is still a challenge owing to complex root canal system, difficulty in mechanical debridement, polymicrobial nature of infection, and root resorption. Hence, the importance of the sterilization of canal has improved the treatment prognosis. The concept of lesion sterilization and tissue repair therapy, which is a non-instrumentation endodontic treatment followed by placement of antibiotics combinations for controlling endodontic pathogens^[40].

Despite the fact that 3 Mix was effective clinically and radiographically, numerous experts stated that more study is needed to compare this procedure to traditional root canal therapy. However, the uncontrolled use of antibiotics has caused a spike in resistant strains, encouraging researchers to explore for a herbal alternative^[40].

Functional bioactive materials have received much attention in the scientific research in recent years. So, this study was conducted to assess the efficacy, release and antibacterial effect of Acemannan and 3mix antibiotics as a pulpotomy agent in non-vital primary molars.

The age group selected for this study was from four to eight years to reserve the primary molars till the time of exfoliation, as early loss of primary teeth leads to space problem. The selected cases in this study had bilateral non-vital primary lower molars to achieve the treatment on the two groups under the same environmental factors for accurate results.

In this study, propylene glycol and macrogol were used as a vehicle for better diffusion of medicaments even in the presence of anatomical aberrations and blocked canals. In addition to their germicidal efficacy, the low surface tension and the hygroscopic properties of propylene glycol improves its penetration ability and subsequently sustained release of the medicaments for prolonged periods^[41,42].

Non-vital pulpotomy has been advocated when the inflammatory process affecting the coronal pulp and extends to the radicular pulp leading to an irreversible change in the pulp tissue. Another application for this technique is when the pulp is completely non vital

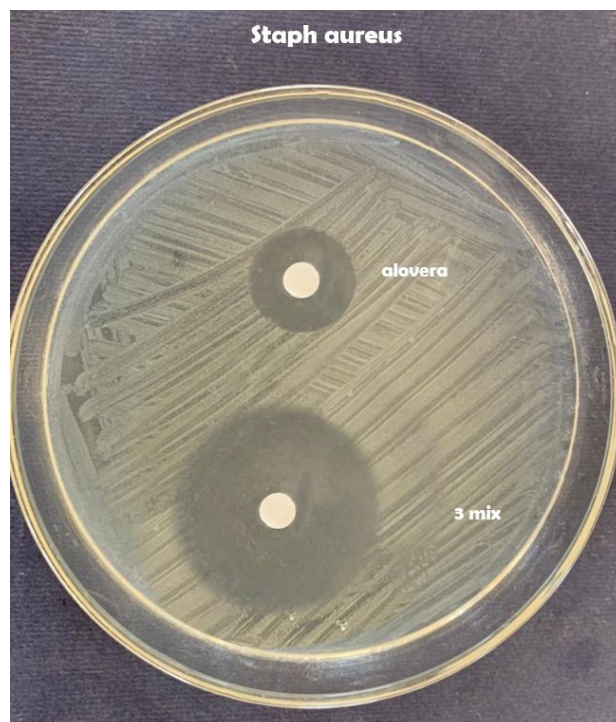


Figure 8 Muller-Hinton agar plate inoculated with *Staphylococcus aureus* shows growth inhibition zones formed by tested materials.

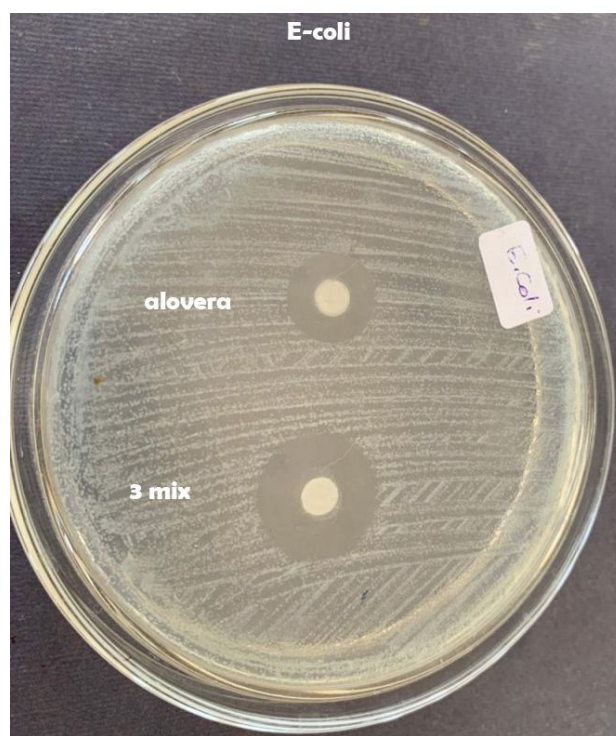

Figure 9 Muller-Hinton agar plate inoculated with *Escherichia coli* shows growth inhibition zones formed by tested materials.

with abscess formation^[43].

In this study, clinical as well as radiographic examinations were used during follow up periods. Several criteria have been used for evaluation of non vital pulpotomy agents in primary teeth, such as the presence of pain, mobility and swelling^[44] as well as the periapical or bifurcation changes and root resorption pattern was seen in radiographic periapical films^[45].

In the present study, radiographic analysis was conducted by using the computerized detection of furcation defects by gray

level detector. This method improves the detection of density changes in bony structure. It has also been used in the evaluation of the progression, arrest, or regression of the lesion because of its accuracy^[46,47].

In the present study, the overall clinical success rate of acemannan after one year was 82%. Most of the cases were clinically free from pain sensation, mobility and pain in percussion. These results may be contributed to anti-inflammatory, anti-bacterial, immunoregulatory function, healing and regenerative properties of *Aloe vera*^[48,49]. It enhance formation of a partial calcified tissue This finding is similar to the results observed in another study which demonstrated formation of dentine bridge, and soft tissue organization of the pulp in acemannan-treated group^[50].

These results are also consistent with finding of Jittapiromsak et al^[23], they found that acemannan increased pulp cell proliferation and enhance pulp tissue organization with mild or no inflammation. Further clinical and histological studies with longer follow-up till the period of tooth exfoliation are needed to ensure the efficacy of this.

This result also coincides with Khairwa et al^[22]. they found that a mixture of zinc oxide powder and *Aloe vera* gel in primary teeth has showed 93% clinical success rate when used as a root canal filling material in primary teeth in addition to Songsiripradubboon et al^[50], they reported 100% success rate of acemannan as a direct pulp capping material.

In the present study, radiographic success rate of acemannan was 82%, this results in accordance with Khairwa et al^[22]. reported 73% radiographic success rates when *Aloe vera* was mixed with zinc oxid powder as a root canal filling material in primary teeth, while Songsiripradubboon et al^[50] reported 85% radiographic success rates when acemannan was used as a direct pulp capping material in human primary teeth.

Regarding radiographic evaluation, accemanan showed better improvement in intra-radicular bone density with treatment than 3 Mix group. Failures associated with 3 Mix group can be attributed to it cannot eradicate canal infection in long term treatment modality and leaving infected material in the radicular region which should not replace the instrumentation phase^[51,52].

Additional signs of internal resorption may be the result of the remnant pulp's inflammatory response. This can cause a vascular change in the pulp, causing inflammation and the creation of granulation tissue, with subsequent internal resorption scenario^[52].

Regarding antibacterial effect, in the present study the agar disk diffusion test was used as a preliminary identification because it is the method used for routine antimicrobial susceptibility testing approved by the clinical and laboratory standards institute for bacteria and yeasts testing^[53,54]. Also, *Staphylococcus aureus* and *Escherichia coli* were selected because they are usually found in infected root canals of primary teeth^[55,56].

The 3 Mix antibiotic showed largest inhibition zone and significantly better than acemannan against *Staphylococcus aureus* and *Escherichia coli*, this result agreed with Islam et al^[57], Ghoname et al^[58] and Priya et al^[59], they reported that 3Mix showed the largest inhibition zones against *Escherichia coli* and *Staphylococcus aureus* and *Enterococcus faecalis*.

Although, 3mix showed largest inhibition zone than *Aloe vera* but it showed poor clinical and radiographical results that might indicate poor bioavailability of the drug for long time. Therefore, further microbial studies for 3mix bioavailability are highly recommended. Also the limitations of the present study is short time follow up that may affect the results and there were few studies were available for comparison.

REFERENCE

1. Takushige T, Cruz E, Hoshino E. Endodontic treatment of primary teeth using combination of antibacterial drugs. *Int Endod J* 2004; **37**: 132-138. [PMID: 14871180]; [DOI: 10.1111/j.0143-2885.2004.00771.x]
2. Carrotte P. Endodontic treatment for children. *Br Dent J* 2005; **198**: 9-15. [PMID: 15716881]; [DOI: 10.1038/sj.bdj.4811946]
3. Velling D, Captain R. A study of the treatment of infected primary teeth. *J Dent Child* 1961; **28**: 213-219.
4. Ranly D, Garsia-Gody F. Current and potential pulp therapies for primary and young permanent teeth. *J Dent* 2000; **28**: 153-161. [PMID: 10709337]; [DOI: 10.1016/s0300-5712(99)00065-2]
5. Soekanto A, Kasugai S, Matakai S, Ohya K and Ogura H. Toxicity of camphorated phenol and camphorated parachlorophenol in dental pulp cell culture. *J Endod* 1996; **6**: 284-289. [PMID: 8934985]; [DOI: 10.1016/S0099-2399(96)80259-7]
6. Hosbon P. Pulp treatment of deciduous teeth. *Br Dent J* 1970; **128**: 275-283. [PMID: 5270352]; [DOI: 10.1038/sj.bdj.4802457]
7. Hoshino E, Ando N, Sato M, Kota K. Bacterial invasion of non-exposed dental pulp. *Int Endod J* 1992; **25**: 2-5. [PMID: 1399049]; [DOI: 10.1111/j.1365-2591.1992.tb00941.x]
8. Thomson A, Kahler B. Regenerative endodontics-biologically-based treatment for immature permanent teeth: a case report and review of the literature. *Aust Dent J* 2010; **55**: 446-497. [PMID: 21133946]; [DOI: 10.1111/j.1834-7819.2010.01268.x]
9. Sato T, Hoshino E, Noda T. Invitro antimicrobial susceptibility to combination of drugs of bacteria from carious and edodontic lesions of human deciduous teeth. *Oral Microb Immunol* 1993; **8**: 172-177. [PMID: 8233571]; [DOI: 10.1111/j.1399-302x.1993.tb00661.x]
10. Al-Zayer MA, Straffon LH, Feigal RJ and Welch KB. Indirect pulp treatment of primary posterior teeth: a retrospective study. *Pediatr Dent*. 2003; **25**(1): 29-36. [PMID: 12627699]
11. Lo EH, Christopher J, Deyu VP, Wim P. Six year follow up of atraumatic restorative treatment restorations placed in Chinese school children. *Community dentistry and oral epidemiology*, 2007; **35**(5): 387-392. [PMID: 17822487]; [DOI: 10.1111/j.1600-0528.2006.00342.x]
12. De Souza EM, Daniela FG, Raquel SS, Cinthia CD and Maria F. Clinical Evaluation of the ART Technique Using High Density and Resin-Modified Glass Ionomer Cements. *Oral health & preventive dentistry*, 2003; **1**(3): 201-207. [PMID: 15641498]
13. Pinto AS, De Araujo FB, Franzon R, Figueiredo MC, Henz S, Garcia-Godoy F and Maltz M. Clinical and microbiological effect of calcium hydroxide protection in indirect pulp capping in primary teeth. *Am J Dent*, 2006; **19**(6): 382-6. [PMID: 17212082]
14. Davidovich E, Weiss E., Fuks AB and Beyth N. Surface antibacterial properties of glass ionomer cements used in atraumatic restorative treatment. *J Am Dent Assoc*, 2007; **138**(10): 1347-52. [PMID: 17908849]; [DOI: 10.14219/jada.archive.2007.0051]
15. Marchi JJ, De Araujo F B, Froner AM, Straffon LH and Nor JE. Indirect pulp capping in the primary dentition: a 4 year follow-up study. *J Clin Pediatr Dent*, 2006; **31**(2):68-71. [PMID: 17315796]; [DOI: 10.17796/jcpd.31.2.y4um5076341226m5]
16. Duque C, Negrini TC, Hebling J, Spolidorio D M. Inhibitory activity of glass-ionomer cements on cariogenic bacteria. *Oper Dent*, 2005; **30**(5): 636-40. [PMID: 16268399]
17. Loyola-Rodriguez, Garcia-Godoy F, and R. Lindquist. Growth inhibition of glass ionomer cements on mutans streptococci. *Pediatr Dent*, 1994; **16**(5): 346-9. [PMID: 7831139]
18. Tuna D and Olmez A. Clinical long-term evaluation of MTA as a direct pulp capping material in primary teeth. *Int Endod J*, 2008; **41**(4): 273-8. [PMID: 18042222]; [DOI: 10.1111/j.1365-2591.2007.01339.x]
19. Langeland KA. Comparison of pulpal response to freeze-dried

- bone, calcium-hydroxide, and zinc oxide-eugenol in primary teeth in two cynomolgus monkeys. *Pediatr Dent*, 1996; **18(3)**: 190-3. [PMID: 8784907]
20. Nakashima M. The induction of reparative dentine in the amputated dental pulp of the dog by bone morphogenetic protein. *Arch Oral Biol*, 1990; **35(7)**: 493-7. [PMID: 222252]; [DOI: 10.1016/0003-9969(90)90078-o]
 21. Rutherford RB, Wahle J, Tucker M, Rueger D and Charette M. Induction of reparative dentine formation in monkeys by recombinant human osteogenic protein-1. *Arch Oral Biol*, 1993; **38(7)**: 571-6. [PMID: 8368953]; [DOI: 10.1016/0003-9969(93)90121-2]
 22. Khairwa A, Bhat M, Sharma R, Satish V, Maganur P and Goyal A K. Clinical and radiographic evaluation of zinc oxide with aloe vera as an obturating material in pulpectomy: an in vivo study. *J Indian Soc Pedod Prev Dent*, 2014; **32(1)**: 33-8. [PMID: 24531599]; [DOI: 10.4103/0970-4388.127051]
 23. Jittapiromsak N, Sahawat D, Banlunara W, Sangvanich P and Thunyakitpisal P. Acemannan, an extracted product from Aloe vera, stimulates dental pulp cell proliferation, differentiation, mineralization, and dentin formation. *Tissue Eng Part A*, 2010; **16(6)**: 1997-2006. [PMID:20088703]; [DOI: 10.1089/ten.TEA.2009.0593]
 24. Nakornchai S, Banditsing P, Visetratana N. Clinical evaluation of 3Mix and Vitapex as treatment options for pulpally involved primary molars. *Int J Paediatr Dent* 2010; **20**: 214-221. [PMID: 20409203]; [DOI: 10.1111/j.1365-263X.2010.01044.x]
 25. Hasan O, Funda K. Effect of unintentionally extruded calcium hydroxide paste including Barium Sulfate as a radiopaquing agent in treatment of teeth with periapical lesions: Report of a case. *J Endod* 2008; **34**: 888-891. [PMID: 18571001]; [DOI: 10.1016/j.joen.2008.04.012]
 26. Islam M, Masum M, Mahub R and Haque M. Antibacterial Activity of Crab-Chitosan against Staphylococcus aureus and Escherichia coli. *J Adv Scient Res* 2011; **2(4)**.
 27. Hudzicki J. Kirby-Bauer disk diffusion susceptibility test protocol. *Am Soc Micro* 2009; **30**.
 28. Ross J, Nicole E, Flamm K and Ronald N. Determination of disk diffusion and MIC quality control guidelines for GSK2140944, a novel bacterial type II topoisomerase inhibitor antimicrobial agent. *J Clin Micro* 2014; **52(7)**: 2629-2632.
 29. Trairatvorakul C and Chunlasikawaiwan S. Success of pulpectomy with zinc oxide-eugenol vs calcium hydroxide/iodoform paste in primary molars: a clinical study. *Pediatr Dent* 2008; **30(4)**: 303-308. [PMID: 18767509]
 30. Chen K and Hollender L. Digitizing of radiographs with a flatbed scanner. *J Dent* 1995; **23(4)**: 205-208. [PMID: 7629323]; [DOI: 10.1016/0300-5712(95)91183-n]
 31. Chakraborty B, Nayak A and Rao A, Efficacy of Lesion Sterilization and Tissue Repair in Primary Tooth with Internal Resorption: A Case Series. *Contemp Clin Dent* 2018; **9(2)**: 361-364.
 32. Cruz E, Kota K, Huque J, Iwaku M and Hoshino E. Penetration of propylene glycol into dentine. *Int Endodo J* 2002; **35(4)**: 330-336.
 33. Bashir A, Saeed B, Mujahid TY, Jehan N. Comparative study of antimicrobial activities of aloe vera extracts and antibiotics against isolates from skin infections. *Afr J Biotechnol*. 2011; **10**: 3835-40.
 34. Irshad S, Butt M, Yonus H. In-vitro antibacterial activity of aloe barbadensis miller. *Int Res J Pharmaceuticals*. 2011; **1**: 59-64.
 35. Trairatvorakul C and Detsomboonrat. Success rates of a mixture of ciprofloxacin, metronidazole, and minocycline antibiotics used in the noninstrumentation endodontic treatment of mandibular primary molars with carious pulpal involvement. *Int J Paediatr Dent* 2012; **22(3)**: 217-227.
 36. Prabhakar A, Sridevi E, Raju O and Satish V. Endodontic treatment of primary teeth using combination of antibacterial drugs: An in vivo study. *J Indian Soc Pedod Prev Dent* 2008; **26(5)**: 5-7.
 37. Takushige T, Cruz E, Asgor M and Hoshino E. Endodontic treatment of primary teeth using a combination of antibacterial drugs. *Int Endod J* 2004; **37(2)**: 132-138.
 38. Nakornchai S, Banditsing P and Visetratana N. Clinical evaluation of 3Mix and Vitapex as treatment options for pulpally involved primary molars. *Int J Paediatr Dent* 2010; **20(3)**: 214-221.
 39. Carrotte V. A clinical guide to endodontics. *Brit Dent J* 2009; **206(2)**: 79-84. [PMID: 19165263]; [DOI: 10.1038/sj.bdj.2009.6]
 40. Reddy G, Sridevi E, Sankar A, Pranitha K. Pratap S and Vinay C. Endodontic treatment of chronically infected primary teeth using triple antibiotic paste: An in vivo study. *J Conserv Dent* 2017; **20(6)**: 405-410. [PMID: 29430091 PMCID: PMC5799985]; [DOI: 10.4103/JCD.JCD_161_17]
 41. Oltizky I. Antimicrobial properties of a propylene glycol based topical therapeutic agent. *J Pharm Sci* 1965; **54**: 787-788. [PMID: 5845896]; [DOI: 10.1002/jps.2600540528]
 42. Tasman F, Cehreli ZC, OganC, Etikan I. Surface tension of root canal irrigants. *J Endod* 2000; **26**: 586-587. [PMID: 11199798]; [DOI: 10.1097/00004770-200010000-00002]
 43. Llewelyn D. UK national clinical guidelines in paediatric dentistry. The pulp treatment of the primary dentition. *Int J Paediatr Dent* 2000; **10(3)**: 248-252. [PMID: 11310120]; [DOI: 10.1046/j.1365-263x.2000.00223.x]
 44. Trairatvorakul C and Chunlasikawaiwan S. Success of pulpectomy with zinc oxide-eugenol vs calcium hydroxide/iodoform paste in primary molars: a clinical study. *Pediatr Dent* 2008; **30(4)**: 303-308. [PMID: 18767509]
 45. Chen K and Hollender L. Digitizing of radiographs with a flatbed scanner. *J Dent* 1995; **23(4)**: 205-208. [PMID: 7629323]; [DOI: 10.1016/0300-5712(95)91183-n]
 46. Nummikoski PV, Steffensen B. Clinical validation of a new subtraction radiography technique for periodontal bone loss detection. *J Periodontol* 2000; **71**: 598-605. [PMID: 10807124]; [DOI: 10.1902/jop.2000.71.4.598]
 47. Ortman MF, Dunford R. Subtraction radiography and computer assisted densitometric analyses of standardized radiographs: a comparison study with absorptiometry. *J Periodontal Res* 1985; **20**: 644-651. [PMID: 2935619]; [DOI: 10.1111/j.1600-0765.1985.tb00849.x]
 48. Reynolds T and Dweck AC. Aloe vera leaf gel: a review update. *J Ethnopharmacol*. 1999; **68(1-3)**: 3-37. [PMID:10624859]
 49. Hamman J. Composition and applications of Aloe vera leaf gel. *Molecules*. 2008; **13(8)**: 1599-616. [PMID:18794775]; [PMCID: PMC6245421]
 50. Songsiripraduboon SB, Sangvanich W, Trairatvorakul P, Thunyakitpisal C. Clinical, radiographic, and histologic analysis of the effects of acemannan used in direct pulp capping of human primary teeth: short-term outcomes. *Odontology*, 2016; **104(3)**: 329-37. [PMID:26264630]; [DOI:10.1007/s10266-015-0215-4]
 51. Parhizkar A, Nojehdehian H, Asgary S. Triple antibiotic paste: momentous roles and applications in endodontics: a review. *Restorative dentistry & endodontics*. 2018 Apr 26; **43(3)**. [PMID: 30135847]; [PMCID: PMC6103545]; [DOI: 10.5395/rde.2018.43.e28]
 52. Trairatvorakul, C. and Detsomboonrat, P., 2012. Success rates of a mixture of ciprofloxacin, metronidazole, and minocycline antibiotics used in the non-instrumentation endodontic treatment of mandibular primary molars with carious pulpal involvement. *International journal of paediatric dentistry*. **22(3)**: pp.217-227. [PMID: 21951271]; [DOI: 10.1111/j.1365-263X.2011.01181.x]
 53. Richardson H, Emslie H and Senior B. Agar diffusion method for the assay of colicins. *Appl Microbiol* 1968; **16(10)**:1468-1474. [PMID: 4879211]; [PMCID: PMC547686]; [DOI: 10.1128/am.16.10.1468-1474.1968]
 54. Bonev B, Hooper J and Parisot J. Principles of assessing bacterial susceptibility to antibiotics using the agar diffusion method. *J antimicrob chemother* 2008; **61(6)**: 1295-1301. [PMID: 18339637]; [DOI: 10.1093/jac/dkn090]
 55. Hegde A and Lakshmi P. Prevalence of selected microorganisms

- in the pulp space of human deciduous teeth with irreversible pulpitis. *Endodo J* 2013; **25**(1): 107-111.
56. Ercan E, Dalli M, Yavuz I and Ozekinci T. Investigation of microorganisms in infected dental root canals. *Biotechnol & Biotechnol Eq J* 2014; **20**(6): 166-172.
57. Islam M, Masum M, Mahub R and Haque M. Antibacterial Activity of Crab-Chitosan against *Staphylococcus aureus* and *Escherichia coli*. *J Adv Scient Res* 2011; 2(4).
58. Ghoname N and Afifi T. clinical, radiographical and antibacterial evaluation of 3 Mix as a root canal filling material of primary teeth. *Egypt Dent J* 2013; **59**: 87-115.
59. Harini M, Bhat S and Sundeep K. Comparative evaluation of bactericidal potential of four root canal filling materials against microflora of infected non-vital primary teeth. *J Clin Pediatr Dent* 2010; **35**(1): 23-29. [PMID: 21189760]; [DOI: 10.17796/jcpd.35.1.u57p4500360g2752]