

Acute Liver Ischemia Secondary to Acute Severe Pancreatitis: A Case Report

Chun-Wun Marten Lau¹, MBChB; Catherine Wing-Yan Tam², MBChB; Hoi-Ping Shum¹, FHKCP

1 Department of Intensive Care, Pamela Youde Nethersole Eastern Hospital, 3 Lok Man Road, Chai Wan, Hong Kong SAR, China;

2 Department of Radiology, North District Hospital, 9 Po Kin Road, Sheung Shui, Hong Kong SAR, China.

Conflict-of-interest statement: The authors declare that there is no conflict of interest regarding the publication of this paper.

Open-Access: This article is an open-access article which was selected by an in-house editor and fully peer-reviewed by external reviewers. It is distributed in accordance with the Creative Commons Attribution Non Commercial (CC BY-NC 4.0) license, which permits others to distribute, remix, adapt, build upon this work non-commercially, and license their derivative works on different terms, provided the original work is properly cited and the use is non-commercial. See: <http://creativecommons.org/licenses/by-nc/4.0/>

Correspondence to: Chun-Wun Marten Lau, MBChB, Department of Intensive Care, Pamela Youde Nethersole Eastern Hospital, 3 Lok Man Road, Chai Wan, Hong Kong SAR, China.

Email: martenlau@gmail.com

ORCID: 0000-0001-8104-2322

Received: August 10, 2021

Revised: September 1, 2021

Accepted: September 3, 2021

Published online: October 21, 2021

ABSTRACT

Splanchnic venous thrombosis is one of the known vascular complications of acute pancreatitis. However, acute liver ischemia is rare, and we hereby present a unique case of acute necrotizing pancreatitis leading to acute liver ischemia and decompensated hepatic failure. This case demonstrates vascular complications with serial computed tomography and explores the potential benefit of extracorporeal blood purification in severe pancreatitis.

Key words: Pancreatitis; Hepatic infarction; Mesenteric ischemia

© 2021 The Authors. Published by ACT Publishing Group Ltd. All rights reserved.

Lau CWM, Tam CWY, Shum HP. Acute Liver Ischemia Secondary to Acute Severe Pancreatitis: A Case Report. *Journal of Gastroenterology and Hepatology Research* 2021; **10(5)**: 3599-3603 Available from: URL: <http://www.ghrnet.org/index.php/joghr/article/view/3219>

INTRODUCTION

Splanchnic venous thrombosis is one of the known vascular complications of acute pancreatitis (AP)^[1]. It may involve the splenic vein (SV), portal vein (PV) and superior mesenteric vein (SMV), either separately or in combination. Complications including upper gastrointestinal bleeding, bowel ischemia and hepatic decompensation (jaundice, ascites, and hepatic encephalopathy) have been reported. Its pathogenesis is largely attributed to local and systemic inflammation. Management relies on the treatment of the underlying AP. The use of anticoagulation therapy lacks consensus due to an increased risk of bleeding. The literature on anticoagulation therapy in the setting of AP is lacking. This report presents a case of acute pancreatitis resulting in acute liver ischemia that led to hepatic failure, a scenario that is rarely reported in the literature.

CASE PRESENTATION

A 47-year-old woman initially presented to the emergency department in February 2021, with complaints of abdominal pain for 1 day. She had a history of pancreatitis with subsequent cholecystectomy performed at the age of 39, and the clinical details of the last episode of pancreatitis were unclear. The patient described the pain as generalized severe abdominal pain, with the pain worst in the epigastric region. The patient did not have a history of smoking, alcohol consumption or herbal medicine use.

On admission, her serum amylase level was 1826 IU/L (normal range: < 125 UI/L), with a hemoglobin level of 11.8 g/dL, total leukocyte count of $22.76 \times 10^9/L$ (normal range $3.7-9.3 \times 10^9/L$), aspartate aminotransferase level of 66 IU/L (normal range < 40 IU/L), lactate dehydrogenase level of 683 IU/L (normal range 128-245 IU/L), and triglyceride level of 19.4 mmol/L (normal < 1.7 mmol/L). Alanine aminotransferase, total alkaline phosphatase, and total bilirubin levels and renal function were normal. An abdominal computed tomography (CT) scan revealed gross diffuse swelling of the pancreas with adjacent fluid, without gross focal liver mass lesion or common duct stone. Intrahepatic and common ducts were not

dilated.

Subsequently, she entered hypovolemic shock with acute kidney injury and was transferred to the intensive care unit 1 day after admission. She was given fluid replacement and empirical meropenem therapy. Blood purification using endotoxin/cytokine hemoabsorptive continuous venovenous hemofiltration (CVVH) (oXiris, Gambro Hospal, Sweden) connected in series with MG-350 cytokine hemoabsorptive cartilage (MG-350; Foshan Biosun Group, Biological Material Co., Ltd., Foshan, Guangdong, China) was started. Hypertriglyceridemia was managed with intravenous insulin infusion and gemfibrozil. After 24 hours, the abdominal pain worsened, and blood results revealed acute liver failure, with the alanine aminotransferase level raised to 1440 IU/L and an international normalized ratio of 2.7. The C-reactive protein (CRP) level was 243 mg/L (normal range ≤ 5 mg/L), while intraabdominal pressure was raised to 17 mmHg. Abdominal CT imaging with contrast was repeated and showed necrotizing pancreatitis (Figure 1). A hypofilling defect was noted within the entire splenic vein with a nonocclusive thrombus in the SMV just proximal to the portal venous confluence (Figure 2). The left main portal vein was narrowed, while the main portal vein and right portal vein were patent without sizable filling defects. Acute ischemia was noted in the left lobe of the liver (Figure 3).

She was treated with acetylcysteine infusion for liver protection from day 2 to day 6 and continued on extracorporeal blood purification therapy from day 3 to day 8. She made gradual improvement over this period in terms of inflammatory marker levels, with the CRP level dropping from 243 mg/L to 164 mg/L, intraabdominal pressure decreasing from 23 mmHg to 12 mmHg, and improved liver and renal function. Blood purification and renal replacement therapy were stopped on day 8. Interval abdominal CT imaging on day 8 showed a thrombosed splenic vein, lower main portal vein and upper superior mesenteric vein (Figure 4). The splenic infarct showed interval improvement (Figure 5).

Her clinical course was further complicated with perforation of the distal descending colon on day 13, which was treated with partial colectomy and loop ileostomy. She was transferred from the intensive care unit to the general ward on day 30 and subsequently to private care to continue postoperative care and rehabilitation.

DISCUSSION

Peripancreatic vascular complications due to severe acute pancreatitis are well documented in the literature. Although reported incidences of pancreatitis-induced splanchnic vein thrombosis (PISVT) vary widely across studies, an overall incidence of 14.1% is reported, with mean incidences varying from 22.6% in patients with acute pancreatitis to 12.4% in patients with chronic pancreatitis^[2]. While the portal vein (PV), splenic vein (SV) and superior mesenteric vein (SMV) are involved either in combination or separately, the incidence of SV thrombosis ranks highest, followed by PV and SMV involvement^[3]. Acute liver ischemia resulting from PISVT is rarely reported due to the unique hepatic vascular configuration^[4-6]. The liver possesses a dual arterial and portal blood supply, in addition to a rich network of intra- and extrahepatic collateral arteries. A complex compensatory mechanism exists in cases of reduced or absent blood flow. Our patient without a history of a previous thrombotic event was found to have extensive splanchnic vein thrombosis, which led to liver ischemia and infarction.

The pathogenesis of PISVT is multifactorial, with pancreatic and peripancreatic inflammation being a major factor. Disruption

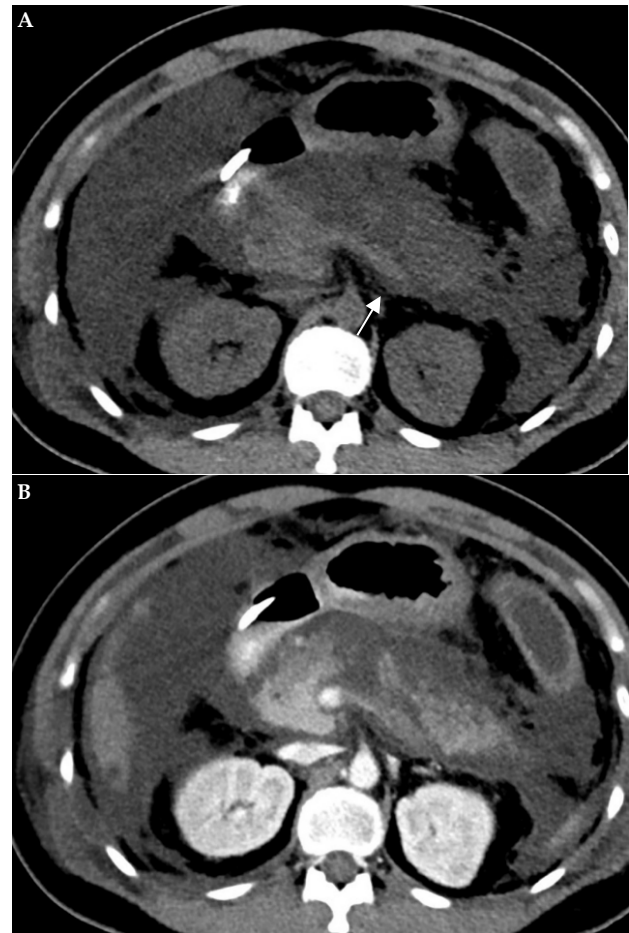


Figure 1 Abdominal CT imaging at presentation on precontrast (A) and postcontrast (B) scans. The pancreas was diffusely edematous with patchy hypoenhancing areas in the pancreatic body suggestive of necrotizing pancreatitis. There was a highly dense area without contrast enhancement in the splenic vein due to thrombosis (arrow).

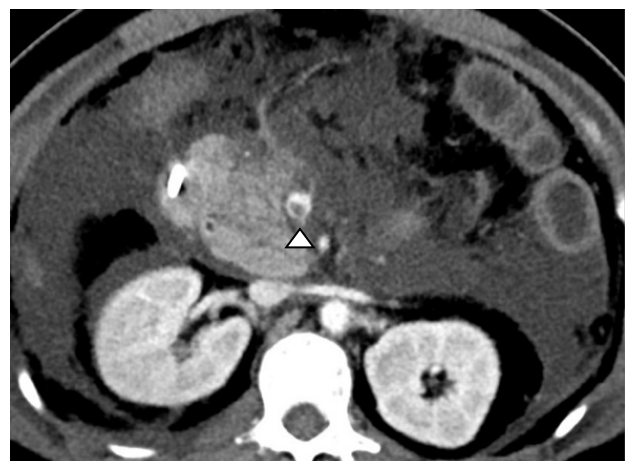


Figure 2 Abdominal contrast-enhanced CT imaging at presentation showing a nonocclusive thrombus in the superior mesenteric vein (arrowhead).

of pancreatic tissue and compression of vessels by local collection initiates inflammation, followed by cellular infiltration, edema and a coagulation cascade, subsequently leading to platelet deposition and fibrin formation^[7,8]. Experimental studies have demonstrated an increased risk of splanchnic and extrasplenic venous thrombosis caused by a systemic hypercoagulable state in AP due to the effects of inflammatory mediators such as TNF, IL-1 and IL-6^[9,10]. A study

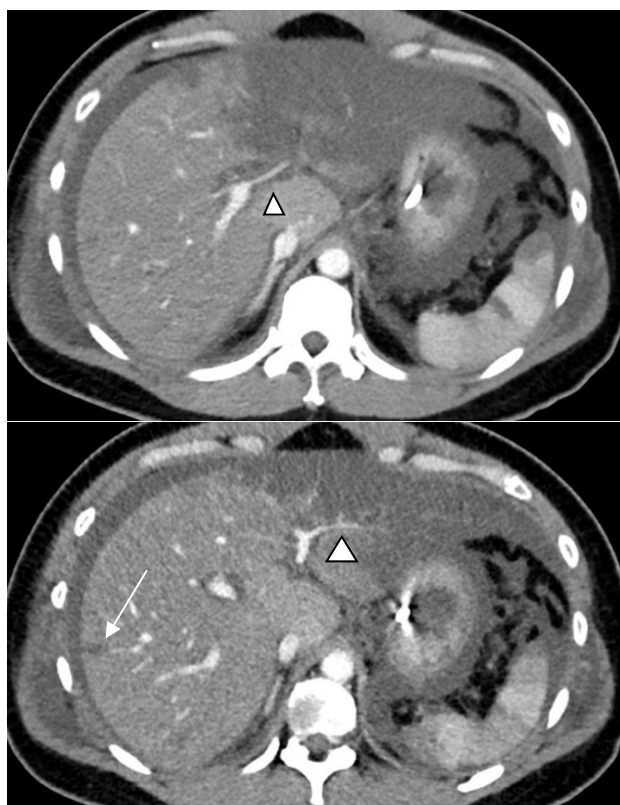


Figure 3 Abdominal contrast-enhanced CT imaging at presentation on selected slices showing narrowing of the left portal vein (arrowhead). Ill-defined areas of hypoenhancement in the left liver lobe and smaller areas in the right liver lobe (arrow) suggest hypoperfusion. Note that there are also wedged-shaped hypoenhancing areas in the spleen, also suggesting hypoperfusion.

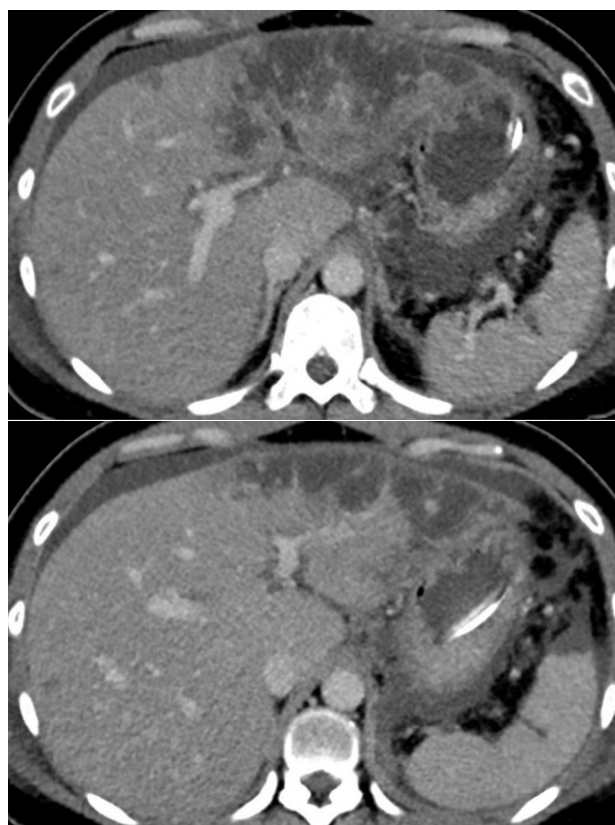


Figure 4 Course of the hypoperfused area on contrast-enhanced CT imaging performed on day 8 after admission. The left portal vein is less narrowed, with an improved extent of hypoenhancement in the left liver lobe, although persistent areas of hypoenhancement suggest ischemia/infarction.

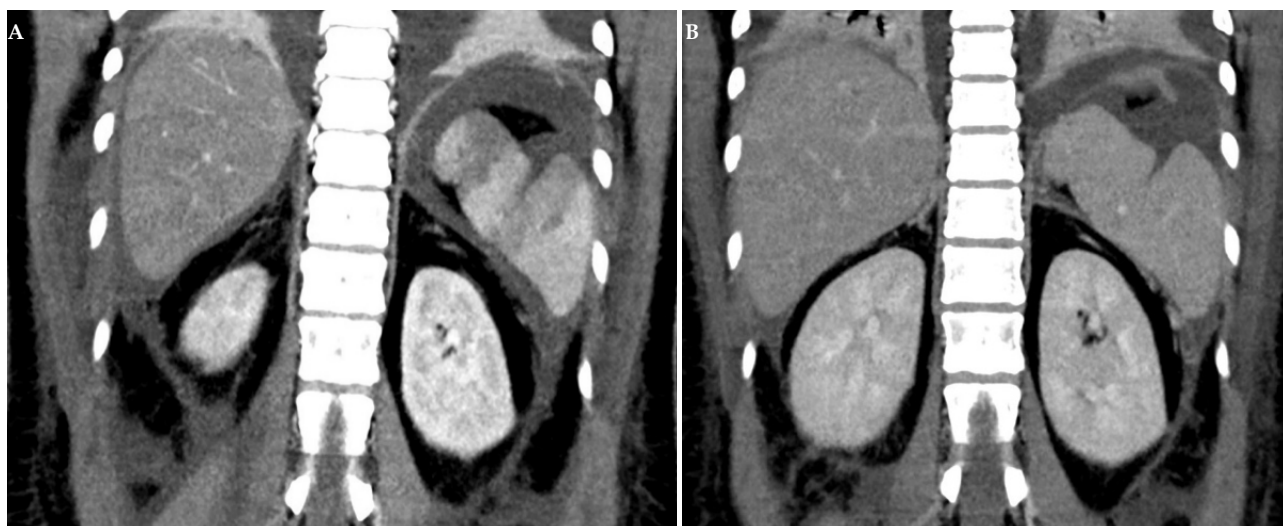


Figure 5 Coronal reformatted image of a contrast-enhanced CT scan of the abdomen. The hypoperfused areas in the spleen were improved on contrast-enhanced CT scan on day 8 (B) compared with those on admission (A).

found that markers of disease severity, including C-reactive protein (CRP), bedside index for severity in acute pancreatitis (BISAP) score, acute physiology and chronic health evaluation (APACHE) II score, modified CT severity index (mCTSI) value and revised Atlanta class, were significantly higher in patients with PISVT than in the non-SVT group subjects, supporting the hypothesis of an elevated inflammatory response^[11].

Doppler ultrasonography is regarded as the first-line diagnostic tool for splanchnic vein thrombosis due to its high accuracy (81%

sensitivity and 93% specificity) and wide availability^[12]. However, in the setting of pancreatitis with a distended abdomen, the technical difficulty of ultrasonography is anticipated. Computed tomographic venography is another diagnostic modality for the detection of splanchnic vein thrombosis in necrotizing acute pancreatitis, with 100% sensitivity (95% CI: 77.1%-100%) and 92.3% specificity (95% CI: 73.4%-98.7%)^[13]. The emergence of contrast-enhanced multidetector CT (MDCT) and dynamic magnetic resonance (MR) imaging has recently enabled more detailed hepatic hemodynamic

assessments. In cases of hepatic infarct, the newly introduced gadoxetate disodium is a biphasic hepatobiliary MR contrast agent that offers excellent diagnostic accuracy and can delineate the exact area of involvement and assess hepatocellular function^[6].

Initial management consists of treatment of the underlying cause of acute pancreatitis and supportive care, which could result in spontaneous resolution of thrombosis. There are no randomized controlled trials (RCTs) to guide the management of PISVT. Anticoagulants are commonly prescribed in patients with portal venous thrombosis due to causes other than acute pancreatitis given that they might improve the recanalization rate^[14]. However, gastric variceal bleeding from pancreatitis-induced splenic vein thrombosis and portal hypertension might occur. Butler *et al* reported a strikingly high rate of esophagogastric varices (53.0%) in patients with PISVT^[2]. Moreover, patients with acute necrotizing pancreatitis frequently require interventions, and the use of anticoagulation increases bleeding risk during the procedures. Therefore, there is no consensus on the initiation of anticoagulation as a treatment for PISVT. The risk of bleeding and thrombotic complications should be balanced^[1,3,11]. On the other hand, routine splenectomy for PISVT is not indicated given the low incidence of gastric variceal hemorrhage (4%) and the absence of mortality related to variceal hemorrhage^[2]. Based on the above consideration, anticoagulation was not prescribed in our patient.

Hemoabsorptive therapies were given as supportive treatment in our patient because of the fulminant hyperinflammatory state leading to vascular complications and organ dysfunction. Extracorporeal blood purification (EBP) therapies have been proposed to improve the outcome for patients with severe sepsis^[15,16]. The underlying principle is the removal of excessive inflammatory mediators such as tumor necrosis factor- α (TNF- α), interleukin-1 (IL-1), IL-6, IL-8 and IL-10 to modulate the cytokine storm, which could also occur in severe trauma, extensive burns, acute necrotizing pancreatitis, and post-cardiac arrest status. Hemoabsorption is an EBP technique. Sorbents are placed in series and in direct contact with blood via an extracorporeal circuit. These sorbents consist of microfibers or resin-covered beads, enabling them to bind cytokines, chemokines, superantigens, or endotoxins employing hydrophobic interactions, van der Waals forces, or ionic interactions^[17]. Many experimental and pilot clinical studies have reported promising results showing that EBP is well tolerated, effective in clearing inflammatory mediators in plasma and leading to improvement of physiologic parameters^[18]. However, large-scale, prospective RCTs to provide sustainable mortality benefits are still lacking^[19], and ongoing studies are more focused on sepsis than other causes of cytokine storms.

CONCLUSION

We presented a rare case of acute pancreatitis complicated with acute liver ischemia. The mainstay of management was supportive treatment. This report illustrated the potential benefit of extracorporeal blood purification, but more specific recommendations must await further evidence.

Informed Consent

We asked the patient to help us publish the case report in an international journal for discussion, including disease symptoms, diagnosis, and image-related content. Consent was obtained from the patient for their anonymized information to be published. A written consent form was signed by the patient.

CARE Checklist (2016) statement

The authors have read the CARE Checklist (2016), and the manuscript was prepared and revised according to the CARE Checklist (2016).

ACKNOWLEDGMENT

Authors' contributions: CW was responsible for the care of the reported patients, carried out the primary literature search and data collection, and drafted the manuscript. WY contributed to imaging selection, editing, and explanation. HP contributed to the literature review and drafting of the manuscript. All authors revised the manuscript.

REFERENCES

- Heider TR, Azeem S, Galanko JA, Behrns KE. The Natural History of Pancreatitis-Induced Splenic Vein Thrombosis. *Annals of Surgery*. 2004 Jun; **239**(6): 876-80. [PMID: 1356296]; [DOI: 10.1097/01.sla.0000128685.74686.1e]
- Butler JR, Eckert GJ, Zyromski NJ, Leonardi MJ, Lillemoie KD, Howard TJ. Natural history of pancreatitis-induced splenic vein thrombosis: a systematic review and meta-analysis of its incidence and rate of gastrointestinal bleeding. *HPB (Oxford)*. 2011 Dec; **13**(12): 839-45. [PMID: 3244622]; [DOI: 10.1111/j.1477-2574.2011.00375.x]
- Gonzelez HJ, Sahay SJ, Samadi B, Davidson BR, Rahman SH. Splanchnic vein thrombosis in severe acute pancreatitis: a 2-year, single-institution experience. *HPB (Oxford)*. 2011 Dec; **13**(12): 860-4. [PMID: 3244624]; [DOI: 10.1111/j.1477-2574.2011.00392.x]
- Gonzales Aguilar JD, Ramia Angel JM, de la Plaza Llamas R, Kuhnhardt Barrantes AW, Ramiro Perez C, Valenzuela Torres J del C, Garcia-Amador C, Lopez-Marciano AJ. Trombosis portal y necrosis hepática: complicación excepcional de la pancreatitis aguda. *Gastroenterol Hepatol*. 2017 Feb; **40**(2): 88-90. [PMID: 26960734]; [DOI: 10.1016/j.gastrohep.2016.01.006]
- Lev-Toaff A, Friedman A, Cohen L, Radecki P, Caroline D (1987) Hepatic infarcts: new observations by CT and sonography. *American Journal of Roentgenology* 1987 Jul; **149**(1): 87-90. [PMID: 3296715]; [DOI: 10.2214/ajr.149.1.87]
- Maruyama M, Yamada A, Kuraishi Y, Shibata S, Fukuzawa S, Yamada S, Arakura N, Tanaka E, Kadoya M, Kawa S. Hepatic Infarction Complicated with Acute Pancreatitis Precisely Diagnosed with Gadoxetate Disodium-enhanced Magnetic Resonance Imaging. *Internal Medicine*. 2014; **53**(19): 2215-21. [PMID: 25274233]; [DOI: 10.2169/internalmedicine.53.2395]
- Nadkarni NA, Khanna S, Vege SS. Splanchnic Venous Thrombosis and Pancreatitis. *Pancreas* 2013 Aug; **42**(6): 924-31. [PMID: 23587854]; [DOI: 10.1097/MPA.0b013e318287cd3d]
- Mendelson RM, Anderson J, Marshall M, Ramsay D. Vascular complications of pancreatitis. *ANZ Journal of Surgery*. 2005 Dec; **75**(12): 1073-9. [PMID: 16398814]; [DOI: 10.1111/j.1445-2197.2005.03607.x]
- Lasson Å, Ohlsson K. Disseminated Intravascular Coagulation and Antiprotease Activity in Acute Human Pancreatitis. *Scandinavian Journal of Gastroenterology* 1986; **126**: 35-9. [PMID: 2436283]; [DOI: 10.3109/00365528609091890]
- Lasson Å, Ohlsson K. Consumptive coagulopathy, fibrinolysis and protease antiprotease interactions during acute human pancreatitis. *Thrombosis Research* 1986; [DOI: 10.1016/0049-3848(86)90227-6]
- Junare PR, Udgirkar S, Nair S, Debnath P, Jain S, Modi A, Rathi P, Rane S, Contractor Q. Splanchnic Venous Thrombosis in Acute Pancreatitis: Does Anticoagulation Affect Outcome? *Gastroenterology Research*. 2020 Feb; **13**(1): 25-31. [PMID: 32095170]; [PMCID: PMC7011913]; [DOI: 10.14740/gr1223]

12. Valeriani E, Riva N, di Nisio M, Ageno W. Splanchnic Vein Thrombosis: Current Perspectives. *Vascular Health and Risk Management* 2019 Oct 22; **15**: 449-461. [PMID: 31695400]; [PMCID: PMC6815215]; [DOI: 10.2147/VHRM.S197732]
13. Jiang W. Splanchnic vein thrombosis in necrotizing acute pancreatitis: Detection by computed tomographic venography. *World Journal of Gastroenterology*. 2014 Nov 28; **20(44)**: 16698-701. [PMID: 25469039]; [PMCID: PMC4248214]; [DOI: 10.3748/wjg.v20.i44.16698]
14. Ponziani FR Portal vein thrombosis: Insight into physiopathology, diagnosis, and treatment. *World Journal of Gastroenterology*. 2010 Jan 14; **16(2)**: 143-55. [PMID: 20066733]; [PMCID: PMC2806552]; [DOI: 10.3748/wjg.v16.i2.143]
15. Kogelmann K, Jarczak D, Scheller M, Drüner M. Hemoadsorption by CytoSorb in septic patients: a case series. *Critical Care*. 2017 Mar 27; **21(1)**: 74 [PMID: 28343448]; [PMCID: PMC5366999]; [DOI: 10.1186/s13054-017-1662-9]
16. Hawchar F, László I, Öveges N, Trásy D, Ondrik Z, Molnar Z. Extracorporeal cytokine adsorption in septic shock: A proof of concept randomized, controlled pilot study. *Journal of Critical Care* 2019 Feb; **49**: 172-178. [PMID: 30448517]; [DOI: 10.1016/j.jcrc.2018.11.003]
17. Winchester JF, Kellum JA, Ronco C, Brady JA, Quartararo PJ, Salsberg JA, Levin NW. Sorbents in Acute Renal Failure and the Systemic Inflammatory Response Syndrome. *Blood Purification* 2003; **21(1)**: 79-84. [PMID: 12566666]; [DOI: 10.1159/000067860]
18. Rimmel T, Kellum JA. Clinical review: Blood purification for sepsis. *Critical Care* 2011; **15(1)**: 205. [PMID: 21371356]; [PMCID: PMC3222040]; [DOI: 10.1186/cc9411]
19. Shum H, Yan W, Chan T. Extracorporeal blood purification for sepsis. *Hong Kong Medical Journal*. 2016 Oct; **22(5)**: 478-85. [PMID: 27538388]; [DOI: 10.12809/hkmj164876]