

The Optimal Metallic Stents for Malignant Distal Biliary Strictures: According to a Primary Disease and Axial Force

Masafumi Maruyama, Takashi Muraki, Norikazu Arakura, Suguru Yoneda, Tetsuya Ito, Takayuki Watanabe, Masahiro Maruyama, Kazunobu Miyata, Hiroyasu Ushimaru, Shigeyuki Kawa, Eiji Tanaka

Masafumi Maruyama, Takashi Muraki, Norikazu Arakura, Suguru Yoneda, Tetsuya Ito, Takayuki Watanabe, Masahiro Maruyama, Eiji Tanaka, Department of Gastroenterology, Shinshu University School of Medicine, 3-1-1 Asahi, Matsumoto 390-8621, Japan
Shigeyuki Kawa, Center for Health, Safety and Environmental Management, Shinshu University School of Medicine, 3-1-1 Asahi, Matsumoto 390-8621, Japan

Kazunobu Miyata, Department of Gastroenterology, Aizawa Hospital, 2-5-1 Honjou, Matsumoto 390-8510, Japan

Hiroyasu Ushimaru, Department of Gastroenterology, Shinonoi General Hospital, 666-1 shinonoi-ai, Nagano 388-8004, Japan

Correspondence to: Takashi Muraki, MD, PhD, Department of Medicine, Gastroenterology, Shinshu University School of Medicine, 3-1-1 Asahi, Matsumoto 390-8621, Japan. muraki@shinshu-u.ac.jp

Telephone: +081-263-37-2634 Fax: +081-263-32-9412

Received: October 3, 2012 Revised: December 1, 2012

Accepted: December 4, 2012

Published online: March 21, 2013

impaction and prolong stent patency periods.

© 2013 ACT. All rights reserved.

Key words: Self-expandable metallic stent; Distal malignant biliary stricture; Axial force; Stent patency; Bile duct carcinoma

Maruyama M, Muraki T, Arakura N, Yoneda S, Ito T, Watanabe T, Maruyama M, Miyata K, Ushimaru H, Kawa S, Tanaka E. The Optimal Metallic Stents for Malignant Distal Biliary Strictures: According to a Primary Disease and Axial Force. *Journal of Gastroenterology and Hepatology Research* 2013; 2(3): 458-463 Available from: URL: <http://www.ghrnet.org/index./joghr/>

INTRODUCTION

Transpapillary endoscopic biliary stent placement was reported as a means of biliary drainage for malignant distal biliary strictures in 1980^[1] and has since become widespread. As to stents used for implantation, plastic stents were reported in 1981^[2], and then metallic stents in 1989^[3,4]. For unresectable malignant distal biliary strictures, metallic stent placement is reported to prolong stent patency periods^[5], cause fewer complications, and incur lower medical costs than plastic stents^[6]. At present, metallic stents are widely used. In recent years, long-term survival has been observed, even in patients with cancer of the pancreato-biliary system, due to advances in chemotherapy^[7,8]. Thus, control with biliary drainage is an important issue. However, when tumor over-growth or in-growth, stent displacement or migration, or food impaction after metallic stent placement impairs bile flow, subsequent occurrence of cholangitis or obstructive jaundice reduces patient quality of life (QOL).

In recent years, various types of metallic stents^[9,10,11,12] which differ in terms of the presence of covering materials, expansion force (radial force), and straightening force (axial force: AF) have become commercially available. There have been few reports on the use of different metallic stents according to primary diseases associated with unresectable malignant distal biliary strictures.

Regarding transpapillary placement of metallic stents for malignant distal biliary strictures, the presence or absence of covering materials has been widely investigated. Although there is a meta-analysis showing longer patency periods for covered metallic stents^[13], no difference was observed in patency periods between covered and uncovered stents in some reports^[14,15]. Thus, no

ABSTRACT

AIM: Primary diseases for malignant distal biliary strictures vary, and many metallic biliary stent types are marketed. This study aimed to investigate factors, including axial force (AF), which affect patency periods of metallic biliary stents placed for malignant distal biliary strictures according to primary diseases.

METHODS: This retrospective study involved 198 patients (114 with pancreatic head carcinoma, 53 with bile duct carcinoma, 24 with metastasis, and 7 with papillary carcinoma) who underwent metallic biliary stent placement for unresectable malignant distal biliary strictures at our department and 2 neighboring institutions between January 2001 and February 2011.

RESULTS: Employing multivariate analysis, diseases and stent types were extracted as factors affecting stent patency periods. There were no significant differences among stent types in biliary strictures due to pancreatic head carcinoma and lymph node metastasis. For bile duct carcinoma, stent patency periods and AF correlated positively (correlation coefficient, 0.92). Stent non-occlusion periods associated with food impaction as a cause for occlusion showed a positive correlation with AF (correlation coefficient, 0.89).

CONCLUSIONS: For unresectable distal bile duct carcinoma, metallic stents with high AF may prevent stent occlusion due to food

consensus has been reached.

On the other hand, AF varies among types of metallic stents by a factor at least 23 times, whereas RF is a difference only for 6 times for it^[16]. Because AF differs widely among various stents, the shape of a stent after placement varies markedly among stent types. For malignant hilar biliary strictures, stent patency periods are reported to be longer with stents having lower AF^[17]. However, there are no studies, to our knowledge, focusing on the association between stent patency periods and AF in patients with malignant distal strictures.

Moreover, primary diseases associated with unresectable malignant distal biliary strictures vary, and these include strictures due to pancreatic head carcinoma, bile duct carcinoma, carcinoma of the ampulla of Vater, and lymph node metastasis. Strictures due to pancreatic head carcinoma or lymph node metastasis are caused by extrinsic compression of the bile duct. Because pancreatic carcinoma especially causes severe fibrosis, the bile duct is markedly displaced. Moreover, there are cases in which the bile duct epithelium is preserved. On the other hand, shift of the bile duct is rarely observed in bile duct carcinoma. Thus, the optimal metallic stents for placement may vary among primary diseases.

This study aimed to investigate unresectable malignant distal biliary strictures according to primary diseases and to analyze factors, including AF, which affect stent patency periods.

METHODS

Patients

The subjects were selected from endoscopic retrograde cholangiopancreatography (ERCP) databases of our department and 2 institutions and retrospectively evaluated. Out of 6923 consecutive patients undergoing ERCP at these 3 institutions between January 2001 and February 2011, we studied all 198 with malignant strictures in the distal bile duct (114 with pancreatic head carcinoma, 53 with bile duct carcinoma, 24 with lymph node metastasis, and 7 with carcinoma of the ampulla of Vater) who were determined not to be indicated for surgical treatment due to distant metastasis, vascular invasion of the tumor, poor performance status, advanced age, etc., and who instead underwent transpapillary placement of metallic stents.

Endoscopic metallic biliary stenting

In patients with a site of biliary obstruction in the distal bile duct who were suspected of having obstructive jaundice based on blood tests, ultrasonography and symptoms, computed tomography (CT) and/or magnetic resonance imaging (MRI) was performed to diagnose the primary disease.

When ERCP revealed bile duct carcinoma or carcinoma of the ampulla of Vater, horizontal spread in the bile duct was assessed with further ERCP and intra-ductal ultrasonography. Then, nasobiliary drainage was performed. In consideration of CT and MRI findings, systemic conditions and patient requests, resection was performed in those with resectable tumors. In patients with unresectable tumors, endoscopic metallic stenting was performed after biliary drainage. In all patients, stenting was performed under sedation in the prone position using a JF-260V or JF-240 (Olympus, Tokyo, Japan) scope. After cholangiography, a guidewire [Visiglide (Olympus, Tokyo, Japan) or Jagwire (Boston-Scientific, Natick, USA)] was placed in the bile duct, and a metallic stent was inserted through the scope to the bile duct. The stent was positioned with its distal end not reaching the hepatic portal region. If the proximal end was allowed to protrude from the ampulla of Vater, it would be left protruding by 5-10 mm. The stent was placed within the bile duct in patients with proximal biliary strictures. Although types of metallic stents were selected at

the discretion of doctors in charge, the same metallic stent placement strategy was used.

In principle, histological diagnosis was performed. If cancer was not detected by transpapillary bile duct biopsy, pancreatic duct brush cytology, or pancreatic juice cytology, cancer would be diagnosed after at least 1 year had elapsed.

Metallic Stents

The measurements of Isayama *et al.*^[16] were used for AF. AF was defined as a force required to bend a stent 60 degrees at 20 mm from the center. The AF of each stent is shown in table 1. The effects of AF on stent patency periods were assessed by evaluating the correlation between the patency period of each stent and AF.

Clinical care and assessment

If jaundice, increased hepatobiliary enzymes, abdominal pain, or fever occurred after metallic stent placement, ERCP was performed. Occlusion due to a tumor growing toward both ends of a metallic stent was defined as over-growth. Occlusion due to a tumor growing into a metallic stent was defined as in-growth. Occlusion due to biliary sludge/food scraps was defined as food impaction. The stent patency period was defined as the time to stent occlusion (in-growth, over-growth, or food impaction) or stent displacement/migration. The reason including displacement/migration is because it causes impairs bile flow.

We compared and assessed 50% stent patency periods. For food impaction, 80% stent non-occlusion periods were assessed.

Statistical methods

Comparisons among the disease groups were performed with the chi-square test and the Kruskal Wallis test. Univariate analysis was performed with the log-rank test with Kaplan-Meier curves. A $p < 0.05$ was considered significantly significant. Multivariate analysis was performed with the Cox proportional hazard model. All tests were performed using the IBM SPSS Statistics Desktop for Japan ver. 19.0 (IBM Japan Inc., Tokyo, Japan).

RESULTS

Basic characteristic of the patients with distal bile duct strictures is shown in table 2.

Factors affecting stent patency periods

Univariate analysis identified primary diseases and stent types as factors with major impacts on stent patency periods. In patients with a stent protruding from the ampulla of Vater, the stent patency periods

Table 1 The axial force of the stent types^[16].

	Axial Force
Uncovered metallic stent	
Wallstent	0.66
Diamond stent	0.29
Za-stent	0.30
SMART stent	0.46
Sinus Super Flex stent	0.44
Flexxus(Luminexx) stent	0.51
SelfX stent	0.19
Zilver stent	0.22
ZEO stent	0.18
Covered metallic stent	
Silicone covered Wallstent	0.95
Polyurethane covered Wallstent	0.73
Diamond stent	0.46
Viabil biliary stent	0.14
ComVi stent	0.04

The axial force: a force required to bend a stent 60 degrees at 20 mm from the center.

Table 2 Characteristics according to the primary disease.

	Pancreatic headcarcinoma (n=114)	Bile duct carcinoma (n=53)	Lymph nodemetastasis (n=24)	Carcinoma of the ampulla of Vater (n=7)
Age (range)	72.5 (45-91)	80 (48-94)	70 (42-83)	85 (58-92)
Male (%)	55	51	50	60
Cover (%)	79	75	58	80
Protrude from the papilla (%)	87	57	63	80
Chemotherapy (%)	55	9	55	20
Stent types				
Silicone Covered Wall (%)	42	32	17	14
Covered ComVi (%)	18	19	17	44
Covered Diamond (%)	15	21	25	14
Uncovered Luminexx (%)	10	13	17	14
Others (%)	15	15	25	14

Table 3 Single variable analysis of comparison of cumulative stent patencies.

	p value
Age (<75 vs ≥75)	0.66
Sex	0.33
Primary disease	0.01 *
Cover	0.25
Protrude from the papilla	0.08
Chemotherapy	0.35
Stent types	0.02*

Log-rank test. * :p<0.05.

Table 4 Multivariate analysis of comparison of cumulative stent patencies.

	p value	Hazard Ratio
Primary disease		
Bile duct carcinoma		1
Pancreatic head carcinoma	<0.01 **	0.36 (0.20-0.64)
Lymph node metastasis	0.63	0.82 (0.37-1.84)
Carcinoma of the ampulla of Vater	0.02*	0.08 (0.01-0.69)
Stent types		
Covered ComVi		1
Silicone Covered Wall	0.01 *	0.37 (0.17-0.80)
Covered Diamond	0.62	0.72 (0.20-2.63)
Uncovered Luminexx	0.02*	0.33 (0.13-0.81)

Cox proportional hazard model. * :p<0.05; ** is p<0.01

tended to be long (Table 3).

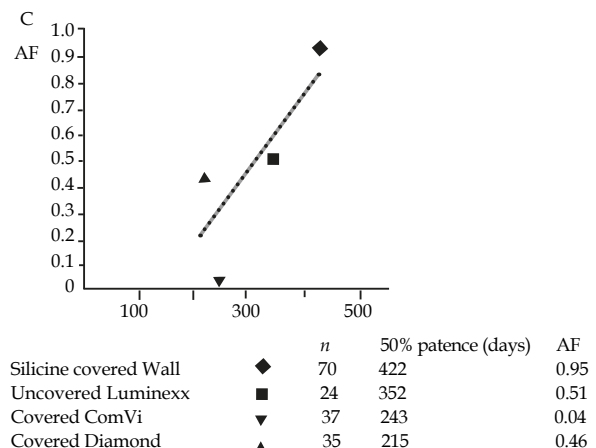
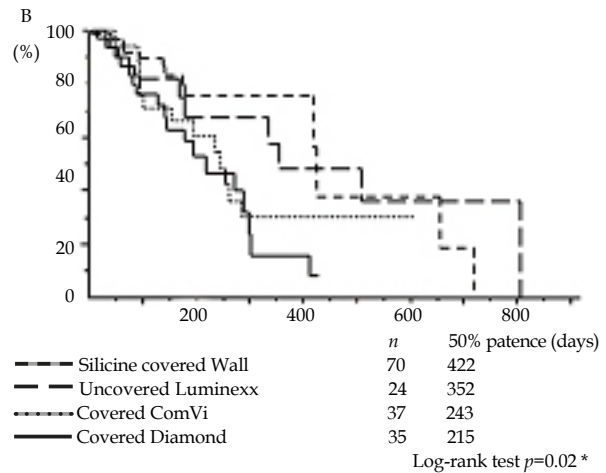
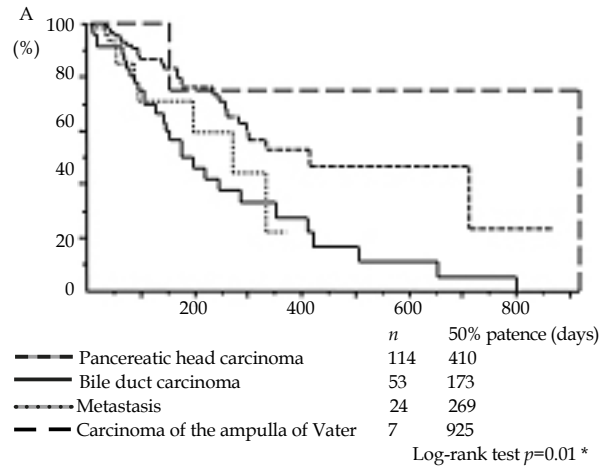
Based on analysis of primary diseases, the 50% stent patency periods were 173 days for bile duct carcinoma, 269 for lymph node metastasis, and 410 for pancreatic carcinoma, indicating patency periods to be significantly shorter for bile duct carcinoma (p=0.01) (Figure 1A).

Based on analysis including all diseases according to stent types, the 50% stent patency periods were 215 days for Covered Diamond stents (Boston-Scientific, Natick, USA), 243 for Covered ComVi stents (TaeWoong Medical, Seoul, Korea), 352 for Uncovered Luminexx stents (Bard, Tempe, Arizona, USA), and 422 for Silicon Covered Wall stents (Boston-Scientific, Tokyo, Japan) (p=0.02) (Figure 1B).

Based on analysis including all diseases according to stent types, there was a positive correlation between AF and stent types with a coefficient of 0.79 (Figure 1C).

Based on analysis including all diseases according to whether or not a stent protruded from the ampulla of Vater, the 50% stent patency periods were 410 days in patients with a stent protruding from the ampulla of Vater and 242 in those with a stent placed entirely within the bile duct (p=0.08) (Figure 1D).

By multivariate analysis, primary diseases and stent types were extracted as significant factors. Bile duct carcinoma was associated with a higher risk of stent occlusion than pancreatic carcinoma, and the Covered ComVi stent carried a higher risk for stent occlusion than the Uncovered Luminexx and Silicone Covered Wall stents (Table 4).



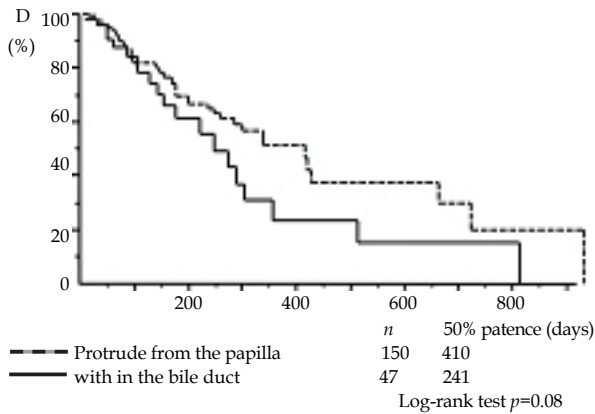


Figure 1 A: Stent patency periods according to primary diseases. (Kaplan-Meier method) A significant difference was observed between groups ($p=0.01^*$). B: Stent patency periods based on analysis including all primary diseases according to stent types. (Kaplan-Meier method) A significant difference was observed between groups ($p=0.02^*$). C: Correlation between axial force (AF) and 50% stent patency periods based on analysis including all primary diseases (correlation coefficient, 0.79). AF: a force required to bend a stent 60 degrees at 20 mm from the center. D: Stent patency periods based on analysis including all primary diseases according to the presence or absence of stent protrusion from the ampulla of Vater. (Kaplan-Meier method).

Combined evaluation of both primary diseases and types of metallic stents—Evaluation of optimal metallic stents according to diseases –

Pancreatic head carcinoma: The 50% stent patency periods were 258 d for Covered ComVi stents, 294 for Covered Diamond stents, and 415 for Silicone Covered Wall stents, showing no significant differences among stent types (Figure 2A).

Bile duct carcinoma: The 50% stent patency periods were 81 days for Covered ComVi stents, 193 for Covered Diamond stents, 352 for Uncovered Luminexx stents, and 422 for Silicone Covered Wall stents, showing significant differences among stent types ($p=0.03$) (Figure 2B).

Moreover, a positive correlation was observed between the 50% stent patency periods and AF (correlation coefficient, 0.92) (Figure 3A).

The 80% stent non-occlusion periods associated with food impaction as a cause of occlusion correlated positively with AF (correlation coefficient, 0.89) (Figure 3B).

Biliary strictures due to lymph node metastasis: The 50% stent patency periods were 193 days for Covered ComVi stents, 269 for Covered Diamond stents, and 331 for Uncovered Luminexx stents, showing no significant difference among stent types (Figure 2C).

Carcinoma of the ampulla of Vater: No evaluation was performed due to the small number of patients.

DISCUSSION

This study identified disease and stent types as factors affecting stent patency periods.

The evaluation according to primary diseases revealed that bile duct carcinoma affects stent patency periods. There have been few studies of metallic stent placement according to primary diseases. Only studies with a high proportion of patients with pancreatic carcinoma have been reported^[9,11,14,18]. This may be attributable to the small number of patients with distal bile duct carcinoma requiring metallic stent placement because resection is performed in many such patients. However, in the study conducted at our department, the stent patency periods in patients with bile duct carcinoma were

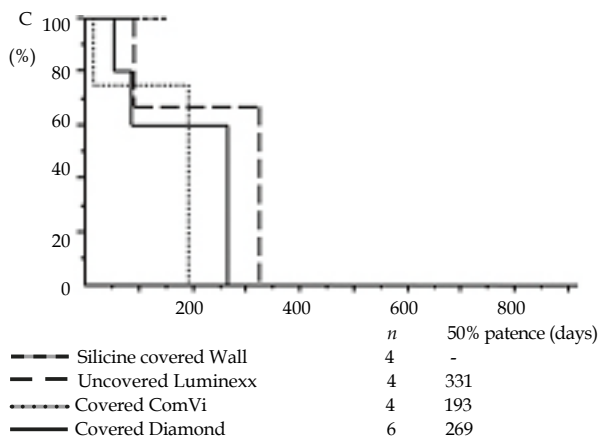
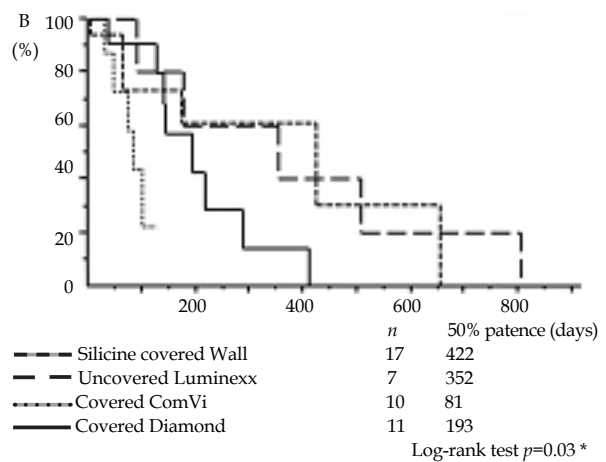
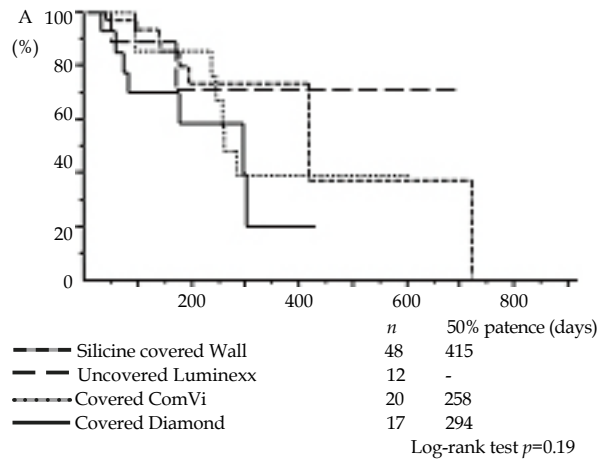


Figure 2 A: Stent patency periods for pancreatic carcinoma according to stent types. B: Stent patency periods for bile duct carcinoma according to stent types ($p=0.03^*$). C: Stent patency periods for lymph node metastasis according to stent types.

markedly shorter than those in patients with pancreatic carcinoma and carcinoma of the ampulla of vater. A reason for short stent patency periods in patients with bile duct carcinoma may be that in-growth or over-growth of the cancer directly disturbs uncovered stent and over-growth of the cancer directly disturbs covered stent because bile duct carcinoma involves malignant transformation of the bile duct epithelium. Furthermore, the evaluation of stent types revealed Covered Wall stents to have the longest patency period.

Interestingly, we found that patency periods tended to be longer in patients with a stent protruding from the ampulla of Vater, which had likely been caused by tumoral over-growth. Stent occlusion by over-

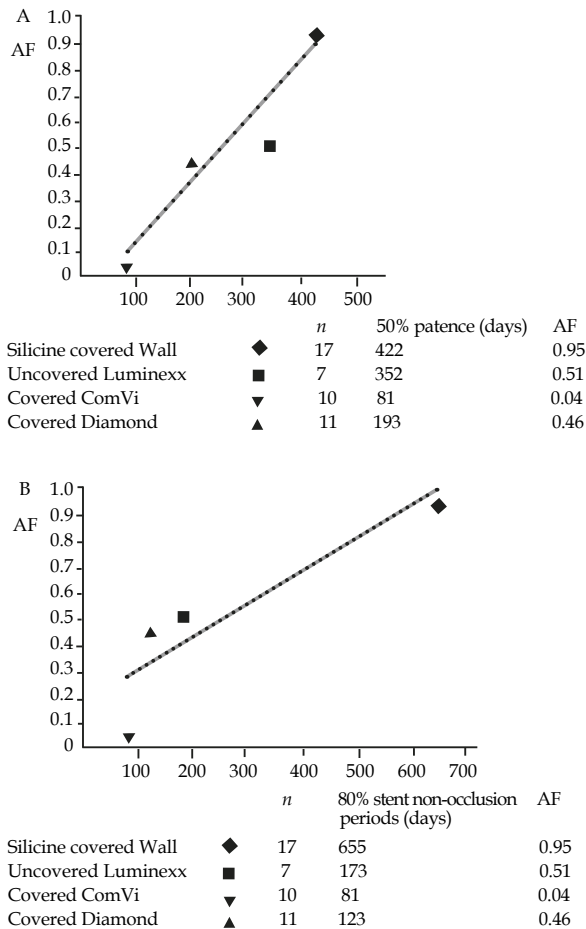


Figure 3 A: Correlation between axial force(AF) and 50% stent patency periods for bile duct carcinoma (correlation coefficient, 0.92). B: Correlation between AF and 80% stent non-occlusion periods associated with food impaction for bile duct carcinoma (correlation coefficient, 0.89). AF: a force required to bend a stent 60 degrees at 20 mm from the center.

growth was seen in of nine of 47 patients in the stent placed entirely within the bile duct, compared with only eight of 150 patients in the stents protruding from the ampulla of Vater (data not shown). The higher frequency of occlusion in the former group may have been due to tumoral over-growth in patients with a stent placed entirely within the bile duct.

Because both diseases and stents were revealed to significantly affect stent patency periods, we performed combined evaluation of both to identify optimal stents for each disease. We found stent patency periods to be long for stents with high AF in bile duct carcinoma cases. This is attributable to mild axial displacement of the course of the bile duct in bile duct carcinoma. However, because biliary strictures due to pancreatic carcinoma and lymph node metastasis are caused by lesions outside the bile duct, the axis of the bile duct is severely displaced. The results of this study may be attributable to the fact that, in cases of bile duct carcinoma as opposed to pancreatic carcinoma and lymph node metastasis, a stent with high AF further straightens the bile duct and reduces stagnation of bile flow.

It was reported that Covered ComVi stent showed high rate of food impaction more than Covered Wallstent, which the author regarded the high incidence rate of food impaction of Covered Comvi stent as inner bare wire loosely exposed into the bile duct^[19].

But in this study, we confirmed by the observation that food impaction often caused occlusion of metallic stents with low AF(data not shown). Conversely, low AF metallic stent may cause to

occlusion by food impaction.

Even among similar bile duct carcinomas, pathological conditions vary between hilar bile duct carcinoma and distal bile duct carcinoma because the bile duct is bent. In metallic stent placement for malignant hilar biliary stricture, stents with low AF reportedly contributed to prolongation of stent patency periods^[17].

There is also a report that metallic stent placement in patients with bile duct carcinoma results in early improvement of QOL and contributes to early social rehabilitation^[20]. Thus, selection of stents that remain patent for a long period is important in patients with bile duct carcinoma.

The limitations of this study are the small number of patients and its retrospective design. In the future, multicenter prospective studies with a larger number of patients are necessary.

In conclusion, for biliary strictures due to unresectable distal bile duct carcinoma, selection of metallic stents with high AF may prolong stent patency periods.

REFERENCES

- 1 Soehendra N, Reynders-Frederix V. Palliative. Bile duct drainage-a new endoscopic method of introducing a transpapillary drain. *Endoscopy* 1980; **12**: 8-11
- 2 Huibregtse K, Haverkamp HJ, Tytgat GN. Transpapillary positioning of a large 3.2 mm biliary endoprosthesis. *Endoscopy* 1981; **13**: 217-219
- 3 Huibregtse K, Chenq J, Coene PP, Fockens P, Tytgat GN. Endoscopic placement of expandable metal stents for biliary strictures--a preliminary report on experience with 33 patients. *Endoscopy* 1989; **21**: 280-282
- 4 Neuhaus H, Hagenmüller F, Classen M. Self-expanding biliary stents: preliminary clinical experience. *Endoscopy* 1989; **21**: 225-228
- 5 Davids PH, Groen AK, Rauws EA, Tytgat GN, Huibregtse K. Randomised trial of self-expanding metal stents versus polyethylene stents for distal malignant biliary obstruction. *Lancet* 1992; **340**: 1488-1492
- 6 Knyrim K, Wagner HJ, Pausch J, Vakil N, A prospective, randomized, controlled trial of metal stents for malignant obstruction of the common bile duct. *Endoscopy* 1993; **25**: 207-212
- 7 Burris HA 3rd, Moore MJ, Andersen J, Green MR, Rothenberg ML, Modiano MR, Cripps MC, Portenoy RK, Storniolo AM, Tarassoff P, Nelson R, Dorr FA, Stephens CD, Von Hoff DD. Improvements in survival and clinical benefit with gemcitabine as first-line therapy for patients with advanced pancreas cancer: a randomized trial. *J Clin Oncol* 1997; **15**: 2403-2413
- 8 Valle J, Wasan H, Palmer DH, Cunningham D, Anthony A, Maraveyas A, Madhusudan S, Iveson T, Hughes S, Pereira SP, Roughton M, Bridgewater J; ABC-02 Trial Investigators. Cisplatin plus gemcitabine versus gemcitabine for biliary tract cancer. *N Engl J Med* 2010; **362**: 1273-1281
- 9 Tsuchiya T, Itoi T, Gotoda T, Kuraoka K, Sofuni A, Itokawa F, Kurihara T, Ishii K, Tsuji S, Ikeuchi N, Tanaka R, Umeda J, Moriyasu F. A multicenter prospective study of the short-term outcome of a newly developed partially covered self-expandable metallic biliary stent (WallFlex®). *Dig Dis Sci* 2011; **56**: 1889-1895
- 10 Yang KY, Ryu JK, Seo JK, Woo SM, Park JK, Kim YT, Yoon YB. A comparison of the Niti-D biliary uncovered stent and the uncovered Wallstent in malignant biliary obstruction. *Gastrointest. Endosc* 2009; **70**: 45-51
- 11 Isayama H, Komatsu Y, Tsujino T, Sasahira N, Hirano K, Toda N, Nakai Y, Yamamoto N, Tada M, Yoshida H, Shiratori Y, Kawabe T, Omata M. A prospective randomised

- study of "covered" versus "uncovered" diamond stents for the management of distal malignant biliary obstruction. *Gut* 2004; **53**: 729-734
- 12 Weston BR, Ross WA, Liu J, Lee JH. Clinical outcomes of nitinol and stainless steel uncovered metal stents for malignant biliary strictures: is there a difference? *Gastrointest Endosc* 2010; **72**: 1195-1200
 - 13 Saleem A, Leggett CL, Murad MH, Baron TH. Meta-analysis of randomized trials comparing the patency of covered and uncovered self-expandable metal stents for palliation of distal malignant bile duct obstruction. *Gastrointest Endosc* 2011; **74**: 321-327
 - 14 Kullman E, Frozanpor F, Söderlund C, Linder S, Sandström P, Lindhoff-Larsson A, Toth E, Lindell G, Jonas E, Freedman J, Ljungman M, Rudberg C, Ohlin B, Zacharias R, Leijonmarck CE, Teder K, Ringman A, Persson G, Gözen M, Eriksson O. Covered versus uncovered self-expandable nitinol stents in the palliative treatment of malignant distal biliary obstruction: results from a randomized, multicenter study. *Gastrointest Endosc* 2010 ; **72** : 915-923
 - 15 Telford JJ, Carr-Locke DL, Baron TH, Poneros JM, Bounds BC, Kelsey PB, Schapiro RH, Huang CS, Lichtenstein DR, Jacobson BC, Saltzman JR, Thompson CC, Forcione DG, Gostout CJ, Brugge WR. A randomized trial comparing uncovered and partially covered self-expandable metal stents in the palliation of distal malignant biliary obstruction. *Gastrointest Endosc* 2010 ; **72** : 907-914
 - 16 Isayama H, Nakai Y, Toyokawa O, Togawa O, Kogure H, Sasahira N, Yashima Y, Kawakubo K, Ito Y, Hirano K, Tsujino T, Toda N, Omata M, Koike K. Measurement of radial and axial forces of biliary self-expandable metallic stents. *Gastrointest Endosc* 2009; **70**: 37-44
 - 17 Mukai T, Yasuda I, Isayama H, Nakashima M, Doi S, Iwashita T, Iwata K, Kato T, Tomita E, Moriwaki H. Comparison of axial force and cell width of self-expandable metallic stents: which type of stent is better suited for hilar biliary strictures? *J Hepatobiliary Pancreat Sci* 2011; **18**: 646-652
 - 18 Yoon WJ, Lee JK, Lee KH, Lee WJ, Ryu JK, Kim YT, Yoon YB. A comparison of covered and uncovered Wallstents for the management of distal malignant biliary obstruction. *Gastrointest. Endosc* 2006 ; **63** : 996-1000
 - 19 Isayama H, Kawabe T, Nakai Y, Ito Y, Togawa O, Kogure H, Yashima Y, Yagioka H, Matsubara S, Sasaki T, Sasahira N, Hirano K, Tsujino T, Tada M, Omata M. Management of distal malignant biliary obstruction with the ComVi stent, a new covered metallic stent. *Surg Endosc* 2009; **24**: 131-137
 - 20 Mihalache F, Tantau M, Diaconu B, Acalovschi M. Survival and quality of life of cholangiocarcinoma patients: a prospective study over a 4 year period. *J Gastrointestin Liver Dis* 2010; **19**: 285-290
- Peer reviewers:** Yoshiaki Kawaguchi, Associate Professor, Department of Gastroenterology, Tokai University School of Medicine, 143 Shomokasuya, Isehara, 259-1193, Japan; Hiromichi Ishii, MD, Department of Surgery, Kyoto Prefectural Yosanoumi Hospital, 481 Otokoyama, Yosano-cho, Yosa-gun, Kyoto 629-2261, Japan.