

Pneumoperitoneum after Colonoscopic Polypectomy. A Therapeutic Dilemma

Óscar Cano-Valderrama, Carlos Ferrigni, Iris Sánchez-Egido, Susana Martín-Garre, María Jesús Pérez-Contín, Manuel Giner

Óscar Cano-Valderrama, Carlos Ferrigni, Iris Sánchez-Egido, Susana Martín-Garre, María Jesús Pérez-Contín, Manuel Giner, Department of Surgery, Hospital Clínico San Carlos, Complutense University of Madrid, 28040-Madrid, Spain. dp085@ucm.es

Correspondence to: Manuel Giner, Professor, Department of Surgery, School of Medicine, Complutense University of Madrid, 28040-Madrid, Spain. manginer@med.ucm.es

Telephone: +034-913941217 Fax: +034-913303488

Received: November 12, 2012 Revised: November 26, 2012

Accepted: November 29, 2012

Published online: March 21, 2013

ABSTRACT

Background Pneumoperitoneum may occur following colonoscopy that may be accompanied by perforation of the colon. Most of these cases are managed by emergency surgery. However, this attitude may result in an unnecessary surgery. Cases report Two demonstrative cases of post-colonoscopy pneumoperitoneum are reported. In both cases the pneumoperitoneum appeared a few hours after uncomplicated colonoscopy plus polypectomy without clinical or laboratory evidence of peritonitis. In the first case, since perforation was suspected, a laparotomy was performed that turned out to be an unnecessary procedure. Moreover, pneumoperitoneum recurred and was satisfactorily treated by paracentesis. In our second case, conservative management under close observation was chosen and the patient made an uncomplicated recovery. Conclusion Our experience, which coincides with others', suggests that in absence of peritoneal irritation, a conservative management should be chosen. However, if the patient deteriorates with conservative management, one should proceed to surgery.

© 2013 ACT. All rights reserved.

Key words: Colonoscopy; Polypectomy; Complications; Pneumoperitoneum; Perforation

Cano-Valderrama Ó, Ferrigni C, Sánchez-Egido I, Martín-Garre S, Pérez-Contín MJ, Giner M. Pneumoperitoneum after Colonoscopic Polypectomy. A Therapeutic Dilemma. *Journal of Gastroenterology and Hepatology Research* 2013; 2(2): 423-425 Available from: URL: <http://www.ghrnet.org/index./joghr/>

INTRODUCTION

Pneumoperitoneum, defined as the presence of air within the abdominal cavity, indicates hollow viscus perforation in up to 90% of cases and most of these cases are managed by emergency surgery. The remaining 10% of cases are known as non-surgical or benign pneumoperitoneum (NSP), defined by the presence of air in the peritoneal space that is detectable by roentgenogram and either is managed successfully by observation and supportive care alone or results in a nondiagnostic laparotomy^[1]. The leading cause of NSP is open or laparoscopic surgery followed by mechanical ventilation, cardiopulmonary resuscitation and pneumothorax.

Less frequently pneumoperitoneum may occur following colonoscopy with or without polypectomy, that may be accompanied or not by perforation of the colon. The estimated incidence of benign pneumoperitoneum after diagnostic and therapeutic colonoscopy is between 0% and 3%^[2]. When post-colonoscopy pneumoperitoneum appears, perforation is often suspected and laparotomy indicated on an emergency basis. However, some reports have proved that this attitude may result in an unnecessary surgery^[3-6]. We report two cases of pneumoperitoneum post colonoscopic polypectomy showing the possibilities and utility of a conservative management.

CASE REPORT 1

A 54-year-old man was readmitted in hospital, because of abdominal pain, 12 hours after an uncomplicated colonoscopy that included a snare excision of a 7 mm sigmoid polyp (Figure 1). Exams showed tachycardia (100 bpm), mild leukocytosis (12 000/ μ L), abdominal distension and mild tenderness without fever or signs of peritonitis. Abdominal radiography as well as computed tomography revealed a large pneumoperitoneum with no other significant findings (Figures 2 and 3). Colon perforation was suspected and laparotomy indicated. Surgery was guided by intraoperative colonoscopy. The insufflated colon was submerged in normal saline solution and inspected for bubbles. No cause of pneumoperitoneum or other abnormalities were found at surgery.

Five days after operation, the patient complained of abdominal distension and dyspnea. Toraco-abdominal computed tomography revealed a greater pneumoperitoneum with a small amount of free fluid (Figure 4). Sonography-guided paracentesis was performed

with immediate symptomatic improvement. Post-paracentesis abdominal radiographs showed complete resolution and the patient was satisfactorily discharged 14 days after admission.

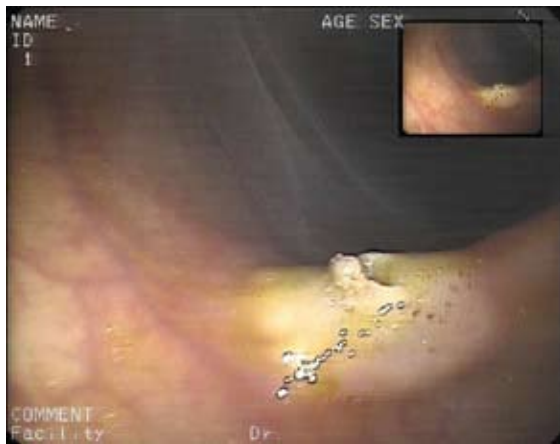


Figure 1 Endoscopic view of the colonic mucosa after polypectomy.

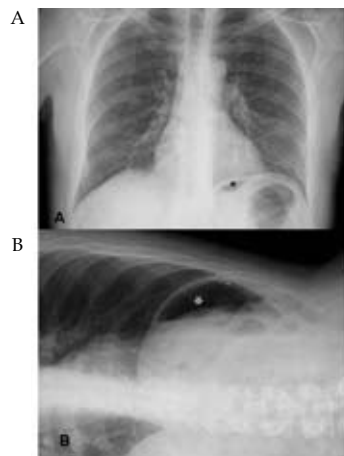


Figure 2 Postero-anterior chest radiograph showing gas under the left hemidiaphragm (A: black asterisk). Left lateral decubitus film confirming the extraluminal air (B: white asterisk).

CASE REPORT 2

A 72-year-old woman was readmitted the day after a screening colonoscopy that included excision, by biopsy forceps, of a 3 mm sigmoid polyp. The patient's only complaint was abdominal pain. Physical exam revealed mild tenderness in the right abdomen. Blood tests were normal. Plain abdominal radiography and computed tomography showed a large pneumoperitoneum without intraperitoneal fluid (Figure 5). Without clinical or laboratory evidence of peritonitis, a conservative management under close observation was chosen. Although the pneumoperitoneum persisted during the patient's hospital stay, she recovered from symptoms and was discharged after six days of clinical and radiological observation.

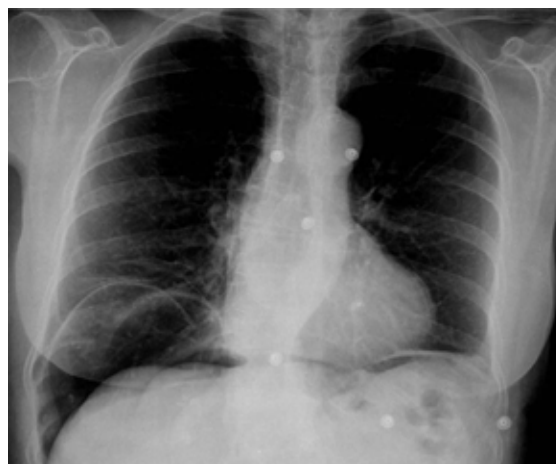

Figure 5 Upright chest radiography taken 24 hours after colonoscopy showing a large pneumoperitoneum outlining the superior surfaces of the spleen and the liver.

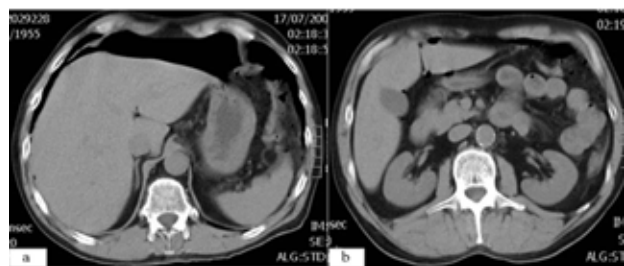


Figure 3 Axial computed tomography scan shows a collection of air anterior to the liver (a). In a lower level, bubbles of air are seen surrounding the left hepatic lobe, the gallbladder and next to the left anterior abdominal wall (b).

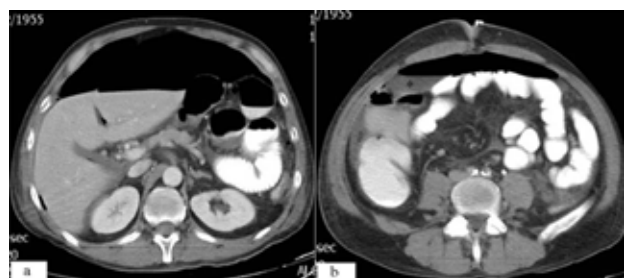


Figure 4 Axial contrast-enhanced computed tomography scan performed five days after surgery showing a greater pneumoperitoneum as compared to the previous study (a). There is a small amount of free fluid. Air-fluid levels are seen (b; black asterisk).

DISCUSSION

In case of pneumoperitoneum, the route of introduction of air into the abdominal cavity can be abdominal, thoracic, gynecologic, or idiopathic. In a search of the medical literature from 1970 to 1999 using the key words pneumoperitoneum and benign, nonsurgical, spontaneous, iatrogenic, barotrauma, pneumatosis, diaphragmatic defects, free air, mechanical ventilation, gynecologic, and pelvic, 482 articles were identified and all case reports and reviews of NSP were reviewed^[1]. Most cases of NSP occurred as a procedural complication or as a complication of medical intervention. The most common abdominal etiology of NSP was retained postoperative air (prevalence 25% to 60%). NSP occurred frequently after peritoneal dialysis catheter placement (prevalence 10% to 34%) and after gastrointestinal endoscopic procedures (prevalence 0.3% to 25%, varying by procedure). The most common thoracic causes included mechanical ventilation, cardiopulmonary resuscitation, and pneumothorax. One hundred ninety-six case reports of NSP were recorded, of which 45 involved surgical exploration without evidence of perforated viscus.

Pneumoperitoneum after colonoscopy with polypectomy is commonly attributed to microperforation. Perforation was not evident in our first case by means of the used technique (presence of air bubbles coming from the submerged colon). Moreover, there is evidence that NSP is possible after colonoscopic polypectomy without perforation^[6].

Many patients complain of bowel distension and abdominal pain after air insufflation of the intestinal tract during colonoscopy; the method used by us in both cases. Recently, carbon dioxide (CO₂)

instead of air has been used. A meta-analysis focused to evaluate the efficiency, safety, and comfort of colonoscopy with CO₂ versus air, demonstrated that CO₂ insufflation produced less abdominal discomfort during and following the procedure, without any additional adverse reactions, warranting its routine clinical use^[7]. On the other hand, in a recent comparative study to evaluate the effects of CO₂ insufflation on pneumoperitoneum and bowel distension after percutaneous endoscopic gastrostomy, a lower incidence of pneumoperitoneum and less distension of the small bowel were shown in the CO₂ group in comparison to the air counterpart^[8].

The treatment of benign pneumoperitoneum can be conservative or surgical. Perhaps the most important maneuver for differentiating between the two possibilities is by performing a thorough history and physical examination. This in conjunction with a diagnostic peritoneal lavage, contrast studies, or endoscopic evaluation can help prevent a patient from having needless surgery^[9]. Pneumoperitoneum can be seen by three different ways: i) air can enter abdominal cavity transmurally from colon without any perforation. These cases may be treated with only follow-up, ii) a microperforation in colon wall without signs of peritonitis and leucocytosis may be also treated with antibiotics in selected cases, and iii) a true perforation can occur during colonoscopy with intraabdominal air. Overt perforation or signs of peritonitis with fever and other inflammatory signs indicates surgery. Since there were no signs of frank peritonitis, surgery could have been avoided in both of our patients.

Colon perforation which complicates less than 0.5% of colonoscopies^[10], too often promotes laparotomy. After colonoscopy, perforation of the colon requires surgical intervention more frequently than bleeding^[11]. There are three mechanisms responsible for colonoscopic perforation: mechanical perforation directly from the colonoscope or another instrument, barotrauma from excessive air insufflation, and, finally, perforations that occur during therapeutic procedures. If a perforation does occur, patient's signs and symptoms are related to the size and site of the perforation, adequacy of the bowel preparation, amount of peritoneal soilage, underlying colonic pathology, and, finally, overall clinical condition of the patient.

In a recent study a total of 17 357 consecutive endoscopic procedures of the colon (13 699 colonoscopies and 3 658 flexible sigmoidoscopies), performed over a 9-year period, were reviewed^[12]. Fifteen patients (0.09%) had colonic perforation, 14 from colonoscopy and 1 from sigmoidoscopy. Perforations were caused by direct trauma from either the shaft or the tip of the endoscope ($n=12$, 80%) and endoscopic polypectomy ($n=3$, 20%). All patients with post-colonoscopy perforation underwent surgical management: primary repair (27%) or bowel resection (73%). The mortality rate was 13% and postoperative complication rate was 53%.

Classically, treating all post-colonoscopy pneumoperitoneums by laparotomy has been advocated^[13,14]. Our experience, which coincides with others^[3-5], suggests that in absence of peritoneal irritation, a conservative management should be chosen, though paracentesis may occasionally be required to evacuate a large pneumoperitoneum^[3]. After colonoscopy, pneumoperitoneum appears occasionally without colon perforation^[6]. On the other hand, a localized perforation may be demonstrated with lack of pneumoperitoneum. Even with small perforations, conservative approaches with intravenous antibiotics and bowel rest could be attempted, after considering whether there is coexisting peritonitis,

the timing of diagnosis and the patient's clinical condition. However, if the patient deteriorates with conservative management, one should proceed to surgery.

ACKNOWLEDGMENTS

The authors express their gratitude to Mr. James P. Nowlan for his help in translating the manuscript.

REFERENCES

- Mularski RA, Sippel JM, Osborne ML. Pneumoperitoneum: a review of nonsurgical causes. *Crit Care Med* 2000; **28**: 2638-2644
- Pearl JP, McNally MP, Elster EA, DeNobile JW. Benign pneumoperitoneum after colonoscopy: a prospective pilot study. *Mil Med* 2006; **171**: 648-649
- Vieira A, Fernandes V, Freitas J. Post-colonoscopy polypectomy pneumoperitoneum successfully treated by paracentesis. *Endoscopy* 2005; **37**: 782
- Khan ZA, Novell JR. Conservative management of tension pneumoperitoneum. *Ann R Coll Surg Engl* 2002; **84**: 164-165
- Ustek S, Boran M, Kismet K. Benign pneumoperitoneum after colonoscopy. *Case Rep Med* 2010; **2010**: 631036
- Eisenbach C, Bläker H, Stremmel W, Sauer P, Schaible A. Pneumoperitoneum following endoscopic mucosal resection without perforation of the colon. *Endoscopy* 2008; **40** Suppl 2: E64-E65
- Wu J, Hu B. The role of carbon dioxide insufflation in colonoscopy: a systematic review and meta-analysis. *Endoscopy* 2012; **44**: 128-136
- Nishiwaki S, Araki H, Hayashi M, Takada J, Iwashita M, Tagami A, Hatakeyama H, Hayashi T, Maeda T, Saito K. Inhibitory effects of carbon dioxide insufflation on pneumoperitoneum and bowel distension after percutaneous endoscopic gastrostomy. *World J Gastroenterol* 2012; **18**: 3565-3570
- Rowe NM, Kahn FB, Acinapura AJ, Cunningham JN. Nonsurgical pneumoperitoneum: a case report and a review. *Am Surg* 1998; **64**: 313-322
- Gatto NM, Frucht H, Sundararajan V, Jacobson JS, Grann VR, Neugut AI. Risk of perforation after colonoscopy and sigmoidoscopy: a population-based study. *J Natl Cancer Inst* 2003; **95**: 230-236
- Damore LJ, Rantis PC, Vernava AM, Longo WE. Colonoscopic perforations. Etiology, diagnosis, and management. *Dis Colon Rectum* 1996; **39**: 1308-1314
- Lohsiriwat V, Sujarittanakarn S, Akaraviputh T, Lertakyamanee N, Lohsiriwat D, Kachinthorn U. Colonoscopic perforation: A report from World Gastroenterology Organization endoscopy training center in Thailand. *World J Gastroenterol* 2008; **14**: 6722-6725
- Brynitz S, Kjaergård H, Struckmann J. Perforations from colonoscopy during diagnosis and treatment of polyps. *Ann Chir Gynaecol* 1986; **75**: 142-145
- Nelson RL, Abcarian H, Prasad ML. Iatrogenic perforation of the colon and rectum. *Dis Colon Rectum* 1982; **25**: 305-308

Peer reviewer: Yosuke Tsuji, Department of Gastroenterology, NTT Medical Center Tokyo, 5-9-22, Shinagawa-ku, Tokyo, 141-8625, Japan; Everson L.A. Artifon, ua guimaraes passos 260 apto 111, University of Sao Paulo(USP)-Sao Paulo, Brazil.