

## Multiple Gastric Carcinoids: Uncommon Cause of Recurrent Melena, A Case Report

Mohamed M Refaey, Mohamed H Emara, Tarik I Zaher, Tarik M Ezzat

Mohamed M Refaey, Mohamed H Emara, Tarik I Zaher, Tropical Medicine Department, Faculty of Medicine, Zagazig University, Zagazig, 44519, Egypt

Tarik M Ezzat, General Surgery Department, Faculty of Medicine, Zagazig University, Zagazig, 44519, Egypt

Correspondence to: Mohamed H Emara, MD, Tropical Medicine Department, Faculty of Medicine, Zagazig University, Zagazig, 44519, Egypt. Email: [emara\\_20007@yahoo.com](mailto:emara_20007@yahoo.com)

Telephone: +0201002724482 Fax: +020552346893

Received: November 27, 2012 Revised: December 21, 2012

Accepted: December 26, 2012

Published online: March 21, 2013

### ABSTRACT

Carcinoid tumors are neuroendocrine tumors that are not commonly originate from the stomach. The authors reported a 41 year old female patient presented with recurrent attacks of melena. Diagnostic upper endoscopy revealed three ovoid corporal masses proved by histopathology to be gastric carcinoids and were successfully removed by subtotal gastrectomy. Although rare, gastric carcinoids should not be overlooked while evaluating cases of recurrent melena.

© 2013 ACT. All rights reserved.

**Key words:** Carcinoid; Melena; Stomach; Endoscopy

Refaey MM, Emara MH, Zaher TI, Ezzat TM. Multiple Gastric Carcinoids: Uncommon Cause of Recurrent Melena, A Case Report. *Journal of Gastroenterology and Hepatology Research* 2013; 2(2): 482-484 Available from: URL: <http://www.ghrnet.org/index./joghr/>

### INTRODUCTION

Carcinoid tumors are neuroendocrine tumors that originate from the embryonic neural crest. The prominent feature of carcinoid tumors is the production of multiple hormones<sup>[1]</sup>. The majorities of carcinoid tumors originates in the gastrointestinal tract (GIT), and are usually discovered incidentally<sup>[2]</sup>. Gastric carcinoid tumors are rare, constituting less than 1% of gastric neoplasms<sup>[3]</sup>. Gastric carcinoids arise from endocrine cells in the gastric mucosa<sup>[4]</sup>. There

are three types of gastric carcinoids<sup>[5,6]</sup>. Type I is associated with chronic atrophic gastritis type A. Type II is seen in Zollinger-Ellison syndrome/multiple endocrine neoplasia type I (MEN-1) syndrome. Type III is a sporadic tumor<sup>[4,6]</sup>.

Melena refers to bleeding from the upper GIT proximal to the ligament of Treitz in the form of black, tarry, offensive and glistening stool<sup>[7]</sup>. Carcinoid tumors of the upper GIT when invade the overlying mucosa and erode through a blood vessel may cause bleeding within the lumen of the GIT and presented clinically as melena<sup>[8]</sup>.

### CASE REPORT

A 41 year old female patient presented with recurrent attacks of melena. The patient when presented to the emergency unit due to the bleeding episode was fully conscious, blood pressure 100/60, pulse rate of 96, and she was pale. The laboratory parameters were normal except for hemoglobin that was 9.1 gm%. She gave history of previous 2 attacks of melena, that was treated conservatively and she refused to perform diagnostic upper GIT endoscopy for it. Diagnostic upper endoscopy (for the current bleeding episode) showed three ovoid mucosal swellings in the corpus of the stomach with umbilicated and ulcerated surface and a visible vessel was seen inside it (figure 1). Multiple biopsies were taken for histopathology that showed carcinoid tumor invading the gastric mucosa and submucosa, associated with mild atrophic gastritis and there was no lymphatic invasion nor intestinal metaplasia. The patient was examined by abdominal ultrasound and triphasic multislice CT to evaluate the gastric wall invasion, nodal and liver metastases. No extramural spread was confirmed. The patient was successfully treated by subtotal gastrectomy. At gross pathologic evaluation of the excised stomach, multiple carcinoid tumors with diameters ranging from 1.0 to 3.0 cm were seen. Microscopic examination of the proximal, distal, and radial margins of the stomach were tumor free, and regional lymph nodes were not invaded. The patient was candidate for monthly follow up by clinical examination, full laboratory assessment and abdominal ultrasound examination and three monthly by upper endoscopic and CT examinations for one year. Neither gastric mural disease nor extragastric manifestations such as lymphadenopathy and hepatic metastasis were reported. The patient remained stable during the period of follow up (30 months after her operation).

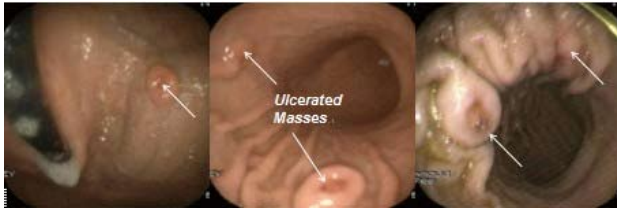


Figure 1 Endoscopic appearance of gastric carcinoids.

## DISCUSSION

Type I gastric carcinoids are the most frequent type encountered in about 65% of cases<sup>[9]</sup>; are associated with enterochromaffin-like cellular hyperplasia, and hypergastrinemia<sup>[3]</sup>. The tumors are usually small (<1 cm) polypoid lesions located in the gastric body or fundus<sup>[10]</sup>. Nodal and hepatic metastases are not common<sup>[11]</sup>. Endocrine symptoms are rare; 5-year survival is high, for tumors less than 1.0 cm in size, either in polypoid or submucosal morphology<sup>[2]</sup>. Type II tumors are caused by hypergastrinemia from gastrin-producing tumors of the pancreas or small intestine. Type II gastric carcinoids patients suffer from repeated GIT bleeding and hypergastrinemia. Prognosis is intermediate, between types I and type III<sup>[9]</sup>. Type III gastric lesions represent about 20% of gastric carcinoids and are not associated with hypergastrinemia<sup>[3]</sup>. Forty percent occur in the antropyloric area<sup>[4]</sup> when discovered; they are usually single tumor more than 2 cm. They can cause either a classic syndrome of facial flushing, abdominal cramps, diarrhea, left-sided endocardial fibrosis, and 24 h urinary 5-HIAA more than 10 mg, or an atypical carcinoid syndrome associated with vasoactive substances and polypeptide hormone production<sup>[4]</sup>. Nodal metastasis is reported in 55% of patients and liver metastases, in 25% of patients<sup>[6]</sup>. Five-year survival is only 50%<sup>[9]</sup>.

Enterochromaffin-like cells, the main endocrine cells in the gastric fundus, are sensitive to gastrin and give rise to type I gastric carcinoid tumors<sup>[12]</sup>. Patients with type I gastric carcinoids may present with abdominal pain, bleeding, diarrhea, and vomiting. However, up to one-third of patients may be asymptomatic<sup>[13]</sup>. Our case seems to be type I gastric carcinoid, due to the associated gastritis, lack of endocrinal manifestations and the lack of nodal and liver metastases. The bleeding episodes reported in this case are directly related to invasion of overlying gastric mucosa and the presence of blood vessels underneath the ulceration site. Lack of the typical carcinoid syndrome should never exclude the carcinoid tumors; such tumors as reported in this case may present with manifestations that mimic other gastric disorders. Cases with upper GIT bleeding should be endoscoped<sup>[14]</sup>. Although, endoscopy is an invasive maneuver yet it helps to confirm the diagnosis and achieve a variety of therapeutic approaches in the same setting. The lesions in this case were flat and ulcerated, endoscopic mucosal resection was not feasible and in addition the presence of visible vessels beneath the ulcerated surface raise the risk of bleeding, and that is why we decided to operate in this patient. Endoscopic examination is a horror for some patients and this may delay the diagnosis and that is why verbal reassurance is required before the procedure<sup>[15]</sup>. Typically that was happened with this case, she refused to be endoscoped for her previous two attacks of melena and after oral discussion about the steps, benefits and risks of the procedure she agreed to be endoscoped. Fortunately the patient was diagnosed before occurrence of extra-gastric spread, a sequele if occurred would complicate the management plan and subsequently her survival. No consensus has been reached regarding the role of medical treatment versus surgical treatment. Medical treatment includes octreotide therapy or dietary modification to acidify the stomach. If medical

therapy is chosen, patients require close endoscopic surveillance<sup>[3]</sup>. For tumors larger than 1 cm, multicentric tumors, or recurrent tumors, laparoscopic antrectomy is most effective and leads to a reduction of gastrin levels and regression of carcinoid tumors<sup>[16]</sup>. Our case was treated by subtotal gastrectomy due to causes mentioned before. No postoperative recurrence was observed through the follow up period (30 months in this case). Close follow up would pick up cases with tumor recurrence and potentially improve the patient survival.

## REFERENCES

1. Onaitis MW, Kirshbom PM, Hayward TZ, Quayle FJ, Feldman JM, Seigler HF, Tyler DS. Gastrointestinal carcinoids: characterization by site of origin and hormone production. *Ann Surg* 2000; 232: 549-556.
2. Chuah SK, Hu TH, Kuo CM, Chiu KW, Kuo CH, Wu KL, Chou YP, Lu SN, Chiou SS, Changchien CS, Eng HL. Upper gastrointestinal carcinoid tumors incidentally found by endoscopic examinations. *World J Gastroenterol* 2005; 11: 7028-703.
3. Modlin IM, Sandor A. An analysis of 8305 cases of carcinoid tumors. *Cancer* 1997; 79: 813-829.
4. Rybalov S, Kotler DP. Gastric carcinoids in a patient with pernicious anemia and familial adenomatous polyposis. *J Clin Gastroenterol* 2002; 35: 249-252.
5. Rindi G, Luinetti O, Cornaggia M, Capella C, Solcia E. Three subtypes of gastric argyrophil carcinoid and the gastric neuroendocrine carcinoma: a clinicopathologic study. *Gastroenterology* 1993; 104: 994-1006.
6. Creutzfeldt W. The achlorhydria-carcinoid sequence: role of gastrin. *Digestion* 1988; 39: 61-79.
7. Fallah MA, Prakash C, Edmundowicz S. Acute gastrointestinal bleeding. *Med Clin North Am* 2000; 84: 1183-208.
8. Gilani N, Ramirez FC. Endoscopic resection of an ampullary carcinoid presenting with upper gastrointestinal bleeding: A case report and review of the literature. *World J Gastroenterol* 2007; 13: 1268-1270.
9. Ahlman H, Kolby L, Lundell L, Olbe L, Wangberg B, Granerus G, Grimelius L, Nilsson O. Clinical management of gastric carcinoid tumors. *Digestion* 1994; 55: 77-85.
10. Borch K. Atrophic gastritis and gastric carcinoid tumours. *Ann Med* 1989; 21: 291-297
11. Higham AD, Dimaline R, Varro A, Attwood S, Armstrong G, Dockray GJ, Thompson DG. Octreotide suppression test predicts beneficial outcome from antrectomy in a patient with gastric carcinoid tumor. *Gastroenterology* 1998; 114: 817-822.
12. Dakin GF, Warner RR, Pomp A, Salky B, Inabnet WB. Presentation, treatment, and outcome of type I gastric carcinoid tumors. *J Surg Oncol* 2006; 93: 368-372.
13. Sjoblom SM. Clinical presentation and prognosis of gastrointestinal carcinoid tumors. *Scand J Gastroenterol* 1988; 23: 779-787.
14. Cappell MS; Medscape. Therapeutic endoscopy for acute upper gastrointestinal bleeding. *Nat Rev Gastroenterol Hepatol*. 2010; 7: 214-29.
15. Pehlivan S, Ovayolu N, Koruk M, Pehlivan Y, Ovayolu O, Gülşen MT. Effect of providing information to the patient about upper gastrointestinal endoscopy on the patient's perception, compliance and anxiety level associated with the procedure. *Turk J Gastroenterol*. 2011; 22:10-17.
16. Hwang EC, Sagel SS, Brunt EM. Best cases from the AFIP: multiple gastric carcinoids. *Radiographic*. 2009; 29:1206-9.

Peer reviewer: Jeng ,Kuo-Shyang, MD, FACS, Professor of

Refaey MM *et al.* Multiple gastric carcinoids and melena

Surgery. (HPB Surgery and Liver Transplantation), Vice President of Far Eastern Memorial Hospital, 6F., No.21, Sec. 2, Nanya W. Rd., Banciao Dist., New Taipei City 22056, Taiwan; Rommel Burbano,

Laboratório de Citogenética Humana, Instituto de Ciências Biológicas, Campus Universitário do Guamá/Universidade Federal do Pará, Av. Augusto Correa, 01, CEP 66075-110, Belém – Pará, Brazil.