

Journal of

Gastroenterology and Hepatology Research

Online Submissions: <http://www.ghrnet.org/index./joghr/>
doi: 10.6051/j.issn.2224-3992.2012.02.032

Journal of GHR 2012 February 21; 1(1): 16-19
ISSN 2224-3992 (print) ISSN 2224-6509 (online)

CASE REPORT

Effect of Pegylated Interferon Therapy After Curative Treatment of Hepatitis C Virus-Related Hepatocellular Carcinoma - A Case Report

Hiroki Nishikawa, Yukio Osaki, Ryuichi Kita, Toru Kimura, Eriko Iguchi, Yorimitsu Koshikawa, Soichiro Ako, Tadashi Inuzuka, Haruhiko Takeda, Jun Nakajima, Fumihiko Matsuda, Azusa Sakamoto, Sinichiro Henmi, Keiichi Hatamaru, Tetsuro Ishikawa, Sumio Saito

Hiroki Nishikawa, Yukio Osaki, Ryuichi Kita, Toru Kimura, Eriko Iguchi, Yorimitsu Koshikawa, Soichiro Ako, Tadashi Inuzuka, Haruhiko Takeda, Jun Nakajima, Fumihiko Matsuda, Azusa Sakamoto, Sinichiro Henmi, Keiichi Hatamaru, Tetsuro Ishikawa, Sumio Saito, Department of Gastroenterology and Hepatology, Osaka Red Cross Hospital, Osaka, 543-0027, Japan

Correspondence to: Hiroki Nishikawa, MD, Department of Gastroenterology and Hepatology, Osaka Red Cross Hospital, 5-30 Fudegasaki-cho, Tennoji-ku, Osaka, 543-0027, Japan. h-nishikawa@osaka-med.jrc.or.jp

Telephone: +81-6-6774-5111 Fax: +81-6-6774-5131

Received: December 14, 2012 Revised: January 13, 2012

Accepted: January 23, 2012

Published online: February 21, 2012

© 2012 Thomson research. All rights reserved.

Keywords: HCC(hepatocellular carcinoma); Low dose Peg-IFN α 2a; SVR; RFA; Recurrence

Nishikawa H, Osaki Y, Kita R, Kimura T, Iguchi E, Koshikawa Y, Ako S, Inuzuka T, Takeda H, Nakajima J, Matsuda F, Sakamoto A, Henmi S, Hatamaru K, Ishikawa T, Saito S. Effect of pegylated interferon therapy after curative treatment of hepatitis C virus-related hepatocellular carcinoma - A Case Report. *Journal of Gastroenterology and Hepatology Research* 2012; 1(1): 16-19 Available from: URL: <http://www.ghrnet.org/index./joghr/>

ABSTRACT

The 5-year recurrence rate of hepatocellular carcinoma (HCC) is known to be as high as 60-100% even if radically treated by radiofrequency ablation (RFA) or surgery. Accordingly it is required to treat background liver disease after radical treatment of HCC. A 50s male with hepatitis C virus-related HCC (Genotype1b, 300KIU/mL) underwent RFA followed by pegylated interferon (PEG-IFN) α -2b and ribavirin combination therapy. Although the patient had an early virological response (EVR), he experienced a relapse. The patient was treated with low-dose Peg-IFN α 2a administration (90 μ g/2-4 weeks) for persistently normal alanine aminotransferase (ALT) and was followed up.

Peg-IFN- α 2a administration was initiated at doses of 90 μ g. HCV RNA test becomes negative after single dose, and then the patient remained negative HCV RNA result and normal ALT level. After three months, recurrence of HCC 1.5 cm in size located at segment 2 of the liver was observed and treated with RFA. After that, Peg-IFN- α 2a administration was restarted and he had persistently negative HCV RNA result, normal ALT level, and normal alpha-fetoprotein (AFP) level. Six months after the end of IFN treatment, his HCV-RNA test was negative, that is to say, he obtained a sustained virological response (SVR). Moreover, there has been no evidence of HCC recurrence for 24 months after the second treatment of RFA.

The HCC patient with genotype 1b and high viral load was treated with radical RFA followed by low-dose Peg-IFN α 2a, and his HCV RNA level became negative, and he obtained an SVR, and ALT and AFP levels became normal. It was speculated that the Peg-IFN- α 2a low-dose administration might contribute to preventing subsequent recurrence of HCC.

INTRODUCTION

In chronic hepatitis C, repeated liver cell necrosis and regeneration due to persistent inflammation promote hepatic fibrosis, which is associated with increased cancer incidence and leads to cirrhosis. About 7% per year of patients with cirrhosis develop cancer in Japan^[1]. Hepatocellular carcinoma (HCC) is characterized by multicentric carcinogenesis. In addition, it is known that the 5-year recurrence rate of HCC is as high as 60-100% even if the primary HCC is treated by radiofrequency ablation (RFA) or surgery radically. Accordingly it is required to treat background liver disease after radical treatment of HCC, and virological response after antiviral treatment becomes important in terms of fibrosis suppression and inhibition of hepatic carcinogenesis^[2].

In antiviral treatment for chronic hepatitis C, pegylated interferon (PEG-IFN) plus ribavirin (RBV) therapy achieves successfully 80 to 90% sustained virological response (SVR) rate in patients with genotype 2, and even in resistant cases, about 50% in patients with genotype 1 and high viral load; the treatment outcome has been improved remarkably. However, a complete response rate is low in elderly at especially high carcinogenic risk or patients with cirrhosis, and measures for patients with no complete responses with PEG-IFN plus RBV therapy become important^[3].

In the USA, a study reported that the low-dose, long-term PEG-IFN administration decreased cancer incidence in patients with cirrhosis^[4]. In Japan, a study was performed to determine whether carcinogenesis was inhibited by interferon (IFN) therapy following HCC treatment, and showed that effective inhibition of carcinogenesis by IFN therapy in many cases^[2, 5-8]. In particularly, PEG-IFN- α 2a as pegylated interferon drug can be used alone and can be expected to provide sufficient effect even if it is administered

biweekly because of its long half-life in blood.

We report rare experience of a primary HCC patient with genotype 1b and high viral load who was treated with radical RFA followed by PEG-IFN- α 2b plus RBV therapy with relapse but then achieved an SVR by low-dose PEG-IFN- α 2a administration.

CASE PRESENTATION

Case: 59-year-old male; **Chief Complaint:** Intensive examination and treatment for HCC; **Past Medical History:** 1978 Transfusion was performed when bleeding duodenal ulcer was treated; 1996 Chronic hepatitis C was pointed out; 2003 Endoscopic hemostasis was performed to treat gastric ulcer bleeding.

Present Illness: While attending to another hospital due to cirrhosis caused by chronic hepatitis C, suspicious lesion indicating HCC about 2 cm in size located at segment 6 was pointed out by computed tomography (CT) scan for screening. The patient was referred to our hospital and was hospitalized for the purpose of intensive examination and treatment.

Condition on Admission: Height 180 cm; weight 94 kg; blood pressure 138/68 mmHg; temperature 36.6 degrees Celsius; heart sound and pulmonary sound, normal. No comment in particular. The test results on admission are shown in Table 1.

Hospital Course 1

On December, 2007, single HCC 2.3 cm in size located at segment 6 was diagnosed by CT during hepatic arteriography (CTHA) and CT during arterial portography (CTAP) before percutaneous radio-frequency ablation (PRFA) (Figure 1). After transcatheter arterial injection treatment (TAI), PRFA was performed (using 3-cm Cool-tip needle) on December, 2007. This procedure finished without complication, complete ablation was confirmed by dynamic CT taken for effect measurement (Figure 1), and the patient was discharged.

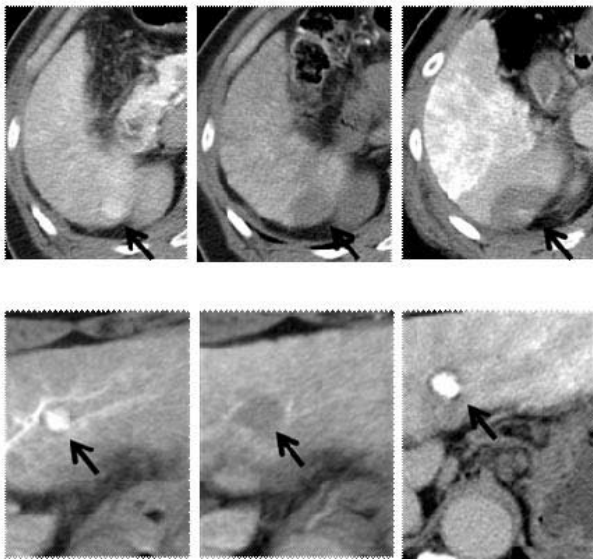


Figure 1 The upper is the image of hepatocellular carcinoma at the time of first treatment in December, 2007. (Upper left) CTHA, contrast material injected; (Upper middle) CTAP, defect region is found in hepatocellular carcinoma about 2.3 cm in size located at segment 6; (Upper right, dynamic CT) the patient underwent radiofrequency ablation and achieved complete ablation. The lower is the image of recurrence hepatocellular carcinoma at the time of second treatment in November, 2009. (Lower left) CTHA, contrast material injected; (Lower middle) CTAP, defect region is found in hepatocellular carcinoma about 1.5 cm in size located at segment 2; (Lower right, dynamic CT) the patient underwent radiofrequency ablation and achieved complete ablation.

Hospital Course 2

The combination of Peg-IFN- α 2b 0.5 μ g/kg plus ribavirin 1000 mg therapy for virus elimination as well as patient's wish was initiated in March, 2008. Dose finding was based on platelet count or other laboratory data because it was a cirrhosis case. Figure 2 shows changes in quantity of HCV RNA, blood cell count, and ALT level during IFN. HCV RNA showed negative results (by real time PCR) at 10 weeks from the start of administration. We paid attention to hematopenia and the patient completed 48 weeks administration on February, 2009. The dose was fixed at Peg-IFN- α 2b 0.5 μ g/kg and ribavirin 1000 mg.

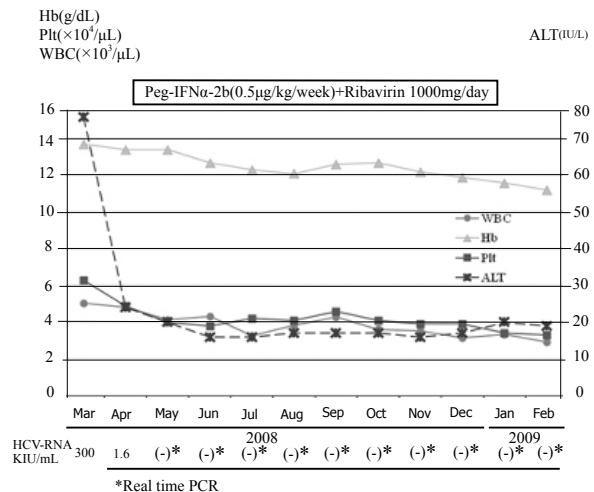


Figure 2 Changes in quantity of HCV RNA, blood cell count, and ALT level during Peg-IFN plus RBV combination therapy.

Hospital Course 3

Relapse was confirmed by blood test at 6 months after the combination of Peg-IFN- α 2b 0.5 μ g/kg plus ribavirin 1000 mg therapy finished (HCV RNA, 3.2 Log IU/mL; by RT-PCR). Therefore we consulted with the patient again, and started low-dose Peg-IFN α 2a administration (90 μ g/2-4 weeks) for persistently normal ALT.

Peg-IFN- α 2a administration was initiated at doses of 90 μ g. HCV RNA test becomes negative after single dose immediately. Although the patient remained negative HCV RNA result and normal ALT level, recurrence of HCC 1.5 cm in size located at segment 2 of the liver was observed by dynamic CT in November, 2009. (Figure 1) Accordingly, Peg-IFN- α 2a 90 μ g administration was discontinued and PRFA was performed in December, 2009, and complete ablation was confirmed using dynamic CT. (Figure 1) HCV RNA result was 4.5 Log IU/mL in January, 2010, which showed the patient was in the relapsed setting, and ALT level was elevated to 75 IU/L again. Therefore Peg-IFN- α 2a 90 μ g administration was restarted. We administered Peg-IFN- α 2a 90 μ g to the patient with attention to hematopenia. Negative HCV RNA result was confirmed in March, 2010. Elevated ALT recovered to normal level. We continued to administer Peg-IFN- α 2a 90 μ g/2-4 weeks, and the patient has remained negative HCV RNA result, normal ALT and AFP levels (Figure 3). In March, 2011, we discontinued to administer low dose Peg-IFN- α 2a because of his wish. Despite the discontinuation of IFN treatment, his HCV-RNA test was negative 6 months after the end of IFN treatment, that is, he obtained an SVR. For the present, there has been no evidence of HCC recurrence for about 24 months after the second treatment of RFA.

DISCUSSION

Spontaneous recovery from chronic hepatitis C occurs extremely rarely. If left untreated, chronic hepatitis C can lead to cirrhosis and progress to HCC. Regarding antiviral treatment, about half of patients with genotype 1b and high viral load who were treated with PEG-IFN plus RBV therapy, and about 80 to 90% of patients with genotype 2 have been achieved SVR; the combination of Peg-IFN plus RBV therapy has been becomes the standard therapy for high viral load case^[3].

The predictive factor for therapeutic response includes host side factor such as age, sex, the degree of hepatic fibrosis progression, fatty change, insulin resistance, and IL28B genetic polymorphism^[9-13]; virus side factor such as genotype, viral load, mutation in interferon sensitivity determining region (ISDR)^[14], and core amino acid mutation^[15]; therapeutic side factor such as dose and duration of IFN administration, and adherence to the Peg-IFN plus RBV combination therapy.

Genotype 1b and high viral load are found in cirrhosis patients with or elderly persons and many of them are included in resistant case. In addition, these patients cannot maintain adequate drug adherence because of decreased platelet and white blood cell and physical burden or other reasons; it is considered that their treatment outcomes of IFN are poorer than patients with chronic hepatitis or young adults from these reasons.

The patient in our study has genotype 1b and high viral load as well as cirrhosis that is refractory to IFN. Furthermore, the patient achieved early virological response (EVR) in spite of his condition that dose of Peg-IFN- α 2b had to be reduced because of low platelet level. It seems that core amino acid mutation (70th/91th) has suitable conditions for complete response [e.g., virus side factor such as wild type/wild type and ISDR (3)].

This patient developed recurrence in the liver about 2 years after RFA for primary HCC. Generally the first recurrence following HCC treated radically is hard to control even by IFN treatment which significantly suppresses at the second or later recurrence^[16]. In our case, low-dose Peg-IFN- α 2a administration is expected to suppress the second or later recurrence because he obtained an SVR by the low-dose Peg-IFN- α 2a therapy.

Also, it should be noted that during both PEG-IFN- α 2b plus RBV therapy and low-dose Peg-IFN- α 2a administration, the patient has had a course without problem although the platelet count changes at extremely low levels. When response to IFN treatment is benign like this case, it is considered as significant to continue treatment by blood test carefully and follow-up strictly, even if hematopenia is remarkable.

PEG-IFN- α 2a as pegylated interferon drug can be used alone and can be expected to provide sufficient effect even if it is administered biweekly as low-dose, long-term administration because of its long half-life in blood. In this case, the patient continues to receive Peg-IFN- α 2 at 90 μ g/2-4 weeks since biweekly administration decreases platelet count extremely. However, its long half-life in blood avoids frequent IFN administration and contributes to maintain the patient's quality of life; which can be considered as the advantages of low-dose Peg-IFN- α 2a therapy.

CONCLUSION

We had an experience of primary HCC patient with genotype 1b and high viral load was treated with RFA followed by PEG-IFN- α 2b plus RBV therapy with relapse but SVR was obtained by low-dose PEG-IFN- α 2a administration. When response to the first IFN treatment is benign like this case, even if the patient developed relapse, low-dose PEG-IFN- α 2a administration can lead to persistent negative HCV-RNA level and may contribute to significant suppression of HCC.

ACKNOWLEDGEMENTS

There is no one who contributed towards the study by making substantial contributions to conception, design, acquisition of data, or analysis and interpretation of data.

REFERENCES

- 1 Yoshida H, Shiratori Y, Moriyama M, Arakawa Y, Ide T, Sata M, Inoue O, Yano M, Tanaka M, Fujiyama S, Nishiguchi S, Kuroki T, Imazeki F, Yokosuka O, Kinoyama S, Yamada G, Omata M. Interferon therapy reduces the risk for hepatocellular carcinoma: national surveillance program of cirrhotic and noncirrhotic patients with chronic hepatitis C in Japan. IHIT Study Group. *Ann Intern Med* 1999; **131**:174-181
- 2 Shiratori Y, Shiina S, Teratani T, Imamura M, Obi S, Sato S, Koike Y, Yoshida H, Omata M. Interferon therapy after tumor ablation improves prognosis in patients with hepatocellular carcinoma associated with hepatitis C virus. *Ann Intern Med* 2003; **138**: 299-306
- 3 Fried MW, Shiffman ML, Reddy KR, Smith C, Marinos G, Gonçales FL Jr, Häussinger D, Diago M, Carosi G, Dhumeaux D, Craxi A, Lin A, Hoffman J, Yu J. Peginterferon alfa-2a plus ribavirin for chronic hepatitis C virus infection. *N Engl J Med* 2002; **347**: 975-982
- 4 Lok AS, Everhart JE, Wright EC, Di Bisceglie AM, Kim HY, Sterling RK, Everson GT, Lindsay KL, Lee WM, Bonkovsky HL, Dienstag JL, Ghany MG, Morishima C, Morgan TR; HALT-C Trial Group. Maintenance Peginterferon Therapy and Other Factors Associated With Hepatocellular Carcinoma in Patients With Advanced Hepatitis C. *Gastroenterology* 2011; **140**(3): 840-849
- 5 Nishiguchi S, Shiomi S, Nakatani S, Takeda T, Fukuda K, Tamori A, Habu D, Tanaka T. Prevention of hepatocellular carcinoma in patients with chronic active hepatitis C and cirrhosis. *Lancet* 2001; **357**:196-197
- 6 Arase Y, Ikeda K, Suzuki F, Suzuki Y, Kobayashi M, Akuta N, Hosaka T, Sezaki H, Yatsuji H, Kawamura Y, Kobayashi M, Kumada H. Prolonged interferon therapy reduces hepatocarcinogenesis in aged patients with chronic hepatitis C. *J Med Virol* 2007; **79**:1095-1102
- 7 Kubo S, Nishiguchi S, Hirohashi K, Tanaka H, Shuto T, Kinoshita H. Randomised clinical trial of long-term outcome after resection of hepatitis C virus-related hepatocellular carcinoma by postoperative interferon therapy. *Br J Surg* 2002; **89**: 418-422
- 8 Kudo M, Sakaguchi Y, Chung H, Hatanaka K, Hagiwara S, Ishikawa E, Takahashi S, Kitai S, Inoue T, Minami Y, Ueshima K. Long-term interferon maintenance therapy improves survival in patients with HCV-related hepatocellular carcinoma after curative radiofrequency ablation. *Oncology* 2007; **72**: 132-138
- 9 Ge D, Fellay J, Thompson AJ, Simon JS, Shianna KV, Urban TJ, Heinzen EL, Qiu P, Bertelsen AH, Muir AJ, Sulkowski M, McHutchison JG, Goldstein DB. Genetic variation in IL28B predicts hepatitis C treatment-induced viral clearance. *Nature* 2009; **461**: 399-401
- 10 Tanaka Y, Nishida N, Sugiyama M, Kurosaki M, Matsuura K, Sakamoto N, Nakagawa M, Korenaga M, Hino K, Hige S, Ito Y, Mita E, Tanaka E, Mochida S, Murawaki Y, Honda M, Sakai A, Hiasa Y, Nishiguchi S, Koike A, Sakaida I, Imamura M, Ito K, Yano K, Masaki N, Sugauchi F, Izumi N, Tokunaga K, Mizokami M. Genome-wide association of IL28B with response to pegylated interferon-alpha and ribavirin therapy for chronic hepatitis C. *Nat Genet* 2009; **41**: 1105-1109
- 11 Suppiah V, Moldovan M, Ahlenstiel G, Berg T, Weltman M, Abate ML, Bassendine M, Spengler U, Dore GJ, Powell E,

- Riordan S, Sheridan D, Smedile A, Fragomeli V, Müller T, Bahlo M, Stewart GJ, Booth DR, George J. IL28B is associated with response to chronic hepatitis C interferon-α and ribavirin therapy. *Nat Genet* 2009; **41**:1100-1104
- 12 Rauch A, Kutalik Z, Descombes P, Cai T, Di Iulio J, Mueller T, Bochud M, Battegay M, Bernasconi E, Borovicka J, Colombo S, Cerny A, Dufour JF, Furrer H, Günthard HF, Heim M, Hirschel B, Malinverni R, Moradpour D, Mühlhaupt B, Witteck A, Beckmann JS, Berg T, Bergmann S, Negro F, Telenti A, Bochud PY; Swiss Hepatitis C Cohort Study; Swiss HIV Cohort Study. Genetic variation in IL28B is associated with chronic hepatitis C and treatment failure — a genome-wide association study. *Gastroenterology* 2010; **138**:1338-1345
- 13 Thomas DL, Thio CL, Martin MP, Qi Y, Ge D, O'Huigin C, Kidd J, Kidd K, Khakoo SI, Alexander G, Goedert JJ, Kirk GD, Donfield SM, Rosen HR, Tobler LH, Busch MP, McHutchison JG, Goldstein DB, Carrington M. Genetic variation in IL28B and spontaneous clearance of hepatitis C virus. *Nature* 2009; **461**: 798-801
- 14 Enomoto N, Sakuma I, Asahina Y, Kurosaki M, Murakami T, Yamamoto C, Ogura Y, Izumi N, Marumo F, Sato C. Mutations in the nonstructural protein 5A gene and response to interferon in patients with chronic hepatitis C virus 1b infection. *N Eng J Med* 1996; **334**: 77-81
- 15 Akuta N, Suzuki F, Kawamura Y, Yatsuji H, Sezaki H, Suzuki Y, Hosaka T, Kobayashi M, Kobayashi M, Arase Y, Ikeda K, Kumada H. Predictive factors of early and sustained responses to peginterferon plus ribavirin combination therapy in Japanese patients infected with hepatitis C virus genotype 1b: amino acid substitutions in the core region and low-density lipoprotein cholesterol levels. *J Hepatol* 2007; **46**: 403-410
- 16 Shiratori Y, Shiina S, Teratani T, Imamura M, Obi S, Sato S, Koike Y, Yoshida H, Omata M. Interferon Therapy after Tumor Ablation Improves Prognosis in Patients with Hepatocellular Carcinoma Associated with Hepatitis C virus. *Ann Intern Med* 2003; **138**: 299-306

Peer reviewers: Luis Rodrigo, Professor, Department of Gastroenterology, University Hospital Central of Asturias, c/ Celestino Villamil s. n°, 33.006. Oviedo. Spain; Edoardo G. Giannini, MD, PhD, Assistant Professor, Gastroenterology Unit, Department of Internal Medicine, University of Genoa, Viale Benedetto XV, no. 6, 16132, Genova, Italy; Soung Won Jeong, MD, PhD, Assistant Professor/Hepatologist, Division of Gastroenterology, Department of Internal Medicine, Soonchunhyang University Hospital, 22, Daesagwan-gil, Yongsan-gu, Seoul, 140-743, Korea.