

Portal Biliopathy

Premashish J Halder

Premashish J Halder, Department of GI Surgery, Jagjivanram Hospital, Maratha Mandir Lane, Mumbai Central, MUMBAI – 400 008, India

Correspondence to: Premashish J Halder, Department of GI Surgery, Jagjivanram Hospital, Maratha Mandir Lane, Mumbai Central, MUMBAI, 400 008, India. pjhaldar@gmail.com

Telephone: +0919004490585

Received: July 4, 2012

Revised: November 30, 2012

Accepted: December 3, 2012

Published online: April 21, 2013

ABSTRACT

Portal biliopathy is caused by large collaterals compressing the biliary tree in patients with long-standing portal hypertension. The natural history of the condition is still unknown. A number of contentious and unresolved issues relating to this complex condition are discussed.

© 2013 ACT. All rights reserved.

Key words: Portal biliopathy; Portal vein thrombosis; Portal cavernoma; Pericholedochal varices; Portal systemic shunt

Halder PJ. Portal Biliopathy. *Journal of Gastroenterology and Hepatology Research* 2013; 2(4): 494-497 Available from: URL: <http://www.ghrnet.org/index./joghr/>

INTRODUCTION

Portal biliopathy (PB) is a clinical rarity with myriad presentations. With increasing awareness the reported incidence in the literature is on the rise. As a clinical entity it was first described by Sarin *et al*^[1], though the first description came from Fraser *et al*^[2] way back in 1944.

Portal biliopathy refers to an abnormality of the entire biliary tract including the extra hepatic and intra hepatic ducts, cystic duct and the gall bladder in patients with portal vein thrombosis leading to portal hypertension (Figure 1).

Though findings of PB may be seen on imaging in patients with extra hepatic portal vein obstruction (EHPVO), only a small proportion of these individuals are symptomatic (5% - 33%)^[3,4,5]. EHPVO is the most frequent cause of PB (81% - 100%)^[3,4,5]. PB usually results from the long-standing portal hypertension that results in the development of large collaterals in the biliary region resulting

in a portal cavernoma (Figures 2 and 3).

The clinical presentation may be an asymptomatic patient with

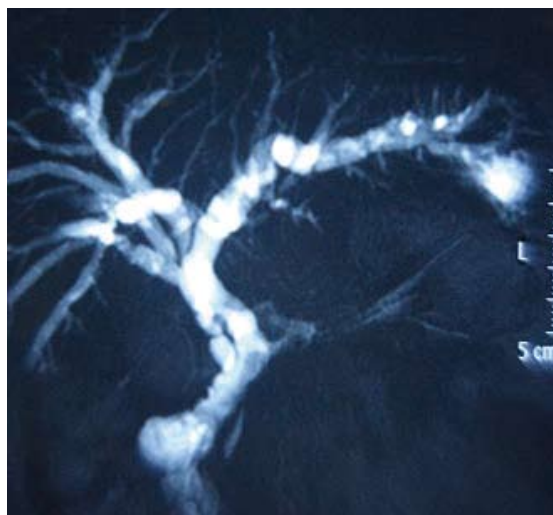


Figure 1 Showing the changes of portal biliopathy in the biliary tree on imaging.

imaging findings on Endoscopic Retrograde Cholangiography (ERC) or MRCP, or patient may be symptomatic with features of chronic cholestasis due to biliary strictures or biliary pain or acute cholangitis caused by biliary calculi.

Certain issues regarding Portal biliopathy are discussed below: (1) Can ERCP findings predict reversibility of Portal biliopathy? (2) Role of Endoscopic ultrasound (EUS); (3) Is there a role for direct one stage surgery for cases of PB? (4) Is there a role for early surgery in patients with PB? (5) Shuntable vein is not available – What should be the strategy? (6) Is there any place for Liver transplantation in PB?

CAN ERCP FINDINGS PREDICT REVERSIBILITY OF PORTAL BILIOPATHY?

ERCP continues to be the mainstay in the diagnosis of PB. ERCP findings of PB include bile duct strictures and irregularities, dilatations, displacements and angulations besides filling defects caused by intraluminal bulgings of the pericholedochal varices or stones in the biliary system (Figure 4).

Can the findings on ERCP predict the reversibility of the biliary

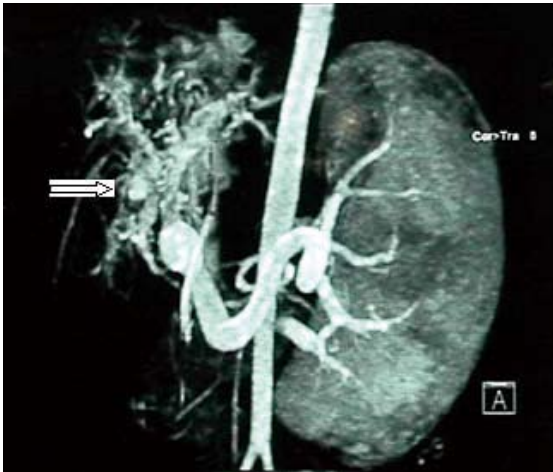

Figure 2 Portal cavernoma in a case of portal biliopathy (marked by arrow).

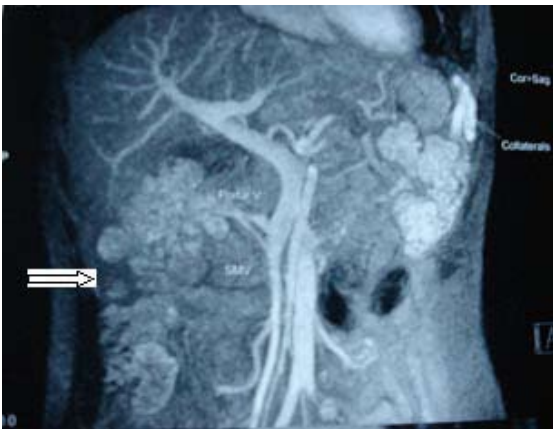

Figure 3 CT Angiogram showing extensive collaterals in the pericholedochal area, marked by block arrow.

changes of PB?

In a study of 12 patients of PB, Shin *et al*^[6] proposed imaging features to stratify PB patients among three types that were originally described by Dhiman *et al*^[3] as varicoid, fibrotic and mixed types depending on the appearance of the bile duct at the point of obstruction. It is proposed that varicoid PB is biliary obstruction by large collateral (paracholedochal) veins that compress and distort the extra hepatic bile duct, while fibrotic PB results from smaller intramural (epicholedochal) collaterals visible as narrowed, thickened and densely enhancing bile ducts.

What is the clinical significance of the above findings? Varicoid PB may be reversible with portal systemic shunt, but the fibrotic type is not, and this is seen in long standing PB where fibrotic lesions predominate^[7].

Walsher *et al*^[8], however, propose that the “fixed” biliary obstruction seen in the fibrotic variety is likely to be a result of chronic kinking of the extra hepatic bile duct by the pancreaticoduodenal veins, rather than ischemia or inflammation produced by chronic hypertrophy of the epicholedochal venous network in the setting of portal venous thrombosis.

Role of Endoscopic ultrasound (EUS)

EUS can serve to diagnose biliary varices in patients with EHPVO and jaundice. In a study by Palazzo *et al*^[9], EUS identified biliary varices in the wall of the common bile duct in 16 out of 21 asymptomatic patients (76%), which were not visible on computed tomography and ultrasonography.

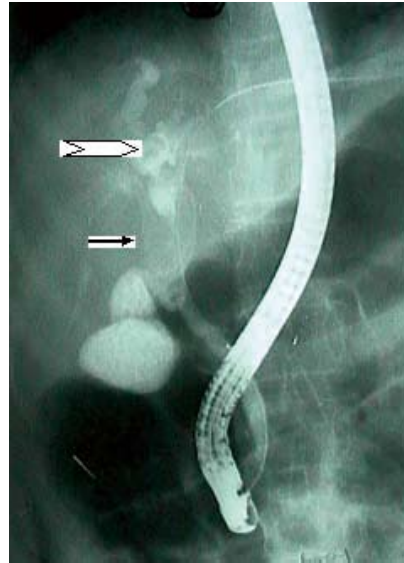


Figure 4 ERCP showing calculus in CBD (thin arrow) and dilated biliary radicals (block arrow) in a patient with portal biliopathy.

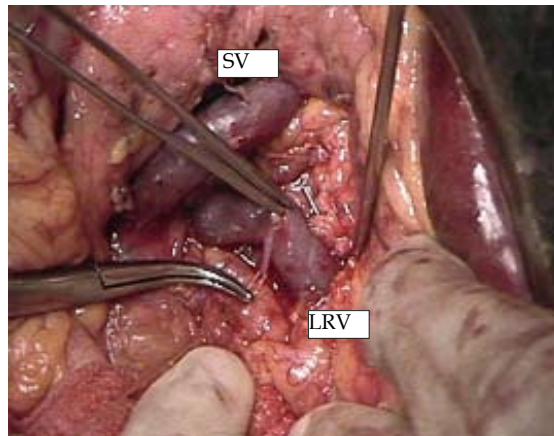


Figure 5 Splenorenal shunt being performed for portal biliopathy. (SV = Splenic vein, LRV = Left Renal vein).

Umphress *et al*^[10] have described a patient with obstructive jaundice related to portal vein thrombosis in whom the diagnosis was made by EUS and Doppler ultrasound that demonstrated the venous collaterals around the bile duct, which were not picked up by other imaging modalities.

EUS can also be useful in picking up varices in the papillary area, which can prevent bleeding arising from sphincterotomy or trauma during ERCP that can lead to torrential bleeding. EUS can also differentiate strictures caused by portal biliopathy from those due to malignancy.

Thus EUS is becoming an integral part of the management protocol of portal biliopathy.

Standard treatment outline in Portal Biliopathy: (1) Sphincteromy, balloon dilatation, endoprosthesis – for jaundice, cholangitis, biliary stenosis, bile duct stones; (2) Portal systemic shunt – for persistent biliary obstruction despite endoscopic treatment / failure/non – feasibility of endoscopic treatment. (Figure 5); (3) Bilioenteric anastomosis – for persistent biliary obstruction despite a portal systemic shunt operation. This surgery is recommended only as a second stage surgery after a shunt surgery is done^[1,3,11,12]; (4) Asymptomatic cases detected on abnormal LFTs/ imaging are best kept under observation, as the entity has been documented to be progressive^[12] and the natural history is still unknown.

IS THERE A ROLE FOR DIRECT ONE STAGE SURGERY FOR CASES OF PB?

Vibert *et al*^[13] showed a reduction in biliary obstructive symptoms within 3 months of portal – systemic shunt surgery in 70% patients with portal biliopathy. However, 50% of these patients subsequently required a biliary bypass. Bile duct obstruction may persist because of fibrosis in the pericholedochal areas and stricture formation. These patients require a biliary bypass, which is rendered safer with a portal – systemic shunt, as attempts without a shunt procedure have resulted in severe bleeding, complications and death^[1,3,4,5,11].

D’Souza *et al*^[14] have described a one-stage procedure combining a non – selective portal systemic shunt surgery with biliary bypass, performed on a 24-year-old man with a tight biliary stricture resulting from PB. The hepaticoducho – jejunostomy was safely and effectively performed using the Pringle maneuver to control bleeding, thereby avoiding a second surgery. Patient has no problems at 18 months follow – up with normal liver function tests.

While in the above – mentioned report, a successful one – stage bilioenteric anastomosis was successfully completed, the evidence at present does not recommend a one – stage surgery for dealing with biliary problems of PB.

Could intra operative pharmacological control of portal hypertension reduce the bleeding and allow a one stage biliary surgery? The answer is not clear, though the use of vasoactive drugs in non – shuntable vein status is mentioned in the appropriate section below.

IS THERE A ROLE FOR EARLY SURGERY IN PATIENTS WITH PB?

Should decompressive shunt surgery be done only when biliary obstruction is recurrent and progressive or is there a place for early surgery in patients with portal biliopathy?

The biliary strictures of PB are presumed to be of ischemic etiology. Histologic studies have shown that, apart from dilatation of the peri - portal collaterals, there is also neogenesis of vessels and formation of connective tissue occurring with increasing duration of thrombosis, which results in a tumor – like solid tissue that does not disappear after shunt surgery^[11,15] similar to the fibrotic lesions described by Dhiman^[3] as well as others. Since the duration of thrombosis is an important factor in the development of these fibrotic lesions, there may be a role of performing an early shunt procedure to prevent the progression to fibrosis and possibly intervene at the stage of reversibility of the biliary changes of PB. By the same token “asymptomatic” patients may be considered for early shunt procedure before they progress to development of biliary strictures, as the disease is progressive and the natural history of the disease is unknown^[12].

Relying only on endoscopic treatment for prolonged periods is fraught with the possibility of progression of the biliary strictures making it more difficult as well as dangerous for dilatation/ stenting resulting in higher failures with passage of time. The surgery also becomes more difficult with longer periods of endoscopic treatment with higher complications, morbidity and mortality. Thus there may be a strong case for considering early surgery, but the issue at present is controversial.

SHUNTABLE VEIN IS NOT AVAILABLE – WHAT SHOULD BE THE STRATEGY?

Camerio *et al*^[16] state that in cases where portal – systemic Spleno –

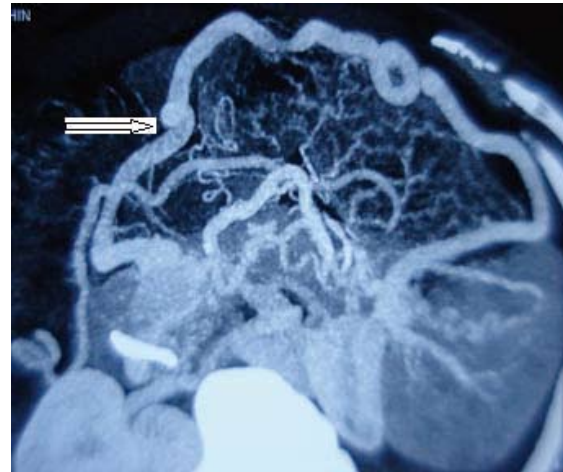


Figure 6 CT Angiogram showing portal cavernoma with non-visualized splenic vein. A dilated collateral vein is seen from an omental vein. (Block arrow).

renal or Mesenterico – caval shunting is not feasible due to extensive thrombosis of the Splenic and Superior Mesenteric veins, a make – shift portal – systemic shunt between a suitable portal varix and the caval system can be an interesting alternative. In 3 patients in this study, the make – shift portal – systemic shunt was performed by direct anastomosis in 2 patients and by a prosthetic interposition in 1 case. Shunting was between a splanchnic varix and the Inferior Vena Cava in 2 cases and the left renal vein in 1 case. Postoperative morbidity was nil and follow – up ranging between 2 – 12 years showed good results and no recurrence of biliary obstruction.

Figure 6 below shows a case where no shuntable vein was available except a dilated collateral vein.

If no shuntable vein is available, minimum surgical intervention should be done to avoid bleeding. Vasoactive agents such as Somatostatin, Octreotide, Terlipressin, that reduce the portal hypertension can be infused during biliary surgery in patients without prior shunt surgery to decrease the blood loss^[17,18].

Endoscopic management of the biliary problems of PB is the other alternative in non – shuntable vein status, avoiding the make – shift shunts as described above. The current practice is to put multiple stents instead of single stents as (1) Due to lithogenicity of the bile, single stents have a high incidence of blockages needing frequent and early stent exchanges and (2) With multiple stents, it has been noted that the diameter of the bile duct increases with time^[19].

The continuous dilating force exerted on the stricture by an indwelling Self Expandable Metallic Stent (SEMS) can achieve a greater dilatation than the plastic stents. The role of Self Expandable Metallic Stents (SEMS) is limited due to difficulty in removing these stents. However, with the availability of retrievable SEMS, their role may be increased, especially in patients with no shuntable veins/ who are unfit/ unwilling for surgery. Costamagna *et al*^[20] in an invited commentary have stated that fully covered SEMS have greater retrievability, as tissue in growth (tissue hyperplasia) can be avoided, but at a higher risk of stent migration, despite the use of flared ends or anchoring flaps. Kahaleh *et al*^[21] could successfully remove metal stents in 17 out of 18 patients after a mean duration of 4.5 months. Kasher *et al*^[22] in a multi center study, including 37 patients, concluded that removal of covered SEMS was successful in all cases. Thus the use of retrievable metal stents is likely to increase in the future.

Biodegradable stents are the latest entrants in the field of biliary stents. They have certain advantages such as large stent diameter, decreased biofilm accumulation and proliferative changes,

elimination of the need for stent removal and prospects for drug impregnation. However, filling defects due to degraded material may interfere with the cholangiographic assessment. Stent occlusion and migration occur more often than standard stents^[23,24]. At this stage it is too premature to comment on the utility of biodegradable biliary stents in managing biliary complications of PB. Biodegradable biliary stents until now have been experimented only in animal models^[25]. Cholangitis following passage of degraded stent fragments is a bothersome problem that needs further investigation, though initial reports regarding insertion and stricture patency are encouraging.

IS THERE ANY PLACE FOR LIVER TRANSPLANTATION IN PB?

Patients with portal biliopathy may progress to secondary biliary cirrhosis that may ultimately progress to end-stage liver disease. In this situation, the only alternative is liver transplantation^[3,26]. The jaundice as well as the portal hypertension is cured. Such patients are managed with a cavoportal hemi transposition to maintain a prograde portal flow through the numerous collaterals around the Inferior Vena cava^[27].

Portal biliopathy is an intriguing situation with numerous presentations and problems. Though the treatment algorithm is laid down for the majority of patients, the issues discussed above are still unresolved and need further evaluation to settle the issues.

REFERENCES

- 1 Sarin SK, Agarwal SR. Extrahepatic portal vein obstruction. *Semin Liver Dis* 2002; **22**: 43-58
- 2 Fraser J, Brown AK. A Clinical syndrome associated with a very rare anomaly of venous portal system. *Surg Gynecol Obstet* 1944; **78**: 520 - 524
- 3 Dhiman RK, Behera A, Chawla YK, Dilawari JB, Suri S. Portal hypertensive biliopathy. *Gut* 2007; **56**: 1001-1008
- 4 Khuroo MS, Yattoo GN, Zargar SA, Javid G, Dar MY, Khan BA, Boda MI. Biliary abnormalities associated with extrahepatic portal venous obstruction. *Hepatology* 1993; **17**: 807-813
- 5 Agarwal AK, Sharma D, Singh S, Agarwal S, Girish SP. Portal biliopathy: a study of 39 surgically treated patients. *HPB (Oxford)* 2011; **13**: 33-39
- 6 Shin SM, Kim S, Lee JW, Kim CW, Lee TH, Lee SH, Kim GH. Biliary abnormalities associated with portal biliopathy: evaluation on MR cholangiography. *AJR Am J Roentgenol* 2007; **188**: W341-W347
- 7 Chevallier P, Denys A, Novellas S, Schmidt S, Schnyder P, Bruneton JN. Magnetic resonance cholangiography features of biliary abnormalities due to cavernous transformation of the portal vein. *Clin Imaging* 2006; **30**: 190-194
- 8 Walser EM, Runyan BR, Heckman MG, Bridges MD, Willingham DL, Paz-Fumagalli R, Nguyen JH. Extrahepatic portal biliopathy: proposed etiology on the basis of anatomic and clinical features. *Radiology* 2011; **258**: 146-153
- 9 Palazzo L, Hochain P, Helmer C, Cuillier E, Landi B, Roseau G, Cugnenc PH, Barbier JP, Cellier C. Biliary varices on endoscopic ultrasonography: clinical presentation and outcome. *Endoscopy* 2000; **32**: 520-524
- 10 Umphress JL, Pecha RE, Urayama S. Biliary stricture caused by portal biliopathy: diagnosis by EUS with Doppler US. *Gastrointest Endosc* 2004; **60**: 1021-1024
- 11 Chaudhary A, Dhar P, Sarin SK, Sachdev A, Agarwal AK, Vij JC, Broor SL. Bile duct obstruction due to portal biliopathy in extrahepatic portal hypertension: surgical management. *Br J Surg* 1998; **85**: 326-329
- 12 Sarin SK, Agarwal SR. Extrahepatic portal vein obstruction. *Semin Liver Dis* 2002; **22**: 43-58
- 13 Vibert E, Azoulay D, Aloia T, Pascal G, Veilhan LA, Adam R, Samuel D, Castaing D. Therapeutic strategies in symptomatic portal biliopathy. *Ann Surg* 2007; **246**: 97-104
- 14 D'Souza MA, Desai D, Joshi A, Abraham P, Shah SR. Bile duct stricture due to caused by portal biliopathy: Treatment with one-stage portal-systemic shunt and biliary bypass. *Indian J Gastroenterol* 2009; **28**: 35-37
- 15 Condat B, Vilgrain V, Asselah T, O'Toole D, Rufat P, Zappa M, Moreau R, Valla D. Portal cavernoma-associated cholangiopathy: a clinical and MR cholangiography coupled with MR portography imaging study. *Hepatology* 2003; **37**: 1302-1308
- 16 Camerlo A, Fara R, Barbier L, Grégoire E, Le Treut YP. Which treatment to choose for portal biliopathy with extensive portal thrombosis? *Dig Surg* 2010; **27**: 380-383
- 17 Yang JF, Wu XJ, Li JS, Cao JM, Han JM. Effect of somatostatin versus octreotide on portal haemodynamics in patients with cirrhosis and portal hypertension. *Eur J Gastroenterol Hepatol* 2005; **17**: 53-57
- 18 Escorsell A, Bandi JC, Moitinho E, Feu F, García-Pagan JC, Bosch J, Rodés J. Time profile of the haemodynamic effects of terlipressin in portal hypertension. *J Hepatol* 1997; **26**: 621-627
- 19 Costamagna G, Pandolfi M, Mutignani M, Spada C, Perri V. Long-term results of endoscopic management of postoperative bile duct strictures with increasing numbers of stents. *Gastrointest Endosc* 2001; **54**: 162-168
- 20 Costamagna G, Baskoski I. Current treatment of benign biliary strictures - Invited Commentary. *Annals of Gastroenterology* 2012; **25**: 1-4
- 21 Kahaleh M, Tokar J, Le T, Yeaton P. Removal of self-expandable metallic Wallstents. *Gastrointest Endosc* 2004; **60**: 640-644
- 22 Kasher JA, Corasanti JG, Tarnasky PR, McHenry L, Fogel E, Cunningham J. A multicenter analysis of safety and outcome of removal of a fully covered self-expandable metal stent during ERCP. *Gastrointest Endosc* 2011; **73**: 1292-1297
- 23 Tsuji T, Tamai H, Igaki K, Kyo E, Kosuga K, Hata T, Okada M, Nakamura T, Komori H, Motohara S, Uehata H. Biodegradable Polymeric Stents. *Curr Interv Cardiol Rep* 2001; **3**: 10-17
- 24 Ginsberg G, Cope C, Shah J, Martin T, Carty A, Habecker P, Kaufmann C, Clerc C, Nuutinen JP, Törmälä P. In vivo evaluation of a new bioabsorbable self-expanding biliary stent. *Gastrointest Endosc* 2003; **58**: 777-784
- 25 Itoi T, Kasuya K, Abe Y, Isayama H. Endoscopic placement of a new short-term biodegradable pancreatic and biliary stent in an animal model: a preliminary feasibility study (with videos). *J Hepatobiliary Pancreat Sci* 2011; **18**: 463-467
- 26 Bayraktar Y. Portal ductopathy: clinical importance and nomenclature. *World J Gastroenterol* 2011; **17**: 1410-1415
- 27 Filipponi F, Urbani L, Catalano G, Iaria G, Biancofiore G, Cioni R, Campatelli A, Mosca F, Campani D, Romagnoli P. Portal biliopathy treated by liver transplantation. *Transplantation* 2004; **77**: 326-327

Peer reviewer: Manuel Giner, Professor of Surgery, Department of Surgical, School of Medicine, Complutense University of Madrid, 28040-Madrid, Spain.