

Feasibility of Anticoagulation in Patients of Budd-chiari Syndrome with Gastroesophageal Varices and Portal Hypertension

Hany Dabbous, Mohammad Sakr, Sara Abdelhakam, Said Youssef, Mohamed Gharib, Mohamed Shaker, Ahmed Eldorri

Hany Dabbous, Mohammad Sakr, Sara Abdelhakam, Tropical Medicine Department, College of Medicine, Ain Shams University, Cairo, Egypt

Said Youssef, Hematology Department, College of Medicine, Ain Shams University, Cairo, Egypt

Mohamed Gharib, Mohamed Shaker, Ahmed Eldorri, Radio-diagnosis and Interventional Radiology Department, College of Medicine, Ain Shams University, Cairo, Egypt

Correspondence to: Hany Dabbous, Tropical Medicine Department, Ain Shams University, Cairo, Egypt. drhdabbous@yahoo.com

Telephone: +2-23809997 Fax: +2-23809247

Received: January 16, 2013 Revised: March 15, 2013

Accepted: March 18, 2013

Published online: May 21, 2013

bleeding should not be a contraindication for anticoagulation in BCS.

© 2013 ACT. All rights reserved.

Key words: Budd-Chiari syndrome; Anticoagulants; Oesophageal varices; Gastric varices; Portal hypertensive gastropathy

Dabbous H, Sakr M, Abdelhakam S, Youssef S, Gharib M, Shaker M, Eldorri A. Feasibility of Anticoagulation in Patients of Budd-Chiari Syndrome with Gastroesophageal Varices and Portal Hypertension. *Journal of Gastroenterology and Hepatology Research* 2013; 2(5): 581-584 Available from: URL: <http://www.ghrnet.org/index.php/joghr/article/view/384>

ABSTRACT

AIM: Budd-Chiari syndrome (BCS) is characterized by hepatic venous outflow obstruction. Patients with BCS are found to have oesophageal varices (OV), gastric varices (GV) as well as portal hypertensive gastropathy (PHG). Anticoagulation is recommended in BCS though not evaluated in randomized trials. The aim of work is to determine feasibility of anticoagulation in patients with BCS with gastro-esophageal varices.

METHODS: 150 patients with BCS were included. All had upper endoscopy. Band ligation was planned for (OV) with red signs or recent bleeding and cyanoacrylate injection for bleeding (GV) or signs of impending hemorrhage before anticoagulation.

RESULTS: 30 patients (20%) were presented by GI bleeding, 12/30(40%) had large sized OV with (GV) in 3 of them, all had band ligation with cyanoacrylate injection of the (GV) before anticoagulation. The remaining 18 had PHG with medium sized non risky varices in 12/30 (40%) and small OV in 6/30 (20%). Only 2/30 (6.6%) had GI bleeding after anticoagulation with overall survival of 10.4 months. Among 120 patients who were not presented by GI bleeding, 18/120 (15%) had large OV, 57/120 (47.5%) had PHG with small or medium sized OV, one patient had isolated large (GV), and 44 patients had neither OV nor PHG. All were anticoagulated after band ligation of risky varices. 23 (19%) out of 120 died, only 3 (2.5%) due to GI bleeding with overall survival of 12.3 months.

CONCLUSIONS: Anticoagulation in BCS is feasible after band ligation of large or medium sized OV with red signs. History of GI

INTRODUCTION

Budd-Chiari syndrome (BCS) is characterized by obstruction of the hepatic venous outflow tract at the level of the large hepatic veins or in the suprahepatic portion of the inferior vena cava (IVC), in the absence of right heart failure or constrictive pericarditis^[1]. Patients frequently have an underlying thrombotic disorder^[2,3]. The therapeutic options include medical treatment (anticoagulants, diuretics, and treatment of etiological factors if possible) and invasive management [thrombolysis, percutaneous transluminal angioplasty, transjugular intrahepatic portosystemic shunting (TIPS), surgical portosystemic shunting, and orthotopic liver transplantation (OLT)]^[4]. Abdominal pain, ascites, hepatosplenomegaly, and portal hypertension are important features. Most patients with BCS are found to have oesophageal varices (OV) with or without gastric varices (GVs) as well as portal hypertensive gastropathy (PHG). The risk of thrombosis progression in BCS necessitates early initiation of anticoagulation therapy for all patients, although anticoagulation has not yet been evaluated in randomized clinical trials^[5]. Recanalization of thrombosed hepatic veins, the portal vein or the IVC may also occur after anticoagulation. Therefore, it is prudent to evaluate the safety and feasibility of anticoagulation in BCS patients with OV, GV, PHG or all these features.

METHODS

The study was approved by the institutional review board (IRB) and included a cohort of 150 patients who had BCS and presented to the Tropical Medicine Department of Ain Shams University

between November 2005 and November 2009 (Table 1). The study was performed in accordance with the ethical guidelines of the 1975 Declaration of Helsinki. All patients were followed up prospectively for a minimum period of 14 months. The diagnosis of BCS was confirmed radiologically by coloured Doppler ultrasonography, triphasic spiral abdominal computed tomography (CT) or magnetic resonance venography as required. All the patients underwent upper endoscopy at the time of presentation. Band ligation was planned for medium and large sized oesophageal varices (OV) with red signs or evidence of recent bleeding. Band ligation was performed circumferentially starting at level of Z-line. In cases where there were bleeding GVs or if signs of impending hemorrhage were observed during endoscopy, cyanoacrylate injection was performed before anticoagulation therapy. A Beta-blocker (propranolol) was prescribed for primary prophylaxis as much as tolerated for patients (70 patients) with non risky varices and PHG till portal decompression by angioplasty or TIPS was performed. PHG was classified as mild if the gastric mucosa showed mosaic pattern only and severe if there were pinpoint petechiae as well. All the patients began anticoagulation therapy involving unfractionated heparin or low-molecular-weight heparin followed by oral anticoagulation therapy with warfarin (initially 3 mg, with increasing dosage until a target INR of 2-3 was obtained). All patients were informed about the manifestations of gastrointestinal bleeding and instructed to discontinue anticoagulation therapy under such circumstances or if any bleeding was noted. Patients were classified according to grade of esophageal varices as well as according to history of gastrointestinal bleeding on presentation. Kaplan Meier survival was used to determine survival of groups of patients presenting with or without gastrointestinal bleeding and patients with risky or non risky varices. TIPS was performed for 39 (26%) patients, angioplasty of hepatic veins for 23 (15%), angioplasty of IVC for 4 (3%), and medical treatment alone for 84 (56%).

RESULTS

Thirty (20%) of 150 patients presented with a recent history of GI bleeding; 12 (40%) of these 30 patients had large-sized OV with GV in 3 patients, and underwent band ligation with cyanoacrylate injection of the GV before anticoagulation. Of the remaining patients (from the 30 patients), 12 (40%) had PHG with medium-sized non-risky varices and 6 (20%) had small OV; these patients received secondary prophylaxis in the form of beta-blockers until portal decompression by TIPS. Only 2 (6.6%) of the 30 patients had GI bleeding after anticoagulation from medium-sized OV which was easily controlled by band ligation until TIPS was performed. Patients with large-sized OV or GV had an overall survival of 10.4 months, similar to patients with medium-sized and small-sized varices (Figure 1).

Of the 120 patients who did not present with GI bleeding, 18 (15%) had large OV and PHG, 57 (47.5%) had PHG with small or medium sized OV, one patient had isolated large gastric varix, and 44 (35.8%) patients had neither OV nor PHG. All the patients received anticoagulation therapy after band ligation of large and medium sized risky varices. Twenty three (19%) of the 120 patients died, only 3 (2.5%) succumbed to GI bleeding with an overall survival of 12.3 months (Figure 2). Medical therapy alone (without surgical or radiological intervention) in patients with BCS provided a 5-year survival rate of 40% (Figure 3). One patient who was not a candidate for any intervention because of portal vein thrombosis and IVC thrombosis underwent recanalization of the IVC, and the portal and right hepatic veins after 2 years of anticoagulation therapy.

Table 1 Patients demographics.

Age (years)	Median (range)	27.8 (5-55)
Sex	Male	68 (45%)
	Female	82 (55%)
Race	Egyptian	145 (97%)
	Sudanese	2 (1.3%)
	Yemen	2 (1.3%)
	Palestine	1 (0.4%)
Etiology (n=refers to number of patients who had the test)	Factor V Leiden mutation (56)	29 (52%)
	Myeloproliferative (62)	18 (29%)
	Protein C deficiency (80)	23 (28%)
	Protein S deficiency (80)	11 (13.7%)
	Antithrombin III deficiency (80)	3 (3.7%)
	Antiphospholipid antibody Syndrome (70)	14 (20%)
	Not done	34
Child Pugh class	unknown	19
	A	66 (44%)
	B	54 (36%)
Smoking	C	30 (20%)
	No	125 (83%)
History of Venous thrombosis	Yes	25 (17%)
	No	32 (22%)
MELD	Yes	118 (78%)
	Bleeding group	16
Onset	Non bleeding group	14
	Acute	8 (5%)
Portal vein thrombosis	Subacute or chronic	142 (95%)
	Yes	15 (10%)
	No	135 (90%)

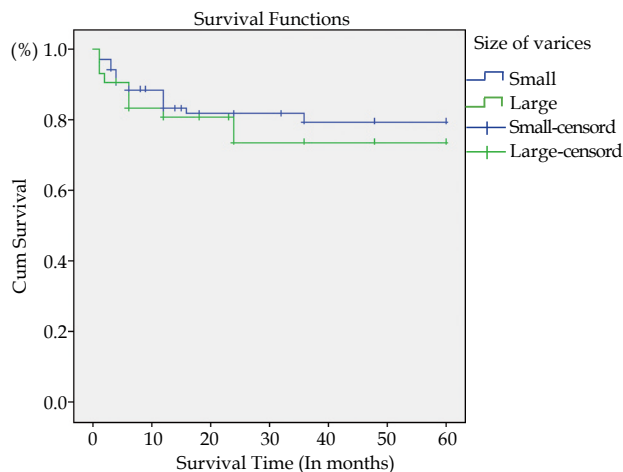


Figure 1 Kaplan Meier survival in months of patients with OV Grade I-II and Grade III-IV (no significant difference).

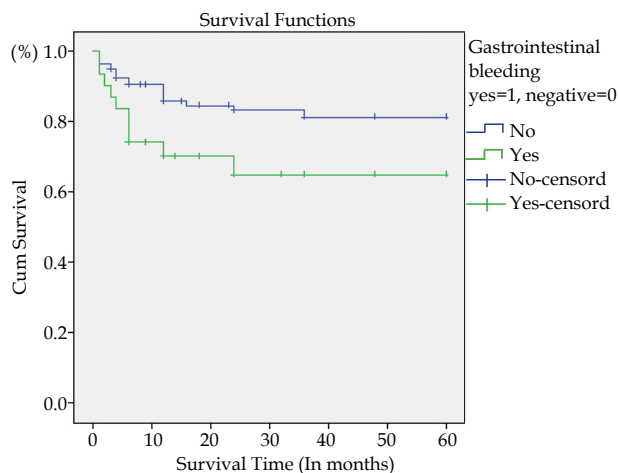


Figure 2 Kaplan Meier survival in months of patients with and without history of gastrointestinal bleeding (no significant difference).

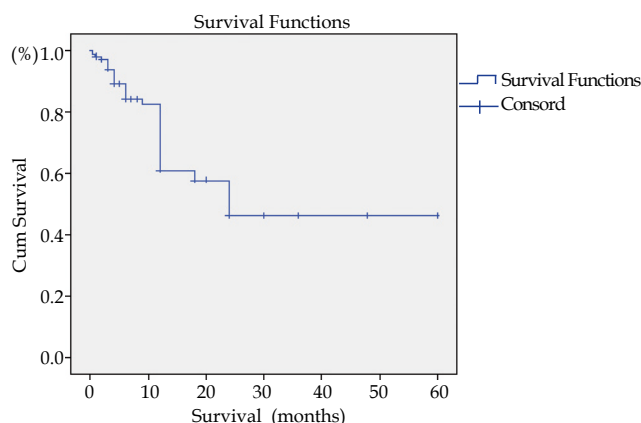


Figure 3 Kaplan Meier survival in months of patients with medical therapy alone.

DISCUSSION

BCS is considered as the hepatic expression of an underlying thrombophilia. Expert panels have recommended routine anticoagulation therapy and treatment of the underlying conditions as the first step in a therapeutic strategy for BCS^[1,5]. Because BCS is a relatively uncommon disorder, it has not been possible to perform prospective randomized therapeutic trials to determine the precise effects of routine anticoagulation therapy. Specifically, the surveys available have not clarified the risk of bleeding. This is of particular relevance to BCS patients who are also at risk of bleeding from portal hypertension^[6].

In the current study, medical treatment alone was found to be sufficient with a 5 year survival rate up to 40%. In other studies, it was found to have a sufficient effect with respect to controlling liver disease in 10% of patients, primarily those with mild disease^[7]. However, this finding remains unexplained. It is safe to recommend that unfractionated heparin, be replaced by low-molecular-weight-heparin, at the initiation of anticoagulation therapy, followed by oral anticoagulation in the form of vitamin K antagonists. There is no evidence indicating that the efficacy of vitamin K antagonists differs from that of heparin. At present, therefore, the choice of anticoagulation therapy should be dictated by pharmacokinetic considerations and by context (i.e. a need for rapid and short-acting anticoagulation therapy for long-term treatment)^[8]. This is one of the clinical trials that emphasized the prevention of gastrointestinal bleeding in patients who had BCS and were receiving anticoagulant therapy. Prophylaxis for bleeding from OV has not been evaluated in clinical trials in the context of BCS^[5].

On following the protocol for anticoagulation with appropriate prophylaxis against GI bleeding from OVs, GVs, or PHG by using esophageal band ligation or beta-blockers or injection in risky GVs, only 3 patients developed GI bleeding requiring hospitalization and intervention after they underwent anticoagulation therapy. Careful preparation of patients before anticoagulation therapy with appropriate prophylaxis is the cornerstone of feasible and safe anticoagulation irrespective of the size of varices or presence of PHG. This may explain why others have reported that OVs constitute the primary source as well as the main independent predictor of bleeding unrelated to invasive therapy for BCS. The authors reported 15 episodes of major GI bleeding in 11 patients of whom only two were undergoing therapy involving a combined prophylactic approach when bleeding occurred^[9]. A strategy similar to that in cirrhotic patients may prove useful^[10] including routine screening for OVs followed by a combined pharmacologic and endoscopic approach.

According to recent meta-analyses for patients with cirrhosis without anticoagulation, the combined approach would carry the advantage of a better prophylaxis for recurrent bleeding than with beta-adrenergic blockade alone or with endoscopic ligation alone^[11].

The possibility of increase in the risk of endoscopic ligation-induced bleeding should be considered in patients already on anticoagulation therapy. Anticoagulation therapy is therefore not initiated until after post-band ligation follow-up endoscopy. Therefore, a similar survival was observed among patients with small, medium-sized and large-sized OVs as well as among those who presented with and without GI bleeding.

In a previous study, patients with a poor outcome following bleeding episodes had the most severe disease at the time of diagnosis^[9]. In another study of an independent group of 237 patients, anticoagulation therapy was associated with improved survival in patients with a good baseline prognosis but not in those with an intermediate or poor prognosis^[12]. However, the data from the present study do not allow for the identification of a subgroup of patients that should not be given anticoagulation therapy because of a prohibitive risk of fatal bleeding.

CONCLUSION

Anticoagulation therapy is feasible for patients with BCS irrespective of OV size and PHG severity. Patients with large or medium-sized OVs with red signs should undergo band ligation before anticoagulation therapy. A history of GI bleeding should not be considered a contraindication for anticoagulation for BCS patients. A multicenter study is recommended to confirm safety of anticoagulation therapy in patients who have OVs and PHG with vascular thrombosis.

REFERENCES

- Janssen HL, Garcia-Pagan JC, Elias E, Mentha G, Hadengue A, Valla DC. Budd-Chiari syndrome: a review by an expert panel. *J Hepatol* 2003; **38**: 364-371
- Denninger MH, Chaït Y, Casadevall N, Hillaire S, Guillin MC, Bezeaud A, Erlinger S, Briere J, Valla D. Cause of portal or hepatic venous thrombosis in adults: the role of multiple concurrent factors. *Hepatology* 2000; **31**: 587-591
- Janssen HL, Meinardi JR, Vleggaar FP, van Uum SH, Haagsma EB, van Der Meer FJ, van Hattum J, Chamuleau RA, Adang RP, Vandenbroucke JP, van Hoek B, Rosendaal FR. Factor V Leiden mutation, prothrombin gene mutation, and deficiencies in coagulation inhibitors associated with Budd-Chiari syndrome and portal vein thrombosis: results of a case-control study. *Blood* 2000; **96**: 2364-2368
- Valla DC. The diagnosis and management of the Budd-Chiari syndrome: consensus and controversies. *Hepatology* 2003; **38**: 793-803
- de Franchis R. Evolving consensus in portal hypertension. Report of the Baveno IV consensus workshop on methodology of diagnosis and therapy in portal hypertension. *J Hepatol* 2005; **43**: 167-176
- Linkins LA, Choi PT, Douketis JD. Clinical impact of bleeding in patients taking oral anticoagulant therapy for venous thromboembolism: a meta-analysis. *Ann Intern Med* 2003; **139**: 893-900
- Plessier A, Sibert A, Consigny Y, Hakime A, Zappa M, Denninger MH, Condat B, Farges O, Chagneau C, de Ledinghen V, Francoz C, Sauvanet A, Vilgrain V, Belghiti J, Durand F, Valla D. Aiming at minimal invasiveness as a therapeutic strategy for Budd-Chiari syndrome. *Hepatology* 2006; **44**: 1308-1316

- 8 Valla DC. Primary Budd-Chiari syndrome. *J Hepatol* 2009; **50**: 195-203
- 9 Rautou PE, Douarin L, Denninger MH, Escolano S, Lebrech D, Moreau R, Vidaud M, Itzykson R, Moucari R, Bezeaud A, Valla D, Plessier A. Bleeding in patients with Budd-Chiari syndrome. *J Hepatol* 2011; **54**: 56-63
- 10 Garcia-Tsao G, Sanyal AJ, Grace ND, Carey W. Prevention and management of gastroesophageal varices and variceal hemorrhage in cirrhosis. *Hepatology* 2007; **46**: 922-938
- 11 Gonzalez R, Zamora J, Gomez-Camarero J, Molinero LM, Baniñares R, Albillos A. Meta-analysis: Combination endoscopic and drug therapy to prevent variceal rebleeding in cirrhosis. *Ann Intern Med* 2008; **149**: 109-122
- 12 Darwish Murad S, Valla DC, de Groen PC, Zeitoun G, Hopmans JA, Haagsma EB, van Hoek B, Hansen BE, Rosendaal FR, Janssen HL. Determinants of survival and the effect of portosystemic shunting in patients with Budd-Chiari syndrome. *Hepatology* 2004; **39**: 500-508

Peer reviewers: Sebastiano Bonventre, Department of Surgical and Oncological Sciences, University of Palermo, Via Resuttana Colli, 367, 90146 Palermo, Italy; Mohamed Ismail Yasawy, Department Of Medicine, Dammam University, P.O.Box 40143, Al-Khobar 31952, Saudi Arabia.