

Fecal Calprotectin: A Non-invasive Marker for Assessing the Intestinal Inflammation in Patients with Colonic Diverticular Disease

Ventsislav N Nakov, Plamen I Penchev, Radislav V Nakov, Ivan N Terziev, Milko T Shishenkov, Todor G Kundurzhiev

Ventsislav N Nakov, Plamen I Penchev, Radislav V Nakov, Clinical Center of Gastroenterology, University Hospital Queen Joanna, Medical University, Sofia 1527, Bulgaria

Ivan N Terziev, Department of Pathology, University Hospital Queen Joanna, Medical University, Sofia 1527, Bulgaria

Milko T Shishenkov, Department of Clinical Laboratory and Immunology, Military Medical Academy, Sofia 1431, Bulgaria

Todor G Kundurzhiev, Department of Social Medicine and Health Management, Section of Biostatistics, Medical University, Sofia 1527, Bulgaria

Correspondence to: Ventsislav N Nakov, MD, PhD, Clinical Center of Gastroenterology, University Hospital Queen Joanna, Medical University, 8 Byalo more Str, Sofia 1527,

Bulgaria. dr.nakov1962@abv.bg

Telephone: +359898677172

Fax: +35929432103

Received: February 9, 2013

Revised: March 5, 2013

Accepted: March 8, 2013

Published online: May 21, 2013

controls ($p < 0.0001$), IBS patients ($p < 0.0001$), subgroups with asymptomatic DD ($p < 0.01$) and symptomatic DD ($p < 0.01$).

CONCLUSIONS: FCP is a non-invasive, easy to investigate and reliable biomarker for assessing the intestinal inflammation in patients with DD of the colon and for distinguishing these patients from patients with functional gastrointestinal disorders.

© 2013 ACT. All rights reserved.

Key words: Diverticular disease; Fecal calprotectin; Irritable bowel syndrome; Intestinal inflammation

Nakov VN, Penchev PI, Nakov RV, Terziev IN, Shishenkov MT, Kundurzhiev TG. Fecal Calprotectin: A Non-invasive Marker for Assessing the Intestinal Inflammation in Patients with Colonic Diverticular Disease. *Journal of Gastroenterology and Hepatology Research* 2013; 2(5): 585-589 Available from: URL: <http://www.ghrnet.org/index.php/joghr/article/view/385>

ABSTRACT

AIM: To assess the fecal calprotectin (FCP) values in different degrees of colonic diverticular disease (DD) and to assess histologically the presence (or absence) of inflammation in the colonic mucosa in these patients.

METHODS: This study enrolled 45 patients with different types of DD who had all undergone total colonoscopy. The control group consisted of 15 healthy controls and 17 patients with irritable bowel syndrome (IBS). FCP was analyzed in stool samples by means of "Calpo Test" based on ELISA.

RESULTS: The mean value of FCP in the healthy controls was 37.9 mg/kg. The mean value in IBS patients was 33.8 mg/kg and did not differ significantly ($p = 0.4630$) from that of the healthy controls. In the patients with asymptomatic DD the mean value of FCP was 48.7 mg/kg and there was no significant difference from those in the healthy controls ($p = 0.2326$) and the IBS patients ($p = 0.0922$). The mean value of FCP in symptomatic DD patients was 115.3 mg/kg, which is significantly higher than those in all other subgroups – healthy controls ($p < 0.0001$), IBS patients ($p < 0.0001$), and asymptomatic DD ($p < 0.001$). In patients with diverticulitis FCP values were significantly higher (mean value of 433.2 mg/kg), the differences were statistically significant as compared to healthy

INTRODUCTION

Colonic diverticular disease is a routine finding in older patients. During the last years its prevalence has risen in the western countries^[1-3], in particular, it is within 12 to 49%^[4,5]. Asymptomatic diverticulosis is most often discovered incidentally in patients with other indications (e.g. colonoscopy in screening for colo-rectal carcinoma) or in investigations conducted in patients in order to find the reason for an anaemic syndrome^[6]. In other cases, patients have symptoms varying from nonspecific abdominal symptoms, clinically indistinguishable from irritable bowel syndrome – IBS (symptomatic uncomplicated diverticular disease) to severe symptoms of diverticulitis or other complications of diverticulosis (perforation, stricture, bleeding)^[7].

For many years diverticular disease (DD) was considered as a "bacteria-associated disease" – bacterial overgrowth associated with obstruction of the diverticular neck by feces. They abrade diverticular mucosa, causing low-grade inflammation and blockage of drainage. The obstruction can lead to an increase of normal bacterial flora, restriction of venous outflow with local ischaemia and alteration of immune mechanisms^[8]. However, some studies show that mesalazine and probiotics are effective in the treatment of DD^[9-11]. It seems that these results are related to a surprising

similarity between DD and inflammatory bowel disease (IBD). Moreover, a defective CD-2 pathway that induces apoptosis in the lymphocytes of lamina propria in patients with diverticulitis is established, leading to amplification of the local immune response in these patients, similar to that observed in patients with Crohn's disease (CD) and ulcerative colitis (UC)^[7,8]. In recent studies, Tursi *et al.*^[7,12] demonstrate histologically an inflammatory infiltrate in DD patients, associated with different degrees of the disease, higher than in the healthy controls.

Nowadays, a "gold standard" for assessing the location, extension and severity of the intestinal inflammation is the endoscopy with biopsy^[13]. However, endoscopic procedures are invasive, with a substantial risk of complications^[14]. Unfortunately, the tests widely used in the clinical practice – erythrocyte sedimentation rate (ESR), leucocytes and platelets count in the peripheral blood, C-reactive protein (CRP), etc. – have low sensitivity and do not reflect adequately the intestinal inflammation^[15,16]. In order to optimize the assessment of gut inflammation, some other tests and methods are used. The increase of intestinal permeability could be a surrogate marker of inflammation but this method has not been widely used in clinical practice^[17]. One of the most precise ways to localize inflammation in the gut is Indium111-leukocyte scanning and the count of Indium111-bounded leukocytes in the feces^[18]. This method is unsuitable for outpatient practice because of the exposure to radiation, the four-day collection of the stool samples, and its high price. In the search for new, more accessible, informative and inexpensive tests for diagnosis and assessment of gut inflammation in the last years of the 20th century, more attention was paid to the bio-active markers^[19]. These markers include calprotectin, lactoferrin, polymorphonuclear elastase, myeloperoxidase, etc.^[14,20-22]. Among these, the most widely applied in clinical practice is fecal calprotectin (FCP).

Calprotectin is a calcium- and zinc-binding protein comprising up to 60% of the neutrophil cytosolic proteins. In small amounts, it is found in monocytes, some macrophage subtypes, tissue eosinophils of the ileum and shed epithelial cells, except for those in normal skin. It is released from the neutrophils during cell activation or cell death. Competing with various enzymes for the limited amount of zinc, calprotectin can suppress many zinc-dependent enzymes and thereby kill some microorganisms and other cells. Calprotectin is also a strong chemotactic factor for neutrophils. Calprotectin has been studied clinically in plasma and various body fluids, where it is presented at concentrations proportional to the level of inflammation^[19,23-25].

The assessment of FCP finds wide application in the examination of intestinal inflammation, which is normally examined by invasive methods. In case of inflammation of the bowel wall neutrophils migrate toward and through it and thereby calprotectin passes into the feces. It resists metabolic degradation by intestinal bacteria and is stable in stool for up to 7 days^[24].

We aimed to assess the role of fecal calprotectin as a non-invasive marker of intestinal inflammation in patients with colonic DD.

METHODS

Patients

In this prospective study 45 consecutive patients affected by DD with and without inflammatory signs, who had undergone total colonoscopy, were enrolled. The patients were stratified in three subgroups, as follows: 16 patients affected by asymptomatic diverticulosis who had undergone total colonoscopy for colon cancer screening; 15 patients affected by symptomatic uncomplicated DD (without signs of inflammation) who had undergone total colonoscopy for long-lasting or recurrent abdominal pain; 14 patients

affected by acute uncomplicated diverticulitis (symptomatic DD with signs of diverticular inflammation but without complication). These patients had abdominal pain with signs of inflammation (increased ESR, serum CRP and/or white cell count). Complications were excluded by computed tomography scan^[26-28]. They had undergone partial sigmoidoscopy, in which inflamed diverticula were visualized: then the study was terminated because of the possible risk of complications. When treatment was carried out and control of the condition was achieved, all the patients underwent total colonoscopy for exclusion of any additional pathological process.

Patients affected by neoplastic diseases of the colon or IBD were excluded. Moreover, patients taking non-steroid anti-inflammatory drugs (NSAIDs) for less than a month before the study were also excluded.

The control group consisted of two subgroups: 17 subjects affected by IBS and matched by sex and age. All of them had undergone total colonoscopy for long-lasting abdominal pain. They covered the Rome III criteria^[29] with absence of any "alarm" features. In addition, all these patients underwent routine hematological and biochemical tests as well as stool examination for microorganisms and parasites. Furthermore, thyroid function tests, anti-transglutaminase IgA examination (for suspected celiac disease) and a lactulose hydrogen breath test were performed. In these patients, colonoscopy did not show any abnormalities, including diverticula – a normal endoscopic image of the colon was acquired.

15 healthy controls matched by sex and age who underwent total colonoscopy for colon cancer screening. Each of them had neither history of any gastrointestinal disorder nor complaints at the time of the examination.

Also, in these subgroups, patients taking NSAIDs for less than a month before the study were excluded.

Endoscopic procedures

In all patients total colonoscopy was performed the day after they had undergone standard bowel preparation, consisting of an oral polyethylene glycol solution (Fortrans, Beaufour Ipsen Industrie, France) taken in the afternoon before the examination. In control group subjects, three bioptic samples of colonic mucosa were collected. In DD patients, three biopsies were taken from the mucosa between diverticula.

Histological assessment

The bioptic samples were fixed in 10% neutral buffered formalin, embedded in a paraffin block and processed for sectioning. All tissue sections were sliced to obtain sections of 5 µm thickness then stained with haematoxylin and eosin for light microscopic examination. The tissue sections were visualized for the following: inflammatory lesions, mononuclear cell infiltration, neutrophil infiltration, eosinophil infiltration, plasmacyte infiltration, fibrin exudation, lymphangiectasis, tissue destruction and tissue repair. The degree of inflammation was assessed according to the count and type of inflammatory cells on field, at ×40 magnification. An inflammatory process was accepted if there were more than 5 lymphocytes with predominantly basal localization. Neutrophilic infiltrate and the presence of monocytes/histiocytes were also evaluated on routine slides.

Fecal calprotectin assessment

In all patients, calprotectin was analyzed in stool samples by means of "Calpo Test" based on enzyme-linked immunosorbent assay (ELISA), made by Nova Tec Immunodiagnostica of Germany.

All tested persons provided 1-5 grams of stool samples prior to preparation for colonoscopy, respectively, before starting therapy when it was carried out. The samples were immediately put into a freezer at (-) 20°C. Before analyzing, the samples were defrosted at room temperature followed by extraction of 100 mg feces from each sample in a buffer solution. A defined volume of supernatant was diluted 50 times and introduced into veritable determination of calprotectin. The reading was automatic against a calibration curve. The final result was presented in milligrams per kilogram feces (mg/kg).

Statistical methods

For data analysis the following statistical methods were used: descriptive statistics for tabular and graphical presentation of results; Kolmogorov-Smirnov test and Shapiro-Wilk test for normality of the distributions of the studied variables; nonparametric tests of Mann-Whitney to verify the hypotheses of a difference in two independent samples; analysis of sensitivity and specificity of diagnostic methods; and ROC analysis. The obtained results were assessed as statistically reliable in threshold level of significance $p < 0.05$.

Ethics approval

The study was approved by the Ethics Committee of University Hospital Queen Joanna in Sofia, Bulgaria. Written informed consent was obtained from all patients and control subjects.

RESULTS

The patients with DD, the healthy controls and the IBS patients did not differ for age distribution (Table 1).

Results of FCP examination

The mean value of FCP in the healthy controls was 37.9 mg/kg (8.3-68.0) with standard deviation (SD) of 16.4 and median of 34.5 (Table 2). The value quoted as normal for fecal calprotectin was <50 mg/kg of stool (the baseline value of the manufacturer). In the present study, we accepted an increased value above $1.96 \times SD + \text{mean value}$ (37.9), e.g. values above 70 mg/kg. All healthy controls were below this value.

The mean value in IBS patients was 33.8 mg/kg which did not differ significantly ($p = 0.4630$) from that of the healthy controls (Table 2, figure 1).

In the patients with asymptomatic DD the mean value of FCP was 48.7 mg/kg (Table 2) and there was no significant difference from the mean values in the healthy controls ($p = 0.2326$) and the IBS patients ($p = 0.0922$) (Figure 1).

The mean value of FCP in symptomatic DD patients was 115.3 mg/kg (Table 2) which was significantly higher than the mean values

Table 1 Demographic characteristics of the studied population.

	HC	IBS	Asymptomatic DD	Symptomatic DD	Diverticulitis
M/F	8/7	6/11	9/7	8/7	7/7
Median age	61.2+/-11	57.6+/-12	64.1+/-13	62.5+/-12	60.8+/-11
p value	//	n.s.	n.s.	n.s.	n.s.

HC: healthy controls; IBS: irritable bowel syndrome; DD: diverticular disease.

Table 2 FCP values in healthy controls - HC, IBS patients and DD patients.

Group	N	Mean	SD	Median	Min	Max
HC	15	37.9	16.4	34.5	8.3	68.0
IBS	17	33.8	17.8	31.1	5.0	62.4
Asympt. Diverticulosis	16	48.7	22.4	42.0	12.7	71.7
Sympt. DD	15	115.3	39.5	105.9	69.8	212.4
Acute Diverticulitis	14	433.2	153.1	399.0	311.4	691.0

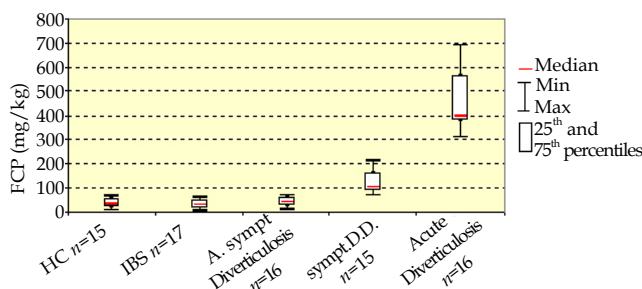


Figure 1 FCP in healthy controls, IBS patients and different degrees of diverticular disease (DD).

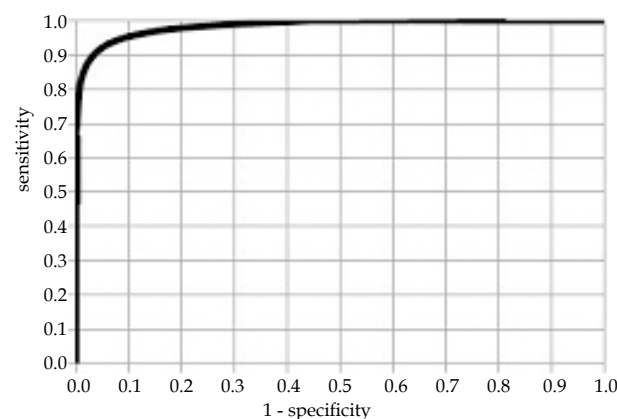


Figure 2 ROC analysis of the results for sensitivity and specificity of FCP, distinguishing the cases of diverticular disease without inflammation from those of diverticular disease with mild inflammation.

in all other subgroups – healthy controls ($p < 0.0001$), IBS patients ($p < 0.0001$) and asymptomatic DD ($p < 0.001$) (Figure 1).

In patients with diverticulitis FCP values were significantly higher (mean value of 433.2 mg/kg) (Table 2). The differences were statistically significant as compared to healthy controls ($p < 0.0001$) and IBS patients ($p < 0.0001$) as well as for the subgroups with asymptomatic DD ($p < 0.01$) and symptomatic DD ($p < 0.01$) (Figure 1).

Histological findings

Healthy controls and IBS patients had colonic mucosa with normal histology (normal colonic mucosa). In patients with asymptomatic DD, the histological examination of the bioptic samples showed colonic mucosa with normal histological structure and lack of lymphocyte infiltration. In symptomatic DD subgroup lymphocyte infiltration was detected (more than 5 lymphocytes on field) as well as single monocytes/histiocytes. Scattered neutrophils were found in 2 patients from this subgroup. All patients with acute diverticulitis had marked inflammatory infiltration in the colonic mucosa – more than 5 lymphocytes on field, presence of monocytes/histiocytes and scattered neutrophils.

At value of 71.15 mg/kg FCP showed sensitivity of 93%, specificity of 94%, area under the ROC curve - 0.983, negative predicting value - 93.75% and positive predictive value of 93.33% for differentiating the cases of DD without inflammation from those of DD with mild inflammation (Figure 2).

Regarding the differentiation of cases of DD with mild inflammation from those of acute diverticulitis, ROC analysis of FCP values showed that at value of 262 mg/kg sensitivity and specificity were both optimal-100%. Because of the fact that optimal values for sensitivity and specificity were reached at this cut-off level, we did not represent this result graphically.

DISCUSSION

Recently, one of the ways to assess the inflammatory process was widely discussed – the analysis of neutrophil infiltration in the intestinal mucosa and neutrophils' transmigration into the lumen^[30]. Up until now in world literature, the assessment of FCP has been mainly launched as a method for determining the disease activity in IBD patients^[14,30,31]. Many authors claim that FCP levels are more closely related to histological evaluation than to endoscopic image, suggesting that this biomarker is more sensitive than endoscopy in the evaluation of IBD activity^[14,20]. Several studies have demonstrated that the high degrees of inflammation are related to elevated FCP values, indicating significant correlation between FCP and the severity of inflammation^[14]. It is considered that FCP reflects better the disease activity in UC than in CD^[30,32].

There are only a few reports in the medical literature about the examination of FCP in colonic DD. Although some studies have found a mild increase of FCP values in diverticulosis^[33], compared to healthy controls, there is no sufficient information about the specific correlation between FCP values and the clinical degree of colonic DD^[34]. Recently, several studies showing the relationship between FCP values, clinical severity of DD and histological findings have been published^[7,35].

In our study, patients with asymptomatic diverticulosis have FCP values similar to those in healthy controls. Histology of colonic mucosa in these patients is normal and there is no inflammatory infiltrate in bioptic samples taken from areas adjacent to the diverticular orifice. These results show that there is no intestinal inflammation in asymptomatic DD and because of that these patients have normal values of FCP and absence of abdominal symptoms. Similar results are reported by Pezzilli *et al.*^[33]. In symptomatic DD subgroup, FCP values were significantly higher than those of the control group and those of the asymptomatic DD subgroup. In line with these results is the histological finding – all patients in this subgroup have inflammatory infiltrate in the bioptic samples taken from colonic mucosa adjacent to the diverticula – over 5 lymphocytes on field, presence of monocytes/histiocytes, and scattered neutrophils in some patients. These data show convincingly that there is a low-grade intestinal inflammation in some of the DD patients (in absence of any endoscopic findings), which correlates to their complaints. In patients with diverticulitis FCP values are significantly higher and the differences are statistically significant as compared to the control group, asymptomatic DD subgroup and symptomatic DD subgroup. It is well known that diverticulitis is a marked inflammation in the diverticular bags and the lining around them, which correlates to relevant endoscopic findings and is a prerequisite for the occurrence of many complications^[6]. Because of the fact that neutrophils are the main carriers of FCP, their presence in the inflammatory infiltrate in patients with acute diverticulitis precisely determines the high values of FCP in them. In some of our patients these values are comparable with the values of FCP in patients with IBD^[14,30,31,36,37].

Our study is one of the few in the world that is focused on this problem. We have not found in the available literature a study, similar to this one, in which FCP has been investigated by the ELISA method (in the published studies up to date on this topic FCP has been investigated by a semi-quantitative rapid test). Our results confirm the relationship between intestinal inflammation and the presence of symptoms in patients with DD. The histological examination demonstrates that the inflammatory infiltrate is associated with the clinical severity of the disease^[7,35]. However, this method is invasive and difficult to perform in clinical practice for distinguishing different levels of DD, particularly diverticulitis, where relative or

even absolute contraindications for lower endoscopy are present. FCP correlates with these parameters and is easy to implement. The practical benefit of this study is the possibility of FCP values to direct us to the presence of inflammation and even to determine its grade, if we previously know that the patient has colonic diverticulosis and occurrence of abdominal symptoms, which would be helpful also in determining the therapeutic strategy. In our opinion, the possibility that elevated FCP levels can help in distinguishing the diagnosis of symptomatic DD from that of IBS is of great importance, because they both can have similar symptoms. The results of our study confirm this possibility. The opportunity to use FCP assessment as a useful tool in determining the therapeutic approach and monitoring of the therapy in patients with DD and intestinal inflammation seems also to be quite promising^[7].

In conclusion, FCP is a non-invasive, easy to investigate and reliable biomarker for assessing the intestinal inflammation in patients with diverticular disease of the colon and also for distinguishing these patients from patients with functional gastrointestinal disorders.

REFERENCES

- 1 Kang JY, Hoare J, Tinto A, Subramanian S, Ellis C, Majeed A, Melville D, Maxwell JD. Diverticular disease of the colon-on the rise: a study of hospital admissions in England between 1989/1990 and 1999/2000. *Aliment Pharmacol Ther* 2003; **17**: 1189
- 2 Makela J, Kiviniemi H, Laitinen S. Prevalence of perforated sigmoid diverticulitis is increasing. *Dis Colon Rectum* 2002; **45**: 955
- 3 Schwesinger WH, Page CP, Gaskill HV III, Steward RM, Chopra S, Strodel WE, Sirinek KR. Operative management of diverticular emergencies: Strategies and outcomes. *Arch Surg* 2000; **135**: 558
- 4 Delvaux M. Diverticular disease of the colon in Europe: Epidemiology, impact on citizen health and prevention. *Aliment Pharmacol Ther* 2003; **18**: 71
- 5 Floch MH, Bina I. The natural history of diverticulitis: fact and theory. *J Clin Gastroenterol* 2004; **38**: 2-7
- 6 Fox JM, Stollman NH. Sleisenger & Fordtran's gastrointestinal and liver disease: pathophysiology, diagnosis, management. Vol.2, 8th ed. Philadelphia: Saunders Elsevier, 2006. Chapter 114, Diverticular disease of the colon; 2613-2632.
- 7 Tursi A, Brandimarte G, Elisei W, Giorgetti GM, Inchingolo CD, Aiello F. Faecal calprotectin in colonic diverticular disease: a case-control study. *Int J Colorectal Dis* 2009; **24**: 49-55
- 8 Cole JA, Cook SF, Sands BE, Ajene AN, Miller DP, Walker AM. Occurrence of colon ischemia in relation to irritable bowel syndrome. *Am J Gastroenterol* 2004; 486-491
- 9 Tursi A. Acute diverticulitis of the colon – current medical therapeutic management. *Expert Opin Pharmacother.* 2004; **5**: 145-149
- 10 Di Mario F, Aragona G, Leandro G, Comparato G, Fanigliulo L, Cavallaro LG, Cavestro GM, Iori V, Maino M, Moussa AM, Gnocchi A, Mazzocchi G, Franzé A. Efficacy of mesalazine in the treatment of symptomatic diverticular disease. *Dig Dis Sci* 2005; **50**: 581-586
- 11 Tursi A, Brandimarte G, Giorgetti GM, Elisei W. Mesalazine and/or Lactobacillus casei in preventing recurrence of symptomatic uncomplicated diverticular disease of the colon: a prospective, randomized, open-label study. *J Clin Gastroenterol.* 2006; **40**: 312-316
- 12 Tursi A, Brandimarte G, Elisei W, Giorgetti GM, Inchingolo CD, Danese S, Aiello F. Assessment and grading of mucosal inflammation in colonic diverticular disease. *J Clin Gastroenterol* 2008; **42**: 699-703

- 13 Konikoff MR, Date I, Andersson I. Role of calprotectin as a biomarker of intestinal inflammatory bowel disease. *Inflamm Bowel Dis* 2006; **12**: 524-534
- 14 Limburg PJ, Ahlquist DA, Sandborn WJ. Fecal calprotectin levels predict colorectal inflammation among patients with chronic diarrhea referred for colonoscopy. *Am J Gastroenterol* 2000; **95**: 2831-2837
- 15 Langhorst J, Elsenbruch S, Mueller T. Comparison of 4 neutrophil-derived proteins in feces as indicators of disease activity in ulcerative colitis. *Inflamm Bowel Dis* 2005; **11**: 1085-1091
- 16 Vermeire S, van Assche G, Rutgeerts P. Laboratory markers in IBD: Useful, magic, or unnecessary toys? *Gut* 2006; **55**: 426-431
- 17 Tibble JA, Sigthorsson G, Bridger S, Fagerhol MK, Bjarnason I. Surrogate markers of intestinal inflammation are predictive of relapse in patients with inflammatory bowel disease. *Gastroenterology* 2000; **119**: 15-22
- 18 Roseth AG, Schmidt PN, Fagerhol MK. Correlation between faecal excretion of indium-111-labelled granulocytes and calprotectin, a granulocyte marker protein in patients with inflammatory bowel disease. *Scand J Gastroenterol* 1999; **34**: 50-54
- 19 Desai D, Faubion WA, Sandborn WJ. Biological activity markers in inflammatory bowel disease. *Aliment Pharmacol Ther* 2007; **25**: 247-255
- 20 Bunn SK, Bisset WM, Main MJ. Fecal calprotectin: validation as a noninvasive measure of bowel inflammation in childhood inflammatory bowel disease. *J Pediatr Gastroenterol Nutr* 2001; **33**: 14-22
- 21 Kane SV, Sandborn WJ, Rufo PA. Fecal lactoferrin is a sensitive and specific marker in identifying intestinal inflammation. *Am J Gastroenterol* 2003; **98**: 1309-1314
- 22 Montalto M, Curigliano V, Santoro L. Fecal calprotectin in first-degree relatives of patients with ulcerative colitis. *Am J Gastroenterol* 2007; **102**: 132-136
- 23 Fagerhol MK. Calprotectin, a faecal marker of organic gastrointestinal abnormality. *The Lancet* 2000; **356**: 1783-1784
- 24 Gearry R, Barclay M, Florkowski C, George P, Walmsley T. Faecal calprotectin : the case for a novel non-invasive way of assessing intestinal inflammation. *Journal of the New Zealand Medical Association* 2005; **118**: N 1214
- 25 Tibble JA, Bjarnason I. Non-invasive investigation of inflammatory bowel disease. *World J Gastroenterol*. 2001; **7**: 460-465
- 26 Köhler L, Sauerland S, Neugebauer E. Diagnosis and treatment of diverticular disease: results of a consensus development conference. *Surg Endosc* 1999; **13**: 430-436
- 27 Pereira JM, Sirlin CB, Pinto PS, Jeffrey RB, Stella DL, Casola G. Disproportionate fat stranding: a helpful CT sign in patients with acute abdominal pain. *Radio Graphics* 2004; **24**: 703-715
- 28 Tursi A, Brandimarte G, Giorgetti G, Elisei W, Maiorano M, Aiello F. The clinical picture of uncomplicated versus complicated diverticulitis of the colon. *Dig Dis Sci* 2008; **53**: 2474-2479
- 29 Drossman DA. The functional gastrointestinal disorders and the Rome III process. *Gastroenterology* 2006; **130**: 1377-1390.
- 30 Silverberg M, Satsangi J, Ahmad T, Arnott ID, Bernstein CN, Brant SR, Caprilli R, Colombel JF, Gasche C, Geboes K, Jewell DP, Karban A, Loftus Jr EV, Peña AS, Riddell RH, Sachar DB, Schreiber S, Steinhardt AH, Targan SR, Vermeire S, Warren BF. Toward an integrated clinical, molecular and serological classification on inflammatory bowel disease: report of a Working Party of the 2005 Montreal World Congress of Gastroenterology. *Can J Gastroenterol* 2005; **19**: 5A-36A
- 31 Rutgeerts P, Sandborn WJ, Feagan BG, Reinisch W, Olson A, Johanns J, Travers S, Rachmilewitz D, Hanauer SB, Lichtenstein GR, de Villiers WJ, Present D, Sands BE, Colombel JF. Infliximab for induction and maintenance therapy for ulcerative colitis. *N Engl J Med* 2005; **353**: 2462-2476
- 32 Roseth AG, Aadland E, Jahnsen J, Raknerud N. Assessment of disease activity in ulcerative colitis by faecal calprotectin, a novel granulocyte marker protein. *Digestion* 1997; **58**: 176-80
- 33 Pezzilli R, Barassi A, Morselli Labate AM, Finazzi S, Fantini L, Gizzi G, Lotzniker M, Villani V, Melzi d'Eril G, Corinaldesi R. Fecal calprotectin levels in patients with colonic polyposis. *Dig Dis Sci* 2008; **53**: 47-51
- 34 Montalto M, Santoro L, Curigliano V, D'Onofrio F, Cammarota G, Panunzi S, Ricci R, Gallo A, Grieco A, Gasbarrini A, Gasbarrini G. Fecal calprotectin in untreated celiac patients. *Scand J Gastroenterol* 2007; **42**: 957-961
- 35 Dumitru E, Alexandrescu L, Suceveanu AI, Dumitru IM, Tofolean IT. M1255 fecal calprotectin in diagnosis of complicated colonic diverticular disease. *Gastroenterology* 2010; **138**: S365
- 36 Damms A, Bischoff SC. Validation and clinical significance of a new calprotectin rapid test for the diagnosis of gastrointestinal diseases. *Int J Colorectal Dis* 2008; **23**: 985-992
- 37 Jensen MD, Kjeldsen J, Nathan T. Fecal calprotectin is equally sensitive in Crohn's disease affecting the small bowel and colon. *SGAS* 2011; 1-7

Peer reviewers: Gokulakrishna Subhas, Department of general surgery, Providence hospital and medical centres, 16001 W. 9 mile road, Southfield, Michigan, the United States of America; Maha Maher Shehata, Professor, Internal Medicine Department, Gastroenterology and Hepatology Unit, Mansoura University, Specialized Medical hospital, 35516, Mansoura, Egypt.