

Efficacy of Calcium Alginate in Prevention of Hepatic Parenchymal Bleeding: An Experimental Study

Erdem Kinaci, Fatih Basak, Oguzhan Dincel

Erdem Kinaci, Fatih Basak, Oguzhan Dincel, SB Istanbul Educational and Research Hospital, Department of General Surgery, Kocamustafapasa, Istanbul, 34089, Turkey

Correspondence to: Erdem Kinaci, MD, Kasap Ilyas Mah. Org Nafiz gurman Caddesi, Istanbul Eğitim ve Arasturma Hastanesi, Genel Cerrahi Klinigi, Fatih, Istanbul, 34089, Turkey. erdemkinaci@gmail.com

Telephone: +90-506-508-79-30

Received: February 14, 2012 Revised: March 1, 2012

Accepted: March 3, 2012

Published online: May 21, 2013

Study. *Journal of Gastroenterology and Hepatology Research* 2013; 2(5): 593-596 Available from: URL: <http://www.ghrnet.org/index.php/joghr/article/view/387>

INTRODUCTION

The liver is the most common injured organ in abdominal trauma. Uncontrollable bleeding is a life-threatening problem in severe traumatic liver injury with the mortality rate of 10%-15%^[1]. The liver is, also, a common site of metastasis in patients with colorectal, neuroendocrine or non-colorectal non-neuroendocrine malignancies. In that cases, surgical resection is only therapeutic option that provides long term survival and even cure^[2]. Hepatic resection can be unpredictably complicated by abundant hemorrhage^[3]. Furthermore, perioperative blood transfusion is a risk factor for poor outcome after liver resections in patients with malignancies^[4]. So, there are two critical aims for surgeons, the first is resection without hemorrhage in elective hepatic surgery and the second is control the bleeding caused by hepatic trauma.

Histologic structure of the liver is an obstacle to control the parenchymal bleeding. Hepatic sinusoidal structure does not have smooth muscle capable of contraction to induce vasoconstriction. Hence, hepatic parenchymal bleeding is not easily controllable and particularly tend to be insistent^[5].

Various substances and/or techniques have been tried out to control the hepatic parenchymal bleeding^[6]. Of the many methods available for this aim, topically applied hemostatic agents like microfibrillar collagens and fibrin glue, have been widely used^[7,8].

Calcium Alginate (CA) is a calcium salt of alginate that is derived from seaweed. Alginate is a polysaccharide that consist of α -L-glucuronic acid ve β -D-mannuroic acid monomers^[9,10]. CA is combination of two alginate molecules with a calcium ion. Currently, it is widely used as a wound dressing material^[9,10]. CA has ion exchange property. On contact with blood, calcium ions are released in exchange for sodium ions^[9,10]. Migrating calcium ions activate coagulation both by stimulating platelet aggregation and working as cofactor in coagulation cascade^[11,12].

Owing to the aforementioned properties of calcium alginate, we anticipated that it could be a reliable hemostatic agent. Hence in this study, the efficiency of CA was evaluated in rats with hepatic parenchymal bleeding caused by experimental laceration, and the possibility of these agents for hemostat was assessed.

ABSTRACT

AIM: Control of hepatic bleeding is still a major problem in hepatic surgery and abdominal trauma. In this study we assesed the effectiveness of Calcium Alginate to improve hepatic parenchymal bleeding in liver trauma or elective hepatic surgery.

METHODS: We studied on a hepatic laceration model in 27 female Wistar albino rats. Subjects were divided into two groups; study group ($n=12$) and control group ($n=15$). Amount of intraoperative bleeding, preoperative and postoperative hematocrit levels and the difference between them were compared.

RESULTS: In comparison of intraoperative bleeding; in study group, bleeding was less in study group (1.31 ± 0.69 mL) than that in control group (2.03 ± 0.83 mL) ($p=0.02$). There was a significant decrease in hematocrit level in both groups. Decrease in hematocrit levels in the study group (5.25 ± 3.67) was significantly less than that in control group ($11.2\pm 3.9L$) ($p=0.002$). In histopathological examination, Calcium Alginate fibers were surrounded by inflammatory cells. There was intense fibrosis around the fibers and contacting tissues. In control group, there was no fibrosis.

CONCLUSIONS: Calcium Alginate is an effective hemostatic agent in the improvement of hepatic parenchymal bleeding. But it can cause intraabdominal adhesions and intestinal obstruction in long term, if it is leaved *in vivo*.

© 2013 ACT. All rights reserved.

Key words: Alginate; Bleeding; Calcium; Hemorrhage; Liver

Kinaci E, Basak F, Dincel O. Efficacy of Calcium Alginate in Prevention of Hepatic Parenchymal Bleeding: An Experimental

MATERIALS

Consent was received from Istanbul University, Cerrahpasa Faculty of Medicine, Experimental Animals Production and Research Laboratory Ethical Committee. (Approval code: 2005-35311). The number of animal subjects was determined after negotiation with a biostatistician specialist. Twenty-seven Wistar albino female rats were selected from ages varying between 28 to 30 weeks and an average weight of 200 g. Rats were kept in plastic based production cages with plastic sides which were covered by a wire knitted cover placed over the top of the cage and animals were fed by privately manufactured pellet type factory fodders prepared especially for such animals.

Rats were randomly divided into two groups: Study group and control group, consisting of 12 and 15 rats respectively. After one night of fasting, they were anesthetized in jars with ether for a period of 45-60 s. Anesthesia was maintained with an injection of 75 mg/kg intramuscular Ketamine (Ketalar®, Eczacıbasi Co). Animals did not receive antibiotic prophylaxis. Preoperative hematocrite level was assessed by the blood sample taken into capillary tubes from the tail. Incision area on the midline of the abdomen was cleaned with 10% povidone iodine solution. The abdomen was entered with a 3 cm median incision that started from just inferior to xiphoid process.

Initially, a funnel shaped plastic bag was taken under the left lobe of the liver. Surgical procedure was applied on a wooden platform which was placed 45 degrees of angle to accumulate the whole blood in placed bag.

The left lobe of liver is located medially in rats. It provides technical facility to reach the liver through median incision, therefore the model was performed on left lobe of liver.

We performed the laceration model that was first described by Aysan^[13]. According to this model, three parallel incisions were performed with 12 no scalpel. There were five millimeters of healthy tissue between the incisions. The incisions were 1-2 mm in depth and 10 mm in length. After the beginning of bleeding, in control group, a standard cotton gauze moisten with 0.9% sodium chloride (NaCl) solution was applied to laceration area for five minutes. At the end of five minutes, gauze was taken out and a thin fibrin cloth upon the laceration area was seen, meanwhile there was no active bleeding. In study group, CA patch (Sorbalgon®, Hartmann) (10×10×2 mm) was packed to the laceration area without any manual pressure and it leaved in the abdomen (Figure 1). The CA patch is currently in clinical use as wound dress. In both groups, blood was collected in the plastic bag for 10 min, including the time to apply the moisten gauze in control group. After the plastic bag taken out, abdominal incision was closed with 3/0 propylene in continuous manner. The collected blood in plastic bag was taken into a scaled injector and measured as milliliter.

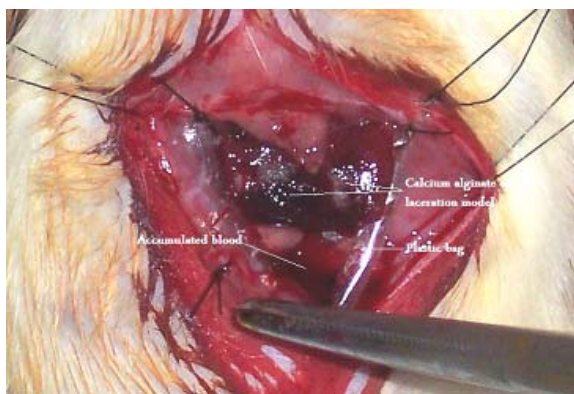


Figure 1 Calcium alginate patch packed on the laceration area.

Hematocrit levels were assessed by the blood sample taken into capillary tubes from the tail at the end of first day postoperatively. At the end of seventh day, a liver specimen including laceration area was taken for histopathological evaluation from all rats under general anesthesia.

Hemostatic effect was assessed by comparing both amount of intraoperative bleeding and difference between preoperative and postoperative hematocrit levels in two groups.

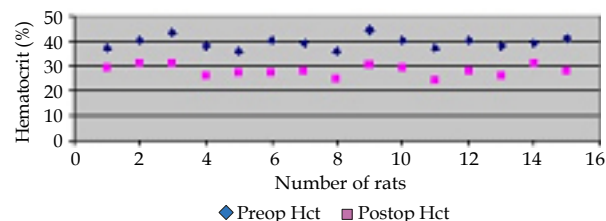
RESULTS

Statistical analysis was done by using GraphPad Prisma V.3 program. Data were evaluated by using descriptive statistical methods (median, standart deviation). Additionally to compare the binary groups Mann-Whitney U test and to make recurring measurements of groups Wilcoxon test were used. Reference value was $p < 0.05$.

In both groups, there was significant decrease in hematocrit levels. In control group, maximum and minimum values of preoperative hematocrit levels were 44% and 36%, respectively. In study group, the ranges were between 34% and 49%. However, postoperative hematocrit values were in range between 24% and 31% in control group and between 32% and 44% in study group. The graph in figure 2, shows the hematocrit values of each rat in both groups. When we compared median preoperative hematocrit values of two groups, there was no statistically significant difference ($p = 0.089$). The difference in postoperative hematocrit values was found statistically significant ($p = 0.001$). The amount of blood loss was significantly low in study group than that in control group. There was no postoperative mortality in both groups. The results of study and the statistical analysis shown in table 1 and 2 in details.

Histopathological examination was performed under X300 magnification light microscope. In study group, the calcium alginate fibers were dark colored in heamatoxyline-eosin staining. The material was surrounded by inflammatory cells and there was intense fibrosis between the CA fibers, the liver and the adjacent tissues. However, fibrosis was limited the surface of the liver and there was no fibrotic reaction in deep parenchyma. Although there was some CA fibers surrounded by macrophages that start to resorbition of them, it was very limited. Particularly, no granulomatous foreign body reaction was seen (Figure 3). In control group, microscopically there was subcapsular histiocytic proliferation and fibrin accumulation. No fibrosis was seen (Figure 4).

Preoperative and postoperative hematocrit values of all rats in control group



Preoperative and postoperative hematocrit values of all rats in study group

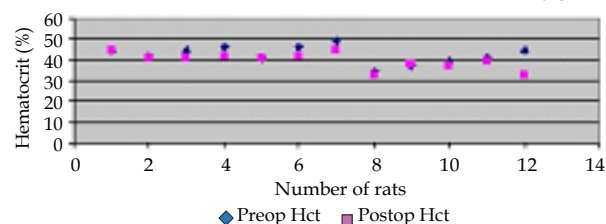


Figure 2 Scattered graph shows preoperative and postoperative hematocrit values of each rat in both groups.

Table 1 Preoperative and postoperative mean hematocrit levels in both groups. Reduction in hematocrit level was significantly low in study group.

	Control Group (n=15)	Study Group (n=12)	MW ¹	P value
Preoperative Hematocrit Level (%)	39.20±1.70	41.83±4.02	42	0.089
Postoperative Hematocrit Level (%)	28.00±4.02	36.75±5.45	16.5	0.001 ²
Wilcoxon	-3.41	-3.07		
P value	0.0001 ²	0.002 ²		

¹ MW: Mann-Whitney U test; ² p<0.05: statistically significant.

Table 2 Mean decrease in hematocrit levels and comparison of them. Mean blood loss was significantly low in study group in comparison with control group.

	Control Group (n=15)	Study Group (n=12)	MW ¹	P value
Decrease in hematocrit levels (mean %)	11.2±3.91	5.25±3.67	18.5	0.002 ²
Amount of bleeding (mL)	2.03±0.83	1.31±0.69	32	0.02 ²

¹ MW: Mann-Whitney U test; ² p<0.05: statistically significant.

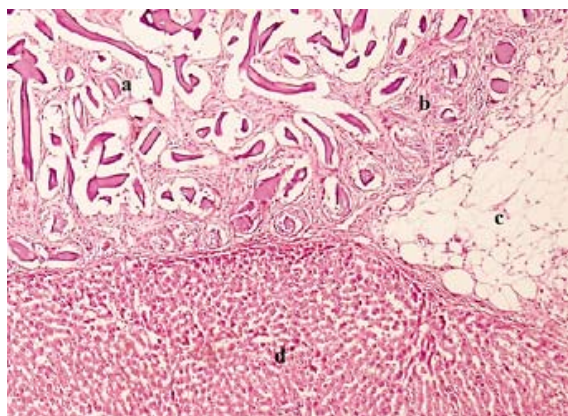


Figure 3 Histologic appearance of the liver specimen of study group a. The calcium alginate fibers (dark colored in heamatoxyline-eosin staining) surrounded by inflammatory cells. Very limited resorbption of some calcium alginate fibers by macrophages. No granulomatous foreign body reaction. b. Intense fibrosis between liver and adjacent tissues. c. Omentum. d. The fibrosis, limited the surface of the liver. No fibrotic reaction in deep parenchyma. (Heamatoxyline-Eosin, ×300).

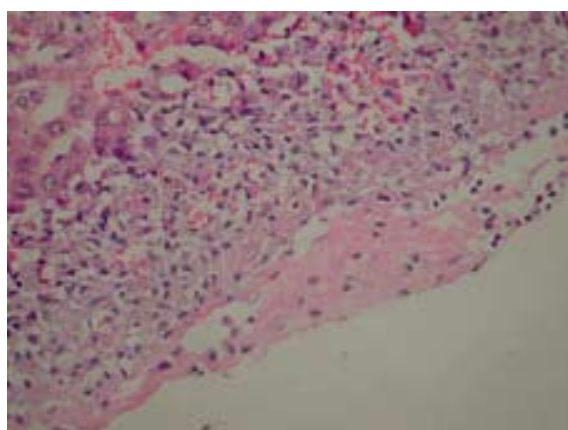


Figure 4 Histologic appearance of the liver specimen of control group. Subcapsular histiocytic proliferation and fibrin accumulation. No fibrosis (Heamatoxyline-Eosin, ×300).

DISCUSSION

Alginate fibers have ion-exchange property. When CA fibers are in contact with the tissue, calcium ions on alginate fibers are replaced by the sodium ions of the body fluid. While the migrating calcium ions serve as a cofactor in coagulation system, sodium ions are bounded to

alginate fibers to make a fibrous gel named sodium alginate, which is highly water-soluble and absorbable *in vivo*^[9,14].

The main mechanism of action of topically applied hemostatic agents is the contact activation of platelets. In addition, some agents have other mechanisms, like glue or plug effect^[13]. Whereas, CA exhibits its hemostatic effect by releasing calcium ions. Calcium ions activate factor VII, IX and X in coagulation system. In literature, it is reported that the effect on coagulation system increases while the amount of calcium ions increases on alginate fibers^[6,15]. In this study we ignored the contact activation of platelets, because it was a subject for both groups. Therefore, we focused on the effect of calcium ions on coagulation system.

CA has previously been experimented as topical hemostatic agent. It was successfully used as an endovascular embolisation material in experimental model of aneurysm by Soga^[16]. Likewise, it is demonstrated that CA swabs significantly decrease per-operative blood loss and post-operative suction drainage loss in case of internal fixation of intertrochanteric fractures of the proximal femur^[17].

However, in three studies it was demonstrated that CA was not superior to standart gauze application in improvement of bleeding after hemorrhoidectomy, tooth extraction and adenotonsillectomy^[15,18,19].

As seen, there are contradictions in literature. Both positive and negative results have been reported about the hemostatic effects of CA. In our study, calcium alginate had been left in the abdomen on hepatic laceration area. It decreased the amount of intraoperative blood loss and diminished the reduction in hematocrit level. In the studies that showed no significant effect of CA on bleeding, the material had not been left in the wounds, so it can be the reason of this negative results.

Alginate is an absorbable material^[9]. In our histopathologic examination, absorbtion process was seen only in a few areas. If we consider that the specimen was taken in seventh day, it can be predicted that the absorbtion process will take a long time depends on the amount of material. Furthermore, microscopically, there was an intense fibrosis between the alginate fibers and adjacent tissues. The fibrosis is one of the main steps of formation of adhesion which is the most common cause of mechanical intestinal obstruction^[4,20].

The bioadhesive properties of CA have been investigated^[21]. In our study, leaving of CA in the abdomen lead to intraabdominal adhesions, so mechanical intestinal obstruction can be expected in long term. This study is focused to hemostatic effect of CA, so the adhesive effect of it is not assesed in detail. But, the adhesive effect of CA must be considered in future studies.

In conclusion, CA is significantly effective hemostatic material for hepatic bleeding. But, it tends to cause intraperitoneal adhesion by making intense fibrosis. Therefore, further experimental and clinical studies should be planned to assess the utility of CA in the abdomen.

REFERENCES

- 1 Parks RW, Chryso E, Diamond T. Management of liver trauma. *Br J Surg* 1999; **86**: 1121-1135
- 2 De Santibañes E, Sánchez Clariá R, Palavecino M, Beskow A, Pekolj J. Liver metastasis resection: a simple technique that makes it easier. *J Gastrointest Surg* 2007; **11**: 1183-1187
- 3 Smyrniotis V, Farantos C, Kostopanagiotou G, Arkadopoulos N. Vascular control during hepatectomy: review of methods and results. *World J Surg* 2005; **29**: 1384-1396
- 4 Kooby DA, Stockman J, Ben-Porat L, Gonen M, Jarnagin WR, Dematteo RP, Tuorto S, Wuest D, Blumgart LH, Fong Y. Influence of transfusions on perioperative and long-term outcome in patients following hepatic resection for colorectal metastases. *Ann Surg* 2003; **237**: 860-869

Kinaci E *et al.* Does calcium alginate prevent hepatic bleeding?

- 5 Clark WR Jr, Leather RP. Hemostasis during liver resections. *Surgery* 1970; **67**: 556-557
- 6 Chapman WC, Clavien PA, Fung J, Khanna A, Bonham A. Effective control of hepatic bleeding with a novel collagen-based composite combined with autologous plasma: results of a randomized controlled trial. *Arch Surg* 2000; **135**: 1200-1204
- 7 Kohno H, Nagasue N, Chang YC, Taniura H, Yamanoi A, Nakamura T. Comparison of topical hemostatic agents in elective hepatic resection: a clinical prospective randomized trial. *World J Surg* 1992; **16**: 966-969
- 8 CoStasis Multi-center Collaborative Writing Committee. A novel collagen-based composite offers effective hemostasis for multiple surgical indications: Results of a randomized controlled trial. *Surgery* 2001; **129**: 445-450
- 9 Qin Y. Absorption Characteristics of alginate wound dressings. *J App Polymer Science* 2003; **91**: 953-957
- 10 Gilchrist T, Martin AM: Wound treatment with Sorbsan-an alginate fibre dressing. *Biomaterials* 1983; **4**: 317-320
- 11 McNicol A, Israels SJ. Platelets and anti-platelet therapy. *J Pharmacol Sci* 2003; **93**: 381-396
- 12 Spronk HM, Govers-Riemslog JW, ten Cate H. The blood coagulation system as a molecular machine. *Bioessays* 2003; **25**: 1220-1228
- 13 Aysan E, Kilic K, Kinaci E, Basak F, Caliskan YK. Efficacy of "Aluminium Sulphate" in prevention of hepatic parenchymal bleeding. *Turk J Surg* 2004; **20**: 147-152
- 14 Jarvis PM, Galvin DAJ, Blair SD, McCollum CN. How does calcium alginate achieve haemostasis in surgery? *Thromb Haemostas* 1987; **58**: 50
- 15 Henderson NJ, Crawford PJ, Reeves BC. A randomised trial of calcium alginate swabs to control blood loss in 3-5-year-old children. *Br Dent J* 1998; **184**: 187-190
- 16 Soga Y, Preul MC, Furuse M, Becker T, McDougall CG. Calcium alginate provides a high degree of embolisation in aneurysm models: A specific comparison to coil packing. *Neurosurgery* 2004; **55**: 1401-1409
- 17 Davies MS, Flannery MC, McCollum CN. Calcium alginate as haemostatic swabs in hip fracture surgery. *J R Coll Surg Edinb* 1997; **42**: 31-32
- 18 Ingram M, Wright TA, Ingoldby CJ. A prospective randomized study of calcium alginate [sorbsan] versus standard gauze packing following haemorrhoidectomy. *J R Coll Surg Edinb* 1998; **43**: 308-309
- 19 Milford CA, Sudderick RM, Bleach NR, O'Flynn PE, Muggliston TA, Hadley J. The influence of calcium alginate haemostatic swabs upon operative blood loss in adenotonsillectomy. *Clin Otolaryngol Allied Sci* 1990; **15**: 303-306
- 20 DiZerega GS, Campeau JD. Peritoneal repair and post-surgical adhesion formation. *Hum Reprod Update* 2001; **7**: 547-555
- 21 Gaserod O, Jolliffe IG, Hampson FC, Dettmar PW, Skjak-Braek G. The enhancement of the bioadhesive properties of calcium alginate gel beads by coating with chitosan. *Int J Pharm* 1998; **175**: 237-246

Peer reviewers: Jing-Min Zhao, Professor, Chief Physician, MD, PhD, Department of Pathology and Hepatology, Beijing 302 Hospital, No.100 Xisihuan Middle Road, Beijing 100039, China; Fethi Derbel, Professor, Department of general and digestive surgery, University hospital Sahloul, 4056, SOUSSE, Tunisia.