

## A Rare Case of Pediatric Gastric Xanthoma: Diagnosis and Follow-up

Marco Gasparetto, Pennelli Gianmaria, Galuppini Francesca, Cananzi Mara, Guariso Graziella

Marco Gasparetto, Cananzi Mara, Guariso Graziella, Department of Women's and Children's Health Unit of Gastroenterology, Digestive Endoscopy, Hepatology, and Care of the Child with Liver Transplantation, University Hospital of Padova, Italy

Pennelli Gianmaria, Galuppini Francesca, Department of Medicine DIMED, Surgical Pathology and Cytopathology Unit, University Hospital of Padova, Italy

Correspondence to: Marco Gasparetto, MD, Padova University Hospital, Department of Women's and Children's Health, Unit of Gastroenterology, Digestive Endoscopy, Hepatology, and Care of Children with Liver Transplants, Via Giustiniani 3, 35128 Padova, Italy. [markgasp@gmail.com](mailto:markgasp@gmail.com)

Telephone: +39-049-8213-509 Fax: +39-049-821-5430

Received: March 2, 2013 Revised: March 24, 2013

Accepted: March 26, 2013

Published online: May 21, 2013

### ABSTRACT

Gastric xanthomas are rare benign lesions that appear to be associated with inflammation of the gastric mucosa. Their etiology has yet to be fully elucidated and only one pediatric case and a few adult cases have been described to date. We report on a pediatric case of gastric xanthomatosis. A 13-year-old girl with dysphagia, burning sensation in the chest, regurgitation and rumination after meals (with no abdominal pain or altered stool frequency) underwent upper GI endoscopy, disclosing six gastric lesions appearing as nodules and soft pseudo-polyps measuring 0.5-1 cm, with a "papilloma-like" greyish-white top. Histology identified foamy histiocytes leading to the diagnosis of gastric xanthoma. No treatments have been administered to the patient during a 1-year follow-up, and the girl's signs and symptoms have resolved spontaneously. It is important to recognize gastric xanthomas because they often have an ulcer-like appearance at endoscopy, and inappropriate antacid treatment might consequently be prescribed. Taking biopsies during upper GI endoscopy is fundamental to the diagnosis of gastric xanthoma, as well as to exclude gastric tumors.

© 2013 ACT. All rights reserved.

**Key words:** Gastric xanthomatosis; Pediatric; Ulcers; Foamy histiocytes; Upper GI endoscopy

Gasparetto M, Pennelli G, Galuppini F, Cananzi M, Guariso G. A Rare Case of Pediatric Gastric Xanthoma: Diagnosis and Follow-up. *Journal of Gastroenterology and Hepatology Research* 2013; 2(5): 607-608 Available from: URL: <http://www.ghrnet.org/index.php/joghr/article/view/391>

### INTRODUCTION

Gastric xanthomas are rare, single or multiple, benign lesions most frequently found in the antrum. The first description of gastric xanthoma was published by Lubarsch and Borchardt in 1929<sup>[1]</sup>.

These lesions appear to be associated with inflammation of the gastric mucosa, especially in patients with chronic gastritis, *Helicobacter pylori* infection, intestinal metaplasia, or bile reflux<sup>[2]</sup>.

The formation of gastric xanthoma appears to be related to healing processes in response to tissue damage. Previous studies by Hori, Tsutsumi<sup>[3]</sup> and Isomoto<sup>[4]</sup> identified *Helicobacter pylori* in 48% of biopsies from gastric xanthomatous lesions, and an association with atrophic gastritis.

No correlation has been found between the onset of GI xanthomatosis and dyslipidemia, diabetes mellitus or cutaneous xanthomatosis<sup>[5]</sup>.

Unlike cutaneous xanthelasma, no correlation has yet been recognized between GI xanthoma and any increased cardiovascular risk<sup>[6]</sup>.

The etiology of gastric xanthoma is still not clear, given the rarity of these conditions. A limited number of cases in adults over >35 years old has been reported<sup>[2-7]</sup>, while - to our knowledge - only one previous pediatric case has been published to date<sup>[8]</sup>.

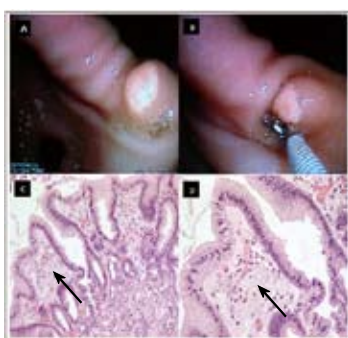
### CASE REPORT

A 13-year-old girl came to our attention for dysphagia, burning sensation in the chest, and regurgitation and rumination after meals; she reported no abdominal pain or altered stool frequency.

Clinical examination revealed a normal picture except for a mild decrease in body weight (from the 25<sup>th</sup> to the 10<sup>th</sup> %ile) in relation to the girl's height (50<sup>th</sup> %ile). Blood tests (including hematological profile, infection indexes, biochemical profile, liver and coagulation tests, pancreatic enzymes) were all negative, and so were Gastro-Panel tests, a combined evaluation of serum pepsinogens A (PGA) and C (PGC), gastrin-17 (G17) and anti-*H. pylori* antibodies<sup>[9]</sup>.

A first upper GI tract endoscopy had already been performed at the time of symptom onset, revealing two whitish kissing lesions 0.3 cm in diameter, surrounded by hyperemic mucosa, in the middle of the lesser gastric curve, and a mildly hyperemic antral mucosa. Histology had demonstrated inactive chronic gastritis in the antrum and in the areas adjacent to the two lesions. No *Helicobacter pylori* was detected. Therapy with the proton pump inhibitors (PPI) was prescribed and completed for one month, with only partial remission of symptoms.

Given a relapse of symptoms two weeks after suspending PPI treatment, a second upper GI endoscopy was performed at our Unit (two months after the first endoscopy). This time, 6 gastric lesions were found (Figure 1), appearing as nodules and soft pseudo-polyps measuring 0.5-1 cm, with a greyish-white top, resembling a papilloma. There was evidence of bile reflux. Histology identified foamy histiocytes (see arrows in Figure 1) compatible with gastric xanthoma.



**Figure 1** Gastric xanthoma: endoscopic and histological features. A and B: endoscopic features of gastric xanthoma, appearing as nodular, soft pseudo-polypoid lesions measuring 0.5-1 cm, with a greyish-white papilloma-like top. C and D: histology with hematoxylin and eosin staining reveals the typical foamy histiocytes (arrows) of gastric xanthoma (original magnification 20× in C; 40× in D).

Based on current knowledge of gastric xanthoma, and given the absence of other gastric lesions, no further treatments have been administered to the patient during a 1-year follow-up (since the first upper GI endoscopy). The girl's initially reported signs and symptoms resolved spontaneously soon after our evaluation, and she currently has a normal quality of life. No further endoscopies are scheduled for the time being, unless significant symptom recurrence or other causes for alarm are reported.

## DISCUSSION

Although gastric xanthomas are considered rare, there are signs of an increase in their incidence<sup>[8]</sup>. Considering all the case reports in the literature, the updated prevalence of GI xanthomatosis in the general population is estimated to be in the range of 0.018% to 0.8% (with a 7% peak in the Asian population)<sup>[8]</sup>.

The histological pattern of gastric xanthoma is characterized by numerous foamy histiocytes in the lamina propria; the absence of nuclear atypia and cytokeratins rules out gastric malignancies<sup>[3]</sup>.

It is important to recognize gastric xanthomas correctly to avoid their endoscopically ulcer-like appearance prompting unwarranted antacid treatments<sup>[2,5]</sup>.

In the case described here, GastroPanel findings<sup>[9]</sup> were normal at

the time of the first endoscopy, whereas they would probably have been altered in the event of a peptic ulcer.

Taking biopsies during upper GI endoscopy is fundamental to the diagnosis of gastric xanthoma and enables gastric tumors to be ruled out<sup>[10]</sup>. On immunohistochemical analysis of bioptic samples from xanthomatous lesions, human macrophage markers are positive, while cytokeratins will be negative in the absence of gastric tumor<sup>[11]</sup>.

The case described here is a rare example of gastric xanthoma in pediatric age. It was diagnosed on a second upper GI endoscopy performed at our Unit, and the results of a previous endoscopy were available for comparison. This enabled us to draw on a retrospective endoscopic follow-up to shed further light on the behavior of these lesions. When a patient is diagnosed with GI xanthomatosis, no specific treatments or routine endoscopic follow-up are currently recommended, with the exception of cases presenting with concomitant diseases (i.e. chronic gastritis, peptic ulcers)<sup>[2,5]</sup>.

## REFERENCES

- 1 Wetzler G, Felix AA, Lipton JF. Image of the month: gastric xanthelasma. *J Ped Gastroenterol Nutr* 2010; **51**: 1
- 2 Gravina AG, Iacono A, Alagia I, D'Armiento FP, Sansone S, Romano M. Gastric xanthomatosis associated with gastric intestinal metaplasia in a dyspeptic patient. *Dig Liv Dis* 2009; **41**: 765
- 3 Hori S, Tsutsumi Y. *Helicobacter pylori* infection in gastric xanthomas: immunohistochemical analysis of 145 lesions. *Pathol Int* 1996; **46**: 589-593
- 4 Isomoto H, Mizuta Y, Inoue K, Matsuo T, Hayakawa T, Miyazaki M, Onita K, Takeshima F, Murase K, Shimokawa I, Kohno S. A close relationship between *Helicobacter pylori* infection and gastric xanthoma. *Scand J Gastroenterol* 1999; **34**: 346-352
- 5 De Roberto G, Ravizza D, Fiori G, Trovato C, Maffini F, Tamayo D, Crosta C. A massive gastric xanthomatosis. *Endoscopy* 2009; **41**: E54-E55
- 6 Sun Young Yi. Dyslipidemia and *H. pylori* in gastric xanthomatosis. *World J Gastroenterol* 2007; **13**: 4598-4601
- 7 Hiroyuki K, Shunsuke Y, Yoshifumi S, Kazuo A, Kazunari M and Rieko K. A rare case of xanthogranuloma of the stomach masquerading as an advanced-stage tumor. *World Journal of Surgical Oncology* 2011; **9**: 67
- 8 Jansen HJ, van Krieken JH, Römkens TEH. Yellow-white lesions in the upper gastrointestinal tract. *The Netherlands Journal of Medicine* 2009; **67** (10)
- 9 Guariso G, Basso D, Bortoluzzi CF, Meneghel A, Schiavon S, Fogar P, Farina M, Navaglia F, Greco E, Mescoli C, Zambon CF, Plebani M. GastroPanel: evaluation of the usefulness in the diagnosis of gastro-duodenal mucosal alterations in children. *Clin Chim Acta* 2009; **402**: 54-60
- 10 Moran AM, Fogt F. 70-year-old female presenting with rectosigmoid (colonic) xanthoma and multiple benign polyps. Case Report. *Pol J Pathol* 2010; **1**: 42-45

**Peer reviewers:** Andrew Stewart Day, Department of Paediatrics, University of Otago, Christchurch, P.O. Box 4345, Christchurch, 8140, New Zealand; Petar Ivanovski MD, PhD, Associate Professor of Pediatrics, subspecialist of hematology, General Pediatrics, University Children's Hospital Medical Faculty University of Belgrade 10 Tirshova str. 11000, Belgrade, Serbia.